



INTERNATIONAL SCIENTIFIC MEETING (TINI IV) & IKORGI NATIONAL CONGRESS XI

*Revolutionary Paradigm for the Future Vision
of Endodontics & Restorative Dentistry*

November 3rd-5th, 2017
Shangri-La Hotel
May. Jend. Sungkono 120 Surabaya

BUKU PROSIDING

Panitia Temu Ilmiah International IV & Konggres IKORGI XI
Sekretariat Dep. Konservasi Gigi FKG UNAIR
Jl. Mayjend Prof. Dr. Moestopo 47 Surabaya – 60132
Telp : 031-5030255 ext.117, Fax : 031-5039478
Email : konservasiunair@yahoo.com

PROCEEDING

International Scientific Meeting (TINI IV) & National Congress IKORGI XI

Theme :

Revolutionary Paradigm for the Future Vision of Endodontics and Restorative Dentistry

Surabaya, November 3rd – 5th, 2017

Steering Committee:

- M.Rulianto,drg.,MS.,SpKG(K)
- Prof.Dr.Latief Mooduto,drg.MS.Sp.KG(K)
- Karlina Samadi,drg.MS.Sp.KG(K)

Organizing Committee:

- Ari Subiyanto, drg.MS.Sp.KG (K)
- Karlina Samadi,drg.MS.Sp.KG(K)
- Dr.Dian Agustin W.,drg.,SpKG(K)
- Eric Priyo Prasetyo,drg.,M.Kes.,SpKG(K)
- Dr.Tamara Yuanita, drg.MS.Sp.KG(K)
- Dr. Ira Widjastuti,drg.,M.Kes.,SpKG(K)
- Dr. Widya Saraswati,drg.,M.Kes.,Sp.KG
- Galih Sampoerno,drg.M.Kes.,SpKG(K)
- Devi Eka Yuniarti,drg.,M.Kes.,SpKG(K)

Editor:

- M. Rulianto,drg.,MS.,SpKG(K)

Reviewer:

- Prof. Dr. Latief Mooduto,drg.,MS.,SpKG(K)
- Dr. Ira Widjastuti,drg.,M.Kes.,SpKG(K)
- Dr. Dian Agustin Wahyuningrum,drg.,SpKG(K)
- Eric Priyo Prasetyo,drg.,M.Kes.,SpKG(K)



Published by:

PENGURUS PUSAT IKATAN KONSERVASI GIGI INDONESIA (PP IKORGI)

Jl. Mayjend. Prof. Dr. Moestopo No. 47 Surabaya 60132

Telp. (031) 5030255; Fax. (031) 5020256

ISBN 978-602-19108-6-3

OPENING SPEECHES

Dear colleague,

International Scientific Meeting (TINI IV) & National Congress IKORGI XI is a great scientific meeting place for dentistry specialized in dental conservation. More than 70 full papers go to the Scientific Section of International Scientific Meeting Seminar (TINI IV) & National Congress IKORGI XI from colleagues of various educational institutions, hospitals and dental practitioners specialists and general. We thank you for the participation of our colleagues.

In organizing the International Scientific Meeting Seminar (TINI IV) & National Congress IKORGI I, the committee gives freedom to the contributor of the manuscript to select the desired publication. Contributors can publish papers in proceeding. This proceeding book contains complete papers presented at the International Scientific Meeting (TINI IV) & National Congress IKORGI XI.

We apologize if in the management and acceptance of papers there are many shortcomings. Feedback and criticism build our colleagues hope for improvement in the future. Hopefully this proceeding can be useful for us all.

Congratulations seminar, see you at International Scientific Meeting Seminar (TINI IV) & National Congress IKORGI XI in Surabaya

Surabaya, 3 – 5 November 2017

Ari Subiyanto, drg.,MS.,Sp.KG(K)

TABLE OF CONTENTS

OPENING SPEECHES	iii
TABLE OF CONTENTS	iv
C-SHAPED ROOT CANAL TREATMENT IN MANDIBULAR MOLAR (CASE REPORT)	
Adelia Mutia Indah, Juanita AG, Selviana Wulansari	1
HEMISECTION OF MANDIBULAR FIRST MOLAR WITH PERFORATED FURCATION	
Adeline Jovita Tambayong*, Prof. Dr. Mandojo Rukmo, drg., M.Sc., Sp KG (K)**	7
DIRECT COMPOSITE RESIN RESTORATION REINFORCED WITH SHORT FIBER POST ENDODONTIC TREATMENT ON NECROSIS MOLAR MANDIBULAR: A CASE REPORT	
Amarendra Anindita*, R. Tri Endro Untara**	13
THE ROLE OF GLASS IONOMER CEMENT PLACEMENT AS A BARRIER IN INTERNAL BLEACHING POST ENDODONTICALLY TREATED MAXILLARY ANTERIOR : CASE REPORT	
Amellia Tjandra ¹ , Agus Subiwahjudi ²	19
INTRACORONAL BLEACHING ON TOOTH DISCOLORED BY TRIPLE ANTIBIOTIC PASTE	
Andari Putrianti ¹ , Munyati Usman ²	25
RETREATMENT AND ROOT CANAL TREATMENT WITH ALL PORCELAIN CROWN RESTORATION AND FIBER POST ON FOUR ANTERIOR TEETH FRACTURE POST TRAUMA	
Arafita Putri Fardani*, Ema Mulyawati**	31

COMPOSITE RESIN RESTORATION WITH FABRICATED FIBER-REINFORCED POST COMPOSITE ON NECROSE PULP OF MAXILLARY CENTRAL INCISOR POST ROOT CANAL TREATMENT	
Betagia Swandhika Wisesa* Ema Mulyawati**	41
RETROGRADE FILLING USING MINERAL TRIOXIDE AGGREGATE (MTA) AND BONE GRAFT (REGENERATIVE MATERIAL) PLACEMENT AFTER APICOECTOMY AS MANAGEMENT OF NON-SURGERY ENDODONTIC FAILURE IN RIGHT MAXILARY CENTRAL INCISOR WITH PERIAPICAL GRANULOMA	
Budiono Wijaya ¹ and Pribadi Santosa ²	49
LITERATURE REVIEW	
EFFECTIVENESS DIODE LASER AS ADDITIONAL DEVICE ON ROOT CANAL DISINFETCION	
Chitra Iselinni ¹ , Ratna Meidyawati ²	55
APICAL RESECTION: AN ALTERNATIVE MANAGEMENT OF LARGE PERIAPICAL CYST	
Clarrisa Fredline*, Ari Subiyanto**	65
MANAGEMENT OF ESTHETIC COMPLEX CASE IN ANTERIOR MAXILLARY TEETH THROUGH A COMPREHENSIVE APPROACH: A CASE REPORT.	
CyrillaPrima A. M. ¹ , Tunjung Nugraheni ²	73
MANAGEMENT OF APEXIFICATION WITH MINERAL TRIOXIDE AGGREGATE APICAL PLUG ON PERMANENT MAXILLARY CENTRAL INCISORS : A CASE REPORT	
Dani Rudyanto*, Dian A Wahjuningrum.**	81
MANAGEMENT OF FIVE ROOT CANALS IN MANDIBULAR FIRST MOLAR TOOTH: A CASE REPORT	
Daryono, ¹ Bernard O. Iskandar, ² Wiena Widyastuti ²	89
NON-SURGICAL MANAGEMENT OF A LARGE PERIAPICAL LESION USING A SIMPLE ASPIRATION TECHNIQUE : A CASE REPORT	
Desneli* Adhita Dharsono**	95

ROOT CANAL TREATMENT AND RESTORATION USING METAL PREFABRICATED TAPERED SERRATED POSTS WITH PORCELAIN FUSED TO METAL FULL CROWN IN FAILURE ENDODONTIC TREATMENT	
Dewi Damarsasi*; Diatri Nari Ratih**	103
APICAL RESECTION FOR PERIAPICAL CYST TREATMENT CASE	
Diana Soesilo	111
THE AESTHETIC REHABILITATION OF THE MAXILLARY INCISORS AND SUPRAPOSITION OF THE MANDIBULAR CENTRAL INCISORS	
Andina Irinawati Prasetyo ¹ , Sri Kunarti ²	117
CROWN LENGTHENING AND ALL PORCELAIN JACKET CROWNS WITH THE PREFABRICATED FIBER POST REINFORCEMENT ON THE 12TH TOOTH OF THE CLASS IV ELLIS FRACTURE.	
Istikhomah Darmawati* ; Yulita Kristanti**	129
EFFECT OF ADDITION OF WHITE SHRIMP SHELL'S NANO CHITOSAN (LITOPENAEUS VANNAMEI) IN CALCIUM HYDROXIDE AGAINST FIBROBLAST CELL CYTOTOXICITY (MTT Test)	
¹ Dewa Made Wedagama ² , Yusfitra	139
INTERNAL BLEACHING AND RESTORATION USING PREFABRICATED FIBER POST COMBINED WITH POLYETHYLENE FIBER AND DIRECT COMPOSITE RESIN IN ENDODONTICALLY TREATED TOOTH WITH FLARED CANAL.	
Yohannes Dian Indrajati* ; Tunjung Nugraheni**	145
APICAL SURGERY FOR PERIAPICAL LESION MANAGEMENT CAUSED BY TRAUMATIC INJURY	
Ni Luh Putu Sri Widani ¹ , Firmansyah ² dan Wignyo Hadriyanto ³	157

PH CHANGES OF ROOTS FOLLOWING ROOT CANAL DRESSING WITH HYDROGEL CHITOSAN, CONVENTIONAL CALCIUM HYDROXIDE AND A COMMERCIAL CALCIUM HYDROXIDE PASTE : LITERATURE REVIEW

Dwi Yani Sastika G* Trimurni Abidin **167

MULTIPLE DIASTEMA CLOSURE USING DIRECT VENEER RESTORATION COMBINED WITH EXTERNAL BLEACHING: A CASE REPORT

Edra Brahmantya Susilo*, Ira Widjiastuti**179

HEALING OF LARGE PERIAPICAL LESION WITH NON SURGICAL ENDODONTIC TREATMENT APPROACH: A CASE REPORT

Ellyda Nasution * Dennis ** Trimurni Abidin **185

REPLANTATION AND REPOSITION OF IATROGENIC AVULSION IMPACTED CANINE DUE TO NEGLIGENCE EXTRACTION: A CASE REPORT

Eltica Oktavia * Dennis ** Trimurni Abidin **193

APEXIFICATION USING MINERAL TRIOXIDE AGGREGATE AND COMPOSITE CROWN RESTORATION WITH FIBER REINFORCED CUSTOMIZED DOWEL CORE ON LEFT CENTRAL INCISOR MAXILLA

Erlita Hapsari*; Diatri Nari Ratih**203

DILACERATED ROOT CANAL TREATMENT USING HYFLEX CM ROTARY FILES

Erliyana¹, Endang Suprastiwi²207

MANAGEMENT OF C-SHAPE CANALS : TWO CASE REPORT

Gary Wijaya* Trimurni Abidin**213

MANAGEMENT OF ANTERIOR DENTAL TRAUMA (TWO YEARS AFTER TRAUMA) : A CASE REPORT

Hanny Aryani¹, Bernard O. Iskandar², Dina Ratnasari²219

ENDODONTIC TREATMENT OF MAXILLARY LATERAL INCISOR WITH SUSPECTED RADICULAR CYST AND EXTERNAL APICAL ROOT RESORPTION: A CASE REPORT	
Hasti Dwi Setiati ¹ , Endang Suprastiwi ²	223
MANAGEMENT OF NARROW CANAL ON MAXILLARY RIGHT LATERAL INCISIVUS (A CASE REPORT)	
Hendro Santoso Malimas ¹ , Tien Suwartini ² , Anastasia E. Prahasti ²	231
ENDODONTIC RETREATMENT OF MAXILLARY FIRST MOLAR WITH ADDITIONAL OF MB 2 ROOT CANAL A CASE REPORT	
Hernika Harperiana ¹ , Juanita A Gunawan ² , Anastasia EPrahasti ²	237
RETROGADE FILLING USING MINERAL TRIOXIDE AGGREGATE (MTA) AFTER APICOECTOMY IN ENDODONTIC FAILURE CASE WITH OVERFILLED OBTURATION, ACRYLIC CROWN, AND CUSTOM DOWEL POST-CORE	
Ida Fitri Setiyowati*, R. Tri Endra Untara**	243
THE SHRINKAGE DIFFERENCES OF ROOT CANAL TREATMENT USING BALANCED FORCE AND STEP BACK PREPARATION TECHNIQUE WITH THERMOPLASTICIZED FILLING TECHNIQUE (SCANNING ELECTRON MICROSCOPY)	
I Gusti Agung Ayu Hartini, Gede Bintang Anugrah	251
ANTIBACTERIAL EFFICACY OF CHITOSAN AS ROOT CANAL IRRIGANTS IN ENDODONTICS ON ENTEROCOCCUS FAECALIS (LITERATUR REVIEW)	
Imelda Darmawi * Trimurni Abidin**	259
EFFECT OF CURRENT LED LIGHT CURING ON POLYMERIZATION OF DIFFERENT PHOTOINITIATOR OF COMPOSITE RESIN : A LITERATURE REVIEW	
Juliana Siregar * Dennis** Rasinta Tarigan***	269
APICAL CURETAGE AND PREFABRICATED FIBER POST WITH RESTORATION OF CLASS IV COMPOSITE RESIN	
Kiki Maharani Fadhilah*, Pribadi Santosa**	281

ROOT CANAL TREATMENT OF SUBGINGIVAL CARIES ON DISTAL MANDIBULAR SECOND MOLAR DUE TO WISDOM TOOTH IMPACTION : A CASE REPORT	
Kissy Wicaksana ¹ , Bernard O. Iskandar ² , Aryadi Subrata ²	289
HEMISECTION OF MANDIBULAR FIRST MOLAR	
Leedwin Kalyana Alison*, Wignyo Hadriyanto**	295
INTRACORONAL BLEACHING FOLLOWED BY DIRECT COMPOSITE RESTORATION AS A MANAGEMENT OF DISCOLORED ANTERIOR TEETH : A CASE REPORT	
Lidya Octavia ¹ , Sri Subekti Winanto ² , Elline ²	301
ANTIBACTERIAL POTENTIAL OF N-ACETYLCYSTEINE AS AN ENDODONTIC IRRIGANT AGAINST <i>ENTEROCOCCUS FAECALIS</i> BIOFILM	
Ridzki Ridhalaksani ¹ , Kamizar ² , Nilakesuma Djauharie ²	307
BLEACHING TECHNIQUE FOR DISCOLORATION IN POST ENDODONTIC TREATMENT TOOTH : A CASE REPORT	
Makkunrai Eka Kramatawati Elizabeth ¹ , Karlina Samadi, drg., MS, SpKG(K) ²	325
THE USE OF PREFABRICATED FIBER POSTCOMBINEDWITH POLYETHYLENE RIBBON AS CUSTOMIZED POST IN WIDE ROOT CANAL FOLLOWING ENDODONTIC RETREATMENT A CASE REPORT	
Marsintha L.M.T*, Dennis**, TrimurniAbidin**	331
RESTORATION OF ENDODONTICALLY TREATED TEETH WITH SEVERE LOSS OF TOOTH STRUCTURE – CASE REPORT	
Mike Wijaya* Dennis**Trimurni Abidin **	339
TREATMENT OF DISCOLORATION ON THE MAXILLARY CENTRAL INCISORWITH WALKING BLEACH TECHNIQUE (A CASE REPORT)	
Muh.Yusri*, Rahmi Alma Farah **	345

ROOT CANAL TREATMENT OF LOWER RIGHT MOLAR IN CHRONIC TERMINAL RENAL FAILURE.	
Muhammad Zaal Haq ¹ , Anggraini Margono ²	355
RETRIEVAL OF SEPARATED INSTRUMENT FROM THE CURVED CANAL USING ULTRASONIC TIP INSTRUMENT : A CASE REPORT	
Natalia Iskandar Setiawan ¹ , Bernard O Iskandar ² , Aryadi Subrata ²	363
RETAINING EXTENSIVE CAVITY HYPERPLASTIC PULPITIS MANDIBULAR FIRST MOLAR WITH PULPECTOMY AND ENDOCROWN : A CASE REPORT	
Paulus Alexander ¹ , Eko Fibryanto ² , Taufiq Ariwibowo ²	371
COMPREHENSIVE TREATMENT OF MAXILLARY ANTERIOR TEETH : A CASE REPORT	
Priska Lasari ¹ , Tien Suwartini ² , Wiena Widyastuti ²	375
DISCOLORATION TREATMENT WITH IN OFFICE BLEACHING : A CASE REPORT	
Rike Kapriani	381
POTENCY OF CHITOSAN NANO GEL AS DESENSITIZING AGENTS	
Rina Oktavia* Trimurni Abidin**	389
CONVENTIONAL ENDODONTIC RETREATMENT OF MANDIBULAR FIRST MOLAR WITH UNDERFILLING	
Riza Permitasari*, Kamizar**	399
DIRECT VENEER COMPOSITE FOR DIASTEMA AND PEG SHAPED ON ANTERIOR MAXILLARY TEETH (CASE REPORT)	
Rozyta K Hakim ¹ , Juanita A Gunawan ² , Selviana Wulansari ²	409
ROOT CANAL RETREATMENT OF TRUE COMBINED LESION IN MANDIBULARY RIGHT CANINE	
Selviana Swastiningtyas ¹ , Anggraini Margono ²	415

ENDOCROWN AS A FINAL RESTORATION FOR ENDODONTICALLY TREATED TEETH WITH CHRONIC APICAL ABSCESS—A CASE REPORT Stephani Marthios ¹ , Sri Subekti Winanto ² , Elline ²	423
DIFFERENT FERRULE DESIGNS ON FRACTURE RESISTANCE IN MAXILLARY ANTERIOR TOOTH : LITERATURE REVIEW Tri Sari Dewi Purba * Dennis**Rasinta Tarigan**	429
ROOT CANAL RETREATMENT OF A RIGHT MAXILLARY LATERAL INCISOR TEETH CAUSED OF INADEQUATE ROOT CANAL TREATMENT Waviyatul Ahdi ¹ , Nilakesuma Djauhari ²	441
A COMPARATIVE EVALUATION OF FRACTURE RESISTANCE OF ENDODONTICALLY TREATED TEETH OBTURATED WITH AH PLUS AND GUTTAFLOW SEALERS USING DIFFERENT OBTURATION TECHNIQUES: LITERATURE REVIEW Yeamy Agustina Marpaung* Trimurni Abidin ** Indra N***	451
CASE REPORT: SURGICAL ENDODONTIC TREATMENT OF MAXILLARY CENTRAL INCISORS WITH LARGE PERIAPICAL LESION Ekhtiyanto Cahyadi KY. ¹ , Ira Widjiastuti ²	461
MANAGEMENT OF TRAUMATIZED TOOTH WITH OPEN APICAL AND DISCOLORATION: A CASE REPORT Farida Widhi Astuti ¹ , Edhie Arif Prasetyo ²	467
ROOT CANAL TREATMENT IN MAXILLARY SECOND PREMOLAR WITH CORONAL FLARING SHAPED OF THE TWO-THIRD ROOT CANAL Dwi Arniawaty*, Dewa Ayu Nyoman Putri Artiningsih**	475
APEXIFICATION WITH MINERAL TRIOXIDE AGGREGATE (MTA) AND INTERNAL BLEACHING ON RIGHT UPPER CENTRAL INCICIVUS TOOTH WITH DISCOLORATION Elisabeth Reni* dan Pribadi Santosa**	483

MESIAL ROOT HEMISECTION AND RESTORATION AS A TREATMENT OPTION OF MANDIBULAR FIRST MOLAR : A CASE REPORT	
Dinda Dewi Artini, drg ¹ , Prof. Dr. Ruslan Effendy, drg. MS., Sp.KG(K) ²	493
ROOT RESECTION OF MAXILLARY FIRST MOLAR: A CASE REPORT	
Dina Ristyawati ¹ , M. Mudjiono ²	501
THE POTENTIAL ROLE OF PROPOLIS ON DENTIN REGENERATION AND REPAIR DURING DIRECT PULP CAPPING TREATMENT	
Ardo Sabir ^{1,2*} , Juni Jekti Nugroho ²	509
AESTHETIC CORRECTION OF A MICRODONTIC TOOTH USING DIRECT COMPOSITE RESIN : A CASE REPORT	
Mulia Rahmah ¹ , Cecilia G Lunardhi ²	521
ESTHETIC REHABILITATION OF SEVERELY DISCOLORED ANTERIOR TOOTH WITH INTERNAL BLEACHING FOLLOWED BY DIRECT COMPOSITE LAMINATE VENEER	
Gustantyo Wahyu Wibowo ¹ and R. Tri Endra Untara ²	527
MTA APPLICATION ON APICAL PERFORATION WITH FIBER POST AND COMPOSITE RESIN RESTORATION.	
Ivan Salomo ¹ , Ira widjiastuti ²	541
AESTHETIC ENHANCEMENT WITH A COMBINATION OF EXTRACORONAL BLEACHING AND VENEER PROCEDURE	
Ketut Sri Widyawati*, Ema Mulyawati**	547
SUCCESSFUL USE OF BIODENTIN FOR A VITAL PULP THERAPY ON A LOWER MOLAR DEEP CAVITY	
Mochammad Kennedy* Trimurni Abidin**	555
TREATMENT OF ENDO PERIO LESION WITH .TRAUMATIC OCCLUSION ON RIGHT LATERAL INSICIVUS MAXILLARY	
Norma Avanti ¹ , Nila Kesuma Djauharie, drg, MPH, SpKG(K) ²	561

ENDODONTIC RETREATMENT OF MAXILLARY SECOND PREMOLAR WITH ROOT CANAL CONFIGURATION VERTUCCI CLASS II	
Mettasari Puspa Wardoyo ¹ , Dewa Ayu Nyoman Putri Artiningsih ²	569
ROOT CANAL TREATMENT OF UPPER FIRST MOLAR WITH TWO-THIRD APICAL OBLITERATION	
Celine Marissa ¹ , Munyati Usman ²	579
MANAGEMENT ON APICAL THIRD FRACTURE OF CENTRAL INCISOR : A CASE REPORT	
Putu Ferbika ¹ , Latief Mooduto ²	587
SMILE MAKEOVER IN THE PATIENT WITH MULTIPLE CARIES, FRACTURE AND LABIOVERSION	
Ratih Elisa Nandarani ¹ , Kun Ismiyatin ²	593
ROOT CANAL TREATMENT IN FIRST LOWER LEFT MOLAR WITH MIDDLE MESIAL AND RADIX ENTOMOLARIS : CASE REPORT	
Raymond Kandou*, Nirawati Pribadi**	599
ROOT CANAL TREATMENT WITH COMPOSITE RESIN RESTORATION AND POLYETHYLENE FIBER AS REINFORCEMENT IN MANDIBULAR RIGHT SECOND MOLAR TOOTH WITH A SINGLE ROOT CANAL	
Reni Nofika*, Tunjung Nugraheni**	607
THE CONSERVATIVE MANAGEMENT OF EXTERNAL ROOT RESORPTION OF PERMANENT INCISIVE CENTRAL CAUSED BY A TRAUMA : A CASE REPORT	
Ruth Sarah Wibisono ¹ , Tamara Yuanita ²	617
ROOT CANAL RETREATMENT OF PERIAPICAL ABSCESS ON MAXILLARY LATERAL INCISOR	
Sasi Suci Ramadhani ¹ , Ratna Meidyawati ²	623
APEXIFICATION AND ESTHETIC MANAGEMENT OF DISCOLORED AND FRACTURED NECROTIC TOOTH WITH IMMATURE ROOT: A CASE REPORT	
Sinta Puspitadewi ¹ , Adioro Soetojo ²	629

RESTORATION DIRECT COMPOSITE CLASS I WITH TECHNICAL STAMP : A CASE REPORT	
Ricky Yudatmoko ¹ , Laksmiari Setyowati ²	639
AESTHETIC TREATMENT ON NON VITAL TRAUMATIC ANTERIOR TEETH BY INTRACORONAL BLEACHING	
Sumitro TH ¹ , Nanik Zubaidah ²	645
MANAGEMENT OF FRACTURED INSTRUMENTS BY FILE BYPASS TECHNIQUE IN ROOT CANAL MANDIBULAR MOLAR	
Meita Herisa ¹ , Ratna Meidyawati ²	651
BICUSPIDIZATION : TREATMENT FURCAL PERFORATION IN MANDIBULAR MOLAR	
Tri Estiyaningsih ¹ , M.Rulianto ²	659
THE ANTIBACTERIAL EFFECT OF A DIODE LASER ON <i>ENTEROCOCCUS FAECALIS</i> BIOFILM	
Ayu Sandini, Ratna Meidyawati	667
CASE REPORT	
MANAGEMENT OF CRACK TOOTH SYNDROME ON VITAL TOOTH MAXILLARY LEFT FIRST MOLAR	
Laili Aznur*, Irmaleny**	679

CASE REPORT

C-SHAPED ROOT CANAL TREATMENT IN MANDIBULAR MOLAR (CASE REPORT)

Adelia Mutia Indah, Juanita AG, Selviana Wulansari

Department of Conservative Dentistry Faculty of Dentistry Trisakti University

ABSTRACT

Background : The C-shaped root canal configuration is mostly seen in mandibular molar followed by other mandibular molars and maxillary molars respectively. A conical or square configuration is characteristic of roots having a c-shaped canal. The etiology for occurrence of c-shaped canal is failure of Hertwig's epithelial root sheath to fuse on buccal or lingual root surface. **Objective :** The aim of this case report was to present the success of c-shaped root canal treatment of mandibular second molar. **Case :** A 23-year-old female patient came to Department of Conservative Dentistry Faculty of Dentistry Trisakti University. She felt that her tooth has a big cavity since a long time. Objective assessment showed a cavity extend to the pulp involving occlusal and distal area. Radiographic examination showed cavity extended to the pulp with apical lesion and periodontal ligament widening on his left mandibular second molar. **Conclusion :** C-shaped root canal treatment of mandibular second molar proven to be successful.

Keywords : c-shaped canal, root canal configuration, mandibular second molar

INTRODUCTION

The C-shaped configuration of root canal is one of the most important anatomical variations of the canal. It was first documented by Cooke and Cox in 1979.¹ The prevalence of C-shaped root canal reported to ranges from 2.7% to 44.5% in mandibular second molars. Failure of Hertwig's epithelial root sheath to fuse on to the buccal or lingual root surface may be the main cause of this configuration. This

type canal configuration consists a single ribbon shaped orifice instead of several discrete orifices and the orifice looks like 180° arc starts from mesio lingual line angle to and sweeps around the buccal to the end at the distal aspect of the pulp chamber. Two main basic form of C-shaped canal are single ribbon shaped canal from orifice to apex and multiple canals may present below the C-shaped orifice.²

The first classification of the C-shaped root canals was done by Melton and co-authors in 1991. Later based on it, Fan made an anatomic classification:³

1. Category I (C1) - continuous C-shaped root canal from the orifice to the apex of the root
2. Category II (C2) -one main root canal and a smaller one
3. Category III (C3) – two or three root canals
4. Category IV (C4) - an oval or a round canal
5. Category V (C5) - no canal lumen or there is one close to the apex.

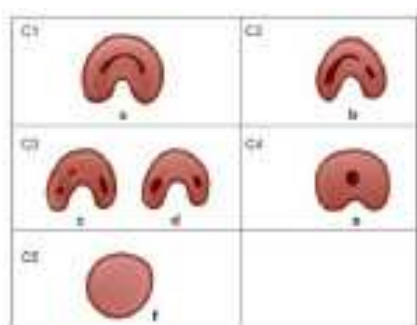


Figure 1. classification of the C-shaped root canals was done by Melton and co-authors in 1991

Fan suggests that 3 types of teeth with C-shaped configuration of the pulp chamber are included in the radiological classification:^{3,4}

1. Type I. Conical or square root with visible separation of medial and distal part. Medial and distal canal merge near the apical foramen in a single one

2. Type II. Conical or square root with visible separation of medial and distal part. Medial and distal canal have separate apical foramen but run approximately in parallel and are almost equal in length
3. Type III. Conical or square root with visible separation of medial and distal part. Medial and distal canal have separate apical foramen, run approximately in parallel but one of them is longer than the other.

OBJECTIVES

To describe root canal treatment management of C-Shape canal configuration.

CASE REPORT

A 23-year-old female patient has visited to Department of Conservative Dentistry Trisakti University, with the chief complaint of the leftback tooth which has been the large cavity. There was no pain history, it's just discomfort on eating due to often tucked food. Clinical examination revealed that the tooth #37 had deep caries that had reached the pulp from distal part (Figure 2-A). The tooth gave negative response to thermal test (cold) and was not tender to percussion and palpation. Radiographically the tooth was conical in shape with fused mesial and distal root with a thin radiolucent line between them, with a suspected of C-shaped canal. A diagnosis of Pulp Necrosis with exacerbated chronic

periapical periodontitis(Figure 2-B)
The patient's medical history was non-contributory.

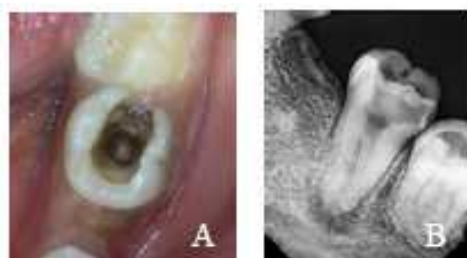


Figure 2. (A)Pre operative. Occlusal viewing, tooth #37 had deep caries in the occlusal part extends distally. (B)Tooth #37 was conical in shape with fused mesial and distal root with a thin radiolucent line between them also have the radiolucency in the periapikal.

The treatment begins with the placement of rubber dam and prepare access cavity (Figure 3). A single semicircle shape orifice was found with two canal, conical in shape with fused mesial and distal root and it was possible to insert a size #10 and #15 K-file for explore the canal, working length was determined with electronic apex locator (Root ZX, J. Morita MFG. Corporation, Kyoto, Japan) then confirmed radiographically (Figure 4) The gained working length of the tooth #37 is 21mm for mesial and distal canal.Preparation begins with a glide path preparation using a Proglider #16/02 (Dentsply, Maillefer, Ballaigues, Switzerland). These canal were completely instrumented, Cleaning and shaping with hand K files and ProTaper rotary files (Dentsply Maillefer, Ballaigues, Switzerland) up to X2 (25/06), The anti-

curvature filing method was performed to avoid the strip perforation.5,25% Sodium hypochlorite and saline were used as irrigants in between instrumentation. Final irrigation was 5,25% Sodium hypochlorite, 17% EDTA and 2% Chlorhexidine and saline in each sequence. Each irrigation solution was activated using sonic technique by the Eddy (EDDY polyamide tip, VDW) into the root canal up to 1 mm shorter than the working length for 1 minute. Fitting master cone was done and the radiography was taken (Figure 5).Obturation was done with combaine of gutta-percha cone Protaper Next X3 (Dentsply, Maillefer, Ballaigues, Switzerland) and injectable thermoplasticized gutta percha (SybronEndo)also root canal sealer (Saelapex, SybronEndo) using vertical compaction technique (Figure 6). Composite endocrown was made as final restorationwas given after 2 week. The patient was recalled after a week and 3 months for evaluation of treatment. The tooth was functioning normal, patient was free of pain and there were radiographic began to improve (Figure 7).

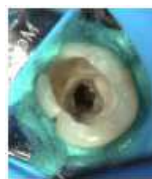

Figure 3.
Access
preparation

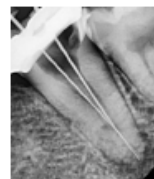

Figure 4.
Working
length

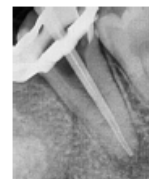

Figure 5.
Fitting of
Master cone

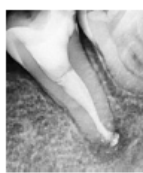

Figure 6.
Obturation

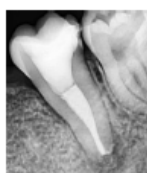

Figure 7.
Three month
follow-up

DISCUSSION

These Case represents type I C-shaped canal according to Fan et al.⁴ radiographic classification of C-shaped canal. There was a mesial and a distal canal that merged into one before exiting at the apical foramen. This type of tooth usually possess conical or square root with a vague, radiolucent longitudinal line separating the root into distal and mesial parts.

C-shaped canal poses diagnostic difficulty radiographically because of the two-dimensional view of the radiograph. The presence of thin fin, slit and web create difficulty in the canal shaping, through debridement and obturation. It is uncertain whether a C-shaped orifice found on the floor of the pulp chamber may continue to the apical third of the root. Irregular areas in a C-shaped canal that may house soft-tissue remnants or infected debris may escape thorough cleaning or filling and may be a source of bleeding and severe pain. Sometimes deep penetration is needed to get a proper access to canal. During cleaning and shaping, normal preparation can be done in mesial and distal canals. Nevertheless the isthmus should not be prepared with larger than number 25 files;

otherwise, strip perforation is likely.²

The anti-curvature filing method will be useful in these circumstances. To get a maximum disinfection in the inaccessible areas, use of ultrasonics will be more effective. Irrigation is an crucial part of root canal disinfection because it attains cleaning beyond what might be achieved by root canal instrumentation alone. Due to the presence of canal irregularities, it is important to select the proper obturation system. Many authors recommended themoplasticised systems as it completely fill the canal irregularities. Furthermore, proper placement of sealers also plays a critical role in obturation.^{1,2}

In C-shaped canals because during mechanical debridement some parts of canal remain untouched. All the cases reviewed after 1-week and 3 months to evaluate the RCT by intra oral examination. The patients were free of pain and there were radiographic began to improve.

CONCLUSION

The proper diagnosis plays a key role for the management of C - shaped canals. Depending upon the morphology the management mode can be selected. Due to the unusual anatomy of teeth with C-shaped root canal system, The successful endodontic management needs proper knowledge about aberrant root canal systems. Appropriate mode can be selected depending upon this morphology. The considerable care should be taken during biomechanical preparation and obturation

of C-shaped canals for good long term prognosis. followed by three dimensional sealing of aberrant space, it's necessary to know and learn appropriate techniques of irrigation and filling with suitable techniques. C-shaped root canal treatment of mandibular second molar proven to be successful.

REFERENCES

1. Dilek Helvacioglu-Yigit. Endodontic Management of C-shaped Root Canal System of Mandibular First Molar by using a modified Technique of Self-adjusting File System. *The Journal of Contemporary Dental Practice*, January 2015;16(1):77-80
2. Deenadayalan Elumalai et all. Management of C-shaped root canal configuration with three different obturation systems. *European journal of general dentistry*. Year : 2015. Volume : 4; Issue : 1; Page : 25-28.
3. Janet Kirilova, Snezhanka Topalova-Pirinska. C-Shaped Configuration Of The Root Canal System – Problems And Solutions. *Journal of IMAB - Annual Proceeding (Scientific Papers)* 2014, vol. 20, issue 1
4. Malik Sartaj, Ankushsangra, Riyaz Farooq, Aamir Rashid and Fayaz Ahmad. C-Shaped configuration of the root canal system of mandibular second molar: A case report. *International Journal of Applied Dental Sciences* 2017; 3(1): 98-100

HEMISECTION OF MANDIBULAR FIRST MOLAR WITH PERFORATED FURCATION

Adeline Jovita Tambayong*, Prof. Dr. Mandojo Rukmo, drg., M.Sc., Sp KG (K)**

*Resident, Departement of Conservative Dentistry

** Staff Departement of Conservative Dentistry

Faculty of Dental Medicine, Airlangga University
Surabaya, Indonesia

Introduction

Loss of the posterior teeth is eventful and undesirable often leading to teeth drifting, loss of masticatory function and loss of arch length, which requires prevention and maintenance measures. Nevertheless, treatment strategy to retain such teeth involves periodontal, prosthodontic and endodontic assessment for appropriate selection to allow for stronger survival. Hemisection is a conservative way of preserving tooth.¹ Hemisection refers to surgical separation of a multi-rooted tooth with the extraction of one root along with the crown, especially a mandibular molars.² The treatment goal is the preservation of remaining tooth structure and restoration of the function.³ It is an option to be considered before the extraction of molars specially in the presence of conditions such as severe vertical bone loss (one root of a multi-rooted tooth), furcation destruction, unfavorable proximity of roots of adjacent teeth, preventing adequate hygiene in maintenance of proximal areas and severe root exposure due to dehiscence.¹ Contraindications include the presence of

a strong abutment tooth adjacent to the proposed hemisection, which could act as an abutment to a prosthesis, the remaining root may be inoperable for root canal treatment, fusion or proximity of the roots may prevent their separation.¹

The prognosis of root resection has been documented. Some reported that hemisection on the molar teeth had more than 90% survival rate, whereas others reported that 30% of resected molars failed over a 10-year period. That is the reason that it should be considered when deciding which root should be retained: the amount of supporting tissue around the roots, anatomy of the root in relation to the endodontic treatment, the periapical condition, and the mobility of the root.⁴

Endodontic therapy must be performed before the separation then the furcation region is carefully smoothed, to allow proper cleansing and thus to prevent accumulation of plaque.⁵ Hemisection need a proper restoration to cover and stabilizing the remain tooth with adjacent teeth. Lateral forces can lead to increase stresses if the inclined planes of the cusps

are not reduced in the final restoration and thus preventing the mobility of the retained segment.⁶ So this is a kind of conservative procedure which preserves tooth structure as much as possible and retains at least a part the tooth rather than extraction of the whole tooth.²

Case Report

A 25-years-old man was referred to the Conservative Dentistry of Airlangga University with pain and grossly decayed of tooth on the lower right side of the mouth. The tooth were decay since 1 years ago then he went to the dentist but the treatment is not done yet. Three days ago he felt pain again then he came to the clinic to continue the treatment.

On intraoral examination revealed deep caries with no mobility on the right mandibular first molar (Figure 1). Not responding to vitality test. On radiographic examination revealed severe periapical bone loss was evident on mesial root involving the furcation area with radiopaque gutta-percha just in the mesial root canals (Figure 2). The patient was reluctant to lose the tooth and prefer to have hemisection.

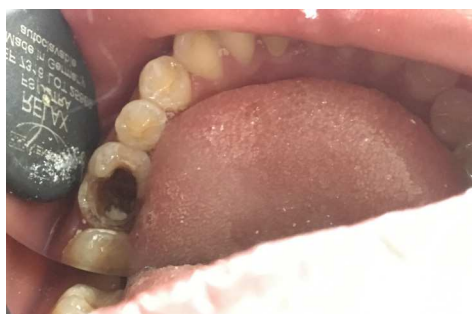

Figure 1. Preoperative Clinical View

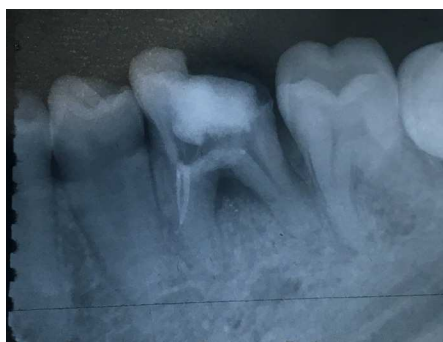

Figure 2. Radiographic preoperative

Case Management

After detailed clinical and radiographic examination, the patient was informed about the procedure. The tooth was isolated with a rubber dam and the access cavity was prepared. The canals were initially instrumented with K-file 8, 10, 15 (C-pilot, VDW) (Figure 3) and then the working length (18 mm) was determined with apexlocator (Root ZX II, J. Morita) and confirmed radiographically (Figure 4). Biomechanical preparation was performed using crown down technique with rotary Protaper Next files (Dentsply, Maillefer USA) and the canal was enlarged upto X3 (Figure 5). During cleaning and shaping procedure, root canals were irrigated with a combination of 2,5% sodium hypochlorite and normal saline then, the preparation was checked by gutta-percha. Root canals were dried and filled with calcium hydroxide (Metapaste, Meta biomed) as an intracanal medicament.

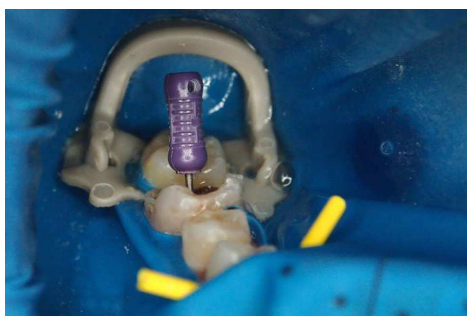


Figure 3. Glide path using K-file no 10

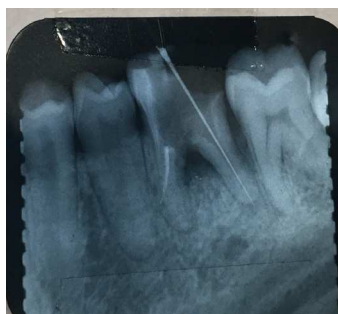

Figure 4. Radiographic of Working length confirmation

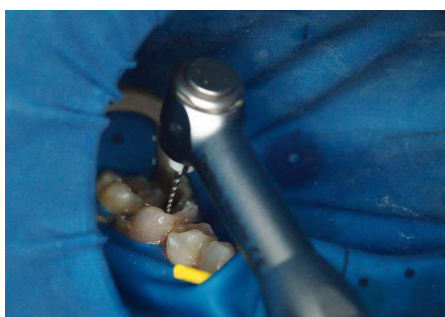


Figure 5. Preparation using rotary instruments

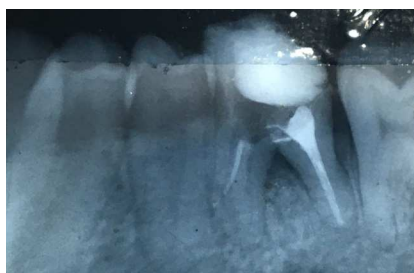

Figure 6. Radiographic of obturation

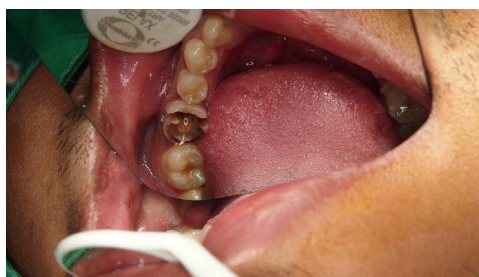

Figure 7. Mesial and distal canals separation

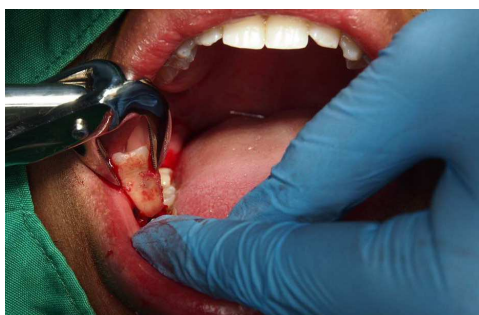

Figure 8. Extraction of mesial root canals

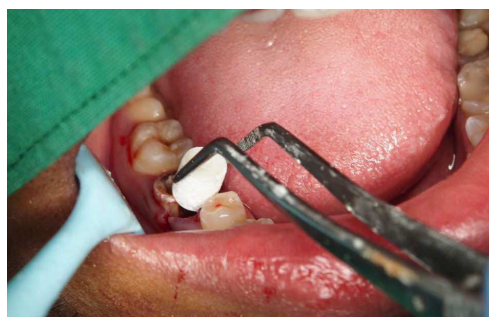

Figure 9. Insertion of bone graft into the socket.

In the second visit, patient was asymptomatic. Irrigation performed to remove the calcium hydroxide from root canal. Final irrigation was done with 2.5% sodium hypochlorite followed normal saline irrigation, EDTA 17% followed normal saline irrigation, and chlorhexidine 2%. The canals were dried with paper points. Obturation were done with gutta percha and sealer (Top Seal, Dentsply,

Maillefer USA) then confirmed by a digital radiograph. (Figure 6)

The patient was recalled after one week for hemisection of the tooth. The procedure was initiated by anaesthetizing the inferior alveolar nerve and the lingual nerve with 2 ml pehacaine. A long fissure bur was used to separate the mesial and distal canals (Figure 7) and then the mesial canals was extracted out of the socket with extraction forceps (Figure 8). The socket was irrigated with sterile saline to remove debris. The remaining portion of the distal tooth was trimmed to remove any sharp edge. Bone graft (Gamacha, Kimia Farma, Indonesia) was inserted in the socket (Figure 9) then the gingiva was sutured using 3.0 nylon thread. Splinting was done of second premolar, first molar and second molar with fiber and composite resin. Afterwards, periodontal pack was given to protect the lesion.

The sutures were removed after an observational period of one week. Then the gutta-percha was removed from the two-third root canal and fiber post was cemented using Rely X Self Adhesive Universal Resin Cement (3M ESPE, Germany) followed by core build up with composite resin (Tetric N-Ceram Bulk Fill, Ivoclar Vivadent) (Figure 10).

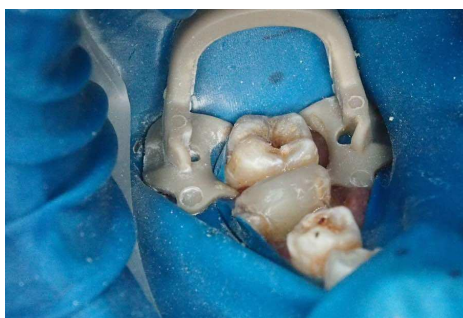

Figure 10. Core build up

Tooth preparation for porcelain fused to metal was done and chamfer finish line was placed all around the margin (Figure 11). A polyvinyl siloxane impression was made for the prepared teeth followed by alginate impression for the antagonist. The shade was determined with a shade guide (Vita classic) then temporary crown was cemented using temporary cement (Fregenol, GC America)(Figure 12).

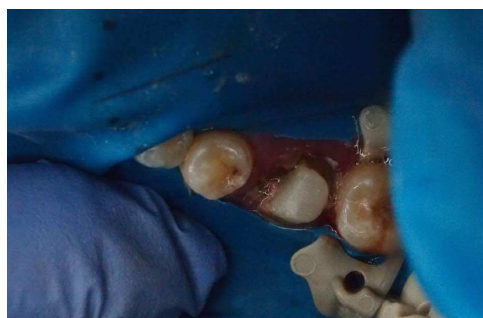

Figure 11. Preparation of crown

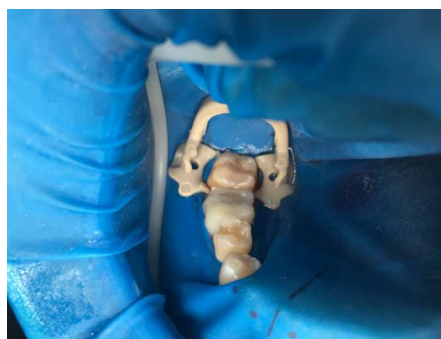

Figure 12. Temporary Crown

The cast was sent to the laboratory. A fixed prosthesis of porcelain fused to metal crown with a sanitary pontic area on the mesial root and an occlusal rest was made and cemented with glass ionomer luting cements (Figure 13).

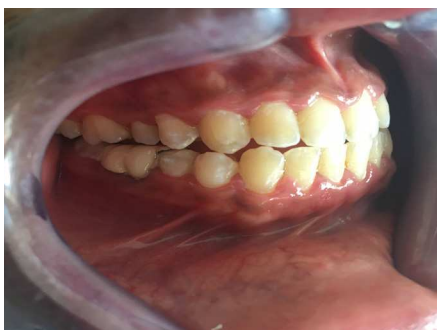

Figure 13. Insertion of Crown

The patient returned after 3 months (Figure 14) with no pain and no mobility. Radiograph examination show no periapical lesion and bone formation at the extraction socket (Figure 15).

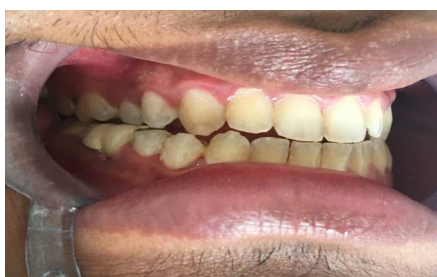

Figure 14. three months after insertion

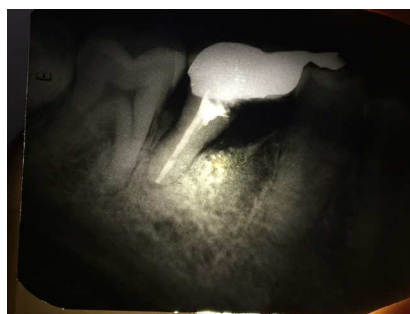

Figure 15. Radiographic three months after insertion

Discussion

Hemisection is a surgical separation of a multi-rooted tooth with the extraction of one root along with the crown.² It is an alternative treatment to extraction to save the multi-rooted teeth by endodontic approach and restoring them with suitable restorative material to splinting it with the remaining tooth to decrease the risk of displacement teeth. This treatment is a suitable option when the damage is restricted to one root and the other root is healthy and remaining portion of tooth can very well act as an abutment. Indication of hemisection such as severe vertical bone loss (one root of a multi-rooted tooth), furcation destruction, unfavorable proximity of roots of adjacent teeth, preventing adequate hygiene in maintenance of proximal areas and severe root exposure due to dehiscence.¹ It provides a good, absolute and biological cost saving alternative with good long term success.

In this case, the endodontic was done only on the distal root and extraction was done on the mesial root. The extraction

was done because of the severe vertical bone loss of the mesial root with furcation destruction whereas the distal root can still be maintained.

The prognosis is comparable to any other tooth with endodontic treatment which is depends on the supporting bone, the restorative treatment plan, and the oral hygiene of the patient. In the present case, good prognosis was observed with proper occlusion, absence of mobility, and healthy periodontal condition.

Conclusion

Hemisection is an alternative, effective, and conservative treatment modality over the extraction

References

1. Babaji P, Sihag T, Chaurasia VR, and Senthilnathan S. Hemisection: A Conservative management of periodontally involved molar tooth in a young patient. J of Natural Sci, Bio, and Med. 2015; 6 (1): 253-255.
2. Shah S, Modi B, Desai K, and Duseja S. Hemisection – A conservative approach for a periodontally compromised tooth - A Case Report. J Adv Oral Res. 2012; 3 (2): 31-36.
3. Mishra P, Sharma A, Mishra SK. Hemisection: A conservative approach of tooth preservation. J Curr Res Sci Med. 2016;2:46-8.
4. Nirmal H, Chaturvedi S, Chaturvedi M, and Deshpande T. Hemisection as an Alternative Treatment for Decayed Multirooted Abutment: A Case Report. IOSR J of Dent and Med Sci. 2013; 7 (4): 32-36.
5. Saad MN, Moreno J, and Crawford C. Hemisection as an Alternative Treatment for Decayed Multirooted Terminal Abutment: A Case Report. JCDA. 2009; 7(5): 387-90.
6. Quader SMA, Alam MS, Khan MOG, and Moral AA. Hemisection Of A Mandibular Molar. Update Dent Coll J. 2011: 1(1): 18-22.

DIRECT COMPOSITE RESIN RESTORATION REINFORCED WITH SHORT FIBER POST ENDODONTIC TREATMENT ON NECROSIS MOLAR MANDIBULAR: A CASE REPORT

Amarendra Anindita*, R. Tri Endro Untara**

*Resident of Conservative Dentistry, Faculty of Dentistry,
Universitas Gadjah Mada Yogyakarta

**Staff Department of Conservative Dentistry, Faculty of Dentistry,
Universitas Gadjah Mada, Yogyakarta

*Jl. Denta No.1 Sekip Utara, Yogyakarta. E-mail: dita.amarendra@gmail.com

ABSTRACT

Background: Short-fiber reinforced composite was introduced as a dental restorative composite resin to be used in high stress-bearing areas, especially in molars.

Aim: The purpose of this study was to report a case management of necrosis molar mandibular with direct resin composite restoration reinforced short fiber of endodontic treated teeth

Case: The 38-year female patient went to Dental Hospital Faculty of Dentistry Gadjah Mada University with the chief complaint on the left mandibular first molar in amalgam was uncomfortable while chewing around 3 months ago. The patient was willing to retain the tooth. In a clinical examination of the left mandibular first molar was tender on percussion, electronic pulpal testing was negative, mobility was grade 2 with amalgam onlay fixed on it.

Treatment: Root canal treatment was performed of the left mandibular first molar continued by insertion of the short-fiber reinforced composite and restored with direct resin composite.

Conclusion: Direct composite resin restoration reinforced with short fiber on necrosis molar mandibular and may be suitable alternative intracoronal strengthening to be used in high stress-bearing areas.

Keywords: root canal treatment, short fiber reinforced composite

INTRODUCTION

Short fiber reinforced composite resin was introduced as a dental restorative composite resin. The composite resin is intended to be used in high stress-bearing areas especially in molars¹. The reconstruction of structurally compromised posterior teeth is a rather challenging procedure. The rehabilitation of a heavily

damaged endodontic treated molar poses a challenge to clinicians. The successful restoration of endodontic treated teeth requires an effective coronal seal, protection of the remaining tooth, restore function, and acceptable aesthetics². The use of custom-made or prefabricated posts has gained popularity and is now frequently employed for the reconstruction

of endodontic treated teeth. However, one mode of failure of post-restored teeth is root fracture, which underscores the need for a minimally invasive procedure³.

The biomechanics of endodontic treated teeth are primarily altered by tissue loss due to endodontic treatment (access cavity, cleaning, and shaping), thereby increasing the fragility of an endodontic treated teeth and thus the risk that it may be fractured⁴. Therefore, the intracoronal strengthening of teeth to protect them against fracture is important, particularly in posterior teeth where the stresses generated by forces of occlusion can lead to the fracture of unprotected cusps. More importantly, the amount of remaining tooth structure following endodontic therapy is an important factor in the evaluation of a tooth's prognosis regarding restorative and/or prosthetic procedures⁵. Restorations combining a base of short fiber reinforced composite resin as substructure and surface layer of conventional composite resin displayed promising performance in high load bearing areas. This case reported a case management necrosis molar mandibular with direct resin composite restoration reinforced short fiber of endodontic treated teeth.

CASE REPORT

The 38-year female patient went to Dental Hospital Faculty of Dentistry Gadjah Mada University with the chief complaint on the left mandibular first molar in amalgam was uncomfortable

while chewing around 3 months ago. In clinical examination mandibular first molar was tender on percussion, electronic pulpal testing was negative, mobility was grade two with amalgam onlay fixed on it (Figure 1a). The probing depths of this tooth was in normal limits. Radiographic examination (Figure 1b) showed a periapical lesion at the mesial and distal apex of the tooth. The patient's medical history was noncontributory. A clinical diagnosis of pulpal necrosis with periapical periodontitis left mandibular first molar was made.

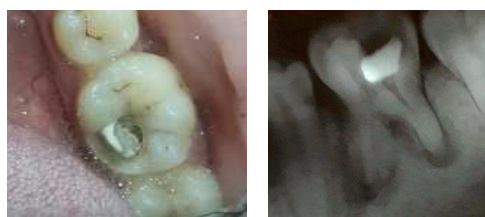

Figure 1. (a) Clinical view of the left mandibular first molar before treatment, (b). **Preoperative radiograph revealing a periapical radiolucent lesion in the region of the mesial and distal root of the left mandibular first molar before treatment.**

CASE MANAGEMENT

The patient was given detailed information regarding the treatment procedure. The first visit was done with anamnesis, clinical examination, radiographic examination, treatment plan, and informed consent. The artificial wall was made with resin composite using universal matrix band. The tooth then isolated with rubber-dam. Root canal treatment was performed by crown-down

technique. The mesiobuccal, mesiolingual, and distobuccal canal was prepared using Protaper Rotary instrument (Dentsply, Maillefer). Started with initial exploration using k-file #8, #10 and #15 along the 2/3 of the temporary working length, measure working length with k-file #15 with apex locator (Propex II, Dentsply) and confirmed with radiograph the working length of each of three canals : mesiobuccal (18mm), mesiolingual (18 mm), distal (19mm) (Figure 2).

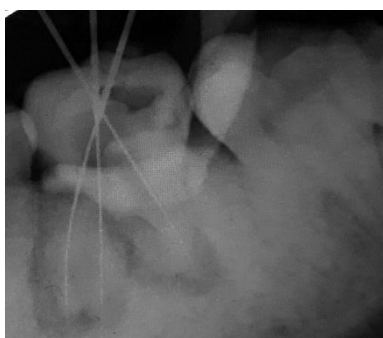


Figure 2. Working length determination radiograph

The apical third of each three canals were cleaned and shaped until ProTaper rotary file F3 (0.30mm in diameter, 0.09 taper). All canal was irrigated with 2,5% sodium hypochlorite and rinsed with aquadest after each file. Canals were dried with sterile paper points, filled with calcium hydroxide paste as an intracanal medicament and temporized with a temporary filling.

The dressing process until two weeks and the teeth are reported asymptomatic. Calcium hydroxide (Ultracal, Ultradent) was removed from the canal with NaOCl irrigation, then the root canals were

obtured with the single cone technique. Master cone gutta-percha was fitted into the prepared canal. With the gutta-percha cone fitted in the canal, a radiograph was taken to confirm fit (Figure 3a). Before obturation procedure, the tooth was irrigated with 2,5% sodium hypochlorite 2mL, rinsed with aquadest, followed by 17% EDTA solution 1mL (SmearClear, Kerr), rinse again with aquadest and 2% chlorhexidine 1 mL used as the last irrigant. The root canals dried with sterile paper points. F3 gutta-percha inserted along the correct working length with TopSeal (Dentsply) as the sealer, then its cut with heat carrier device on the orifice. Radiography examination was performed and revealed hermetic obturation (Figure 3b).

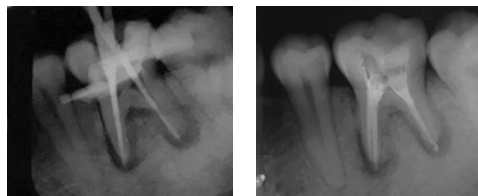


Figure 3.(a) Master cone length radiograph (b). Radiograph showing obturation of tooth 36

Selective etch was performed 15 seconds on the dentin and 30 seconds on the enamel with 37% phosphoric acid etch (3M ESPE) then rinse and air dry leaving moist dentin condition. Dentin bonding (Prime Bond, Dentsply) was applicated to the labial surface with microbrush and activated with light (Light cure) for 20 seconds (Figure 4a). Access cavity was sealed with SDR (Dentsply) (Figure 4b)

and short fiber composite (EverX, GC) inserted for dentin replacement (Figure 4c) and activated with light (Light cure) for 20 seconds.

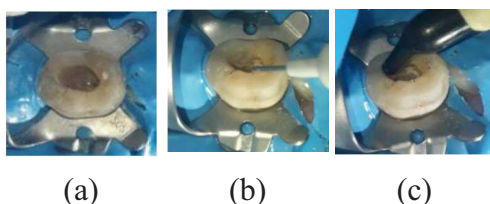


Figure 4. (a). Tooth 36 after etching and bonding step, (b). Access cavity was sealed with SDR (Dentsply), (c). Short fiber composite inserted as a base.

Tooth 36 was restored with direct composite restoration (Figure 5). Anatomical tooth surface was done with composite single shade (3M ESPE) using the cups to cups technique. Polymerization composite restoration with light (Light cure) for 20 seconds. Finishing and polishing were completed with enhance polishing system and rubber polishing point with aluminosilicate/composite polishing paste. The interproximal area was stripping with diamondstrip. Occlusion and articulation were checked with articulating paper. Radiography examination was performed and revealed coronal seal (Figure 5b).

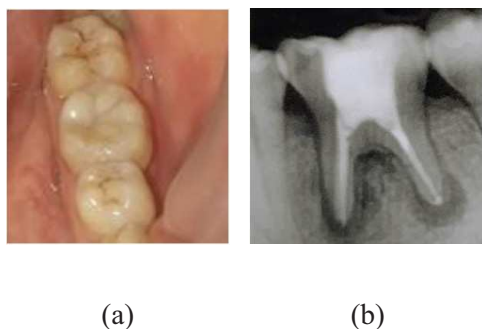


Figure 5. (a). The final restoration, (b). Radiograph showing coronal seal of tooth 36

DISCUSSION

On this case, the necrotic left mandibular first molar restores amalgam without root canal treatment before. A necrotic pulp may trigger the formation of a periapical lesion in the periodontal tissue. Periapical periodontitis chronic lesion caused by bacteria. Bacteria in the root canal may be eliminated through a series of root canal procedures, such as mechanical instrumentation, antiseptic irrigation, and intracanal medication. When bacteria is effectively removed from the root canal, then the healing response and tissue regeneration may occur. Activation of healing response/tissue regeneration causes the inflammatory area around the periapical to heal ⁶.

The selection of final restoration for endodontic treated teeth should consider the amount of the remaining coronal tissue after root canal treatment, esthetic needs, the restorative prognosis, the periodontal prognosis⁷. The selection of final restoration, in this case, is direct composite resin restoration reinforced with short fiber. SDR flowable composite resin used to sealing access cavity and resurfacing of the short fiber composite. The function of bulk short fiber composite substructure is based on supporting the surface particulate filler composite layer and working as crack stopper layer⁸. Reinforcing effect of the fiber fillers is based on stress transfer from polymer matrix to fibers but also the behavior of individual fiber as a crack stopper². In this case, Ever X posterior

which contain short Glass-fibre reinforced have less stiff fibers than carbon fiber posts. They are therefore more flexible than both metal and carbon-fiber posts and this has been both cited as an advantage in some reports and a disadvantage in others⁹.

EverX posterior it consists of a combining of a resin matrix, randomly orientated millimeter scale E-glass fibers (0,3-11,9mm) and inorganic particulate fillers¹⁰. The composite with the high inorganic load choice for the class I preparation which requiring high mechanical performance of restoration. Bulk technique its done to reduce stress at the cavosurface margin and recommended with packable composites. The short random fibers, on the other hand, provide reinforcing effect when placed in bulk, which means that the strength of the material is independent of the fracture load direction ⁷.

CONCLUSION

Direct composite resin restoration reinforced with short fiber on necrosis molar mandibular and may be suitable alternative intracoronar strengthening to be used in high stress-bearing areas.

REFERENCES

1. Garoushi S, Vallittu PK, Watts DC, Lassila LV, 2008, Polymerization shrinkage of experimental short glass fiber-reinforced composite with semi-inter penetrating polymer network matrix, *Dent Mate, Feb*; 24(2):211-5.
2. Garoushi, S., Vallittu, P.K., Lassila, L.V., 2011, Fracture toughness, compressive strength and load-bearing capacity of short glass fibre-reinforced composite resin. *Chin J Dent Res. 2011; 14(1):15-9*.
3. Soares, R., Ida, Fernandes, Marina dan Lambor, R., 2016, Fibre reinforcement in a structurally compromised endodontically treated molar: a case report, *Restor Dent Endod, May*;41(2):143-147.
4. Rocca, G.T., Rizcalla, N., Krejci, I.,2013, Fibre-reinforced resin coating for endocrown preparations: a technical report. *Oper Dent, 38*:242–248.
5. Ama da Vieg, 2016, Longevity of direct and indirect resin composite restorations in permanent posterior teeth: A systematic review and meta-analysis. [*Journal of Dentistry. Volume 54 November 2016, Pages 1-12*](#).
6. Hargreaves, K.M., Cohen, S., 2011, *Cohen's, Pathway of the Pulp*. 10th ed. St.Louis: Mosby.
7. McComb, D., 2008, *Restoration of the Endodontically Treated Tooth*, PEAK, Toronto
8. Garg, N. dan Garg, A., 2014, *Textbook of Operative Dentistry*, 3rd ed, Jaypee, New Delhi.
9. Goldberg, A.J., Burstone, C.J., The use of continuous fiber reinforcement. *Dental Mater 1992;8(3):197-202*.

10. Vallittu, P., Özca, M., 2017, *Clinical Guide to Principles of Fiber-Reinforced Composites in Dentistry*, A volume in Woodhead Publishing Series in Biomaterials, Elsevier Ltd.

CASE REPORT

THE ROLE OF GLASS IONOMER CEMENT PLACEMENT AS A BARRIER IN INTERNAL BLEACHING POST ENDODONTICALLY TREATED MAXILLARY ANTERIOR

Amellia Tjandra¹, Agus Subiwahjudi²

¹Resident, Departement of Conservative Dentistry

² Staff Department of Conservative Dentistry

Faculty of Dental Medicine,
Universitas Airlangga Surabaya, Indonesia

ABSTRACT

Background: Noticable discoloration of teeth can impact on a person self image and confidence. There are variety of management options for discoloured teeth which range from invasive methods like full veneer crowns to least invasive like internal bleaching.

Purpose: The aim of this article is to present the role of glass ionomer cement placement as a barrier in internal bleaching post endodontically treated in maxillary anterior. The most important parameter is the placement of barrier to prevent the resorption of the tooth and to improve the shade of the bleached tooth perfectly. **Case:** A 34 year old male patient was reported to the department of conservative dentistry with complaint of discoloured upper anterior teeth. Patient had history of trauma with anterior teeth 3 years ago. Intraoral examination revealed non vital, brown-grey discoloured maxillary central incisor. **Case management:** The non vital teeth were treated with root canal treatment then gutta-percha filling was removed to 2 mm bellow cemento-enamel junction with gates glidden drill (Dentsply Maillefer, Ballaigues, Switzerland). A plug of glass ionomer cement (GC Fuji PLUS, GC Corporation, Tokyo, Japan.) was placed over the gutta-percha in cervical region to prevent the bleaching agent leak to cervical and apical area which lead to root resorption. Opalescence® Endo was used as the bleaching agent. After 3 days, the tooth showed a definitive improvement in the shade, except cervical third area, this could be the placement of GIC as barrier were too coronally that inhibit the penetration of the bleaching agents. The internal bleaching procedure was repeated after correcting the GIC placement 2 mm bellow CEJ and the patient was recalled after 1 week. The follow up showed significant improvement in the shade of the bleached teeth perfectly. **Conclusion:** The placement of a proper bleach barrier is the most important factor for successful internal bleaching. Internal bleaching can be considered as a safe, effective and non invasive treatment option in the management of endodontically treated discoloured teeth.

Keywords: Discoloration teeth, Bleaching, Hydrogen Peroxide, Non-vital tooth

Correspondence: Amellia Tjandra, Resident of Conservative Dentistry, Faculty of Dental Medicine, Airlangga University. Email: amelliatjandra@yahoo.com

Introduction

The discolouration of non vital teeth could be a result of many factor such as dental trauma or the endodontic procedure itself. Bacterial, mechanical, or chemical irritation to the pulp may result in tissue necrosis and release of disintegration by-products that may penetrate tubules and discolor the surrounding dentin. Such discoloration can usually be bleached intracoronally.

Intra pulpa hemorrhage and lysis of erythrocytes are a common result of traumatic injury to a tooth. Blood disintegration products, presumably iron sulfides, flow into the tubules and discolor the surrounding dentin. If the pulp becomes necrotic, the discoloration persists and usually becomes more severe with time. The failure of the operator to remove blood or other organic material completely from the pulp chamber during the treatment appears to be the most important and common reason for this post endodontic discolouration. Inadequate access to the cavity preparation results in the presence of shelves of dentin which make it difficult to remove the debris from the pulp horns and the lingual area of the pulp chamber. Therefore, adequate access for the complete debridement of the pulp chamber is essential.

Medication and sealing pastes must be removed from the coronal pulp space subsequent to the completion of the root canal therapy. Many of these agents contain silver, which, if left in the crown,

will cause discolouration. The quality and the type of the root canal filling that has been are primary importance. Proper apical sealing is necessary to prevent the bleaching agents leakage. Many different bleaching agents are available today; the ones most commonly used are hydrogen peroxide, sodium perborate, and carbamide peroxide.

Case

A 34 year old male patient was reported to the department of conservative dentistry with complaint of discoloured upper anterior teeth. Patient had history of trauma with anterior teeth 3 years ago. Intraoral examination revealed brown–grey discoloured maxillary right central incisors. Treatment management with endodontic and internal bleaching were planned.

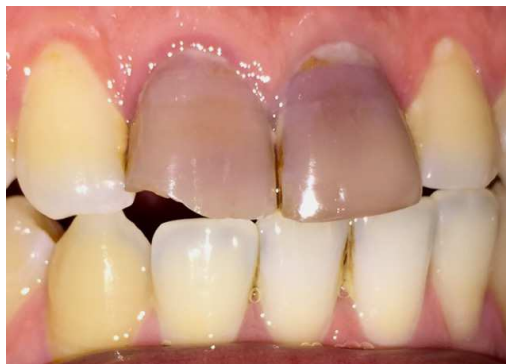

Fig-1: Pre-operative image of patient's tooth.

Case Management

Access opening and complete biomechanical preparation was completed. Calcium hydroxide (Ultracal-Ultradent, St.

Louis, MO, USA) intracanal medicament was placed and recalled the patient after three weeks. Obturation with injection thermoplastic (Beefill-VDW, Germany). The endodontic treatment was carried out under a rubber dam. The access cavity was temporarily sealed with Cavit (3M ESPE, St. Paul, MN, USA). The endodontic treatment was done and recalled after seven

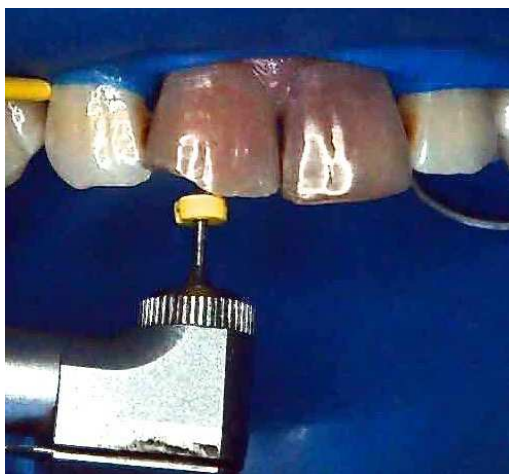


Fig-2: Gutta percha was removed from the access cavity to 2 mm bellow cemento-enamel junction with gates glidden drill;

A plug of glass ionomer cement (GC Fuji PLUS, GC Corporation, Tokiyo, Japan) was placed over the gutta-percha in cervical region to prevent the bleaching agent leak to cervical and apical area which lead to root resorption. The chamber was etched with 37 % phosphoric acid (Total Etch, Ivoclar Vivadent, Liechtenstein) for 30 seconds and it was washed and dried. Opalescence Endo gel (Ultradent, St. Louis, MO, USA), containing 35% hydrogen peroxide was used for bleaching. Opalescence Endo gel was applied inside the pulp chamber and a piece of dry cotton

was placed over and the access cavity was sealed with glass ionomer cement (GC Fuji PLUS, GC Corporation, Tokiyo, Japan.)

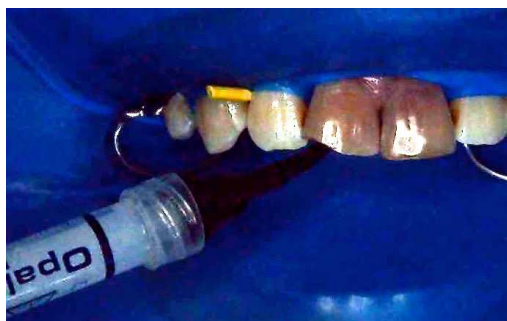

Fig-3: Opalescence Endo gel applied inside pulp chamber.

After 3 days, the tooth showed a definitive improvement in the shade, except at the cervical third area, so the internal bleaching procedure was repeated and the patient was recalled after 1 week. The follow up showed significant improvement in the shade of the bleached teeth perfectly. The Opalescence Endo was removed from the pulp chamber and the access cavity was dressed by Calcium hydroxide (Ultracal-Ultradent, St. Louis, MO, USA) and temporary sealed with with Cavit (3M ESPE, St. Paul, MN, USA).

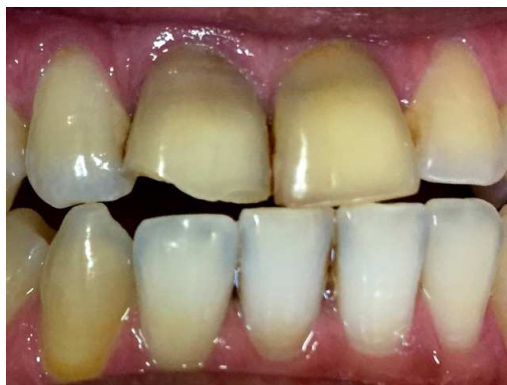

Fig-4: 3 days post internal bleaching

After 1 week pulp chamber was thoroughly rinsed with water and the access cavity was restored by composite resin (Filtek Z350, 3MESPE, MN, USA). Two sittings of bleaching procedure showed complete removal of discoloration of non vital tooth and present colour was comparable to adjacent tooth.

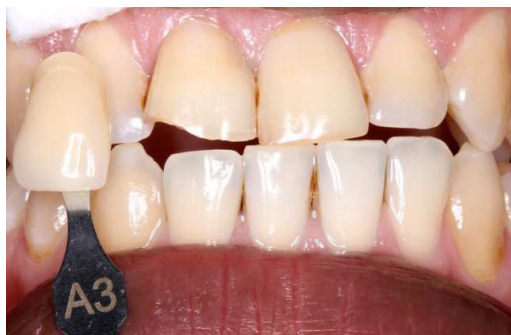

Fig-5: 7 days post internal bleaching

Discussion

Internal bleaching should always be carried out with rubber dam isolation. Adequate obturation ensures a better overall prognosis of the treated tooth. It also provides an additional barrier against damage by oxidizers to the periodontal ligament and periapical tissues. This is essential to prevent leakage of bleaching agents that may infiltrate between the gutta-percha and root canal walls, reaching the periodontal ligament via dentinal tubules, lateral canals, or the root apex.

After 3 days, the tooth showed a definitive improvement in the shade, except at the cervical third area, this could be the placement of GIC as barrier were too coronally, that inhibit the penetration of the

bleaching agents. The correct placement GIC was 2 mm bellow cemento enamel junction. GIC play important role as barrier protection since GIC has chemical interlocking with dentin tubules and GIC has smaller micropores than zinc phosphat cements, it plays adequate sealed post endodontic treatment.

The mechanism of tooth bleaching is unclear. It differs according to the type of discoloration involved and the chemical and physical conditions at the time of the reaction. Bleaching agents, mainly oxidizers, act on the organic structure of the dental hard tissues, slowly degrading them into chemical by-products, such as carbon dioxides, that are lighter in color. Inorganic molecules do not usually break down as well. The oxidation-reduction reaction that occurs during bleaching is known as a redox reaction. Generally, the unstable peroxides convert to unstable free radicals. These free radicals may oxidize (remove electrons from) or reduce (add electrons to) other molecules.

Clinical reports and histologic studies have shown that internal bleaching may induce external root resorption. This is probably caused by the oxidizing agent, particularly 30 to 35% hydrogen peroxide. Presumably, the irritating chemical diffuses via unprotected dentinal tubules and cementum defects and causes necrosis of the cementum, inflammation of the periodontal ligament, and, finally, root resorption.

Bleaching with hydrogen peroxide may affect bonding of composite resins to dental hard tissues. Scanning electron microscopy suggests a possible interaction between composite resin and residual peroxide, causing inhibition of polymerization and an increase in resin porosity. This presents a clinical problem when immediate esthetic restoration of the bleached tooth is required. It is therefore recommended that residual hydrogen peroxide be totally eliminated prior to composite placement.

There is no ideal method for filling the chamber after tooth bleaching. The pulp chamber and access cavity should be carefully restored with a light-cured acid-etched composite resin, light in shade. The composite material should be placed at a depth that seals the cavity and provides some incisal support. Light curing from the labial surface, rather than the lingual surface, is recommended since this results in shrinkage of the composite resin toward the axial walls, reducing the rate of microleakage.

As previously stated, residual peroxides from bleaching agents, mainly hydrogen peroxide and carbamide peroxide, may affect the bonding strength of composites. Therefore, waiting for a few days after bleaching prior to restoring the tooth with composite resin has been recommended. Catalase treatment at the final visit may enhance the removal of residual peroxides from the access cavity; however, this requires further clinical

investigation. Packing calcium hydroxide paste in the pulp chamber for a few weeks prior to placement of the final restoration, to counteract acidity caused by bleaching agents and to prevent root resorption, has also been suggested; this procedure, however, is unnecessary with walking bleach.

Bleached teeth should be frequently examined both clinically and radiographically. Root resorption may occasionally be detected as early as 6 months after bleaching. Early detection improves the prognosis since corrective therapy may still be applied.

Conclusion

This case report demonstrates the successful management of a discoloured, endodontically treated tooth by internal bleaching. Internal bleaching can be used as a very effective and safe post -endodontic treatment for discoloured anterior teeth.

References

1. Prasanna Neelakantan, Nithya Jagannathan. Non Vital Bleaching – A Non Invasive Post Endodontic Treatment Option: A Case Report. *Journal of Clinical and Diagnostic Research*. 2012; Vol-6(3):527-29
2. Rotstein, Ilan. *Tooth Discoloration and Bleaching*; 1996. P. 845-60
3. Firsta Dianty, Endang Sukartini, Milly Armilia. *Bleaching internal untuk merawat perubahan warna gigi insisivus sentralisakan atas* (Laporan

- Kasus). Dentofasial. 2011; Vol.10, No.102:101-104
4. Walton R E, Torabinejad M. Prinsip dan Praktik Ilmu Endodontia. Alih bahasa: Yuwono L. Edisi ke-3. Jakarta: EGC; 2008. P. 455-460.
 5. Ingle JI, Bakland LK. Endodontics. 6th Ed. Ontario:BC Decker Inc.P.; 2008. p. 1389.
 6. Greenwall L, ed. Bleaching techniques in restorative dentistry. New York: Thieme; 2001. P.159.

INTRACORONAL BLEACHING ON TOOTH DISCOLORED BY TRIPLE ANTIBIOTIC PASTE

Andari Putrianti¹, Munyati Usman²

¹Post Graduate Student, Department of Conservative Dentistry, Faculty of Dentistry
Universitas Indonesia

²Lecturer, Department of Conservative Dentistry, Faculty of Dentistry,
Universitas Indonesia

ABSTRACT

A triple antibiotic paste (TAP) mixture of ciprofloxacin, metronidazole, and minocycline was used as intracanal medicament in an attempt to disinfect the root canal. The presence of minocycline has proven effective as antibacterial agent in many studies, but it causes visible tooth discoloration when used inside the tooth crown. Intracoronar bleaching technique is a safe non time consuming treatment alternative used to treat intrinsic discoloration. The purpose of this case report is to present a clinical case of intracoronar bleaching on tooth discolored by TAP.

A 23-year-old woman was referred for an evaluation of tooth #11. The patient complained that the tooth became darker than the adjacent tooth since she went to the dentist for tooth restoration 4 years ago. Clinical examination revealed that tooth #11 was restored with composite resin on mesial side and temporary filling on palatal side. Tooth was sensitive to percussion, unresponsive to cold stimulation, and black-grayish discoloration of coronal tooth structure was noted. Pre-operative radiograph showed there was a widening of periodontal ligament space and thickening of lamina dura. Tooth diagnosed with asymptomatic apical periodontitis caused by partial necrosis. Root canal treatment and internal bleaching were decided to be performed.

Keywords: triple antibiotic paste, intracoronar bleaching, maxillary central incisor

INTRODUCTION

Tooth discoloration has various etiology, clinical appearance, degree of discoloration, and different mechanism of chromogen adherence to tooth structure. It can be classified either extrinsic or intrinsic in nature (Jordan and Boksman, 1984). Extrinsic discoloration occurred in the outer surface of tooth structure, meanwhile intrinsic discoloration occurred inside the tooth structure where the chromogen

penetrates into enamel and dentine during odontogenesis or after tooth eruption.⁽¹⁾

Pulp necrosis, restorative and endodontic materials, trauma, aging process, caries, and parafunctional activity are examples of intrinsic discoloration after tooth eruption.^(2,3) Triple antibiotic paste (TAP) is a intracanal medicament containing minocycline, ciprofloxacin, and metronidazole. Several case has reported

the use of TAP intracoronally causing tooth discoloration because of the presence of minocycline. The efficacy of TAP as intracanal medicament to sterilize the root canal from polymicrobial was undoubted. Recently, TAP also has been used in lesion sterilization and tissue repair (LSTR) therapy to disinfect the root canal.^(3,4)

Intracoronally bleaching is indicated for asymptomatic tooth undergone root canal therapy, it is the preferred treatment alternative compared with veneer and crown. Nowadays, hydrogen peroxide is currently used for bleaching treatment because it contains reactive free radicals.^(2,5) The aim of this article was to present tooth discoloration caused by TAP managed with intracoronally bleaching using high concentration of hydrogen peroxide.

CASE REPORT

A 23-year-old woman referred to RSGM-P complaining her front tooth became darker with time compared with the adjacent tooth since 4 years ago. Tooth #11 and #21 was restored using composite resin in year 2013. Several months after her dental visit, she experienced uncomfortable feeling in the area of #11 especially during eating. The patient returned to the dentist to have a treatment for tooth #11, since then, tooth became discolored with time.

Intraoral examination revealed tooth #11 restored with composite resin on mesial and palatal side. The tooth was discolored and had no response to vitality test, it was sensitive to percussion, and

responded normally to palpation. Oral hygiene score was 1,54 (intermediate). Periapical radiographic examination revealed that tooth #11 had thickening of lamina dura and widening of periodontal ligament space.

A diagnosis of pulp necrosis with asymptomatic apical periodontitis was made. The treatment plan was non-vital root canal, intracoronally walking bleach technique, and composite resin restoration. Intracoronally walking bleach technique was the treatment of choice because it is less invasive and more economical compared with crown restoration. The prognosis was good because tooth #11 still has enough tooth structure and the patient has a high motivation to complete the treatment plan.

METHODS

Anamnesis, clinical and radiograph examination was done in the first visit and rubber dam was used for tooth isolation. The previous restoration was taken and re-access the tooth using diamond and Endo-Z tapered safe-ended bur. After regaining the access, pulp extirpation was done using extirpation needle #25. Working length was determined using apex locator and canal negotiation started with ISO file #25/24 mm was done. Root canal irrigation using sodium hypochlorite 2,5% and EDTA 17% were used and activated with endoactivator.

Pro taper hand used was used for root canal preparation and master apical file was determined. Irrigation using sodium hypochlorite 2,5% and EDTA 17% were

used and activated with endoactivator. Master cone was evaluated clinically and radiographically. Gutta percha cone #F5/24 mm was tried-in to the root canal and tug back sensation was evaluated. Periapical radiograph revealed the master cone was fit inside 1/3 apical of root canal. Root canal was dried using paper point and calcium hydroxide was used for medicament. The cavity was restored using temporary filling material and the patient recalled 1 week after.

On the next visit, the tooth was evaluated before commencing obturation. Tooth #11 was asymptomatic and obtured with single cone technique using gutta percha and AH plus sealer. Light cured glass ionomer used as the liner and periapical radiograph was taken to evaluate obturation. The cavity was restored using temporary filling material and the patient recalled 1 week after.

Tooth evaluation after obturation was asymptomatic and the tooth prepared for intracoronal walking bleach technique. Gutta percha was taken using gates glidden drill 2 mm under the orifice, and "Bobsled" bleaching barrier was made using light cured glass ionomer. Before bleaching material applied, Vaseline was used to protect the mucosa around the lips. Opalescence Endo Gel containing 35% hydrogen peroxide was used and applied inside the pulp chamber. The cavity was restored using temporary filling and the patient recalled 5 days after.

On the next visit, tooth #11 showed brighter color and adjusted with VitaPan Classical Shade Guide. Tooth #11 had A2 shade and the patient feel satisfied with the tooth color. The cavity was cleaned using aquabidest and temporary filling was used. The patient recalled 2 weeks after for permanent restoration using composite resin.

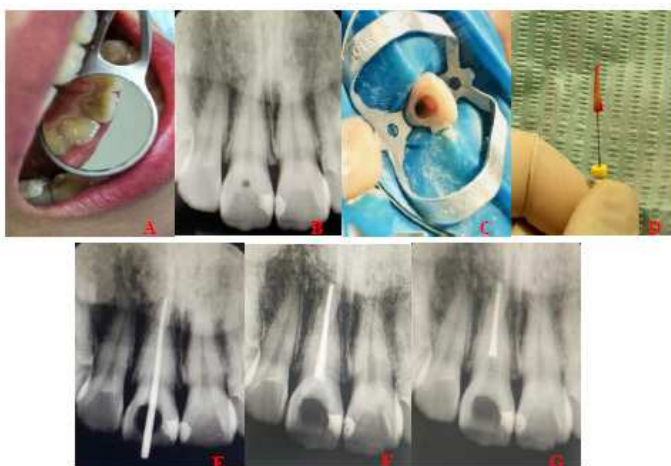

Figure 1. Root Canal Treatment on Tooth #11. Clinical appearance on palatal side (a), periapical diagnostic radiograph (b), tooth access appearance (c), clinical appearance after pulp extirpation (d), periapical radiograph of master cone (#F5/24 mm) (e), periapical radiograph after tooth obturation (f), and periapical radiograph after Gutta percha removal (g)

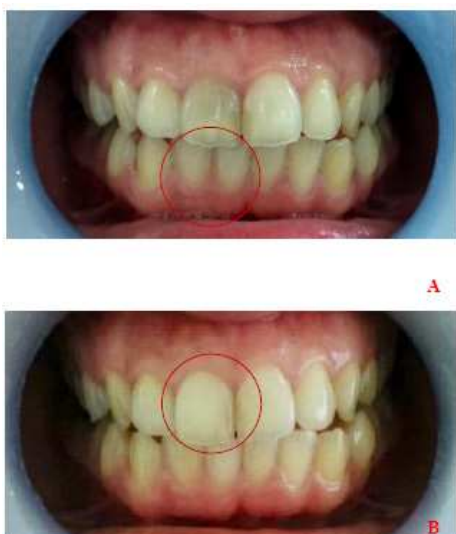


Figure 2. Walking Bleaching Technique on Tooth #11. Clinical appearance before walking bleaching technique (a) and clinical appearance after walking bleaching technique (b)

DISCUSSION

Root canal treatment was done several visits. Cream with an oily consistency was found inside the pulp chamber and greenish-black discoloration was noticed inside the pulp chamber and orifice. After the cream and debris were excavated, it was seen that the pulp horn already exposed. Greenish-black discoloration and the existence of TAP cream (an oily cream with greenish color) inside the pulp chamber were the hallmarks of tooth discoloration caused by TAP.

During regaining access to the pulp chamber the patient felt pain sensation, then the tooth was anesthetized with Lidocaine using infiltration technique. Bleeding was seen inside the orifice, during extirpation, the vital pulp was retracted completely.

The diagnosis then changed to pulp necrosis with asymptomatic apical periodontitis.

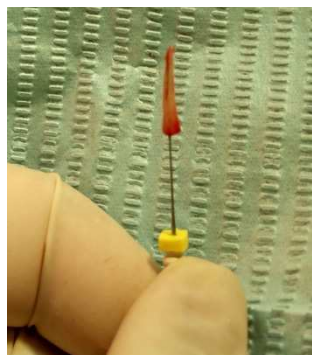

Figure 3. Pulp Extirpation

TAP is a multi-antibiotic intracanal medicament consisting of minocycline, ciprofloxacin, and metronidazole.^(6,7) Minocycline inside TAP could cause greenish-black discoloration, minocycline molecules could bond to calcium ions inside the dentinal structure and form one complex reaction that caused tooth discoloration.⁽⁸⁻¹⁰⁾ Besides minocycline, ciprofloxacin could also cause discoloration, but the mechanism is not fully understood and further studies still needed.⁽¹⁰⁾

Hydrogen peroxide 35% was used because its high concentration is effective to brighten the discolored tooth. Hydrogen peroxide will diffuse to enamel and dentine, it will decompose and release free radicals inside the organic tooth structure. Free radicals have unpaired electrons and are unstable in nature, once they enter the organic tooth structure, they will attack the complex structure of chromogen to gain stability. Free radicals and chromogen bind each other and form simpler molecules that are brighter in nature.^(11,12)

Composite resin was used as definite restoration. Delayed application around 1-2 weeks after tooth bleaching is necessary to eliminate residual free radicals in the pulp chamber. Free radicals residue could interfere composite resin bonding strength to tooth structure, it can disturb polymerisation of composite resin. If direct composite restoration applied on the day of internal bleaching, ascorbic acid 10% placed in the pulp chamber for 10 minutes could be used to eliminate the amount of free radicals in the pulp chamber.⁽¹³⁾ Prophylactic fiber is not necessary in this case, because the tooth still has enough structure to withstand occlusal force and retain direct restoration.

CONCLUSION

This case showed successful intracoronary walking bleach technique using high concentration of hydrogen peroxide in tooth discoloration caused by TAP. Gel application only applied once and the patient already satisfied with the color change. Intracoronary walking bleach technique is a safe, economical, and cost-effective technique for anterior tooth discoloration.

REFERENCES

1. Greenwall L. Bleaching technique in restorative dentistry.pdf. London: Martin Dunitz; 2002.
2. Greenwall L. Linda H. Greenwall, Principles and Techniques, Tooth Whitening in Esthetic Dentistry..

- pdf. Singapore: Quintessence; 2009.
3. Mehanna C, Khoury P, Zogheib T, Kassis C. Aperito Journal of Oral Health and Dentistry Intrinsic Tooth Discoloration , an Updated Review. 2015;1(4).
4. Plotino G, Buono L, Grande NM. Nonvital Tooth Bleaching : A Review of the Literature and Clinical Procedures. 2008;34(4).
5. Dahl JE, Introduction I. TOOTH BLEACHING — A CRITICAL REVIEW OF THE BIOLOGICAL ASPECTS. 2003;14(7722):292–304.
6. Journal I, Dentistry C, Sciences M. Colors in tooth discoloration : A new classification and literature review. 2014;(January).
7. Krastl G, Lenherr P. Tooth discoloration induced by endodontic materials : a literature review. 2013;(Table 1):2–7.
8. Watts A, Addy M. Tooth discolouration and staining : a review of the literature. 2001;190(6):309–16.
9. Suchetha A, Khawar S, Sapna N, Vinaya S, Dab M, Jayachandran C. ALL ABOUT DENTAL STAINS : A REVIEW (PART II). 2016;4(2):47–50.
10. Article R. Cervical root resorption and non vital bleaching. 2013;1864(2):106–11.
11. Goldstein RE, Garber DA. Complete Dental Bleaching. 1st editio. Haus A, editor. Hong Kong: Quintessence

Publishing; 1995. 25-34 p.

12. Mds VRP, Sharadchandra B, Mds M.
“ 3Mix - MP in Endodontics – An
overview .” 2012;3(1):36–45.
13. Suprastiwi E, Heptorina Y.
Application of 10 % Ascorbic Acid
Improves Resin Shear Bond Stregth
In Bleached Dentin. 2014;21(1):1–4.

CASE REPORT

RETREATMENT AND ROOT CANAL TREATMENT WITH ALL PORCELAIN CROWN RESTORATION AND FIBER POST ON FOUR ANTERIOR TEETH FRACTURE POST TRAUMA

Arafita Putri Fardani*, Ema Mulyawati**

* Resident of Department Conservative, Faculty of Dentistry,
Universitas Gadjah Mada, Yogyakarta, Indonesia

** Department of Conservative Dentistry, Faculty of Dentistry,
Universitas Gadjah Mada, Yogyakarta, Indonesia

*Jl. Denta No.1 Sekip Utara, Yogyakarta. E-mail: fitaputri1007@gmail.com

ABSTRACT

Background: Trauma that occurs in the anterior teeth can cause the teeth to be non vital, fracture, malposition, and affecting the aesthetic. Root canal treatment is a treatment to maintain the non-vital teeth in the oral cavity. Aesthetic factors is a consideration in the selection of restoration materials. Golden proportion also affects the aesthetic of the patient's teeth. **Purpose:** This case report aims to inform root canal treatment and retreatment of four anterior teeth with all porcelain crown restoration and fiber post. **Case Management:** The 22 year-old male patient came to RSGM Prof.Soedomo FKG UGM to ask for an upper teeth due to an accident. Broken teeth involve four anterior teeth. Two of the four teeth have been done root canal treatment with metal post and acrylic crown. But the restoration is inadequate. Crown of acrylic used is repeatedly loose and broken. On the periapical radiograph examination radiolucent images appear in the apical regions of 12, 11, 21, and 22, non-hermetic obturation of the teeth 12 and 22. Seen a prefabricated metal posts that does not suitable. Root canal treatment was performed on teeth 11 and 21, retreatment of teeth 12 and 22, with all porcelain crown restoration and fiber post. Recall patient 3 month post-treatment that seen on the periapical radiograph of the lesion is smaller. **Conclusions:** the use of restorative materials and aesthetic factors may influence the success of the treatment.

Keywords: aesthetic, crown porcelain, fracture, golden proportion, root canal treatment.

INTRODUCTION

Majority of the dental injuries consists of crown fractures seen on the permanent anterior teeth. It was reported that almost one fourth of the population experienced dental injuries related with the crown fractures in anterior teeth (1). The main

causes of such injuries are the sport injuries, falling down, and motor vehicle accidents. Crown fracture present almost 92% of all traumatic injuries of the permanent teeth. The anterior incisors are most often affected (80% central incisors and 16 % lateral incisors) because of the anterior position of

the maxilla and tooth protrusion. Various treatment modalities have been practiced in past to restore the fractured anterior teeth including composites, laminates, esthetic crown, or the reattachment of fractured fragment (2). The management of coronal tooth fractures is dependent on many factors such as biological width violation, endodontic involvement, and pattern of fracture, presence or absence of fractured fragment, restorability of tooth, occlusion and aesthetics (3). An injury to the maxillary anterior region causes significant disfigurement of the patient's appearance as well as function which in turn imparts deep psychological impact (4). In this case report, it present retreatment and treatment of four anterior teeth post trauma using restoration of porcelain jacket crown and fiber post.

CASE

A 22-year-old male patient came to Dental Conservative Clinic. Prof. Soedomo RSGM UGM with chief complaint the jacket crown has broken. The tooth had been treated and installed a jacket crown made from acrylic. The dental history he had trauma about 7 months ago because of motor vehicle accident and four of his teeth were fractured. The tooth 12 and 22 have root canal treatment with post metal and acrylic crown (fig.1). There are absence of percussion and mobility in relevant teeth. The tooth 23 has fracture also on the one third incisal (fig.1). Radiograph examination the tooth 12 and 22 have been root canal treatment but the obturation is

not hermetic, it has seen radiolucent on the periapical, the prefabricated metal post not ideal, the tooth 11 and 21 had a radiolucent on periapical (fig.2) and had been used jacket crown, the tooth 11 contained a composite restoration in the one third coronal of root canal (fig.2). The patient was not happy with the previous treatment and want to repair the teeth.

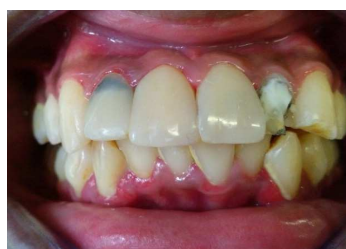

Figure 1. Preoperative clinical condition. Servical of tooth 12 is blackish on the edge of the jacket crown, tooth 22 with a broken acrylic crown, and a tooth 23 has fractured to one third incisal.

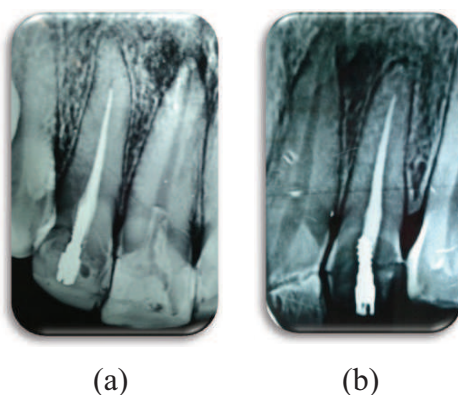


Figure 2. Preoperative intraoral periapical radiograph. It has seen the obturation of tooth 12 is not hermetic, prefabricated metal posts has not suitable, tooth 11 has periapical lesion and contained resin composite in the one third coronal of root canal (a). Periapical lesion on tooth 21 and 22, the tooth 22 obturation is not hermetic and prefabricated post metal has not suitable (b).

Thus, the diagnosis of the tooth 12 is non vital after root canal treatment with periapical lesion, 11 is Ellis fracture Klas IV with periapical lesion, 21 is Ellis fracture Klas IV with periapical lesion, 22 is non vital after root canal treatment with periapical lesion, and 23 is Ellis fracture Klas II. The treatments planning are retreatment of root canal treatment of tooth 12 and 22, root canal treatment of tooth 11 and 21, followed by restoration of all porcelain jacket crown and fiber post, and direct restoration composite resin for tooth 23.

Case Management

On the first appointment, take a profile photo patient and opened an old restoration, after that take an impression to make studying model. Because the old restoration is inadequate so the restoration was opened and made mock up using study model. Profile photo is used to analysis facial and analysis dentofacial. Mock up is used to space analysis, dental analysis, and gingival analysis.

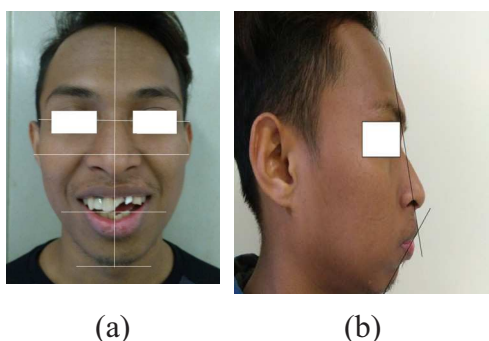


Figure 3. Profile photo patient from fasial (a) and lateral (b).

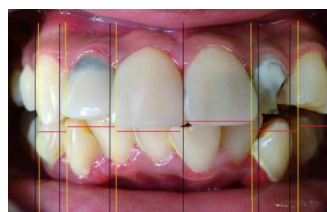

Figure 4. Space analysis using golden proportion theory 0,618:1:1,618

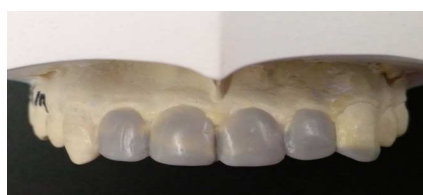

Figure 5. Mock up on study model

Prefabricated metal posts on the tooth 12 and 22 has been taken, obturating material were removed using Peeso reamer and confirmed radiographically. Canals were irrigated with saline to flush the gutta percha and sealer remnants. Working length measurement using radiograph methode and preparation root canal using step back technique. Irrigation using saline solution and NaOCl 2,5%. Canals were dried using paper points and calcium hydroxide based intracanal medicament was placed inside by using a lentulo spiral. The cavity was then temporarily restored (Cavition, GC). In the next visit, master cone radiograph was taken, the canals were obturated with gutta-percha cones and then using resin based sealer (Topseal, Dentsply, Konstanz, Germany) as a root canal sealer.

The next treatment is the tooth 11 and 21. Pulp debridement using barbed broach and K-files. Irrigation with saline solution and NaOCl 2,5% to remove necrotic

tissues. Working length measurement using radiograph method and preparation with step back technique. After drying the canals with paper point, intracanal medicament with calcium hydroxide was placed inside the canal and the access cavity was temporarily sealed (Cavition, GC). The next visit, the canals were obturated using master cone gutta-percha point and resin based sealer (Topseal, Dentsply, Konstanz, Germany).

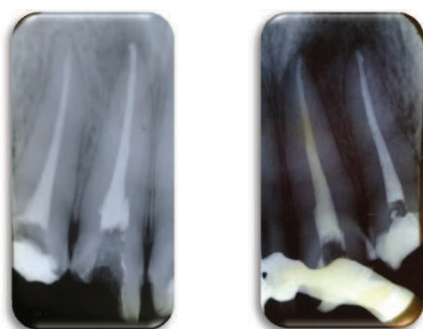


Figure 6. Radiograph periapical post obturation the tooth 12, 11, 21, 22. It has seen hermetic.

Then, after 7 days, patient recalled and the post space was prepared using number 2 & 3 Peeso-reamers (Dentsply, Mallifier) maintaining a seal of 5 mm of apical plug of gutta-percha. Radiograph was taken for the confirmation of the post space preparation (fig. 7).

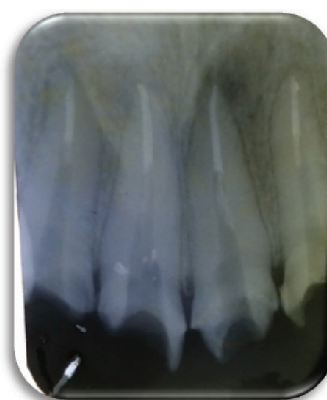


Figure 7. After preparation of post

In the tooth 11 and 21 used prefabricated fiber post. The canal were etching with phosphat acid 37% and application of bonding (STAE Bond, SDI, Australia). After the posts (Radix Fiber post, DENTSPLY) were silanized (Primer Bond RelyX U-200, 3M ESPE) for 60 seconds and then the fiber post were inserted using dual cure resin cement (Built It FR, Pentron) and cured. Core build up using fiber reinforced core material (Built It FR, Pentron). In the tooth 12 and 22, clinical examination of the root canal was wide. So it was decided to restore and reinforce the root with polyethylene fiber (Construct, Kerr) and core build up using resin composite packable (Filtek P60, 3M ESPE). The post space length was measured. This measurement was doubled, estimated core length added and the necessary length of fiber decided. 1 mm wide Construct fiber of about 30 mm length was taken and folded. The fibres were cut with the special scissors which are part of the set (Construct Starter Kit, Kerr). It was moistened with Construct wetting

agent, excess adhesive on the Construct pieces was gently removed with a hand instrument moving in the direction of the fibres and was set aside in a light-protected container. The coronal was etched with 37% phosphoric acid, bonding agent (SDI, Australia) was applied. Resin cement (Rely-X U200, 3M ESPE, St paul, USA) inserted into the canal. The folded end was placed inside the canal, tightly condensed with an endodontic plugger and the free ends were placed coronally. The excess resin was removed. Light curing was done completely by polymerization of the composite. Core build-up was done with composite resin (Filtek P60, 3M ESPE).

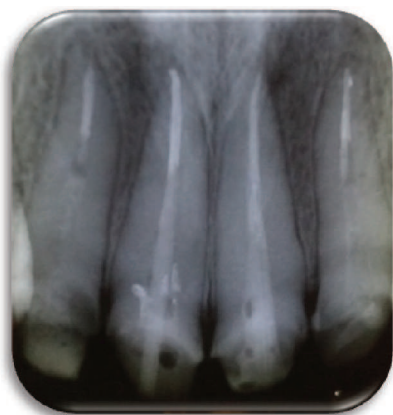


Figure 8. The teeth 11 and 21 after insertion of prefabricated fiber post (Radix Fiber Post, Dentsply), the teeth 12 and 22 after insertion polyethylene fiber.

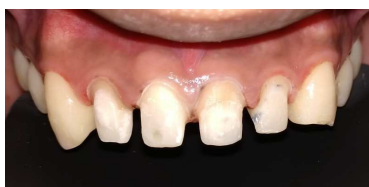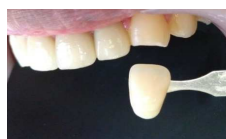


Figure 9. The teeth after preparation of core

Then an impression was made using double impression vinyl polysiloxane (Exaflex Putty, GC) and *hydrophilic polysiloxane* (Exaflex, GC). Temporary crown was made (Revotek LC, GC). After 7 days, all porcelain jacket crown were tried on patient and inspected for marginal fit. After silanized using ceramic primer (RelyX Ceramic Primer, 3M ESPE) porcelain crowns were inserted using cement resin (RelyX U200, 3M ESPE) (fig. 10). The fractured tooth 23 was done with direct restorative using packable resin composite (*Ceram.X Spherotec One Universal, Dentsply*) (fig. 11 (a) and (b)).

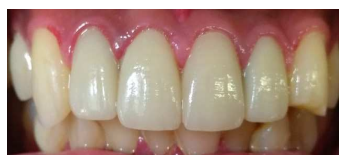

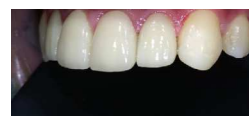Figure 10. After insertion of all porcelain crown restoration



(a)



(b)

Figure 11. Shade guide for composite colour (a) and tooth 23 after direct restoration using resin composite packable (b).

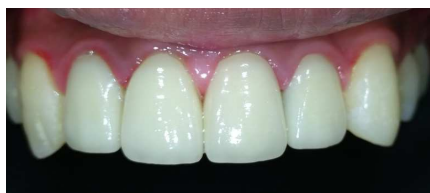

Figure 12. Clinical photo after insertion of jacket crown porcelain on the teeth 12, 11, 21, 22 and direct restoration of resin composite on the tooth 23.

After 3 months patient recalled and evaluation of treatment outcome, patient no complaints, restoration in good condition, not broken, not cracked, unchanged color, condition of supporting tissues in good condition no inflammation (fig.14). On the periapical radiograph examination it has seen the lesion is smaller (fig.13).

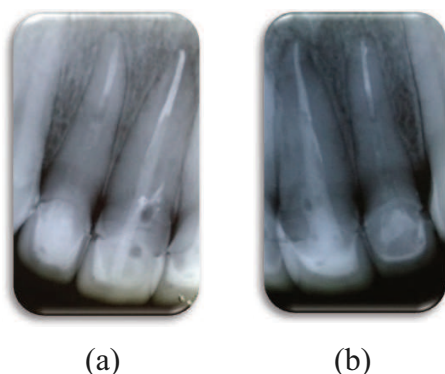


Figure 13. Radiograph periapical of the teeth 12,11 (a), and teeth 21,22 (b) after recalled and control 3 month after treatment. It has seen the lesion on periapical 11 and 21 are smaller.

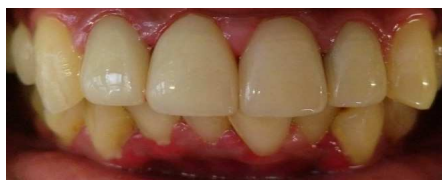

Figure 14. Clinical photo recalled patient after 3 months.

Discussion

A smile is a person's ability to express a range of emotions with the structure and movement of the teeth and lips and can often determine how well a person functions in society. In social interactions, our attention focuses mainly on the mouth and eyes of the face of the person speaking. As the mouth is the center of communication of

the face, the esthetic appearance of the oral region during smiling is a conspicuous part of facial attractiveness. The smile design theory can be broken down into four parts: facial esthetics, gingival esthetics, micro esthetics, and macroesthetics. Facial esthetics involves the lips and soft tissue curvature during smiling, speech, and laughter. Gingival esthetics involves the health of the gingiva, the shape of the interdental papilla, and the presence or absence of black triangles. Micro esthetic features involve the anatomy of the anterior teeth, incisal translucency, characterization, and lobe development. Macro esthetic features involve the facial midline, as well as the size and shape of the teeth. The size and form of the maxillary anterior teeth are important factors in dental and facial esthetics. The goal of dental techniques is to have the maxillary anterior teeth restore optimal dentolabial relations in harmony with the overall facial appearance. Therefore, the need exists for an objective analytical method of smile design using accepted proportional smile design norms. The most influential factors contributing to a harmonious anterior dentition are the size, shape, and arrangement of the maxillary anterior teeth as viewed from the front. The Golden proportion (1.618:1.0) is a mathematically constant ratio that defines the dimensions between larger and a smaller length. This specific relation is unique, perfect, ideal, and desirable. It has been used in many areas, including studying beauty to designing esthetic restorations. It is also a valuable tool for the evaluation of

symmetry, dominance, and proportion in the diagnosis of tooth arrangement and in the application of esthetic dental treatment (5).

Tooth structure lost during endodontic treatment increases the risk of crown fracture, with fatigue mechanisms mediating the fracture of roots over time. Restorations of endodontically treated teeth are designed to; protect the remaining tooth from fracture, prevent reinfection of the root canal system, and replace the missing tooth structure. Posts should provide as many of the following clinical features as possible; maximal protection of the root from fracture, maximal retention within the root and retrievability, maximal retention of the core and crown, maximal protection of the crown margin seal from coronal leakage, pleasing aesthetics, high radiographic visibility, and biocompatibility. An ideal post would have an optimal combination of resilience, stiffness, flexibility, and strength. *Resilience* is the ability to deflect elastically under force without permanent damage. It is a valuable quality in endodontic posts, but too much flexibility in a narrow post compromises its ability to retain the core and crown under functional forces. *Stiffness* describes a material's ability to resist deformation when stressed. The stiffness of a material is an inherent physical property of that material, regardless of size. However, the actual flexibility of a post depends both on the diameter of a specific post and on the modulus of elasticity of the post's

material. Posts with a lower modulus of elasticity are more flexible than posts of the same diameter with a higher modulus of elasticity. Posts made of nonstiff materials (low modulus of elasticity) are more resilient, absorb more impact force, and transmit less force to the root than stiff posts, but low-modulus posts fail at lower levels of force than do highmodulus posts (6).

Ultra high molecular weight polyethylene (UHMWPE) fibre reinforcement systems are gaining in popularity. As bondable reinforcement fibres, they can be used to build up endodontic posts and cores; moreover, it can adapt to the root canal walls without requiring additional enlargement of the root canal after endodontic treatment. These woven fibres have a modulus of elasticity similar to that of dentine and are supposed to create a monoblock dentine post core system able to better distribute forces along the root. Polyethylene fiber has shown to reinforce the weakened root structures (7).

Fibre reinforced restorations have an acceptable success rate. The physical properties of the materials used for these restorations are dependent on the type of composite material, the position, quantity, direction and form of the fibres, the fibre/matrix ratio, distribution of the fibres in the matrix and impregnation of the fibres with the polymer matrix. Application of a fibre layer in a restorative material might increase the load bearing capacity

of the restoration and could prevent crack propagation from the restoration to the tooth. Fibre reinforced composites (FRC) effectively withstand tensile stress, and woven continuous FRC's have the potential to provide more consistent properties than unidirectional fibres because of the three dimensional structure resulting from the leno weave or triaxial braid (8).

According to the manufacturer, apart from having excellent properties in translucency, polyethylene fibers exceed the breaking point of fiberglass and are so tough that special scissors are required to cut them. In addition, unlike loosely braided or bundles of unidirectional fibers, these fibers do not spread or fall apart when manipulated because the dense network of locked-stitched threads prevents the fibers from shifting during manipulation and adaptation before polymerization. Because of these characteristics, polyethylene fibers can be bent to sharp angles and woven to make tight mechanical interlocking from one thread to another. Also, these ultra-high molecular weight polyethylene fibers have a high elasticity coefficient and a high resistance to stretch, distortion and traction that allows them to adapt closely to the contours of the root canal and to properly condense, increasing the content of individually made endodontic post thus decreasing the luting-agent thickness and consequently its polymerization shrinkage. Since the fibers adapt to the root canal, the canal enlargement is not required, hence the natural strength of

the tooth is preserved and a possibility of the root perforation is eliminated. In a comparison with other fiber reinforced posts (including the individually formed glass fiber reinforced post), an individually shaped polyethylene post cemented with dual-cure resin cement shows the least amount of microleakage in overflared root canals. Woven fiber architecture enhances fracture resistance which is also evident in the case of cracks induced by load. The crack stops at the node of the le-no-lock-stitch weave, thereby preventing the crack propagation from the restoration to the tooth and helping maintain the integrity of the fiber reinforcement. It has been shown that polyethylene-reinforced resin provides sufficient retention required for clinical success of a post and core system and adequate fracture resistance with increased incidence of repairable fractures in structurally compromised canals (9).

With the application of adhesive technology to endodontics, the term monoblock has become familiar. Monoblock units can be created in a root canal system either by adhesive root canal sealers such as EndoREZ, in combination with a bondable root filling material Resilon. Monoblocks can also be created using adhesive post systems, which have similar elastic moduli to dentine such as carbon fibre-reinforced posts, prefabricated glass-fibre posts, customized polyethylene fibre posts, or customized glass-fibre posts. When this classification is adapted to the post-core systems, a customized

polyethylene fibre post-core system such as Ribbond (Ribbond Inc., Seattle, WA, USA) can create a primary monoblock in a root. Before creating a post-core build-up restoration with this system, impregnation of polyethylene fibre with a dual curable adhesive system is a necessary step. Impregnated fibre is then condensed into the root canal in combination with a dual curable resin cement. Only one interface occurs between the polyethylene fibre post-core system and the root canal, therefore, polyethylene fibre post-core build-ups can be considered as a primary monoblock system. Prefabricated post systems bonded to root canal dentine via resin cements represent a secondary monoblock, and fibre posts that contain an extra silicon coating such as DT Light (VDW GmbH, Munich, German) or ceramic posts that require a silane coating such as Cosmopost (Ivoclar, Vivadent, AG, Schaan, Liechtenstein) can be considered as tertiary monoblocks (10).

The Construct (Kerr) product is made from cold gas-treated polyethylene fibers impregnated with silane and resin, which allows for easier handling. Impregnation of reinforcing fibers with resin allows fibers to enter the polymer matrix. This is a prerequisite for bonding fibers to the polymer matrix and thus critical for the strength of the composite. Moreover, insufficient impregnation causes several problems. Voids in poorly impregnated fiber composites are oxygen reserves that allow oxygen to inhibit radical polymerization of the acrylic resin inside the composite.

This can lead to a higher residual monomer content in the fiber composite and reduced FRC strength (11).

Conclusion

Trauma on the anterior tooth can result in many problems which influence esthetic appearance. In this case using fiber post because the use of fiber post has a good aesthetic and strength advantages, and can form monoblocks in the root canal system. Jacket crown porcelain has a good aesthetic, long lasting appearance.

REFERENCES :

1. Uslu G, Özyürek T, Ülker Ö, Yılmaz K. Conservative treatment of traumatic anterior teeth via reattachment technique : Two case reports. *Int J Appl Dent Sci* 2017; 3(1) 5-8 ISSN. 2017;3(1):5–8.
2. Thakur VBS, Gupta K, Ishant Sood, Mishra P, Kashl H, Kritika, et al. Natural Rehabilitation of Fractured Anterior Tooth Using Reattachment, a Single Visit Endo- Esthetic Approach- A. *Ann Int Med Dent Res* Vol (3), Issue. 2016;3:13–6.
3. Meghna NBN, Nitika B, Poornima P. A Case Reports Treatment regime for crown fractures : Autogenous tooth fragment reattachment – A case series Abstract : :96–9.
4. Kaushik S, Sharma R, Sharma V, Setya G, Assudani G, Arora A. Management of anterior tooth trauma : Two case reports. *Endodontology*.

2016;28(1):64–7.

5. Azimi M, Dinparvar M, Teimourian H, Farhadian M. Evaluating Recurring Esthetic Dental Proportion (RED) and Golden Proportion in Natural Dentition. *Avicenna J Dent Res* 2016; InPress(InPress) e30267. 2016;1–5.
6. Hargreaves, Kenneth M. BLH. Cohen's Pathways of the Pulp Eleventh Edition. Elsevier; 2016. 1143 hal.
7. Singh S, Nagpal R, Singh P, Up S. Esthetic and Functional Rehabilitation of Maxillary Anterior Tooth by Polyethylene Fibre Post. *Austin J Clin Case Reports*. 2016;3(3):01–4.
8. Belli S, Eskitascioglu G. Biomechanical Properties and Clinical Use of a Polyethylene Fibre Post-Core Material. *Int Dent South Africa* Vol 8, No 3. 8(3).
9. Amžić IP, Baraba A. Esthetic Intracanal Posts. *Acta Stomatol Croat*. 2016;50(1):143–50.
10. Belli S, Eraslan O, Eskitascioglu G, Karbhari V. Monoblocks in root canals: a finite elemental stress analysis study. *Int Endod J*. 2011;44:817–26.
11. Ilday N, Seven N. The influence of different fiber-reinforced composites on shear bond strengths when bonded to enamel and dentin structures. *J Dent Sci*. 2011;6:107–15.

CASE REPORT

COMPOSITE RESIN RESTORATION WITH FABRICATED FIBER- REINFORCED POST COMPOSITE ON NECROSE PULP OF MAXILLARY CENTRAL INCISOR POST ROOT CANAL TREATMENT

Betagia Swandhika Wisesa* Ema Mulyawati**

*Residence of PPDGS Conservative Dentistry Faculty of Dentistry
Universitas Gadjah Mada, Yogyakarta.

**Staff of Conservative Dentistry Department Faculty of Dentistry
Universitas Gadjah Mada, Yogyakarta.

ABSTRACT

Background : Caries that treated with imperfect restoration lead to secondary caries, it can irritate the pulp, causing pulp necrosis and even to cause abnormalities in the periapical tissue. Root canal treatment is the treatment of choice to deal with this case. Maxillary anterior teeth after root canal treatment requires restoration results with a high aesthetic level and also requires the intracanal retention that can support aesthetically restoration result. Fabricated fiber-reinforced composite post is a material that can meet the selection criteria. **Objective** : To report a case of root canal treatment with class IV cavity composite resin restorations with fabricated fiber-reinforced composite post in secondary caries with pulp necrosis with periapical lesion of left maxillary central incisor. **Case Management** : The 25-year-old male patient came to treat his upper left anterior tooth that have discoloured. Spontaneous tooth pain 1 year ago was also reported. Radiographs showed the cavity deep through the pulp canal. Root canal treatment and evaluation a week after that performed before cavity class IV composite resin restorations with fabricated fiber-reinforced composite post as final restoration had done. **Conclusion** : Proper case selection is the success key of a treatment. Fabricated fiber-reinforced composite post with composite resin restorations class IV cavity are an appropriate management option in this case to deal with maxillary central incisor which has a wide root canals and less loss of dental hard tissue that is not too much.

Keywords: *fiber-reinforced composite post, root canal treatment, composite resin restoration.*

Corresponding address : Betagia Swandhika Wisesa, betagia@gmail.com c/o Departemen Konservasi Gigi, Fakultas Kedokteran Gigi Universitas Gadjah Mada, Jl. Denta No.1 Sekip Utara, Yogyakarta, Indonesia

INTRODUCTION

Secondary caries is a carious lesion that begins on the edge of the restoration. Secondary caries can be caused by plaque retention in micro leakage between cavity walls and restoration edges, or adaptation with poor restorations so that the integrity of restoration with cavity walls is imperfect¹. Secondary caries is one of the main reasons patients come to the dentist to perform an existing dental restoration. If secondary caries is not immediate, secondary caries can cause irritation even to necrosis of the pulp and therefore require root canal treatment (RCT) ^{2,3}.

Root canal treatment causing a lot of dentin loss, so an adequate restoration with intracanal retention is needed. Nowadays, the development of dental material has improved. Formerly, post root canal treatment restoration was use metal dowel and crown as a final restoration which is not aesthetic. A metal restoration needs preparation that causing a lot of dentin loss. Post root canal treatment tooth will become weaker and more susceptible to fracture.

The development of post-RCT dental restorations and techniques has rapidly improved, especially in adhesive restoration systems, resulting in post-RCT restorations with increasingly popular composite resins⁷. The advantages of composite resin restorations are shorter visit times, lower costs, and require only minimal reduction of hard tissue of tooth. However, composite resins have poor mechanical resistance in post-RCT or tooth teeth in large pressure

areas⁸.

The use of fiber to support composite resin restorations has been used lately as an alternative to intracanal boosters. It also overcomes the deficiencies of composite resin restorations for post-RCT⁸. The fiber ribbon can adapt well to the root canal without the need to widen the root canal. Fiber base material consists of several types on the market such as polyethylene, carbon, and glass-fiber. Fiber polyethylene which has been waved into ribbon shape when applied together with composite resin creates an excellent dentin-dowel-core monoblock system⁷. The polyethylene fiber tape in addition strengthens the strength of the composite resin to impact, also improves the elastic modulus and flexural strength of the composite resin. The color of transparent polyethylene fibers also supports the creation of an aesthetic restoration especially for anterior teeth⁸. The purpose of this case is to report a case of root canal treatment with restoration of a class IV cavity composite resin with a fiber-reinforced composite fabric post in the maxillary left secondary incisor with pulp necrosis and periapical lesions.

CASE

The 22-year-old male patient came to the RSGM Dental Conservation Clinic. Prof. Soedomo FKG UGM want to replace the upper left front restoration that have changed color. Teeth were restored about 2 years ago. Patients also reported that the tooth had spontaneous pain 1 year ago. At

the time of examination, the tooth does not hurt. Based on the objective examination, the teeth 21 appear to be colored teeth that have undergone a color change on the mesial part (Fig. 1A). In the palatal view (Fig. 1B), there is a marginal gap between the teeth and the edges and the edges of the brown line surrounding the crater. Percussion, palpation, and vitality test results with chloretil showed negative results. Mobility tests also do not show any pathologic wobble. Good oral hygiene and first class molar occlusion relation of class I Angle. Normal gingival tissue state, with pink coral color with racial pigmentation of light brown on facial area, stippling texture, tapered gingival edge shape, and rubbery consistency. On radiographic examination (Figure 1C), it appears to be sticking to the mesial surface of the tooth with the radiolusen area along the slab margin located near the pulp. There is a diffuseradiolucen area in the periapical.

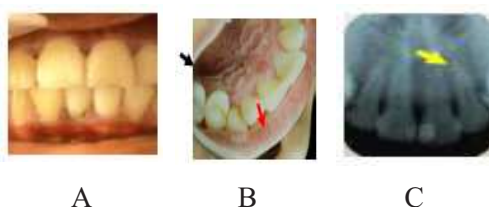


Figure 1. Initial photo of tooth 21. A) There appears a brownish black shadow on the mesio-incisal side of the tooth 21. B) On the palatal part there is a gap between the teeth with a fairly clear blow with the blackish brown on the slit indicated by the black arrow. C) Radiographic examination results show diffuse periapical lesions (yellow arrows)

as well as adjacent pulp patches and radiolucent areas along the margin of the crater (red arrow).

The diagnosis is secondary dental caries with pulp necrosis with periapical lesions. The treatment plan is RCT and restoration of a class IV composite resin with intracanal retention of fiber reinforced composite post. The prognosis is good, because the root canal is straight and there is no root canal constriction, the remaining hard tooth tissue can still be restored, good dental support tissues, relatively small periapical lesions, and cooperative patients.

CASE MANAGEMENT

A complete anamnesis, diagnosis, an explanation of the treatment plan, until the approval of a medical action is performed on the first visit. After the patient approves the informed consent, on the same day, scaling and record maxilla and mandible using irreversible hydrocolloid (Fine Normal Set, GC Corp.) are then filled with stone gypsum. The maxillary record are then recorded with putty prints (Exaflex, GC Corp.) to the incisal gears 12 to 23 (Fig. 2A), after setting is removed and used as a guidance for palatal and palatal guidance. Thereafter the work length measurement (22 mm) (Figure 2B), and the root canal preparation by crown-down technique using ProTaper Hand Use (Dentsply) with the last file size F2 and ended with K-File # 25. The root canal is then administered a calcium hydroxide medicament mixed

with glycerin and sealed with sterile cotton pellets and a temporary restoration. On the second visit, obturation of the root canal 21 was done using gutaperca (ProTaperGuttaPercha, Dentsply) and epoxy resin siler (Topseal, Dentsply). The results of obturation were examined by radiographic examination and the result of obturation was precise and hermetic (Fig. 2C).

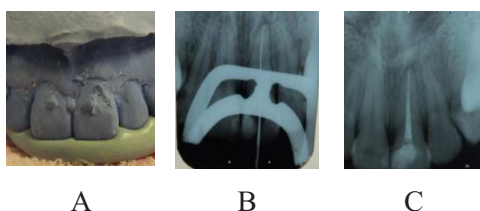


Figure 2. A) Printing model with putty to be used as palatal guidance. B) Measurement of working length. The file appears to be exactly on the length of work previously measured with apex locator (Raypex 6, VDW). C) Obturation radiograph showing the root canal is filled in hermetically.

Restoration of the tooth 21 was performed on the third visit by first selecting the appropriate tooth color according to the shade guide (Vitalumin, VITA Zahnfabrik), ie A2 color (Figure 3). Temporary restoration and old composite resin restoration are then disassembled. Then determined the length of the post canal of 18 mm in order to keep the remaining 4 mm of guttapercha in apical, and to determine the size of Peeso reamer to be used that is number 1 and 2. Guttapercha is taken by inserting the endodontic plugger which is heated and then continued the preparation using Peeso

reamer from the smallest to last size that has been determined. Then the post canal is dried with sterile paper points

The polyethylene fiber band (Construct, Kerr) is then prepared with a length of 3 times the length of the post canal of 54 mm. After that, the self-etch bonding material was applied to the post channel with the microbrush then dried with sterile paper points, and activated for 20 seconds. The same bonding material is also applied to the fiber band until wetted by bonding. The fiber band is then given a flowable composite resin (Construct Resin, Kerr) and flattened to a transparent color. Before the fiber bands are inserted in the post channel, the resin cement (RelyX™ U200, 3M ESPE) is applied first with lentulo. Then the prepared fiber ribbon is inserted into the post canal, using a finger spreader pressed slowly into the apical direction leaving a fiber band of 2/3 crowns in the coronal area. The fiber-reinforced composite ribbon residing in the crown is arranged like a core manufacture (Fig. 3). Then activated the light for 20 seconds.

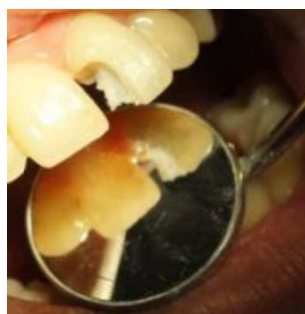

Figure 3. Installation of fiber-reinforced composite tooth post 21.

The restoration is then followed by the preparation of class IV composite resin restoration. All cavosurface margins in unfilled dentin enamel structures are beveled with a chamfer-shoulder design or also called hollowground bevel using a flame shaped diamond bur on the labial section with a depth of 1/2 - 1/3 the thickness of the enamel. The palatal section is prepared with a thickness of 1/2 - 1/3 the thickness of the enamel using a pear shape bur. After that etchant acid 37% (*DenFil™ Etchant-37, Vericom*) and bonding (*Stae, SDI Ltd.*) etching materials were applied and the installation of separating tape (IsoTape, TDV) in tooth 11. Then A2 color composite resin (Filtek Z250, 3M ESPE) was applied to the teeth at the palatal portion first with guidelines of the palatal guidance prepared on the first visit, formed with a plastic instrument to form the incisal shape (Fig. 4A.4B).

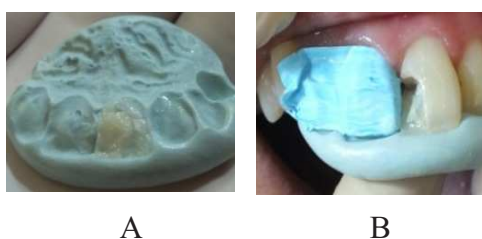

Figure 4. Filling using the guidance palatal guidance of pre-made putty record.

A) The composite resin is first formed according to the palatal shape present in the putty mold. B) Once formed is then applied to the tooth and afterwards it is activated by the light.

The proximal lining to form the embrasur begins with removal of the

palatal guidance, followed by attaching the selluloid strip until the sub-gingiva extends downward, then applied A2 shade composite resin (*Filtek Z250, 3M ESPE*), and 20 seconds of light activation. Then resumed with a Universal Dentin color shade composite resin (*Filtek Z250, 3M ESPE*) at the near end of the incisal of the scratch shape to create the impression of mamelon using plastis instrument, condensed and 20-second light activation. Furthermore, A2 color shade composite resin material (*Filtek Z250.3M ESPE*) is applied to all tooth surfaces and incisal, condensed to form the surface of the tooth using Comporoller (*Kerr*) and activated by 20 seconds. Completion and polishing of composite resin restorations using polishing disc (*OptiDisc, KerrHawe*) and polishing brush (*OptiShine, KerrHawe*). Patients were asked for control 1 week later. The restoration results are shown in Figure 5A.

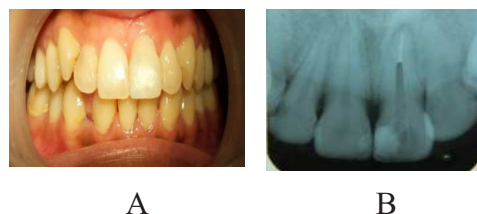

Figure 5. Checking during control. A) Facial tooth look 21 post restoration. The results of the restoration appear to be aligned and satisfactory. The gingival tissue around the tooth of 21 is normal without any sign of inflammation. B) The radiographic appearance at the time of control visit shows periapical tissue or periodontal ligament is normal.

DISCUSSION

The cause of the failure of composite resin restorations in this case is a leak between the restoration with the cavity wall. This causes the teeth to have secondary caries along the edges of the crater to cause pulp necrosis. So the tooth 21 requires root canal treatment before fixing the class IV composite restoration that the patient complained about.

The anterior teeth that have been treated for root canals may be fractured by several factors. In addition to its more fragile structure, the presence of oblique direction force may cause fracture of the anterior teeth post RCT⁹. If it will restore the anterior teeth post RCT, the consideration that should take precedence is the aesthetics and the adequate mechanical strength⁸. Metal-based intracanal retention does not enhance the post-RCT tooth structure that is fragile. The intracanal retention of the metal also serves only as an additional retention that supports the final retreat only. Preparation required before the insertion of intracanal retention of these metals can also be the cause of damage to the remaining hard tissue structure of the tooth and may increase the risk of root perforation. This deficiency has now been overcome with the use of fiber-reinforced composite system⁷. Fiber tape on fiber-reinforced composite systems can boost the mechanical strength of composite resins without reducing their aesthetics. Another advantage of using fiber ribbons is that when used as an intracanal retention, the fabricated fiber-

reinforced composite post adds strength to the restoration core and can also withstand fine occlusal forces⁸. Use of fabricated fiber-reinforced composite as post in this case through careful case selection. According to Oliveira et al.⁹, the use of fabricated fiber-reinforced composite followed by composite resin restorations is only indicated for cases with residual hard dental crown tissue with a high or still maximum height of hard tooth crown tissue of not less than 2-4 mm and having a thickness root canal walls and crown at least 2 mm after preparation. According to Garg and Garg¹⁰, other indications are for post-RCT cases that require high aesthetics without bad habits of bruxism or clenching. Patients with a high risk caries, or a difficult to control cavity moisture initially also contraindicated the use of fiber-reinforced composite. In this case, patients do not have bad bruxism habits, low caries risk, and moisture of the oral cavity can be well controlled. The remaining hard tissue of the tooth owned by the patient is also numerous so that the restoration of the composite resin with the intracanal fabricated fiber-post retention becomes the primary choice in the treatment of this case.

CONCLUSION

Selection of the right case is the key to the success of a treatment. The fabricated fiber-reinforced composite post with the restoration of a class IV cavity composite resin are a good option in this case to handle maxillary central incisor teeth with broad root canals and a lack of tough teeth.

Bibliography

1. Kidd EM. Diagnosis of secondary caries. J Dent Educ. 2001;65(10): 997-1000.
2. Mjör IA, Toffenetti F. Secondary caries : a literature review with case reports. Quintessence Int. 2000;31(3): 165-79.
3. Ghom AG. Textbook of Oral Radiology. New Delhi: Elsevier; 2008. p. 486-7.
4. Pramod JR. Textbook of Oral Medicine 3rded. New Delhi: Jaypee Brothers Medical Publishers (P) Ltd. p. 157-8.
5. Hoen MM, Frank E. Contemporary endodontic retreatments: An analysis based on clinical treatment findings. J Endod. 2002;28:834-7.
6. Fuss Z, Lustig J, Katz A, Tamse A. An evaluation of endodontically treated vertical root fractured teeth: impact of operative procedures. J Endod. 2001;27:46-8.
7. Deliperi S, Bardwell DN. Reconstruction of nonvital teeth using direct fiber-reinforced composite resin: a pilot clinical study. J Adhes Dent. 2009; 11(1):71-8.
8. Barutcigil C, Harorli OT, Yildiz M. Restoration of crown fractures with a fiberpost, polyethylene fiber and composite resin: a combined restorative technique with two case reports. RevClínPesqOdontol. 2009;5(1):73-7.
9. Oliveira SHG, Anami LC, Silva TM, Oliveira RS, Sales ALL, Oliveira AA. Intracanal post reinforcement in anterior teeth to prevent fractures. Braz Dent Sci. 2014; 17(3): 98-104.
10. Garg N, Garg A. Textbook of Operative Dentistry 2nded. New Delhi: Jaypee Brothers Medical Publishers (P) Ltd. p. 325-6.

CASE REPORT

RETROGRADE FILLING USING MINERAL TRIOXIDE AGGREGATE (MTA) AND BONE GRAFT (REGENERATIVE MATERIAL) PLACEMENT AFTER APICOECTOMY AS MANAGEMENT OF NON-SURGERY ENDODONTIC FAILURE IN RIGHT MAXILARY CENTRAL INCISOR WITH PERIAPICAL GRANULOMA

Budiono Wijaya¹ and Pribadi Santosa²

¹Resident of Conservative Dentistry

²Staff Department of Conservative Dentistry
Faculty of Dentistry, Gadjah Mada University
Yogyakarta - Indonesia

ABSTRACT

Endodontic treatment consist of non-surgery and surgery treatment. Non-surgery endodontic treatment failure can be caused by various factors, one of them is caused by persistence of bacteria. Case with big periapical lesion such as periapical granuloma have higher chance to fail because of extra-canal bacteria persistence. Surgery treatment is considered when non-surgery treatment fail. The example of surgery endodontic treatment is apicoectomy. Apicoectomy is an endodontic surgical procedure include the excision of the apical portion of the root and subsequent removal of attached soft tissues. Root-end filling using Mineral Trioxide Aggregate (MTA) and bone graft (regenerative material) placement is an additional procedure following apicoectomy. **Objective:** Aim of this study is to evaluate retrograde filling using Mineral Trioxide Aggregate (MTA) and bone graft placement after apicoectomy on right maxillary central incisor with periapical granuloma that have been endodontic treated and failed. **Case:** Patient, a 19-year-old woman, complained about her upper right front tooth which had been sore since one month after endodontic treatment. patient felt pain while she used her teeth to bite. Based on CBCT evaluation, there were a periapical lesion, radiolucent in the periapical (10,34mm x 12,87mm). Tooth was treated with apicoectomy continued with retrograde filling using MTA, bone graft placement and restored using direct veneer resin composite. **Result:** After two months of evaluation and surgical approach, there was resolution of periapical lesion. Patient never complained on her upper-right fronth tooth again and it could function properly. Mineral Trioxide Aggregate was used because it was easily manipulated, hydrophilic, and could induce tissue healing. **Conclusion:** Mineral Trioxide Aggregate as retrograde filling material and bone graft placement can be used as the management of big periapical lesion such as periapical granuloma.

Keyword: Mineral Trioxide Aggregate (MTA), bone graft, apicoectomy, periapical lesion.

Introduction

Surgical endodontics is a reliable method for the treatment of teeth with periapical lesions that do not respond to conventional root canal treatment. Successful outcomes have been reported in over 80% of cases. This high success rate may be due to modern surgical techniques, magnifying devices, microsurgery instruments, ultrasonic retrotips, and improved root end filling materials.[1]

The cause of apical periodontitis emerges from a pulpal inflammation that exceeds to a necrotic pulp which gives opportunity for bacteria from the oral environment to enter the pulp chamber and the root canal. This colonization inside the tooth results in a leakage of bacterial products, toxins, and/or bacteria's through the apical foramen causing an inflammatory reaction in the periapical tissue.[2]

Periapical granuloma is the reaction due to the microbial attacks and host response events, results in an apical granulation tissue, that is, periradicular bone resorption and degradation of the apical periodontal ligament. In some cases, periapical granuloma can be managed by non surgical endodontic treatment. But, in some cases that have persistent bacterial, apicoectomy surgery is indicated for the management. [2]

Review of literature supports that mineral trioxide aggregate (MTA) due to its higher biocompatibility and sealing ability promotes better healing of the tissues when

placed in contact with the dental pulp or periradicular tissues over the available root end filling materials. Bone graft material as regenerative material is also important to use if the periapical lesion size is bigger than 0,5 cm. [3]

The purpose of this article is to evaluate Mineral Trioxide Aggregate (MTA) as retrograde filling and bone graft (regenerative material) placement after apicoectomy on the right maxillary central incisor that have big persistent periapical lesion (periapical granuloma).

Case

A 19-year-old woman came to clinic of Conservative Dentistry of RSGM Prof Soedomo, Faculty of Dentistry, Universitas Gadjah Mada, Yogyakarta. She complained about tooth ache on her upper right front incisor since one month ago. The pain came if the tooth have been contaced with the lower teeth or bite something. Her tooth was endodontically treated around 1 months ago, and the pain is not subsided after nonsurgical endodontic treatment.

Clinically, there was access cavity that left opened on the palatal aspect of maxillary central incisor (fig.1B). Radiographic examination showed a radiolucent area (periapical lesion) with well-defined border and the diameter is about 1 cm. There was also a radiopaque area on coronal of the teeth (composite restoration) (fig.1C). From CBCT evaluation, periapical lesion diameter was 10,34mm x 12,87mm and apex was open.

(fig.2A).

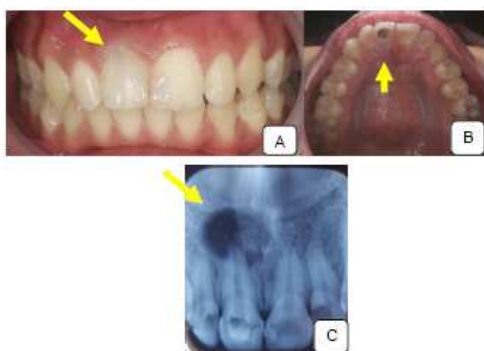


Fig. 1. A. Clinical photograph from labial aspect showed the tooth's colour was darkened, B. Access cavity that left opened on the palatal aspect of the tooth, C. Radiograph examination show there was a radiolucent area with well defined border and the diameter was around 1 cm.

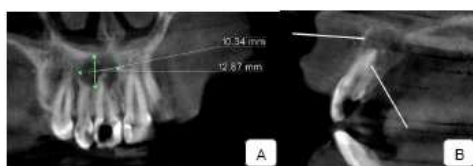


Fig. 2. A. CBCT Interpretation (coronal view) show the size of periapical lesion (10,34mm x 12,87mm) and the apex was open. B. CBCT Interpretation (axial view) show that palatal and labial bone was resorbed and thin.

Case Management

The treatment planning was root canal preparation, orthograde obturation with gutta percha, retrograde filling using MTA and bone graft placement after apicoectomy, and direct veneer resin composite restoration. Patient had no systemic disease and history of allergic reaction.

For the first appointment, anamnesis, clinical examination, radiograph (periapical, panoramic and CBCT) and clinical photography was done. In the next appointment, operator did root canal preparation with step back technique, root canal obturation and apicoectomy. Apicoectomy procedure start with disinfection of surgical area with iodine solution, and local anesthesia with pehacaine. An infiltration anesthesia was performed on the alveolaris superior anterior and nasopalatinus nerve. The flap design was a trapezoid flap. Incisions was did by scalpel #15 (fig.3A) and was dissectioned with raspatorium. The labial bone was opened using a round bur. After this procedure, obturation material and all pathological tissues was removed by curettage. The root end was resected approximately 1 mm of the total root length with a fissure bur and beveled at a 0-10° angle to the long axis of the tooth (fig.3B). The cavity might be prepared with a round microbur for retrograde filling material. Mineral Trioxide Aggregate (MTA) as retrograde filling material was placed on prepared cavity using hand instrument (fig.3C). Finally, bone graft and membran graft was placed on the cavity (fig.3D) and the flap was repositioned with simple interrupted suture (fig.3E). The operation area was covered with periodontal dressing.

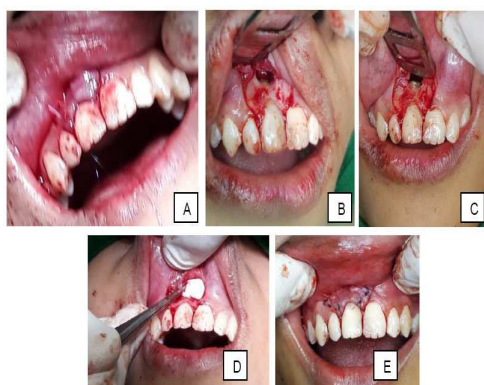


Fig. 3. Trapezoid flap design (A). After removal of infected hard,soft tissue, root resection and bevel(B). Retrograde filling using MTA (C). Bone graft and membran graft placement (D). Flap repositioned with simple interrupted suture (E).

After the surgical procedures, radiographs were taken to verify the quality of the root-end treatment (Fig.4A). The patient was received antibiotics and analgetics-antiinflammations. A follow up evaluation was performed after 7 days (Fig. 4B) to hecting up the suture. The next evaluation was performed after 1 month (fig.4C), 2 months (fig.4D), to confirmed the clinical and radiograph aspects.

Discussion

Treatment of periapical granuloma mainly consist of root canal therapy with or without subsequent apicoectomy. If the initial conventional therapy is unsuccessful, endodontic retreatment represent the best approach for total elimination of bacteria and should be considered before periapical surgery. In this case, root canal has already been prepared and dressed with calcium

hydroxide, but the symtomp did not subsided. In this case, apicoectomy is the treatment choice for preserve the tooth.[4]

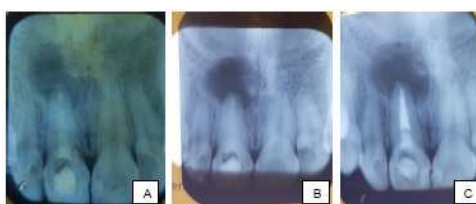

Fig. 4. Periapical radiographic images showed retrograde filling using MTA. (A). Follow up evaluation showed tissues healing after 7 days (B), and 1 month (C).

Apicoectomy is the surgical resection of the root tip of a tooth and its removal together with the pathological periapical tissues. When the size of the lesion is large,the trapezoid flap was chosen as flap design for better visualization. After the flap was retracted, it was continued with osteotomy, removal of cortical plate to expose the root end. [5]

Tip of the root was resected approximately 1 mm of the total root length with a fissure bur and beveled at a 0-10° angle to the long axis of the tooth. Advantages of a zero degree bevel are exposure of fewer dentinal tubules, maintains maximum root length, reduced osteotomy size, and lesser apical leakage [5]. All pathological tissues was removed by curettage. After root resection, a retrocavity is prepared with a small round bur or of an inverted cone bur in an angled micro-handpiece and retrofilled with the root-end obturation material [6].

Numerous materials have been recommended for root-end obturation, and many studies have attempted to identify an ideal material. The most commonly used materials are mineral trioxide aggregate (MTA) and IRM. Recent studies show that although MTA achieved the most favorable healing response, both radiographically and histologically, these results were not statistically different from IRM. Mineral trioxide aggregate is a bioactive inorganic compound consisting of calcium silicate, calcium aluminate, calcium aluminoferrite, calcium sulfate, and bismuth oxide. Although MTA is an expensive material, it has major advantages. The advantages are including excellent biocompatibility, ideal adherence to the cavity walls, low solubility, and induce cementogenesis at the cut root face with deposition of new cementum onto the exposed dentin and MTA surfaces. Mineral trioxide aggregate also has good physical and biological properties, and it being hydrophilic in nature [7].

After retrofilling the root, bone graft and membran graft placement is indicated in this case. Periapical lesion that bigger from 0,5 cm might need some regenerative material to induce osteoformation. The example of regenerative material is bone graft. Bone graft (hydroxiapatite) will act as a filling materials as well as a scaffold, which gradually gets resorbed while preosteoblasts and osteoblasts migrate from the adjacent bone (Osteoconduction). Bone grafts was also used to fill the bony space

in case of large bony defects to prevent the soft tissue in-growth. Membran graft was used to hold the bone graft material in cavity. [8]

The treatment outcome of apical surgery should be assessed clinically and radiographically. Clinical assesment is based on the resolution of signs and symptoms such as pain, swelling, and tenderness to palpation or percussion. Radiological examination should be conducted at annual intervals until healing is observed. Periapical radiographs should be taken, endeavouring to achieve the same angulation as the pre-operative view to allow accurate comparison. In this case, clinically and radiographically it appears to be healing. Clinically, there is no complaints of pain experienced by the patient. [9]

Conclusion

Apicoectomy is the treatment of choice when nonsurgical endodontic treatment fail to manage the case. In large periapical lesion, persistent bacteria is commonly present and cause the failure of conventional endodontic treatment. The use of MTA as a retrograde filling material has many advantadges and results in good healing after several months after apiectomy based on clinical and radiological examination. Regenerative material such as bone graft is also considered to use when periapical lesion is bigger than 0,5 cm. Bone graft will act as

scaffold to osteoformation and prevent the soft-tissue healing formation.

Acknowledgement

The author are grateful to drg. Pribadi Santosa, M.S., Sp.KG (K) and drg. Wignyo Hadriyanto, M.S., Sp.KG (K) as faculty supervisor for providing invaluable guidance throughout the whole operating process and . And also to the patient for allowing the case to be presented.

References

1. Apaydin E.S., Torabinejad M. The effect of calcium sulfate on hard-tissue healing after periradicular surgery. *J. Endod.* 2004;30:17–20.
2. S. Setzer and P. Krasner, “Periapical granuloma and radicular cyst,” in *Endodontology. Biologic Considerations in Endodontic Procedures*, S. Setzer, Ed., pp. 195–236, Lea & Febiger, Philadelphia, Pa, USA, 2nd edition, 1988.
3. Bernabé P.F., Gomes-Filho J.E., Cintra L.T., Moretto M.J., Lodi C.S., Nery M.J., Otoboni Filho J.A., Dezan E. Histologic evaluation of the use of membrane, bone graft, and MTA in apical surgery. *Oral Surg. Oral Med. Oral Pathol. Oral Radiol. Endod.* 2010;109:309–314.
4. Sebastian A., Panikar P., Kota K., and Sasi A. 2016. Periapical Granuloma. *Int J Prev Clin Dent Res* 2016;3(1):35-37.
5. Gagliani M.M., Gorni F.G., Strohmenger L. Periapical resurgery versus periapical surgery: a 5-year longitudinal comparison. *Int. Endod. J.* 2005;38:320–327.
6. Gray G.J., Hatton J.F., Holtzmann D.J., Jenkins D.B., Nielsen C.J. Quality of root-end preparation using ultrasonic and rotary instrumentation in cadavers. *J. Endodont.* 2000;26:281–283.
7. Locurcio LL, Leeson R. A case of periradicular surgery: apicoectomy and obturation of the apex, a bold act. *Stomatological Dis Sci* 2017;1:76-80.
8. Bashutski J.D., Wang H.L. Periodontal and endodontic regeneration. *J. Endod.* 2009;35:321–328.
9. Kim E., Song J.S., Jung I.Y., Lee S.J., Kim S. Prospective clinical study evaluating endodontic microsurgery outcomes for cases with lesions of endodontic origin compared with cases with lesions of combined periodontal–endodontic origin. *J. Endod.* 2008;34:546–551.

LITERATURE REVIEW

EFFECTIVENESS DIODE LASER AS ADDITIONAL DEVICE ON ROOT CANAL DISINFECTICION

Chitra Iselinni¹, Ratna Meidyawati²

¹Resident, Department of Conservative Dentistry, Faculty of Dentistry, Universitas Indonesia, Jakarta, Indonesia

²Lecturer, Department of Conservative Dentistry, Faculty of Dentistry, Universitas Indonesia, Jakarta, Indonesia
chitra.iselinni@gmail.com

ABSTRACT

Disinfection of the root canal system is an important stage for successful root canal treatment. Traditionally, root canal disinfection is achieved by a combination of mechanical instrumentation, the use of disinfection irrigation solutions and the placement of medicaments between visits. The irrigation solution works by direct contact with the target and has limited penetration depth into the root canal system. Therefore, the irrigation solution is unable to eliminate the microorganisms from the deeper dentine layers. Over the last few decades, various devices have been developed to improve penetration and effectiveness of irrigation in the peripheral areas of the root canal. One of the root canal disinfected devices that began to be developed was with the use of lasers. There are various types of lasers that exist in the field of dentistry, one of which is a diode laser. Laser diodes in endodontics are an innovative approach to root canal disinfection because it has the ability to penetrate into the dentin. Keywords: irrigation solution, disinfection, laser diode

INTRODUCTION

Endodontics is a branch of dentistry associated with the prevention, diagnosis and treatment of dental pulp pathoses.¹ Pulp and periapical abnormalities occur due to invasion of microorganisms into the hard tissue of the tooth and progress further until it reaches the root canal system.² The main goal of root canal treatment is the

elimination of microorganisms and their products and pathological debris from the root canal system to prevent re-infection.^{3,4}

Root canal contamination by microorganisms and remaining necrotic soft tissue is considered a major cause of root canal treatment failure.⁵ At least 300 species of different microorganisms are found in root canal infections.⁶ The

eradication of deep microorganisms in the tubular system is a major and very important challenge in long-term dental care with root canal treatment.⁵

Endodontic treatment procedures rely on mechanical instrumentation, irrigation and medicament solutions between visits for disinfection of the root canal system.⁶ The use of an irrigation solution is an important step because it can help eliminate unaffected microorganisms during root canal preparation.¹ However, irrigation solution works by direct contact with the target and has a limited depth of penetration into the root canal wall, so that the irrigation solution is not capable of eliminating the microorganisms from the deeper dentine layers.⁷ This is the reason for using a combination of disinfection solutions with irrigation devices. Traditionally, the irrigation solution is delivered into the root canal through an irrigation needle. The problem with the irrigation needle technique is the replacement of irrigation along the root canal is inadequate, because the highest flow rate is only found in the lumen of the needle and around the needle tip.⁸

Although the use of an irrigation solution may decrease the number of microbes in the infected root canal, it fails to achieve the total disinfection goal of the root canal system. Therefore, root canal disinfection is a major challenge in endodontics and a fundamental principle important for long-term preservation of teeth with root canal treatment. The use of

lasers in the endodontic field is a method developed to meet these challenges. In general, dental lasers provide access to tubular systems previously unattainable by irrigation solutions.⁶

There are various types of lasers that exist in the field of dentistry, one of which is a diode laser. The diode laser in the endodontic is an innovative approach to root canal disinfection because it has the ability to penetrate into the dentin.³ This laser is an option because of some advantages. Among others have a relatively small size compared to other lasers and easy to use.⁵ The antimicrobial effect of the laser depends on the dose of heat generated.⁸

The effectiveness of laser antimicrobials against microorganisms has been demonstrated in previous studies. However, based on several studies indicating that the laser alone is no more effective when compared to the irrigation solution.⁸ Baz and his colleagues conducted an in-vitro study in 2012 to 60 single-rooted teeth. The study compared the effectiveness of root canal disinfection between the use of laser diodes, sodium hypochlorite irrigation solutions, and a combination of laser diodes with sodium hypochlorite. The results showed that disinfection using sodium hypochlorite irrigation solution eliminated more bacteria than laser disinfection. However, test group disinfection of sodium hypochlorite combinations with lasers showed significantly greater amounts of bacterial elimination.^{5,9}

Another study of the diode laser against bacteria by Kaiwar and friends in 2013 also gave the same results. The laser beam of the diode with the irrigation solution produces the highest rate of root canal disinfection when compared with disinfection using only irrigation solution or diode laser alone. In the study obtained statistically significant differences.⁵

In recent years, research on root canal disinfection techniques has improved, one of which is root canal disinfection with additional laser diodes.⁸ Numerous studies suggest that the combination of sodium hypochlorite irrigation solution with a laser diode provides a synergistic effect and can eliminate migrating bacteria to the deeper layers of dentin. Therefore, laser diodes combined with an irrigation solution are able to eliminate more bacteria in order to increase the success of root canal treatment^{5,9}. Therefore, in this paper we will discuss the use of laser diodes as a disinfection enhancer in root canal treatment.

REVIEW

a. Root Canal Treatment

Root canal treatment is a procedure that aims to eliminate the microorganism causing the infection to form an environment in the root canal system that allows the healing process and maintenance of periapical tissue health.¹⁰ This goal can be achieved through the principle of endodontic triads. Endodontic

triads consist of access preparation, root canal preparation and root canal filling. Access preparation plays an important role in determining the next two stages. Good access preparation can provide localization, root canal formation and cleansing, disinfection and filling of the root canal system.¹¹

Root canal preparation was done chemomechanically. After mechanical instrumentation, there are a number of untouched root canal areas, either by the use of manual techniques or rotary instrumentation.⁸ Therefore, the irrigation solution is used to reach the untouched area. The irrigation solution also has antimicrobial properties as part of the root canal disinfection stage.¹²

The final stage of the endodontic triad is the filling of the root canal. Root canal filling is done to prevent microorganisms and tissue fluid from entering the root canal system that has been done chemomechanical preparation. It is expected to support the healing process and maintain healthy periapical tissue.¹³

b. Irrigation as root canal disinfection

When microorganisms are in the root canal, it will be hard to achieve by the body's defense mechanism. Therefore, root canal infection removed by root canal treatment through mechanical procedure with additional chemical such as irrigation is an important stage in chemomechanical preparation.^{14,15} The objective of chemomechanical disinfection is to kill

microorganisms, remove dentine debris, dissolve organic and inorganic components that cannot be achieved by mechanical exhaust and as an irritant lubrication in biological tissues.^{15,16}

Root canal disinfection using an antimicrobial irrigation solution and tissue solvent as an essential part of the chemomechanical debridement. Irrigation is a complementary instrumentation that facilitates the disposal of microorganisms, debris and necrotic tissue, especially from unprepared areas.¹⁷ The ideal irrigation solution has antimicrobial activity properties, is capable of dissolving organic tissue waste, root canal disinfection, discharges debris from an instrumented root canal, lubrication, and has no cytotoxic effect on periradicular tissue.¹⁸

c. Diode Laser

In 1960, Theodore Maiman was a scientist who developed the first laser device using a ruby crystal. A few years later,. Laser stands for Light Amplification by Stimulated Emission of Radiation.¹⁹

Light Amplification by Stimulated Emission of Radiation or Laser, indicating an energy transmission and not. The laser-emitted light is the result of a process

called stimulated emission. Laser is a form of energy in the form of particles called photons and moves in the form of electromagnetic waves.^{20,21} Wavelength measurements are important for laser light, because they can determine how the laser beam is toward the target and the tissue reaction to a particular wavelength. The wavelength is measured in meters (m).²⁰

Among the various lasers that emerged in the mid-1990s, diode lasers also debuted.²² Laser Diodes are one of the most widely developed types of lasers in the science of dentistry and the like with semiconductor active media that can be made of aluminum, gallium, arsenide and indium.^{9,23} Laser diodes are available in four different wavelengths, ie laser diodes with wavelengths of 810 to 830nm, 940nm, 980nm and 1064nm.⁹

Laser diodes can be used in various dentistry procedures. In the diode under use, periodontal pocket therapy, crowning equilibrium, inflamed tissue, phrenectomy and photostimulation of herpetic lesions.^{22,23} Laser diodes can also be applied to procedures involving hard tissues such as teeth. One of these is in endodontic treatment such as root canal disinfection.^{22,24}

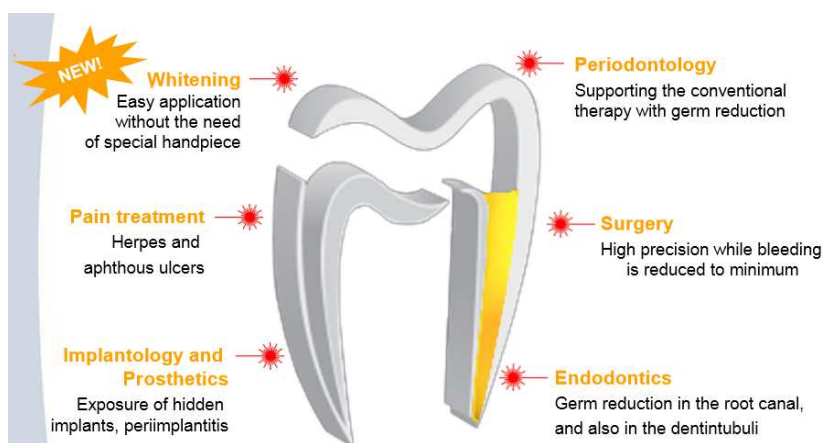


Figure 1. Various applications of Diode Laser in dentistry.²⁴

Some of the advantages of diode lasers are the small size and flexibility to a wide range of treatment applications including extensive use in different areas of dentistry (figure 1).^{22,24} The relatively small size of the diode laser also provides other benefits, requiring a relatively small area of the workspace and good portability that are easy to transport and relatively light.²²

d. Application of diode laser

Laser diodes use flexible glass fibers to channel energy to the desired target area. Generally, a flexible glass fiber is inserted into the handpiece so it can be applied to the tissue. There are several things to consider when using glass fiber, such as the selection of fiber diameter to be used. The flexible glass fiber in the diode laser is available in diameters of 200-320 μm . The size of glass fiber diameter of 200 μm is equivalent to file size 20.²² The thin glass fiber diameter allows the delivery of laser light directly into the root canal so as to effectively provide disinfection effect.⁵

In addition to diameter, which is useful to noting is the speed of movement of the fiber end during treatment. Burned tissue are an unwanted side effect due to excessive force or movement of the fiber ends too slowly.²² The glass fiber is placed 2mm from the working length, then with the circular motion moving from apical to corona. The movement aims for the laser beam to reach the overall root dentine (figure 2).^{15,22}

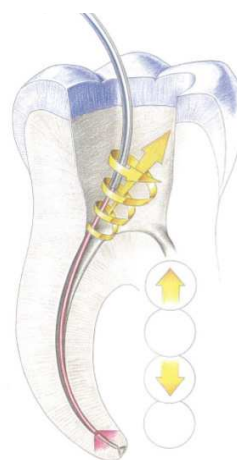


Figure 2. Glass fibers are pulled from apical to coronal evenly with circular motion.¹⁵

DISCUSSION

The elimination of bacteria in the inner dentin layer is a challenge and will affect long-term maintenance of root canal treatment. The irrigation solution applied during conventional root canal treatment works through direct contact with bacteria. Due to the limited depth of penetration the irrigation solution causes bacteria that are in the dentine layer in not affected by the disinfection effect.²⁵

The diode laser disinfection effect can be ascribed to the diode laser penetration capability of up to 1,000 μm into the dentin tubule. This is very different when compared to root canal disinfection using a finite irrigation solution penetrating up to 100 μm , whereas the penetration of microorganisms can reach a depth of 1000 μm (figure 3). The diameter of the dentinal tubules decreases significantly in the deeper dentin layers, so the penetration of the irrigation solution is limited. Laser rays with properties and characteristics, as well as increased local intensity, allow laser light to penetrate into the dentine tubules and affect the effectiveness of antimicrobials.^{15,26,27}

Chemical disinfectant	Bacteria	Laser
100 μm	~1,110 μm	> 1,000 μm

Figure 3. Depth of penetration of irrigation materials, bacteria and laser light.¹⁵

The introduction of laser in the field of endodontics has increased the effectiveness and success of root canal treatment. In general, dental lasers provide accessibility to the dentin tubule system so that better penetration can be achieved.²⁵ Root canal disinfection using laser diodes is a new approach in the endodontic field. Laser beams are considered capable of reaching areas that are unattainable by traditional techniques. The bactericidal effect of the diode laser is obtained from the resulting heat dose. The effectiveness of antimicrobial lasers against different microorganisms has been demonstrated in previous studies. However, based on several studies indicating that the laser alone is no more effective when compared to the irrigation solution.⁸

Baz and his colleagues conducted an in-vitro study in 2012 to 60 single-rooted teeth. The study compared the effectiveness of root canal disinfection between the use of laser diodes, NaOCl solutions, and the combination of diode lasers with NaOCl. The results showed that disinfection using NaOCl irrigation solution eliminated more bacteria when compared with disinfection using laser diode. However, the test group of NaOCl combination disinfection with laser diodes showed significantly greater amounts of bacterial elimination. The combination of the NaOCl irrigation solution with the diode laser provides a synergistic effect and can eliminate the migrating bacteria in the deeper layers of dentin. Therefore, laser diodes combined

with an irrigation solution are able to eliminate more bacteria in order to increase the success of root canal treatment.^{5,9}

The temperature 7°C is considered the highest biologically acceptable temperature threshold to prevent periodontal damage.¹⁹ Several studies have concluded that the use of a 980nm diode laser for root canal treatment results in an increase in temperature at the external root surface. Hmud et al (2010) in his study found that the highest increase in temperature on the external root surface after the use of a diode laser with an irrigation solution was 4°C. Irrigation solutions are considered effective in minimizing thermal changes in the root canal and external root surfaces²⁸. In the same year, another study by Hmud et al gave results that the 980 diode laser was able to induce cavitation on water-based media through the formation and explosion of water vapor.²⁹

The pressure waves generated by the diode laser are thought to play a role in clearing debris in the root canal. This is derived from the diode laser's ability to generate pressure waves and form cavitation. Cavitation is the formation of vapor bubbles in the liquid. This process causes the formation of pressure waves characterized by rapid changes in pressure and high amplitude. The pressure of the bubbles produces an explosion that affects the surface, causing shear forces, surface deformation and material release at the surface. In the root canal, the bubble pressure has the potential to damage the

biofilm of the microorganism, rupture the cell wall of the microorganism and release the smear layer and debris. Bubble pressure can also improve the solution of the irrigation solution thus increasing the ability of disinfection.²⁹

CONCLUSION

The main goal of root canal treatment is disinfection of the root canal system from bacteria that cause pulp or periapical abnormalities. When bacteria infect the pulp tissue, the bacteria also penetrate into the deeper dentine root layer. The eradication of bacteria deep in the tubular system is a major challenge and an important part of the long-term maintenance of teeth with root canal treatment.

The irrigation solution applied during conventional root canal treatment works by direct contact with the target bacteria. However, the effect of irrigation solution is only limited to the most superficial layers of root dentin due to the limitation of penetration ability of the irrigation solution, so that bacteria in the deeper dentine layer are not affected by the disinfection effect. Considering the weakness of the irrigation solution in root canal treatment, new methods have been developed to obtain effective root canal clearance, one of which is the laser.

Lasers are the latest choice in combating root canal microorganisms, especially in deep dentine tubules. Different types of lasers are emerging, one of which is the diode laser which is the

most popular type of laser because of its penetration ability and antibacterial effect and its size is relatively small compared to other types of lasers.

The antimicrobial effect of the laser depends on the dose of heat generated. Based on several studies it has been proven that the laser alone is no more effective than the irrigation solution. However, the combination of irrigation and laser diode solutions resulted in significantly better disinfection. Therefore, the diode laser is effective as a root canal disinfection device because the irrigation solution combined with the diode laser has been shown to have a synergistic effect and can eliminate migrating bacteria to the deeper layers of dentin.

REFERENCES

1. Garg N, Garg A. *Textbook of Endodontic*. 3rd ed. India: Jaypee Brothers Medical Publishers; 2014.
2. Mathew J, Emil J, Paulaian B, John B, Raja J, Mathew J. Viability and antibacterial efficacy of four root canal disinfection techniques evaluated using confocal laser scanning microscopy. *J Conserv Dent*. 2014;17(5):444-448.
3. Jonathan R, Mathew J, Suganthan P, Samuel A, John B. Comparative Evaluation of the Antibacterial Efficacy of Four Different Disinfection Techniques in Minimally Instrumented Experimentally Infected Root Canals: An in vitro Study. *Int J Laser Dent*. 2013;3(2):49-54.
4. Shenoy A, Mandava P, Bolla N, Raj S, Kurien J, Prathap M. Antibacterial efficacy of sodium hypochlorite with a novel sonic agitation device. *Indian J Dent Res*. 2013;24(5):537-541.
5. Kaiwar A, Usha H, Meena N, Ashwini P, Cs M. the efficiency of root canal disinfection using a diode laser: in vitro study. *Indian J Dent Res*. 2013;24(1):14-18.
6. Onay E, Alikaya C, Seker E. Evaluation of antifungal efficacy of Erbium, Chromium:Yttrium-Scandium-Gallium-Garnet Laser against *Candida albicans*. *Photomed Laser Surg*. 2010;28(1):73-78.
7. Mehrvarzfar P, Saghiri M, Asatourian A, et al. Additive effect of a diode laser on the antibacterial activity of 2,5% NaOCl, 2% CHX and MTAD against *Enterococcus faecalis* contaminating root canals: an in vitro study. *J Oral Sci*. 2011;53(3):355-360.
8. Bago I, Plecko V, Panduri D, Schauerl Z, Baraba A, Anic A. Antimicrobial efficacy of a high-power diode laser, photo-activated disinfection, conventional and sonic activated irrigation during root canal treatment. *Int Endod J*. 2013;46:339-347.
9. Baz P, Biedma B, Pinon M, et al. Combined Sodium Hypochlorite and 940 nm Diode Laser Treatment Against Mature *E. Faecalis* Biofilms in-vitro. *J lasers Med Sci*.

- 2012;3(3):116-121.
10. Garg N, Garg A, eds. Introduction and Scope of Endodontics. In: *Textbook of Endodontics*. 3rd ed. New Delhi: Jaypee Brothers Medical Publishers; 2014:1.
11. N G, Garg A. Internal Anatomy and Access Cavity Preparation. In: N G, Garg A, eds. *Textbook of Endodontics*. Malaysia: UNIPRESS Publishing; 2008:143.
12. Garg N, Garg A, eds. Irrigation and Intracanal Medicament. In: *Textbook of Endodontics*. 3rd ed. New Delhi: Jaypee Brothers Medical Publishers; 2014:211-216.
13. N G, Garg A. Obturation of Root Canal System. In: N G, Garg A, eds. *Textbook of Endodontics*. UNIPRESS Publishing; 2008:208.
14. Siqueira J, Machado A, Silveira R, Lopes H, Uzeda M. Evaluation of the effectiveness of sodium hypochlorite used with three irrigation methods in the elimination of *Enterococcus faecalis* from the root canal, in vitro. *Int Endod J*. 1997;30:279-282.
15. Moritz A, Schoop U. Laser in Endodontics. In: Beer F, Goharkhay K, Schoop U, et al., eds. *Oral Laser Application*. berlin: Quintessenz Verlags-GmbH; 2006:241-298.
16. Gomes B, Ferraz C, Vianna M, Berber V, Teixeira F, Souza-Filho F. In Vitro antimicrobial activity of several concentration of sodium hypochlorite and chlorhexidine gluconate in the elimination of *Enterococcus faecalis*. *Int Endod J*. 2001;34:424-428.
17. Rodig T, Sedghi M, Konietzschke F, Lange K, Ziebolz D, Hulsmann M. Efficacy of syringe irrigation, RinsEndo and passive ultrasonic irrigation in removing debris from irregularities in root canals with different apical sizes. *Int Endod J*. 2010;43:581-589.
18. Rajeshwari, Kamath P, Kundabala M, Shenoy S, Hegde V, Thukral N. An evaluation of horizontal depth of penetration of various irrigants into the dentinal tubules when used alone and in combination with diode laser : An in vitro study. *J Interdisciplinary Dent*. 2014;4(3):130-134.
19. Pradhan S, Kamik R. Temperature Rise on External Root Surface during Laser Endodontic Therapy using 940 nm Diode Laser : An in vitro Study. *Int J Laser Dent*. 2011;1(1):29-35.
20. Coluzzi D, Convissar R, Roshkind D. Laser Fundamentals. In: Convissar R, ed. *Principles and Practice of Laser Dentistry*. 2nd ed. St. Louis, Missouri: Elsevier Mosby; 2016:12-15.
21. Nugrohowati, Tananda H. Aplikasi sinar laser di bidang kedokteran gigi. *J Imiah dan Teknol Kedokt Gigi*. 2009;6(1):6-8.
22. Pirnat S. Versatility of an 810 nm Diode Laser in Dentistry : An Overview. *J laser Heal Acad*. 2007;4:1-8.

23. Verma S, Maheshwari S, Singh R, Chaudhari P. Laser in dentistry : An innovative tool in modern dental practice. *Natl J Maxillofac Surg.* 2012;3(2):124-132.
24. Fona Laser Introduction. <http://domdent.husitesdefaultfiles/FONALaser-laser-introduction-2-6-2011.pdf> FONALaser laser introduction.
25. Schoop U, Kluger W, Moritz A, Nedjelik N, Georgopoulos A, Sperr W. Bactericidal effect of different laser systems in the deep layers of dentin. *lasers surg med.* 2004;35:111-116.
26. Hegde M, Bhat R, Shetty P. efficiency of a semiconductor diode laser in disinfection of the root canal system in endodontics : an in vitro study. *J Int Clin Dent Res Organ.* 2015;7(1):35-38.
27. Asnaashari M, Asnaashari N. Clinical Application of 810nm Diode Laser and Low Level Laser Therapy for Treating an Endodontic Problem. *J lasers Med Sci.* 2011;2(2):82-86.
28. Hmud R, Kahler W, Walsh L. Temperature Changes Accompanying Near Infrared Diode Laser Endodontic Treatment of Wet Canals. *J Endod.* 2010;36(5):908-911.
29. Hmud R, Kahler W, George R, Walsh L. Cavitation Effects in Aqueous Endodontic Irrigants Generated by Near-infrared Lasers. *J Endod.* 2010;36(2):275-278.

APICAL RESECTION: AN ALTERNATIVE MANAGEMENT OF LARGE PERIAPICAL CYST

Clarrisa Fredline*, Ari Subiyanto**

*Resident of Conservative Dentistry

**Staff of Conservative Dentistry

Departement of Conservative Dentistry

Faculty of Dental Medicine, Airlangga University

Surabaya, Indonesia

*Clarrisa Fredline, Phone : +62821703635777,

Email : clarrisafredline@gmail.com

ABSTRACT

Background: Necrotic tooth with periapical cyst is one of the most common problem in endodontic. Periapical cyst causes destruction of surrounding tissue. Management of necrotic tooth with periapical cyst can be done with apical resection procedure. Apical resection procedure can assure adequate sealing of the apical. This procedure can reduce the risk of the failure in endodontic treatment. **Case:** 23-years old female come to Departement Of Conservative Dentistry, Airlangga University with the chief complaint of caries in the upper anterior tooth. The tooth sometimes causes pain. Radiographic examination reveal a large periapical cyst in the right lateral incisor. **Case Management :** Preparation of the tooth using rotary instrument and orthograde obturation using gutta perch was the first treatment. The next treatment plan was apical resection. During the surgery, apical part of the root was cut and removal of gutta percha in apical was done using ultrasonic with retreatment tip. This process was followed by obturation using MTA retrogradely. Bonegraft and membran placement was the next important step to heal bone destruction. The tooth then restored with fibre post and all porcelain crown.. **Conclusion:** Management of tooth with large periapical cyst with apical resection can provide satisfactory result.

Keyword : Necrotic tooth, Periapical Cyst, Apical resection

Correspondence : Clarrisa Fredline, Resident Of Conservative Dentistry, Airlangga University. Email: clarrisafredline@gmail.com

Introduction

A periapical cyst originated from epithelial cell rests of Malassez which proliferate by an inflammatory response originating from pulpal necrosis of a non-vital tooth. It is usually associated with endodontic infection in non vital tooth. Periapical cyst is usually asymptomatic, but

can result in a slow-growth tumefaction in the affected region. Radiographically, the description of the lesion is a round or oval, well-circumscribed radiolucent image with corticated margin involving the apex of the infected tooth¹.

Management of periapical cyst can be divided into non-surgical and surgical

treatment. Some authors support that when endodontic infection is eliminated, the immune system will be able to promote healing of the lesion, while other believe that surgical intervention is invariably necessary to promote healing of the lesion¹. Non-surgical treatment is based on orthograde root canal treatment. A surgical approach is only indicated when it is agreed that orthograde retreatment is either not possible or will not solve the problem². When conservative treatment is not possible because of post with crowns, bridges and consideration of the possibility of weakening of the remaining dental hard tissues, there are reasons for undertaking apical surgery. This can be defined as endodontic-surgery procedures that include apical resection, curettage and retrograde filling².

Apical surgery belongs to the field of endodontic surgery, which also includes incision and drainage, closure of perforations, and root or tooth resections. The objective of apical surgery is to prevent bacterial leakage from the root-canal system into the periradicular tissues by placing a tight root-end filling following root-end resection. The most important step in apical surgery is to identify possible leakage areas at the cut root face and subsequently to ensure adequate root-end filling. Only a tight and persistent apical obturation will allow periapical healing with good long-term prognosis³.

Case Report

A 23 years-old female patient came to the Conservative Specialist Department at Dental Hospital of Airlangga University with chief complaint of tooth decay in upper anterior tooth. The patient said that the decay started a few years ago. The tooth sometimes caused pain when exposed to food and sometimes there was spontaneous pain. The last time the pain was felt was about 1 year ago. 6 months ago, the patient had already done filling to the tooth. Since 1 month ago, the filling was off. The patient felt there was swelling in the gingiva upper the tooth.

She was a healthy patient without any systemic medical disorder and was a non-smoker. Intraoral examination showed caries on 22 with pulp involvement (Figure 1). Vitality test of the tooth was negative. Radiographic examination showed profunda perforation caries on 22, and there was a big periapical lesion. Periapical radiograph showed a radiolucent lesion with diameter of 2 cm and corticated margin (Figure 2). It was concluded that the diagnosis of this patient was pulp necrosis with radioculor cyst lesion.

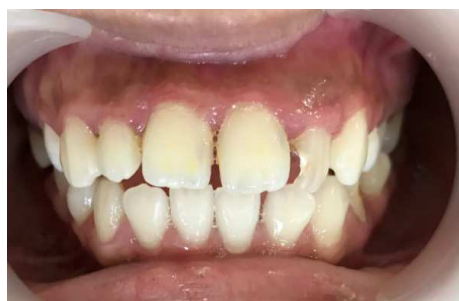

Figure 1 : Pre Operative

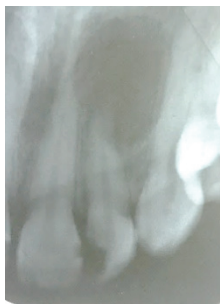


Figure 2: Radiographic Pre Operative

Case Management

Patient was informed about the condition of her tooth, and explained about the options of the treatment. The patient was informed that the first step was conventional root canal treatment, then followed by apical surgery. The patient was agree about the treatment and informed consent was made before the treatment started.

Conventional endodontic treatment started with access opening using endoaccess diamond bur. Working length was measured using Kfile #10 and apex locator(Figure 3). Working length was 23 mm and radiographically confirmed(Figure 4).



Figure 3: Measure the working length using apex locator

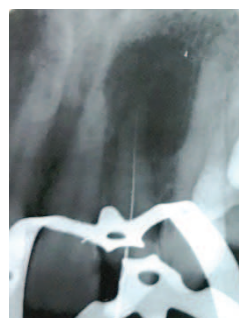

Figure 4 : Diagnostic Wire Photo

Preparation of the root canal was done using Protaper Next. The final rotary file that was used was X3 file(Figure 5). Glyde was used as lubricant during root canal preparation. Irrigation process using NaOCl 2,5% and aquadest was carried out together with root canal preparation.



Figure 5 : Root Canal Preparation

Guttap confirmation was done clinically and radiographically(figure 6). The next step was rewalling proximal wall of the tooth using composite and Dressing with Ca(OH)_2 for one week.

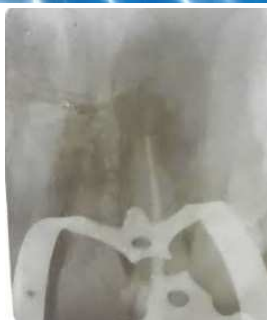

Figure 6: Gutta Percha Trial

One week control showed there was no complaint from the patient and percussion test was negative. Before obturation process, final irrigation was done using NaOCl 5%, Chlorhexidine 2%, EDTA 17% and aquadest. Activation of irrigation solution was done using endoactivator. Root Canal was dried using paper point before obturation. Obturation process using gutta percha and obturation paste was done with single cone technique(Figure 7) then closed with temporary filling.

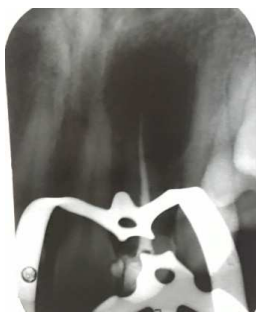

Figure 7: Post Obturation

Apical surgery was scheduled one month after obturation. Before the surgery, patient did complete blood test, blood sugar examination, bleeding and clotting time. The result of the examination showed no systemic abnormalities.

On the surgery day, aseptic process using povidone iodine 1% was done on the surgery area. The next step was local infiltration anesthetic on labial and palatal mucosa. Trapezoid flap was chosen to give a bigger operation field(Figure 8). When the flap was opened, part of the bone had been resorbed. Access to the apical was made by opening the remaining bone using round surgical bur by low speed handpiece under water cooling. After the apical could be seen, curettage of the cyst was done using excavator until all the pathological tissue was cleaned (figure 9).

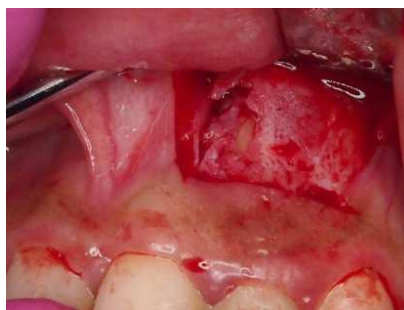

Figure 8: Flap

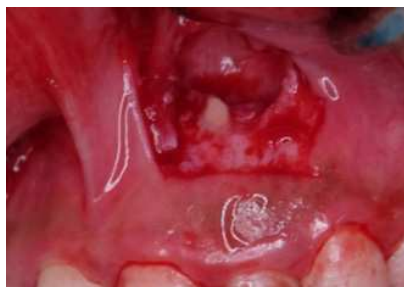

Figure 9: Resorbed Bone

The next step of the surgery was resection of the apical using ultrasonic tip. Guttap percha was reduce about 3 mm from the apical using ultrasonic retreatment tip. Mineral Trioxide Aggregate (MTA) was put retrogradely in the apical. (Figure10)

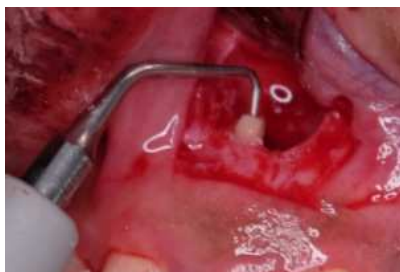

Figure 10: Gutta Percha Reduction Using Ultrasonic Retreatment Tip

Bone graft was put to filled the resorbed bone area(Figure 11). The final step, membrane was put on the bone graft and the gingival flap was placed in the right place. Interrupted Suture was done to prevent the bone graft out. Instruction post surgery was instructed to the patient

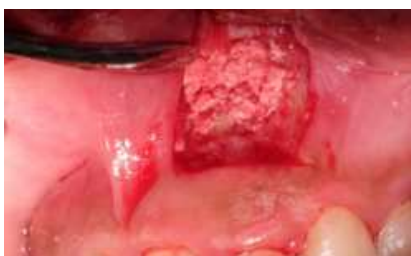

Figure 11 : Bone Graft Placement

Periapical lesion from the surgery was sent to Histopathology laboratorium, and the result showed that periapical lesion in the tooth was periapical cyst.

One week after the surgery, the patient came to remove the suturing and radiographic photo was taken (Figure 12).

The patient did not have any complaint and clinical examination showed a good healing process.

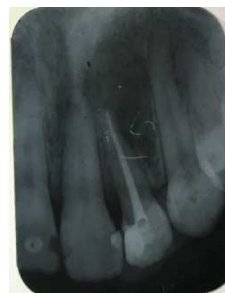

Figure 12: One week Control After Surgery

Three weeks after the surgery, the patient came to do the restoration of her tooth. The treatment plan of the tooth was using fiber post and full porcelain crown(Emax). Guttapercha reduction was done using fibrepost drill, and Fiber post(DMG) was inserted to the root canal usin resin cement(Figure 13). Then, the next step was core build up of the tooth

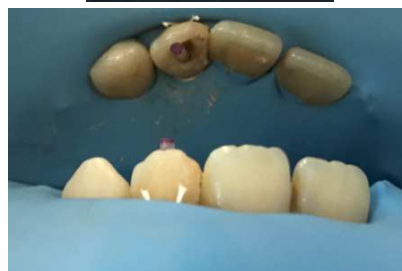
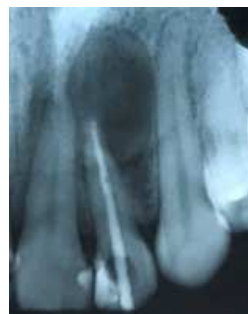
Figure 13: Fiber post Insertion

Tooth preparation for emax porcelain crown was done using round end fissure diamond bur(Figure 14). After tooth preparation was done retraction cord was placed in gingival sulcus to retract the gingiva. Elastomer impression was taken from the prepared tooth and alginate impression was taken from antagonist tooth. Bite registration was also made. Tooth's colour determination was done using VITA 3D shade guide. 1M2 colour for cervical and 1M1 colour for incisal was chosen(Figure 15). Temporary crown was made directly using self cured acrylic(Luxatemp) (Figure 16).

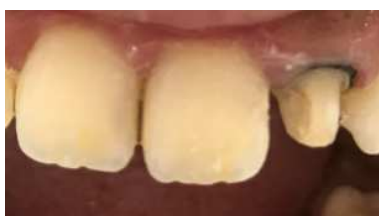

Figure 14: Tooth Preparation

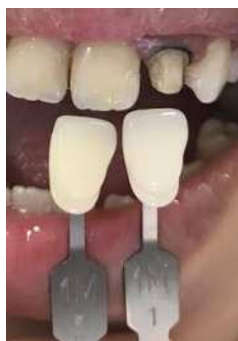

Figure 15: Colour Determination

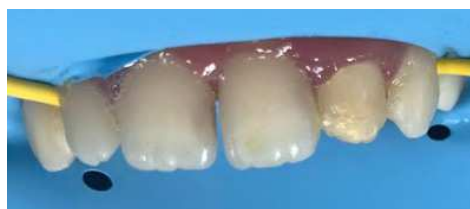

Figure 16: Temporary Crown

Two weeks after taking the impression, crown was ready to be inserted. Porcelain etch and silane was applied to the porcelain and etching and bonding procedure to the tooth was also done. Emax porcelain veneer was inserted to the tooth using resin cement.

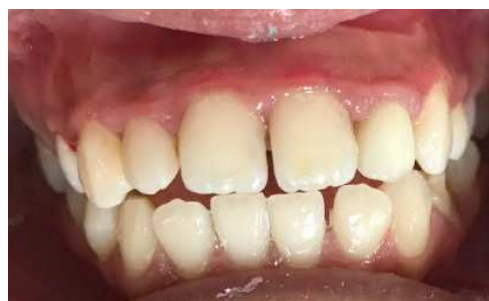

Figure 17 : Post Operative photo

DISCUSSION

The periapical cyst is the most common odontogenic cyst (52.3%-70.7%). The development of a periapical cyst is a gradual process. The inflammatory process from non-vital tooth stimulates the epithelial rest cells of Malassez, and cystic fluid develops around the apex which is composed of cholesterol. The cyst may grow by expansion from the fluid and cause resorption from the surrounding tissue⁴.

The treatment choices for periapical cyst are influenced by factors such as the extension of the lesion, relation with noble structures, evolution, origin, clinical characteristic of the lesion, systemic condition and cooperation of the patient.⁴ It is determine whichone was the best choice between syrger or non-surgery treatment

Indication for apical surgery are retreatment of afailed conventional root

canal treatment, fracture instrument in apical third of root canal, over filling with persistent pain, obliterated root canal, radicular cyst, need biopsy for periapical lesion and perforation in apical. Contra indication for apical surgery are the ratio root: crown should be at least 1:1 after the resection, Teeth suffering from periodontal disease, Anatomical contraindications such as proximity of the periapical pathology to anatomical cavities, Insufficient oral hygienic procedures.²

Conventional endodontic treatment was done in multiple visit with biomechanical preparation (preparation, irrigation and activation) and $\text{Ca}(\text{OH})_2$ was used as a dressing material. It is important for reducing levels of bacteria better than that obtained with mechanical preparation, in unreachable area such as dentinal tubules and ramifications. It is created a more favourable environment leading to healing of periapical lesion⁵. Its mechanism of actions is achieved through the ionic dissociation of Ca^{2+} and OH^- ions and their effect on vital tissues, the induction of hard-tissue deposition and the antibacterial properties.⁴

Apical surgery is the next procedure of the treatment. The incision and flap design should be chosen according to clinical and radiographic parameters, including condition, biotype and width of gingival tissues, presence of a restoration margin, location and extent of the periapical lesion, and patient's esthetic demands. Once the mucoperiosteal flap has been raised,

the cortical bone over the root end is removed and the root end is located. The periapical pathological tissue is curetted out to enhance access and visibility of the surgical field.³

The next surgical step is the root-end resection. The resection plane should be as perpendicular as possible in relation to the long axis of the root. Guttap removal in 3mm from the apical was followed by MTA placement.

MTA is the most commonly recommended material for sealing communications between the root canal system and the periodontium. When MTA is placed in direct contact with human tissues, it will create an antibacterial environment due to its alkaline pH, encourages differentiation and migration of hard tissue-producing cells, and forms Hydroxyapatite on the MTA surface and provides a biologic seal⁶.

After retrograde obturation was finished, bone graft (Gamacha) was put to fill the resorbed bone. Bone graft is used as a bone substitution material/ bone defect maintenance on bone loss, as a bone substitution material to replace extracellular matrix on the damaged bone, as bone substitution material to induce new bone growth. After bone graft placement, membrane was put on the bone graft. Mucoperiosteal flap was put back in the right place and adaptation of flap margins is accomplished with interrupted sutures.

Restorative treatment plan in this case was using fiber post and all porcelain crown. The choice of post design must be in accordance with the biomechanical requirements of the remaining tooth structure. One of the major functions of a post and core systems are to improve the resistance to laterally directed forces by distributing them over as large area as possible. Fiber post which was used in this case, has some advantage risk of fracture and tooth mobility. Fibre post also have including minimal have similar elastic-moduli to dentin. This Phenomenon has been coined by “monobloc”.⁷

Emax crown are used as final restorative in this case. It is made from lithium disilicated ceramic, a material that has been harvested for its translucent color and durability. Emax has some advantage including good esthetic, minimal preparation and tough and durable.

Reference

1. Valois, Carolin RA and Costa-Junior, Edson Dias. Periapical Cyst Repair After Nonsurgical Endodontic Therapy - Case Report. *Brazilian Dental Journal*. 2005. 16(3): 254-258
2. Ivanov, Ivan., Radeva, Elka and Uzunov, Tsonko. Endodontic Surgical Treatment- A Literature Review. *International Journal of Scientific and Research Publication*. 2015. 5(10): 1-5
3. Arx, Thomas Von. Apical Surgery: A Review of Current Techniques and Outcome. *The Saudi Dental Journal*. 2010. 2011(23): 9-15
4. Dwivedi, Shweta., Dwivedi, Chandra Dhar., Chaturvedi, Thakur Prasad and Baranwal, Harakh Chandra. Management Of A Large Radicular Cyst: A Non-Surgical Endodontic Approach. *Saudi Endodontic Journal*. 2014. 4(3): 145-148
5. Azad, Antarksh., HR Chourasia., D. Singh., I. Sharma., A. Azad and V. Pahlajani. Management of A Large Periapical Cyst: A Case Report. *People's Journal of Scientific Research*. 2014. 7(1): 47-50
6. Toptanci, Ismet Rezani., Dalli, Mehmet and Colak, Hakan. The Composition and Biological Action of Mineral Trioxide Aggregate: A Review. *Konuralp Tıp Dergisi*. 2013. 5(2): 70-74
7. Uthappa, Roshan., Mod, Deepika., Kharo, Pranav., S Pavitra., Ganiger, Kavita and Kharod, Hiral. Comparative Evaluation of The Metal Post and Fiber Post in The Restoration of The endodontically Treated Teeth. *Journal of Dental Research and Review*. 2015. 2(2): 73-77

MANAGEMENT OF ESTHETIC COMPLEX CASE IN ANTERIOR MAXILLARY TEETH THROUGH A COMPREHENSIVE APPROACH: A CASE REPORT.

CyrillaPrima A. M.¹, Tunjung Nugraheni²

¹Resident of Conservative Dentistry, Faculty of Dentistry, GadjahMada University;

² Staff Departement of Conservative Dentistry, Faculty of Dentistry,
GadjahMada University

ABSTRACT

Background: Esthetic complex case caused by severe dental caries in anterior teeth may result in the various problem for aesthetic and physical appearance. Dental caries may lead to the necrotic pulp. Comprehensive treatment of endodontic and esthetic treatment is needed to restore teeth's functionality. **Purpose of the study:** To present an overview a comprehensive treatment to an esthetic complex case in anterior teeth with caries and necrotic pulp. **Clinical case:** A 22-year-old woman presented with darkened color in upper anterior teeth. In clinical examination, the necrotic pulp was found in teeth 12, 11, and 21 with gumboil in the gingival mucosa of tooth 12. Dentin caries with mottled enamel was found in tooth 22. Radiographic view showed a widened lamina dura and radiolucency on periapical teeth. **Case management:** Endodontic treatment of teeth 12, 11, 21 and followed by inserting fiber post. Restoration of tooth 12 used direct veneer composite resin, teeth 11 and 21 used indirect crown with indirect ceramopolymer crown, and tooth 22 used direct veneer composite resin. **Conclusion:** A comprehensive treatment comprises of endodontic treatment with fiber post and composite resin restoration can repair teeth's esthetic and functionally.

Keywords: endodontically treated tooth, fiber post, esthetic complex, root canal treatment, direct veneer, indirect crown.

Correspondence: Cyrilla Prima Anggita Maharani, Resident of Conservative Dentistry, Faculty of Dentistry, UniversitasGadjahMada, JIDentaSekip Utara Yogyakarta, Indonesia. E-mail address: cyrillaprima@yahoo.com

INTRODUCTION

Nowadays, complex esthetic treatment in dentistry is being well-known to society. Dentistry has evolved from treating pain and oral diseases to improving esthetics

and the overall look and appeal of an individual. ¹Self-confidence is influenced by the appearance of the individual. The appearance of anterior teeth has an important role in supporting the individual

performance. Esthetic problem on anterior teeth can be caused by several things such as caries, fractures, diastema, attrition, change in color, and shape.²

In this case, patient had multiple caries in anterior maxilla teeth that caused pain, mouth odor, discoloration, and aesthetic disorder. Dental caries is a pathologic process depending on several etiologic factors, which cause the destruction of the dental tissues and produces local and general complications.³ It needed comprehensive treatment to recover function and aesthetic on anterior maxilla teeth. Endodontic treatment of teeth 12, 11, 21 and followed by inserting fiber post. Restoration of tooth 12 used direct veneer composite resin, teeth 11 and 21 used indirect crown with indirect ceramopolymer crown (Ceramage, Shofu Inc), and tooth 22 used direct veneer composite resin. A comprehensive treatment plan is incomplete without an aesthetic analysis or smile design defining the end point of the treatment.

CASE

A 22-year-old female patient went to Dental Hospital Faculty of Dentistry Universitas Gadjah Mada with the chief complaint of a toothache in her anterior maxilla teeth. There were holes and discoloration in her maxillary teeth. Furthermore there was a swollen in the right maxilla tooth. She had spontaneous throbbing pain and she felt discomfort on eating. She wanted to treat her anterior maxillary teeth.

From clinical examination there were caries in teeth 12, 11, 21, and 22 (Picture 1). Tooth 12 had deep caries that reached the pulp, had gumboil in the gingival mucosa, gave a negative response to thermal test and electric pulp tester, and had tender to percussion and palpation. From radiographic examination (Picture 2) was found widened laminadura and radiolucent diffuse image on apical. Tooth 11 and 21 had deep caries that reached the pulp, gave a negative response to thermal test and electric pulp tester, and had tender to percussion and palpation. From radiographic examination was found widened laminadura and radiolucent diffuse image on apical. Tooth 22 had dentin caries with mottled enamel, gave a positive response to thermal test and electric pulp tester, and didn't have a tender to percussion and palpation. From radiographic examination, there were no abnormalities on the apical. Diagnosis of teeth 12, 11, and 21 was dentin caries with necrotic pulp and periapical lesion and tooth 22 was caries dentin.

After through explanation, the patient approved and consented to conservative esthetic improvement procedure through conventional endodontic treatment on teeth 12, 11, and 21. The restoration of tooth 12 was determined using direct composite with fiber post, teeth 11 and 12 using indirect composite crown with fiber post, and tooth 22 using direct composite veneer.

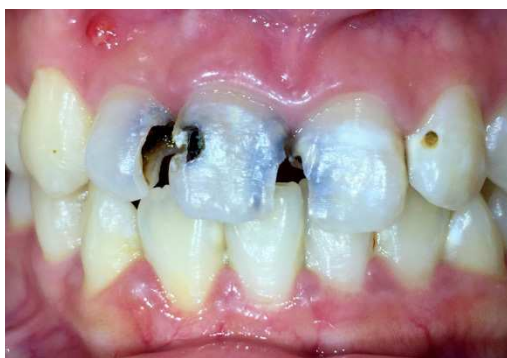

Figure 1. Clinical feature before treatment

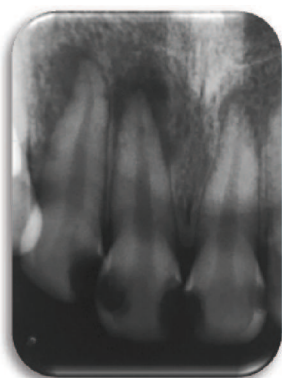


Figure 2. Preoperative radiograph

CASE MANAGEMENT

Subjective and objective examination, intraoral photo, preoperative radiograph, diagnosis, treatment plan, informed consent, maxilla and mandible mold for study and diagnostic model, filled, and molding for mock up model (Picture 3) was done in the first visit.

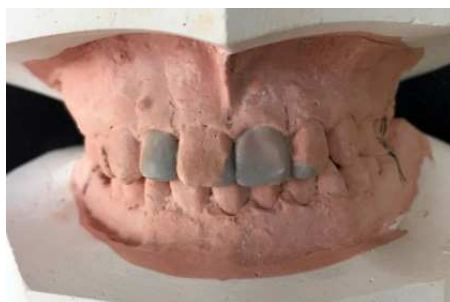

Figure 3. Mock up of model study

On the second visit rubber dam was placed to isolation the teeth (Picture 4). Access opened with endo access bur and diamendo (Fig. 5). Estimation working length was determined by preoperative radiograph (Picture 6). File #10 and #15 used in order to get good glide path. Root canal preparation used step back technique using k-file (*Dentsply*). The master apical file for tooth 12 was #45, tooth 11 was #55, and tooth 21 was #50. Canal of teeth 12, 11, and 21 was completely instrumented and cleaned. 2,5% Sodium hypochlorite, saline water, and 17% EDTA were used as irrigants material. The canal was sterilized with calcium hydroxide paste.

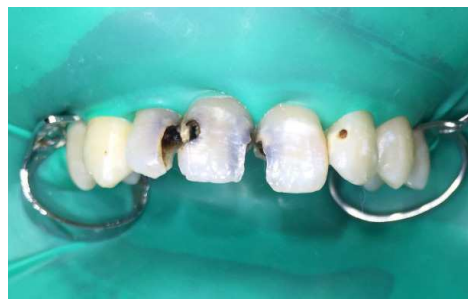

Figure 4. The placement of rubber dam to isolation of the working area

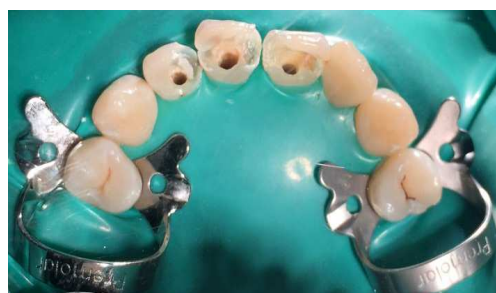

Figure 5. Caries removal and open access of teeth 12, 11, and 21

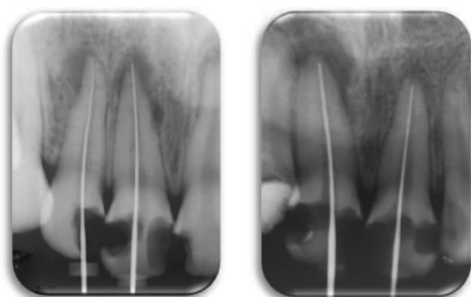


Figure 6. Working length teeth 12, 11, and 21

The third visit gumboil in mucosa tooth 12 had disappear. There was no pain between visit. Objective examination showed that didn't have a tender to percussion and palpation. 2,5% Sodium hypochlorite, saline water, and 17% EDTA were used as irrigants material and final irrigation was 2% Chlorhexidine. Fitting master apical cone was done and the radiography was taken (Figure 7). Obturation was done using lateral condensation technique (figure 8). Sealer (Top Seal, Dentsply) was applied with lentulo and the master apical cone was inserted in the canal. Spreader was used to condense the guttapercha. Guttapercha accessories was inserted in the canal. Guttapercha was cut below the orifice.

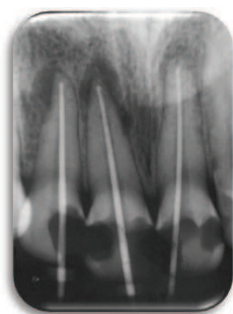


figure 7. Trial master apical cone guttapercha in teeth 12, 11, and 21

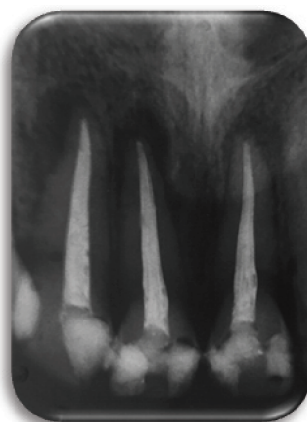


Figure 8. Final obturation radiograph

On the fourth visit guttapercha was removed by using peeso reamer and precision drill on 2/3 length of the root tooth, and prefabricated fiber post was tried in the canal (Picture 9) and inserted into the canal by using adhesive cement resin material (Rely X U200, 3M), light cured for 20 seconds, and the radiograph was taken (Picture 10). Applied core it to created core build up and temporary crown installation on teeth 11 and 21.

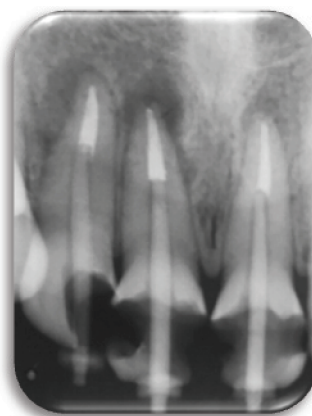
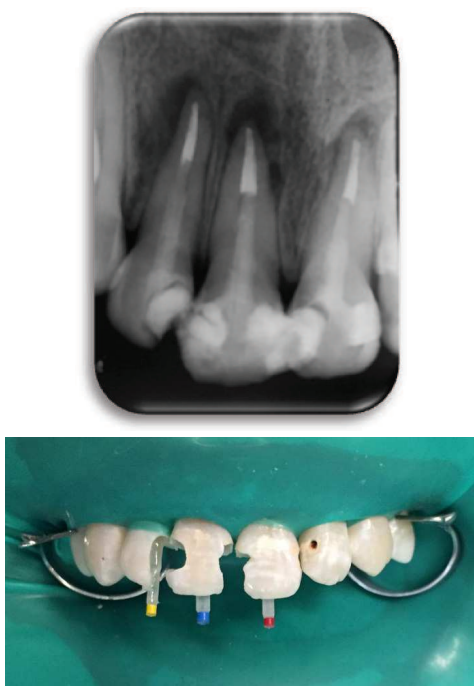

Figure9. Radiograph of fiber post try in



Picture 10. Radiograph of final fiber post sementation and clinical feature of the teeth

The fifth visit, teeth 12 and 22 were restored with direct composite resin. Hollow-ground bevel was made in tooth 12 with flame diamond bur. Etch was applied with 37% phosphoric acid etch (Den-Fill Etchant) then rinsed and air dried until moist dentin condition. Bonding agent (*Adper™ Single Bond 2*, 3M ESPE) was applied with microbrush then air-thinned and cured for 20 seconds. Putty was inserted on palatal 12 to made a palatal guide. Composite resin was applied in a layering technique. Composite resin enamel color A3 (*Herculite™*, Kerr) was applied in the palatal as a palatal guide with plastic instrument. Composite resin with dentin color A2 (*Herculite™*, Kerr) was applied and celluloid strip was inserted

in interdental between 12 and 11 for slip through technique. On the labial surface was applied composite resin enamel color. Light curing was done for 20 seconds after each layer has been applied (Picture 11). Tooth 22 was prepared with depth marked bur to determined the depth of preparation and continued with flat end tapered fissure diamond bur (Picture 12). The final thickness of the preparation was 1 mm on the labial. Chamfer preparation on the cervical margin was chosen to facilitate good polishing procedure with bold preparation edge. Operative procedure direct veneer with composite resin for 22 was done in the same manner as in 12 except the absence of palatal guide to be built. The final adjustment used extra fine diamond burs and polishing strips on the proximal surface and polishing disks (*Sof-Lex*, 3M ESPE).

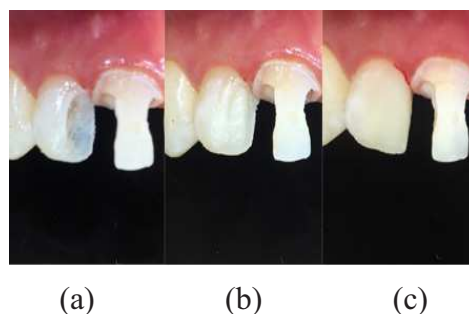


Figure 11. The step restoration of tooth 12. (a) Built palatal guard, (b) applied dentin color, and (c) final restoration

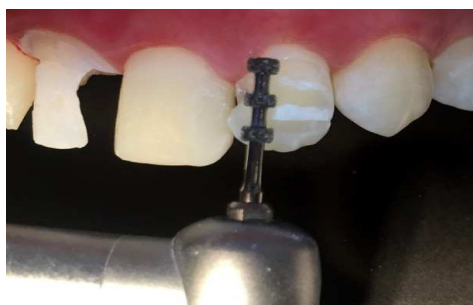


Figure 12. Preparation of tooth 22 with depth marker bur

Gingival cord with the hemostatic agent (*ViscoStat*, *Ultradent*) was inserted on sulcus gingival teeth 11 and 21 and then preparation with flatended tapered diamond bur on proximal and labial. Preparation on palatal used wheel diamond bur. Proximal angle was 6° and length of the core was $\frac{2}{3}$ the length of the crown (Picture 13).

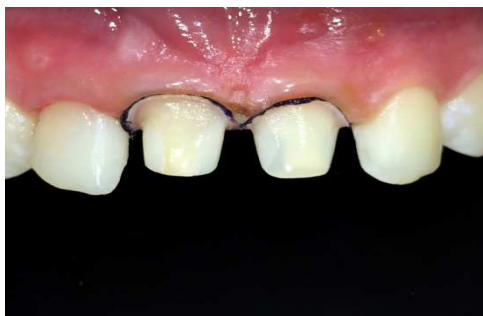

Figure 13. Preparation core build-up of teeth 11 and 21

Casting on maxilla used double impression material and mandibula used irreversible hydrocolloid casting material. A bite registration was made by base plate wax. The color of the teeth by shade guide (*Vita Classic*) was A3 (Picture 14).

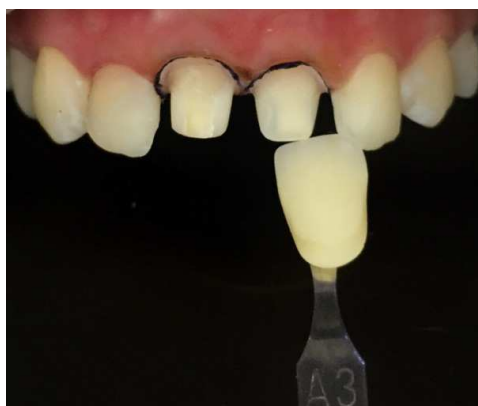

Figure 14. Determination color of the teeth with shade guide

In the last visit, indirect ceramopolymercrown, was tried and shown good self-retention, adaptation, anatomy, color, marginal integrity, occlusion, and there was no complaint from the patient. The indirect ceramopolymer crown was applied with silane for 60 seconds then sprayed with air. Sementation of the crown used adhesive cement resin material (*Rely X U200*, *3M ESPE*) and light cured for 20 seconds. Excess cement was removed and interdental was checked with dental floss (Figure 15).

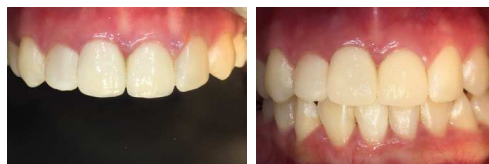

Figure 15. Final restoration of teeth 12, 11, 12, and 21

DISCUSSION

Caries is a localized chemical dissolution of the tooth surface caused by metabolic events taking place in the biofilm covering the affected area. It may develop at any site in the oral cavity such as approximal surface cervical to the contact point.⁴ Dental caries may lead to a necrotic pulp. In this case caries involves 4 teeth on the maxilla.

This case shows an aesthetic rehabilitation using endodontic treatment, fiber post prefabricated, and restoration with either direct composite resin or indirect ceramopolymer crown (*Ceramage, Shofu Inc*). The fiber post prefabricated on teeth 12, 11, and 21 is used for maintaining teeth's strength and retention due to crown lost. Fiber post has a similar modulus of elasticity with dentin (14.0 – 18.6 GPa) so that able to increase resistance on root fracture, producing a stress field similar with natural teeth.⁵

The restoration uses either direct composite and indirect ceramopolymer crown. Indirect ceramopolymer crown is used as an alternative to ceramics as an indirect restorative material in a minimally invasive cosmetic dentistry.⁶ A recent study has shown that ceramopolymer can significantly increase the flexural strength, flexural modulus, energy at break of dental composites over the control. All zirconia reinforced composites (containing 2.5, 5.0 and 7.5 % ZS nanofibers) exhibit significantly higher fracture toughness than the control. Thus ceramopolymer based

restorations can be used less invasively while still giving the desired aesthetic results.⁷ Ceramage (*Shofu Inc, Japan*), a zirconium silicate integrated indirect restorative was developed in the hope of combining the advantages of composite resin and ceramic. Ceramage is composed of a PFS (Progressive Fine Structure) filling of more than 73% plus anorganic polymer matrix, making it more stable than other light-cured composites while more elastic than conventional ceramics. The tensile and compressive strength of ceramage are higher than both composite resin and ceramics, but the elastic modulus is lower than the two materials.⁸

REFERENCES

1. Padmanabha PS, Arul PT, Geeta IB. Full Mouth Rehabilitation of Adult Rampant Caries with Pragmatic Approach. *J Oper Dent Endod* 2017, 2(2):88-92.
2. Mount GJ, Hume WR. Preservation and restoration of tooth structure. Philadelphia: Mosby international Ltd. 1998. P 218-23.
3. Sicca C, Bobbio E, Quartuccio N, Nicolò G, Cistaro A. Prevention of dental caries: A review of effective treatments. *J Clin Exp Dent*. 2016 Dec; 8(5): 604–10.
4. Fejerskov O, Kidd E. Dental caries the disease and its clinical management. 2nd edition. Oxford: Blackwell munksgaard. 2008. P 4.

5. Ferrari M, Breschi L, Gradini S. Fiber post and endodontically treated teeth: a compendium of scientific and clinical perspectives. Singapore: Modern dentistry media. 2008. P 9-12.
6. Thumati P, Reddy KM. Ceramage - A ceramo polymer restoration to be used as an alternative to ceramics; as an indirect restorative material in a minimally invasive cosmetic dentistry protocol - A case report. J Int Dent Med Res 2013; 6(1): 31-35.
7. Sarita, Tumati P. Full mouth rehabilitation by minimally invasive cosmetic dentistry coupled with computer guided occlusal analysis: a case report. [J Indian Prosthodont Soc.](#) 2014 Dec; 14(1): 227–231.
8. Binwen C, Yanzhao MA, Kunxue WU, Hong C, Lu L, Liang L, Jun Lm Zhi C. Influence of Various Materials on Biomechanical Behavior of Endocrown-Restored, Endodontically- Treated Mandibular First Molar: A 3D-Finite Element Analysis Journal of Wuhan University of Technology-Mater. 2015June;643-46.

MANAGEMENT OF APEXIFICATION WITH MINERAL TRIOXIDE AGGREGATE APICAL PLUG ON PERMANENT MAXILLARY CENTRAL INCISORS : A CASE REPORT

Dani Rudyanto*, Dian A Wahjuningrum.**

*Post Graduate Departement of Endodontic

** Department of Endodontic

Faculty of Dental Medicine, Universitas Airlangga Surabaya, Indonesia

ABSTRACT

Background: One of the causes of pulp necrosis is untreated active carious lesion. Pulp necrosis that occurs in an immature permanent teeth can lead to an incomplete root formation which is characterized by the wide root canal space, absence of apical constriction, and open apical. The absence of a natural constriction at the end of the root canal makes control of filling materials difficult. **Purpose:** To analyze the clinical and radiographic appearance of teeth that incomplete root formation and was treated by an mineral trioxide aggregate (MTA) apical plug. **Case:** A 17-years-old male patient came to the Department of Endodontic at Universitas Airlangga Dental and Oral Hospital with the intention to replace the upper front prosthetic crown. Patients felt unsatisfied with the existing crown and wanted to replace it. Based on the anamnesis, the tooth decayed when he was 13 years old and was treated and restored with a crown in a single visit appointment. The tooth has never been symptomatic ever since. Clinical examination showed tooth 11 with an unaesthetic prosthetic crown. Soft tissue surrounding tooth 11 was normal. The periapical radiograph showed that there were an ill fitting post and crown and a wide root canal space and an absence of apical constriction. **Case management:** The prosthetic crown and post were removed; followed by root canal treatment with calcium hydroxide dressing for one week. Apexification was done with MTA to create an apical plug, continued with thermoplastic obturation, fiber post insertion, core build up, and PFM crown insertion. **Conclusion:** Apexification with MTA apical plug is an effective treatment for necrotic immature permanent teeth.

Keywords: apexification, mineral trioxide aggregate, incomplete root formation

Correspondence : Dani Rudyanto, Post Graduate Departement of Endodontic, Faculty of Dental Medicine, Universitas Airlangga. Email : drg.dani02@gmail.com

Introduction

One of the causes of necrosis pulp on immature permanent teeth is dental caries¹. This can cause the process of development and formation of roots to be disturbed by

marked open apical and the absence of apical constriction^{1,2,3}. The open apical is a challenge for the clinician in cleaning, shaping, and obturation during root canal treatment process⁴.

Root canal treatment on teeth with open apical can be completed after apical closure through apexification³. Apexification is a procedure to induce a calcified barrier at the open apical of a non-vital immature permanent tooth^{5,6,7}.

Some of the materials used for open apical management include Tri-calcium Phosphate introduced by Coviello and Brilliant in 1979. In 1993 Schumache and Rutledge suggested the use of Calcium Hydroxide to induce the calcified barrier in the apical permanently. Based on the study, the speed of calcified barrier formation by using Calcium Hydroxide varies between 3-24 months. The use of Calcium Hydroxide in apexification is recommended to be repeated every 3 months or every 6-8 months and not even at all^{8,3}.

In 1993 Torabinejad introduced the Mineral Trioxide Aggregate (MTA) as an apical plug to apical closure without waiting for the formation of a calcified barrier. MTA is a biomaterial with good biocompatibility, can close foramen apical, has the ability to regenerate tissue and can be used in humid conditions. The advantage of using MTA in apexification is more efficiency visiting time^{3,4,1,2}.

This article to analyze the clinical and radiographic appearance of teeth that incomplete root formation and was treated by an mineral trioxide aggregate (MTA) apical plug.

Case report

A 17-years-old male patient came to the Department of Endodontic at Universitas Airlangga Dental and Oral Hospital with the intention to replace the upper front prosthetic crown. Patients felt unsatisfied with the existing crown and wanted to replace it. Based on the anamnesis, the tooth decayed when he was 13 years old and was treated and restored with a crown in a single visit appointment. The tooth has never been symptomatic ever since. Clinical examination showed tooth 11 with an unaesthetic prosthetic crown (Fig.1). Soft tissue surrounding tooth 11 was normal. The periapical radiograph showed that there were an ill fitting post and crown and a wide root canal space, an absence of apical constriction, and open apical (Fig.2).

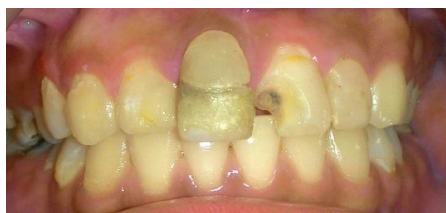

Fig.1. Intra oral

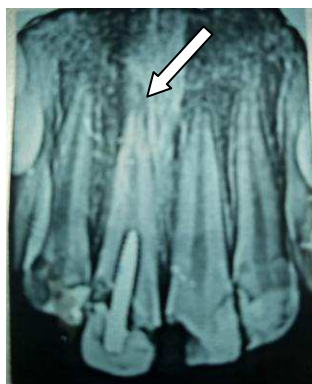


Fig.2. Periapical radiography

Case management

Treatment in this case begins with removing of the post crown and followed by using of rubber dam (Fig.3). Furthermore, the determination of working length using apex locator (Root ZX™) and confirmation through periapical radiography (Fig.4). Root canal debridement is carried out using rotary instrumentation (Protaper Next X3™) with circumferential technique according to length of work. Then the root canal was irrigated using 2.5% NaOCl, 17% EDTA, and 2% chlorhexidine (each irrigation solution change should be rinsed with aquades). The root canal is dried using paper point. Dressing using Ca (OH)₂ paste and temporary filling. Patients were instructed control one week later.

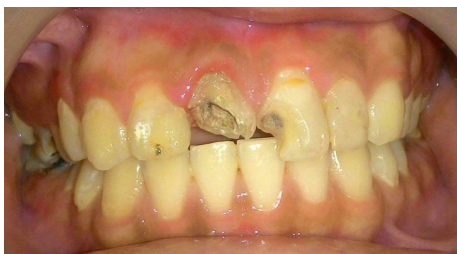

Fig.3. After removing the post crown

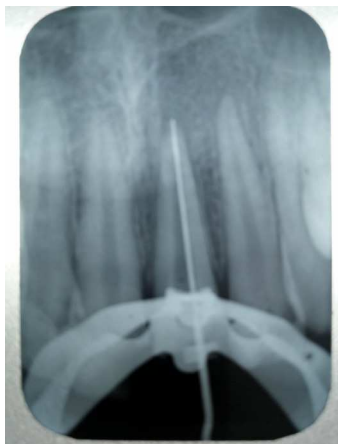

Fig.4. Determination of working length

On the second visit the patient did not have complain uncomfortably condition and the clinical examination showed negative response during percussion, the surrounding tissue seemed normal, and the temporary filling was in well condition. Then performed the use of rubber dam and temporary filling removal. Then the root canal was irrigated using 2.5% NaOCl, 17% EDTA, and 2% chlorhexidine (each irrigation solution change should be rinsed with aquades). The root canal is dried using paper point. Furthermore, MTA application is about 4 mm in apical third using MTA carier and condensation using root canal plugger (Fig.5). After that the cavity was closed with moist cotton and temporary filling and followed by radiographic confirmation (Fig.6).

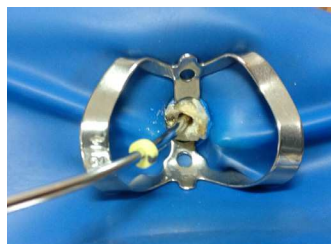

Fig.5. MTA application

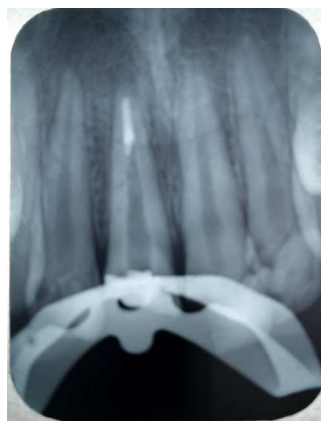


Fig.6. After MTA placement

One week later the patient came for control. The patient also did not have complain and the clinical examination showed negative response during percussion, the surrounding tissue seemed normally, and the temporary filling was in well condition. Then performed the use of rubber dam and temporary filling removal. Then the root canal was irrigated using 2.5% NaOCl and rinsed with aquades. The root canal is dried using paper point. After that is performed root canal obturation with back fill technique and temporary filling. Confirmation of root canal obturation is done through radiography (Fig. 7).

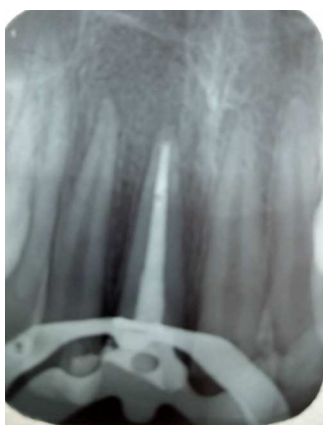

Fig.7. Root canal obturation

On the fourth visit everything is clear, no complain of pain and the clinical examination showed negative response during percussion, the surrounding tissue seemed normal, and the temporary filling was in good condition. Then performed fiber crown lengthening on the teeth 11 (Fig.8).

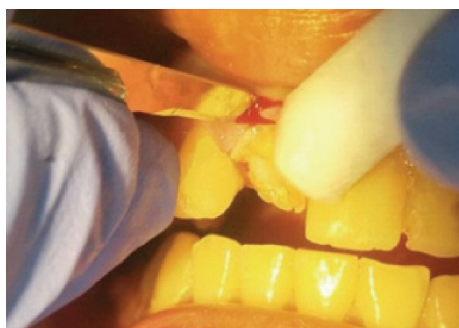


Fig.8. Crown lengthening

One week later the patient came for control, the surrounding tissue seemed normal, and the temporary filling was in good condition. Then performed the use of rubber dam and temporary filling removal. Guttap removal is done using penetration drill then performed fiber post trial. Further confirmation of fiber post trial with periapical radiography (Fig. 9).

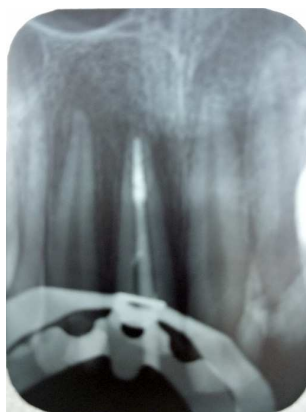

Fig.9. Fiber post trial

Then the root canal was irrigated using 2.5% NaOCl and rinsed with aquades. The root canal is dried using paper point. After that is performed fiber post insertion using self adhesive resin cement (Breeze™) and continued to build the core using core build up composite (Fig.10). And then, impression for working model

uses double impression material, while the antagonistic model uses alginate. After that, bite registration is done, selection of shade guide, and insertion of a temporary crown (Fig. 11).

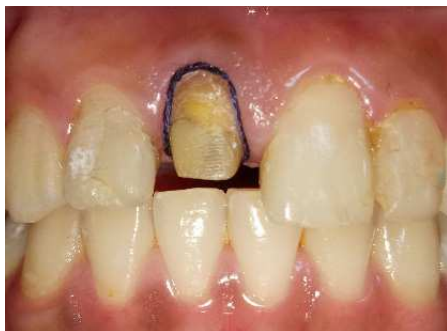

Fig.10. Core build up and retraction cord placement

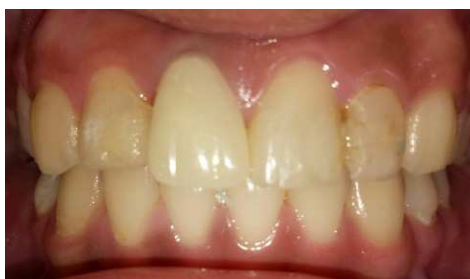

Fig.11. Insertion of temporary crown

On the sixth visit the patient did not have complain and the clinical examination showed negative response during percussion, the surrounding tissue seemed normal, and the temporary crown was in good condition. Then performed temporary crown removal, followed trial of porcelain fused to metal crown, occlusion and articulation checks, and insertion using cement (Fuji I TM) (Fig.12).

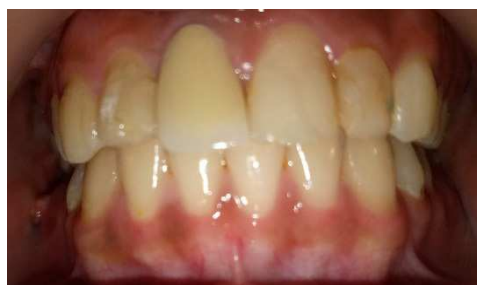

Fig.12. Insertion of fix crown

Discussion

Untreated caries may cause pulp necrosis. If this condition occurs in the teeth with uncomplete formation of roots then it will cause the formation of roots to be stopped^{1,5}.

Root canal treatment of necrosis teeth with open apical is a difficulty and a challenge for clinicians. This is due to the process of an adequate root canal debridement required an accurate working length. However, to obtain an accurate working length of teeth with open apical becomes difficult through the apex locator. Radiographic confirmation is one of solution to find accurate measurements of work length^{3,4}.

Incomplete root formation is characterized by open apical, the absence of apical constriction, and open apical (figure 2). Open apical can also be a problem during irrigation and root canal obturation. This allows the extrusion of irrigation solution to periapical tissue and excess of root canal filling due to poor apical closure when obturation^{9,8,11,7}.

A preliminary treatment is required

prior to root canal treatment of teeth with open apical. This preliminary treatment aims to induce a calcified barrier at the open apical end so that the apical end is expected to close and can properly root canal obturation. This treatment is known as apexification^{8,9,4}.

In this case begins with root canal instrumentation to remove necrotic tissue and root canal dressings using Ca (OH)₂ for a week for root canal disinfectant⁷. Apexification is done using Mineral Trioxide Aggregate (MTA) material. MTA as apexification materials have the advantage of forming apical plug without waiting for calcified barrier formation. So that the open apical can immediately close with the formation of apical plug, it is shown on figure 6. While the calcified barrier formation time using Ca (OH)₂ is unpredictable³. The use of MTA as an apical plug in this case is expected to induce the formation of calcified barrier. Based on the study, the time required for formation of calcified barrier on treated teeth with MTA was less when compared to teeth treated with Ca (OH)₂¹⁰.

Conclusion

Apexification of non-vital immature permanent teeth with open apical using MTA can shorten visit times with apical plug formation without waiting for calcified barrier formation and may be continued with root canal obturation as well as final restoration.

References

1. Flanagan TA. What can cause the pulps of immature, permanent teeth with open apices to become necrotic and what treatment options are available for these teeth. *Aust Endod J.* 2014; 40: 95-100.
2. Silva RV, Silveira FF, Nunes E. Apexification in Non-Vital Teeth with Immature Roots: Report of Two Cases. *Iranian Endodontic Journal.* 2015; 10; 1: 79-81.
3. Shabahang S. Treatment Options: Apexogenesis and Apexification. *Journal of Endodontic.* 2013; 39: S26-S29.
4. Gaitonde P, Bishop K. Apexification with Mineral Trioxide Aggregate: an overview of the material and technique. *Eur. J. Prosthodont. Rest. Dent* 2007; 15; 1: 41–45.
5. Widiadnyani NKE, Mulyawati E. Apeksifikasi pada Gigi Insisivus Kanan Maksila dengan Mineral Trioxide Aggregate. *Maj Ked Gi.* 2013; 20; 2: 170-177.
6. Fatmawati DWA. Penatalaksanaan Apeksifikasi: Pada Fraktur Gigi Depan Atas karena Trauma. *Indonesian of Journal Dentistry.* 2007; 14; 3: 199-203.
7. Kapoor B, Sherwani OAK, Tewari RK, Mishra SK. Single Visit MTA Apexification Technique for Formation of Root-End Barrier in Open Apices - A Case Series.

- University J Dent. 2015; 1; 2: 60-66.
8. Razavian H, Haerian A, Mosleh H. Novel Apexification Method In a Non-Vital Tooth With an Open Apex: A Case Report. Journal of Dentistry, Tehran University of Medical Sciences. 2014; 11; 3: 371-378.
 9. Neha G, Manoj C, Pradnya N, Anuja I, Sneha K, Rakhi C. Apexification with MTA placement – a case report. OSR Journal of Dental and Medical Sciences. 2015; 14; 10: 70-73.
 10. Damle SG, Bhattal H, Loomba A. Apexification of Anterior Teeth: A Comparative Evaluation of Mineral Trioxide Aggregate and Calcium Hydroxide Paste. J Clin Pediatr Dent. 2012; 36; 3: 263-268.
 11. Trope M. Treatment of the Immature Tooth with a Non-Vital Pulp and Apical Periodontitis. Dent Clin N Am. 2010; 54: 313-324.

CASE REPORT

MANAGEMENT OF FIVE ROOT CANALS IN MANDIBULAR FIRST MOLAR TOOTH: A Case Report

Daryono,¹ Bernard O. Iskandar,²Wiena Widyastuti²

¹Resident in Departement of Conservative Dentistry, Trisakti University

²Staff at Departement of Conservative Dentistry Faculty of Dentistry, Trisakti University, Jakarta-Indonesia

ABSTRACT

Background: The five root canals configuration is one of the abnormal morphology of molar teeth commonly found in the mandibular first molar. The treatment of mandibular first molar with five root canals, of which three were located in the distal root and two in the mesial root. A third canal was found between the distobuccal and distolingual root canals. Cleaning, shaping and filling the root canal system effectively is the basis of successful root canal treatment for aberrant canal configuration. **Purpose :** The aim for this case report was present the importance of knowledge of the internal anatomy of five root canals for the success of endodontic treatment in mandibular first molar tooth. **Case :** A 12 years old girl patient with dull pain in his right mandibular first molar since 5 days ago came to the Department of Conservative Dentistry and Endodontics, Trisakti Dental College and Hospitals. She left that his tooth has cavity since 2 years ago. Objective assessment showed a cavity extended to the pulp involving occlusal area (positive percussion test, negative palpation test). Radiographic examination showed cavity extended to the pulp with apical lesion and periodontal ligament widening on his right mandibular first molar tooth. A diagnosis of irreversible pulpitis with acute apical periodontitis was made for the mandibular right first molar. Pulpectomy treatment for 46 tooth was conducted. **Conclusion :** Endodontic success in teeth with the number of canals above that normally found requires a correct diagnosis and careful inspection. Morphological variations in pulpal anatomy must always be considered before beginning treatment. Although the incidence of root and canal variations is rare, every effort should be made to find and treat all canals for successful clinical results. Five root canals treatment of mandibular first molar tooth proven to be successful.

Keywords : five root canals, mandibular first molar, pulpectomy treatment, internal anatomy

Introduction

Variation and configuration root canal anatomy present interesting challenges of success in endodontic treatment require an understanding of the root canal anatomy

and morphology and that the entire root canal system must be cleaned, shaped, and filled. Thus, it is necessary for the clinician to have knowledge of not only the normal anatomy but also its variations.¹

Anatomical characteristics of permanent mandibular molars are generally described as a group of teeth with two roots. The usual canal distribution is two canals in the mesial root and one or two in the distal root.² The variations in the normal anatomy of mandibular molar have been extensively studied in the literature.³ Skidmore and Bjorndol,⁴ Pineda and Kuttler,⁵ Vertucci,⁶ Pomeranz et al,⁷ Martinez-Berna and Badanelli,⁸ and Goel et al⁹ has been reported of five canals in the mandibular first molar to vary between 1% and 15%. Fabra-Campos has been reported of the incidence three distal canals to be much lower at 0.6%.¹⁰ Although Stroner et al have reported the presence of three distal canals in mandibular first molar as early as 1984, yet literature reveals paucity in the reports on the occurrence of middle distal canal in mandibular molars.¹¹ This case report describes the diagnosis and successful management of case of mandibular first molar with this unusual morphological variation of three distal canals.

The aim for this case report was present the importance of knowledge of the internal anatomy of five root canals with three distal and two mesial for the success of endodontic treatment in mandibular first molar tooth.

Case Report

A 12 years old girl patient with dull pain in his right mandibular first molar since 5 days ago came to the Department of Conservative Dentistry and Endodontics,

Trisakti Dental College and Hospitals. She left that his tooth has cavity since 2 years ago. Objective assessment showed a cavity extended to the pulp involving occlusal area (positive percussion test, negative palpation test). Radiographic examination showed cavity extended to the pulp with apical lesion and periodontal ligament widening on his right mandibular first molar tooth (Figure 1). A diagnosis of irreversible pulpitis with acute apical periodontitis was made for the mandibular right first molar. Pulpectomy treatment for 46 tooth was conducted.

The tooth was anesthetized using 2% LidocaineHCl with 1:100.000 epinephrine (Lignospan, SeptodontInc, USA) and isolated using rubber dam. Endodontic access cavity was established. The pulp chamber frequently flushed with 2,5% sodium hypochlorite to remove debris and bacteria. Inspection of the pulp chamber revealed five canal orifices (2 mesial and 3 distal, Figure 2). Canal patency was checked with number 10 K-file (Mani, Inc.; Japan). An electric apex locator (Root ZX Mini, Morita) and a no.15 file were used to establish working length that was confirmed radiographically (Figure 3).

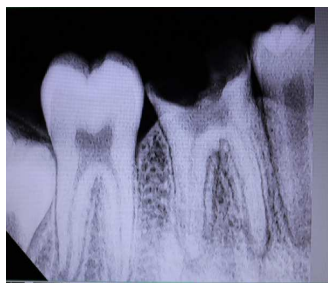

Fig 1. Preoperative radiograph.




Fig 2. Inspection of the pulp chamber revealed five canal orifices

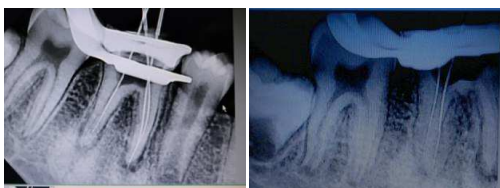

Fig 3. Working length radiograph

Cleaning and shaping was performed using a crown down technique (Figure 4) with Protaper files (Maillefer, Dentsply, Switzerland) under abundant irrigation with 2.5% sodium hypochlorite solution in a 5 mL syringe and EDTA (Glyde, Maillefer, Dentsply, Switzerland). The canals were dried with paper points and an intracanal dressing with calcium hydroxide was applied for 14 days.

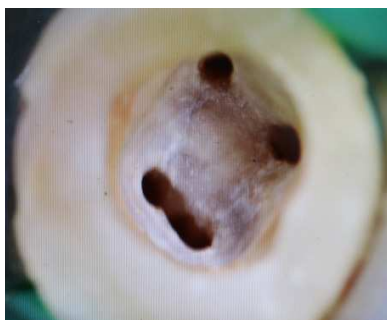

Fig 4. After cleaning and shaping

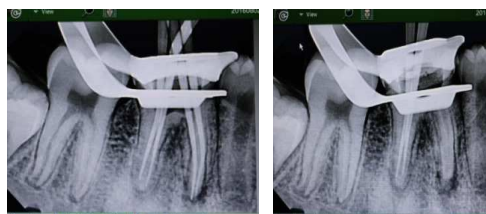

Fig 5. The master cone fit was checked

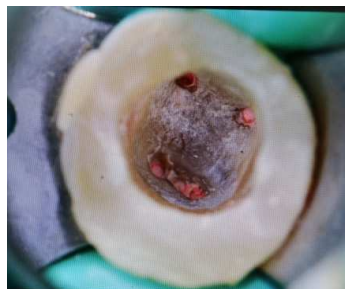

Fig 6. After obturation

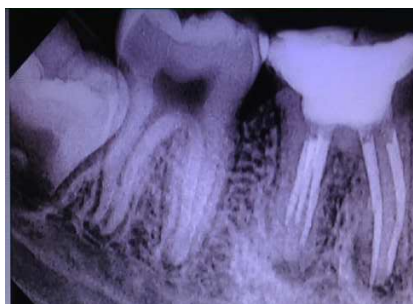

Fig 7. SDR sealing for 46

In the second visit, the calcium hydroxide intracanal dressing was removed, the master cone fit was checked (Figure 5) and the root canals were dried with absorbing paper points.

Root canals were obturated using the warm vertical compaction technique with System B (Sybronendo) and calcium hydroxide resin sealer (Sealapex, Sybronendo). After obturation, Smart Dentin Replacement (SDR, Dentsply) was used for the sealing restoration (Figure 6-7).

Discussion

Studies of the morphologic structure of root canal systems have demonstrated the complexity, numbers, and distributions of canals in mandibular first molars. According to the literature the incidence of third distal canals is 0.6% (Fabra-Campos,1985). The incidence of third canal in the distal root of mandibular molars was found to be much lower than in the mesial root (Martinez-Berna and Badanelli,1985).

The larger mesiodistal dimension of the dimension of the distal root, compared to mesial root, may account for the rare incidence of the third canal created by dentine apposition in distal roots.

In this case report there was confluence of the third middle distal canal with distobuccal and distolingual canals and having common apical termination.

Instrumentation is one of the key factors in the success of endodontic therapy and the clinician should be aware of the varied anatomy. An avid clinician should be always keen to explore the possibility of additional canals whenever in doubt with the assistance of technologies such as the those of magnification and illumination.

Conclusion

Endodontic success in teeth with the number of canals above that normally found requires a correct diagnosis and careful inspection. Morphological variations in pulpal anatomy must always be considered before beginning treatment.

Although the incidence of root and canal variations is rare, every effort should be made to find and treat all canals for successful clinical results. Five root canals treatment of mandibular first tooth proven to be successful.

References

1. Ingle JJ. Endodontics. 3rd ed. Philadelphia: Lea & Febiger.1985:37.
2. Venumuddala VR, et al. Endodontic Management of Mandibular First Molar with Middle Distal Canal: A Case Report. Case Reports in Dentistry.2012:1-4.
3. De Grood ME, Cunningham CJ. Mandibular Molar with five canals: Report of a Case. J Endod.1997;23:60-2.
4. Skidmore AE, BjorndalAM. Root canal morphology of the human mandibular first molar. Oral Surg 1971;32:778-84.
5. Pineda F, Kuttler Y. Mesiodistal and buccolingualroentgenographic investigation of 7,275 root canals. Oral Surg 1972;33:101-10.
6. Vertucci F. Root canal anatomy of the human permanent teeth. Oral Surg.1984;58:589-99.
7. Pomeranz H, Eidelman D, Goldberg M. Treatment considerations of the middle mesial canal of mandibular first and second molars. J Endodon 1981;7:565-8.

8. Martinez-Berna A, Badanelli P. Investigacion clinica de molars inferiors con cinco conductos. Boletin de Informacion Dental 1983;43:27-41.
9. Goel NK, Gill KS, Taneja JR. Study of root canals configuration in mandibular first permanent molar. J Indian Soc Pedod Prev Dent 1991;8:12-4.
10. Fabra-Campos CH. Unusual anatomy of mandibular first molars. J Endodon. 1985;11:568-72.
11. Stroner W, Remeikis N, Carr G. Mandibular first molar with three distal canals. Oral Surg 1984;57:554-7.

NON-SURGICAL MANAGEMENT OF A LARGE PERIAPICAL LESION USING A SIMPLE ASPIRATION TECHNIQUE : A CASE REPORT

Desneli* Adhita Dharsono**

*Resident of Conservative Dentistry Department, Faculty of Dentistry,
Padjadjaran University

**Staff of Conservative Dentistry Department, Faculty of Dentistry,
Padjadjaran University

ABSTRACT

Background :Ultimate goal of a conservative endodontic treatment is to regain tooth function in the stomatognathic system without surgical intervention. All inflammatory periapical lesions should be initially treated with nonsurgical endodontic procedures. Various studies have reported success rate up to 85% following endodontic treatment of teeth with periapical lesions. **Purpose :**To evaluate the outcome of a non-surgical endodontic management of teeth with large periapical lesion using a simple aspiration technique to eliminate swelling and minimize discomfort. **Case :**A 35 years old man was referred with recurrent pain, swelling, and mobility of the maxillary left anterior teeth. Patient has a history of trauma to his anterior teeth when he was 10 years old and has undergone an uncompleted root canal treatment. **Case Management** involves emergency procedure, which is aspiration through root canal. This procedure was done prior to root canal retreatment, followed by final restoration of teeth 21 and 22. **Conclusion :**Non-surgical endodontic treatment provides favourable results; clinically asymptomatic with sign of regression of lesions in radiography, therefore no surgical approach is needed for this case.

Email :ddesneli@gmail.com

Correspondence : Rumah Sakit Gigi dan Mulut – Fakultas Kedokteran Gigi Universitas Padjadjaran, Jalan Sekeloa Selatan No.1 Bandung, Jawa Barat.

BACKGROUND

Ultimate goal of a conservative endodontic treatment is to regain tooth function in the stomatognathic system without surgical intervention. All inflammatory periapical lesions should be initially treated with nonsurgical endodontic procedures. Various studies have reported success rate

up to 85% following endodontic treatment of teeth with periapical lesions.¹

More than 90% of periapical lesion can be categorized into granulomas, radicular cysts and abscesses. Several criteria for clinical diagnosis of periapical cystic lesions include the periapical lesions

is involved with one or more nonvital teeth, in size greater than 200 mm², seen radiographically as a circumscribed, well-defined radiolucent area bound by a thin radiopaque line, and produces a straw colored fluid upon aspiration or as drainage through an accessed root canal system.^{1,2,3} Generally lesions are diagnosed during routine radiographic examination or following acute pain, diagnosis is confirmatory only after surgical biopsy.

CASE

A 35 years old man was referred with recurrent pain, swelling, and mobility of the maxillary left anterior teeth. Patient has a history of trauma to his anterior teeth when he was 10 years old and has undergone an uncompleted root canal treatment.

On clinical examination, asymmetric facial appearance was inspected due to swelling on upper left lip toward nose (Figure 1a). Intraorally, a fluctuant swelling in labial vestibule adjacent to 21 and 22 teeth (Figure 1b) and palatal mucosa looked normal (Picture 1c), vitality test negative, tender to palpation and percussion, with grade II mobility, and normal pocket probing.

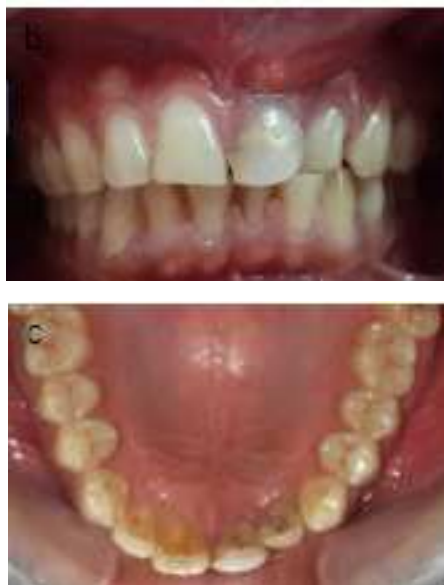

Figure 1 Clinical Examination : 1a. Extra oral, 1b and 1c. Intra oral

Intraoral periapical radiograph of 21 and 22 region was done, which revealed a large periradicular radiolucency unilocular more 200 mm² in size, circumscribed, round, associated with an intact root apex, and rupture of lamina dura, uncompleted obturation in intracanal, and tooth 22 pushed distally (Figure 2).



Figure 2 : Pre-Operative Radiograph

Based on these findings, the patient was diagnosed as previously treated teeth with symptomatic apical periodontitis (AAE,2013).

CASE MANAGEMENT

After informed consent was obtained, access cavity prepared under rubber dam isolation. Gingivectomy was performed to tooth 22 and a composite resin artificial wall was applied (Figure 3). Guttapercha in teeth 21 and 22 was softened with solvent Eucalyptol and taken out using Hedstrom file. Upon opening the cavity, yellow-coloured fluid was extruded from the canals (Figure 4a). Both Root canals were negotiated using hand K-files, found to be equivalent to a size 50 K-file, so widened to a size 80 K-file with working length 21 mm for tooth 21 and 19 mm for tooth 22. Overinstrumentation was done 1 mm beyond the apex with K-File #30. The 24 gauge needle attached to 3 ml syringe was inserted through root canal beyond apex. The exudate was aspirated through root canal by passing the aspiration needle through the apical foramen (Figure 4b).

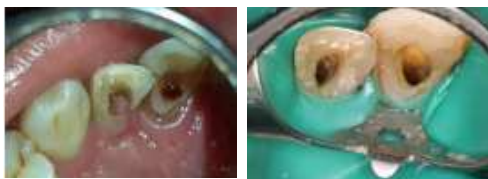


Figure 3. Gingivectomy and Artificial Wall to tooth 22

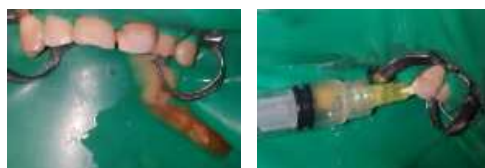

Figure 4. Aspiration Process

The canal were irrigated with 2,52% Sodium Hypoclorit (NaOCl), Chlorhexidine 2%, EDTA 17% and aquades. Each irrigants was activated by endoactivator for 1,5 minutes. Canals were dried with the paper points and calcium hydroxide paste Calciflex II was introduced into the lesion and the teeth were temporized with Cavit G (Figure 5).

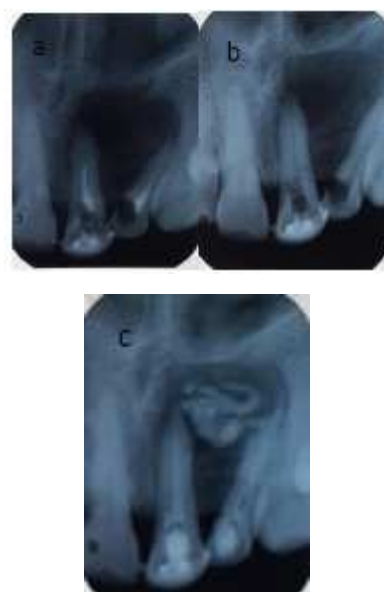


Figure 5. a. Pre-operative, b. Confirmation, c. extrusion $\text{Ca}(\text{OH})_2$,

Reapplication of the dressing was done 6 sequence during 5 months and evaluated radiographically, as demonstrated in Figure 6, a progressive involution of periapical radiolucency occurred.

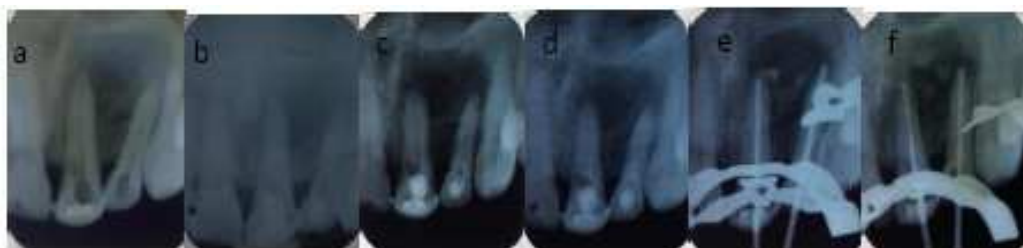

Figure 5 progressive involution of periapical radiolucency :

a. 1st recall (1 weeks); the reduction in size of the lesion, b. 2nd recall (4 weeks), c. 3rd recall (8 weeks), d. 4th recall (10 weeks), e. 5th recall (12 weeks), f. 6th recall (16 weeks); the lesion regressed

On the 6th recall, the patient reported total relief of symptoms and disappearance of the swelling. An evaluation was done radiographically, revealed signs of lesion size reduction. The calcium hydroxide was flushed out of the canals, so the teeth were obturated with gutta-percha and sealer AH Plus Dentsply, using the lateral compaction technique (Figure 6a). Root canal treatments were completed, the patient was recalled one week and 3 months after obturation when the whole of the lesion was healed completely (Figure 6b).

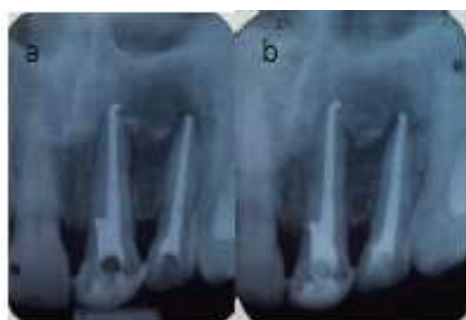

Figure 6 a. obturation, b. recall after 3 months obturation

Gutta-percha of tooth 21 was reduced about 16 mm from incisal and 22 was about

2 mm from orifice (Figure 7). Tooth 21 was reinforced with Luxa-Post DMG. Finally, the teeth 21 and 22 was directly restored with Composite 3M, Filtex 350.

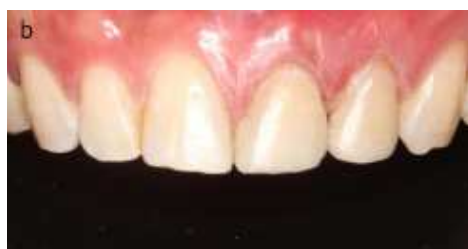

Figure 7 :a. reduction of Guttapercha, b. Final Restoration

DISCUSSION

Pulp necrosis due to trauma or caries that create a favourable environment for microorganisms to grow, are the

main ethiology of a large periapical lesion.⁴ Most periapical lesions (>90%) can be classified as granuloma, radicular cyst, and abscess. The incidence of cyst within periapical lesions varies between 6 and 55 %.^{1,2,3,5} Periapical cysts described as pocket cyst and true cyst. The pocket cyst has its cavity open to the root canal. Apical true cyst is enclosed by lining epithelium and may be attached to the root apex by a cord of epithelium. If the lesion is separated from the apex and with an intact epithelial lining (apical true cyst), it may have developed into a self-perpetuating entity that may not heal when treated non surgically. On other occasions, a large periradicular lesion may have direct communication with the root canal system (apical pocket cyst) and respond favourably to nonsurgical treatment.^{2,5,6}

Nonsurgical management of periapical lesion is preferred than surgical method and should be considered in selective case. The procedures include over instrumentation, aspiration - irrigation technique, and extrusion of Calcium Hydroxide beyond the apex.⁷

Bhaskar proposed to over instrument the canal by 1 mm beyond the apical foramen. This has been suggested to cause transient inflammation and break in the continuity of the epithelial lining of the cyst and thereby resolution of the lesion.^{1,4,8} Penetration of the apical area to the center of the radiolucency (lesion) would establish drainage and relieve the pressure. When the drainage ceases, there

would be proliferation of fibroblast in the area leading to the deposition of collagen. Thus, deposited collagen would compress the capillary network into the area of lesion leading to starving of the epithelial cells. The epithelial cells undergo degeneration and are finally engulfed by macrophages.^{1,9}

Aspiration through the root canal was used to eliminate the creation of Buccal wound as in traditional technique, which causes inflammation of mucosa and cause discomfort. It is a simple technique by using a gauge needle attached to a syringe, passing apical foramen. The growth of the cyst may be attributable to the increased hydrostatic pressure of the confined fluid, which causes additional osteoclastic activity. The aspiration – irrigation technique aids in decreasing the hydrostatic pressure in reducing osteoclastic activity, resulting in shrinkage of the lesion.^{1,2,10,11}

Bacterial population of infected root canal can be significantly reduced by irrigating the root canal. Irrigants that are currently used during cleaning and shaping include NaOCl, Chlorhexidine, EDTA, and aquadest. Sonic vibration, EndoActivator system, in combination with antibacterial irrigants for 1,5 minutes was an effective method to disinfect root canal.¹²

Calcium hydroxide is a material of choice in endodontic treatment because of its high alkaline and bactericidal effects, including neutralizing bacterial endotoxins.^{13,14,15} Buffering substance and systems are expected to function in the periradicular tissues, represented by the

bicarbonate system, phosphate system, protein, and carbon dioxide, which impede a significant increase in PH. Moreover, apically extruded calcium hydroxide paste is likely to be quickly diluted and inactivated in tissue fluid and exudate. In order to achieve the pH levels needed to exceed the tissue buffer capacity and thereby eliminate extraradicular microorganisms, a great amount of paste would have to be extruded.^{8,10,17,18,20,21} Souza et al, suggested the fourfold action of calcium hydroxide beyond the apex; anti-inflammatory activity, neutralization of acid products, activation of the alkaline phosphatase, and antibacterial action.^{3,7} Caliskan MK reported 73,8% success in non surgical management of large cyst like periapical lesions using calcium hydroxide medicament.^{19,20}

After completion of endodontic treatment, the outcome of teeth treatment with large periapical lesions should be determined on the basis of radiographic and clinical evaluations. Healing process was signed with periradicular radiolucency clearly decreasing in size. In addition to radiographic examination, the presence of any clinical signs or symptoms associated with the root canal-treated teeth should be noted at the recall appointment. For clinical success, there should be no pain or swelling, no mechanical allodynia on percussion or palpation, no sinus tract, and normal tooth mobility and function.¹⁵

CONCLUSION

In this case non-surgical endodontic treatment provides favourable results; clinically asymptomatic with sign of regression of lesions in radiography, therefore no surgical approach is needed for this case.

REFERENCES

1. Thomas K, Dhanapal P, & Simon EP. Management of Large Periapical Cystic Lesion by Aspiration and Nonsurgical Endodontic Therapy using Calcium Hydroxide Paste : Case Report. The Journal of Contemporary Dental Practice, November-Desember 2012; 13(6):897-901.
2. Tomar D & Dhingra A. Nonsurgical Root Canal Therapy of Large Cystic Periapical Lesions Using Simple Aspiration and LSTR (Lesion sterilization and Tissue Repair) Technique: Case Report and Review. Department of Conservative Dentistry and Endodontics, Shree Bankey Bihari Dental College and Research Centre, India. <http://dx.doi.org/10.4172/2161-1122.1000312>. June 2015.
3. Dandotikar D, et al. Nonsurgical Management of a Periapical Cyst: A Case Report. J Int Oral Health 2013; 5(3): 79-84
4. Mandhotra P, et al. Accelerated Non Surgical Healing of Large Periapical Lesions using different Calcium Hydroxide Formulations: A Case Series. International Journal of Oral

- Health and Medical Research/ISSN 2395-7387/November-December 2016/Vol 3/Issue 4.
5. Ramchandran Nair PNR, Pajarola G, Schroeder HE. Types and incidence of human periapical lesions obtained with extracted teeth. *Oral Surgery Oral Medicine Oral Pathology Oral Radiology Endodontic* 1996 JN:81 (1): 93-102.
6. Natkin E, Oswald RJ, Carnes LI (1984) The relationship of lesion size to diagnosis, incidence, and treatment of periapical cysts and granulomas. *Oral Surg Oral Med Oral Pathol* 57: 82-94.
7. Bansal R, Khursheed I, Bansal T. Endodontic Management of a PERiapical Cyst- A Review. *J. Adv Med Dent Scie* 2013; 1(1)
8. Bhaskar SN. Nonsurgical resolution of radicular cysts. *Oral Surg Oral Med Oral Pathol* 1972; 34
9. Bender IB. Commentary on General Bhaskar's hypothesis. *Oral Surg Oral Med Oral Pathol* 1972; 34:458-68.
10. Devakumari S, Rekha B, Dominic N. Non Surgical Management of PeriapicalCysts : A Review. *IOSR Journal of Dental and Medical Sciences (IOSR-JDMS)* e-ISSN: 2279-0853, p-ISSN: 2279-0861. Volume 15, issue 4 Ver.II (April 2016). PP 39-42. www.iosrjournals.org
11. Fernandes M & Ataide ID. Non-surgical management of a Large Periapical Lesion Using a Simple Aspiration Technique: A Case Report. *International Endodontic Journal*, 43, 536-542,2010.
12. American Association of Endodontists. Root Canal Irrigants and Disinfectans. Chicago. 2013. www.aae.org
13. Venugopal P, et al. Successful Healing Of Periapical Lesions With Non-Surgical Endodontic Approach. *Journal of Dental Sciences and Research*. February 2011. Volume 2 Issue 1.
14. Siqueira JF Jr, Lopes HP. Mechanisms of antimicrobial activity of calcium hydroxide: a critical review. *IntEndod J*. 1999; 32 (5): 361-9.
15. Siquiera JF. Treatment of Endodontic Infections. 2011.Jerman Angelo Stolle. ISBN: 978-1-85097-205-1.
16. Tanomaru JMG, et al. Effect of different irrigation solutions and calcium hydroxide on bacterial LPS. *IntEndod J*. 2003; 36(11): 733-9.
17. Maristela C, Aldrighi E, Evandro. Progression of Large Periapical Lesion using Calcium Hydroxide Therapy, a six- year follow up case report. *Brazilian Dental Science* 2015 Jan/Mar; 18(1). Doi: 10.14295/bds.2015.v18i1.1015
18. Andrade, et al. Healing of an extensive periapical lesion by means

- of conventional endodontic treatment.
Dental Press Endod. 2012 Oct-Dec; 2
(4): 65-9.
19. Magro MG, Kuga MC, Costa RR, Vencao AC, Vivan RR. Proposal of a minimally invasive technique for acute periapical lesion drainage: a case report and clinical strategy. Dental Press Endod. 2016 Sept-Dec; 6(3): 26-32. DOI: <http://dx.doi.org/10.14436/2358-2545.6.3.026-032.0ar>
20. [Caliskan MK. Prognosis of Large Cyst-like Periapical Lesions Following Nonsurgical Root Canal Treatment: A Clinical Review. IntEndod J 2004; 37\(6\): 408-16.](#)
21. [Valoi CS & Costa Junior ED. Periapical Cyst Repair After Nonsurgical Endodontic Therapy – Case Report. Brax Dent J 16\(3\) 2005](#)

CASE REPORT

ROOT CANAL TREATMENT AND RESTORATION USING METAL PREFABRICATED TAPERED SERRATED POSTS WITH PORCELAIN FUSED TO METAL FULL CROWN IN FAILURE ENDODONTIC TREATMENT

Dewi Damarsasi*; Diatri Nari Ratih**

*) Conservative Dentistry Resident, Faculty of Dentistry, Gadjah Mada University:

**) Staff of Conservative Dentistry Departement Faculty of Dentistry,
Gadjah Mada University

ABSTRACT

Background: The failure on endodontic treatment sometimes can lead to unpleasant pain and swelling. Endodontic treatment is still considered as a treatment of choice for such case because proper cleaning and shaping are mandatory. Restoration of endodontically treated tooth commonly uses posts as intracanal retention especially in molar tooth. Root canal treatment is used for removing bacteria from root canal, obturation with guttapercha and epoxy resin sealer, metal prefabricated tapered serrated posts inmesiobuccal and distolingual root canals, and full restoration with porcelain fused to metal crown. **Purpose:** This case report aims to present the success treatment of post-mummified necrotic root canal in lower left molar. **Case Management:** A 22-year-old male patient came with persistent pain in lower left back tooth. The tooth was previously treated with mummification 1 year ago. The cavity was found on the distooclusal with an exposed pulp chamber. Positive response to percussion test, negative to palpation test, negative to thermal test, and radiograph examination showed periapical lesions in mesial roots. Root canal treatment used crown down method, followed by obturation using guttapercha and epoxy resin sealer; metal prefabricated tapered serrated posts were placed in mesiobukal and distolingual root canals, and full restoration with porcelain fused to metal crown. Three months evaluation showed no complaints. **Conclusion:** Combination of metal prefabricated tapered serrated posts and full porcelain fused to metal restoration can be used as intracoronally and extracoronally reinforcement for endodontically treated tooth.

Keywords : failure endodontic treatment, metal prefabricated tapered serrated posts, full porcelain fused to metal restorations

Contact person: Dewi Damarsasi / 081328818458,

email: damarsasi.dewi@yahoo.co.id

INTRODUCTION

Pulpotomy was indicated to treat deciduous or young permanent teeth that sustained inflammatory on the coronal part of the pulp. This procedure was used to reduce pain in the emergency case before the proper endodontic treatment .¹ The success of endodontic treatment depends on the cleaning, shaping and obturation of the entire root canal system. Before initiating root canal treatment, a dentist should examine the tooth for caries and fracture. Assessment should also be evaluated on its restorability, occlusal function, periodontal tissue health, biological width, and crown-to-root ratio. All previous restorations and existing caries should be removed before initiating root canal treatment. This allows more accurate assessment of its restorability and evaluation for fractures.²

Endodontically treated teeth usually have great loss of structure so the reconstruction must be reinforced with several methods, for example they may require a post to retain the core restoration and one of the most used types is prefabricated post due to easy handling and low cost.³ The success of treatment, depends on the careful selection of cases based on clinical and radiographic examination. In other words, the treatment must be planned carefully to avoid accident, such as root fracture or extensive periodontal ligament damage.⁴

This case report aims to present a case of choosing and designing the final restoration for endodontically treated

left mandibular first molar with class II profunda caries, necrosis pulp, bifurcation and periapical lesions. The periapical radiographic examination shown there were superimposed at the distal and mesial roots. This tooth was treated with pulpotomy about a year ago.

CASE

A 22-year-old male patient referred to Departement Conservative of GadjahMada University with the chief complaint of persistent lower left back tooth pain. Clinical examination revealed a cavity in the disto-occlusal with an exposed pulp chamber (Figure 1) and after access opening, the orifices were covered with antibiotics paste (Figure 2). Periapical radiograph examination showed a decay exposing the pulp chamber in tooth #36 and superimposed at the distal and mesial roots (Figure 3). Tooth #36 was diagnosed as a class II profunda caries with pulp necrosis, with periapical and bifurcation lesion. The treatment planning for tooth #36 was prefabricated metal post with PFM crown as the final restoration.

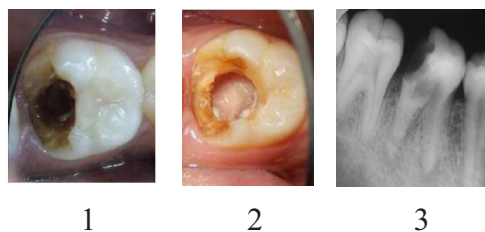


Figure 1. Clinical examination revealed a cavity on the disto-occlusal surface of tooth #36. Figure 2. After access opening. Figure 3. Periapical radiograph

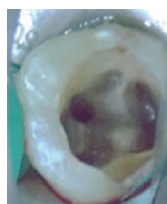
examination showed a decay exposing the pulp chamber in tooth #36 and periapical lesion

In the first visit, anamnesis, clinical examination, radiographic examination, diagnosis and treatment planning were done. The patient was explained about the treatment planning and was asked to sign the informed consent. Removal of carious lesion, construction of an artificial wall was made with glass ionomer cement using universal matrix band at the distal wall. The orifice was isolated with guttapercha. Isolation with a rubber dam and then access opening was made on tooth #36 by endo access bur (Dentsply) which revealed 4 orifices (distolingual, distobuccal, mesiolingual and mesiobuccal) (Figure 4). Exploration of these canals with a C Pilot file size no. 6, no. 8, no. 10 and K-file size no. 15. Working length was determined using apex locator (*Dentaport ZX, Morita*) and confirmed with a radiograph (Figure 5). The working length of all of the root canals were 18 mm.

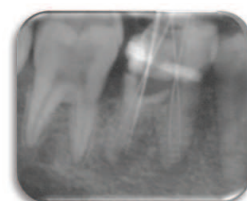
The canals were cleaned and prepared using crown down technique with ProTaper hand use (Dentsply) in sequence to obtain the tug back until file F3. After using each file, the canals were irrigated using 2,5% sodium hypochlorite (NaOCl) and sterile aquades, and the preparation of root canal lubricated with EDTA 15 % gel (WellPrep, Vericom). Finishing of preparation followed by apical gauging to determine that preparation was adequate with the last

file K-file # 30 along the working length of each root canal. Canals were dried with sterile paper points, filled with calcium hydroxide paste (Ultracal, Ultradent) as intracanal medicament and filled with temporary filling (Cavition, GC).

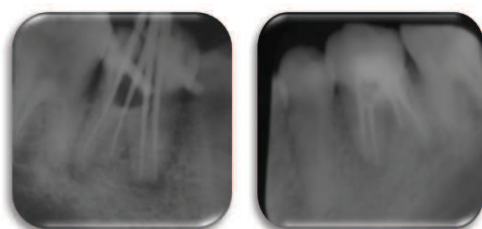
In the second visit, one week later, calcium hydroxide was removed with sodium hypochlorite and gutta-percha points for each canal were fitted and confirmed with radiograph (Figure 6). Root canals were irrigated with 2,5% sodium hypochlorite, 17% EDTA, 2% chlorhexidine, sterile aquadest between solutions and dried with sterile paper points. Gutta-percha point size F3 was sterilized by soaking in a solution of 2.5% NaOCl for 1 minute and rinsed with alcohol. Then Master Point fitting with gutta-percha F3 were done in all root canals. Obturation for each canal was carried out using single cone guttapercha along with epoxy resin endodontic sealer (Top Seal, Dentsply). The gutta-percha was cut 2 mm to apical from orifice and vertical condensation performed using plugger. Glass ionomer cement (Fuji II LC, GC) as barrier was placed and tooth was filled with temporary filling and radiograph was taken to confirm the obturated canals (Figure 7).



4



5



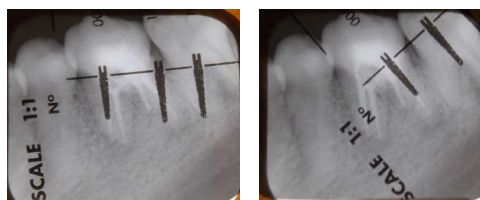6

7

Figure 4. there were the orifices (2 canal distal and 2 canal mesial). Figure 5. Confirmation WL with radiograph. Figure 6. Try in gutta-percha F3.;Figure 7. Obturation

In the third visit, 7 days after second visit, the clinical examination, the temporary filling was good. Subjective examination showed no complain. Objective examinations of tooth 36 showed mobility (-), percussion (-) and palpation (-).The preparation of the tooth 36 incervical line was conducted by using round-ended tapered diamond burs, fissure bur and wheel-shaped diamond burs.

Guttapercha in the distobuccal and mesiolingual root canal were removed by using warm plugger, Peeso reamer (Largo, Dentsply) then a precision drill of the metal post left approximately 4–5 mmguttapercha in the area from the apex of the root canal. Metal prefabricated tapered serrated posts were fitted in the root canals. Then the radiographic picture was taken to confirm the diameter and length of the posts whether they were proportional with the root canal circumstances (Figure 8a and 8b).



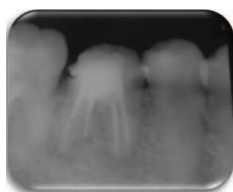8a

8b

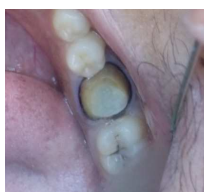8a. Radiographic picture to confirm the diamater and length of post at the mesiobuccal canal

8b.Radiographic picture to confirm the diamater and length of post at the distolingual canal

Silane was applied to the fitting surface of the metal post. The distolingual, mesiobuccalcanals and cavosurfaces were etched by 35% phosphoric acid for 10 seconds then rinsed by water and dried with moist cotton pellet and paper points. Then bonding was applied on microbrush to the cavosurface and paper points to rub the canals then cured for 10 seconds. By using a paste carrier the resin cement (Built It-FR, Pentron) was applied to the mesiobuccal and distolingual root canals, then the tapered serrated posts (Unimetric, Dentsply) were inserted and cured for 20 seconds. Furthermore, the core posts were made by using composite resin (P 60, 3M). Then the radiographic picture was taken (Figure 9a). The #36's core clinical appearance (Figure 9b).



9a



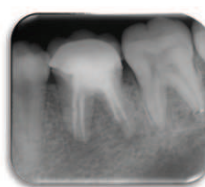9b

Figure 9a. The radiographic picture of core and posts using composite resin and metal post

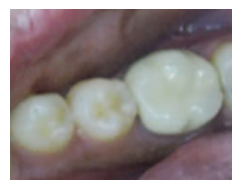Figure 9b. The clinical appearance of core and posts using composite resin and metal post

Retraction cord (Ultrapak, Ultradent) was packed into the gingival sulcus, then impression was done for the lower jaw with double impression technique, using polyvinyl siloxane (Exaflex, GC Corporation) and impression of antagonist jaw was made using irreversible hydrocolloid (Aroma, GC). Then the bite record was taken. Determination of tooth color was done with Shade Guide (A-D Shade Guide, Ivoclar Vivadent) and the color of the porcelain fused to metal crown was decided as the A3. The molding results in the form of a working model in occlusion along with the bite record were sent to the laboratory for processing. Tooth color and design of the crown was informed to the dental laboratory. The next stage was setting temporary crown and temporary cementing was done to avoid fracture of the crown. And then the casts were sent to dental laboratory for making porcelain fused to a metal jacket crown.

In the fourth visit, one week later, there was subjectively no complaints and no clinical abnormalities in the oral cavity of patient. Temporary crown was removed and then the trial of porcelain fused to metal (PFM) crown was done. It was seen that the crown had a good contact area, margin adaptation, occlusion and articulation. Anatomy and the tooth color matched with the expectation. Porcelain fused to metal crown were cemented using self-adhesive bonding technique (Rely-X, 3M). Then the radiographic picture was taken (Figure 10a). The #36's clinical appearance after crown insertion (Figure 10b).



10a



10b

Figure 10a. The radiographic picture of porcelain fused to metal jacket crown

Figure 10b. The clinical appearance of porcelain fused to metal jacket crown

In the next visit, a week after the insertion of crown, subjective and objective examinations were evaluated and no abnormalities were found. Evaluation after 1 month, 3 month after, were done, showing no abnormalities or complaints. The patient was finally asked for evaluation in 6 months and 1 year after the treatment.

DISCUSSION

The tooth was previously treated with mummification 1 year ago. The patient did not continued the endodontic treatment. Until a year after mummification he felt persistent pain on lower left back tooth. Pulpotomy or mummification considered as emergency treatment then continued with endodontic treatment because this treatment was suggested only for deciduous or young permanents dentition. Pulpotomy procedures can be classified into 2 procedures: amount of pulpal tissue removed and type of medicament applied. In this case, using removal pulpal tissue was done based on amount of removal pulpal tissue removed.¹

Normally, mandibular first molar had 3 canals, a canal in distal and to canals in the mesial. But in this case, there were 2 canals and 2 orifices in mesial and distal. The access opening in this case was rectangular shape.¹ Important aim of endodontic therapy is to eliminate microorganisms from the root canal. Instrumentation, irrigation, and intracanal medications significantly reduce the population of microorganisms inside the infected root canal.⁵

This case used calcium hydroxide as dressing because of its antimicrobial activity. It is related to the release of hydroxyl ions in an aqueous environment. Hydroxyl ions are highly oxidant free radicals that show extreme reactivity with several biomolecules. This reactivity is high and indiscriminate, so these free radicals rarely diffuse away from sites of

generation. The lethal effects of hydroxyl ions on bacterial cells are probably due to the following mechanisms: damage to the bacterial cytoplasmic membrane; protein denaturation; and damage to the DNA.⁶

Molar teeth accepts vertical force loads when they were used to chew.⁷ Posts that were used in this case are made from titanium. They are biocompatible, strong, good mechanical properties, safe, distribute pressure and protect the remaining dental tissue.⁴ Parallel self-threading post has parallel shape and it has lamellas so if the force on to the tooth would be forwarded to the root. This mechanism causes tooth to have high fracture resistance.⁷

Composite core materials have been shown to exhibit slightly better mechanical values than conventional materials. The advantages of composite core resins are adhesive bonding to tooth structure and many posts, ease of manipulation, rapid setting, and translucent or highly opaque formulations. Bond strength of composite cores to dentin depends on a complete curing of the resin materials, so dentin bonding agents must be chemically compatible with composite core materials. A degradation of the resin core or the marginal integrity of the crown can result in invasion of oral fluids. Therefore, as with all buildup materials for decimated teeth, more than 2 mm of sound tooth structure should remain at the margin for optimal composite resin core function.¹

Composite core materials can be used in association with metallic posts.

Composite core materials are typically two-paste, self-cured composites, but light-curing materials are also available. The use of light-curing composite core materials generally eliminates the risk of chemical incompatibility between adhesives and self-curing resin core materials. Bonding light-cured resin composites to the irregular structure of the pulp chamber and canal orifices might eliminate the need for a post when sufficient tooth structure remains. Research indicates that bonding to the dentin walls of the pulp chamber is easier and superior to resin dentin bonds made on dentin canal walls.⁸

Silane was used to improve the bonding of dental adhesives to porcelain and metals. Silane agents are organic silicides with a chemical structure expressed as X_3SiY , where X is a chloro, alkoxy, or acetoxo group. These groups can be easily changed to an alkoxy group by hydrolysis, which generates covalent bonding or hydrogen bonding with alkoxy groups on the surface of inorganic materials. The Y group contains a reactive group, such as a vinyl, epoxy, amino, or mercapto group, which combines with organic materials. These two reactive groups improve interface adhesiveness.⁹ Silane was used to improve the bonding of dental adhesives to porcelain and metals. Silane agents are organic silicides with a chemical structure expressed as X_3SiY , where X is a chloro, alkoxy, or acetoxo group. These groups can be easily changed to an alkoxy group by hydrolysis, which generates covalent

bonding or hydrogen bonding with alkoxy groups on the surface of inorganic materials. The Y group contains a reactive group, such as a vinyl, epoxy, amino, or mercapto group, which combines with organic materials. These two reactive groups improve interface adhesiveness.⁹

Porcelain fused to metal (PFM) crown strength is provided by the metal substructure, and a porcelain veneer provides esthetics. Porcelain fused to metal (PFM) crowns are used to restore badly broken down teeth to protect remaining tooth structure. It may also be responsible for maintaining occlusion and providing aesthetics. Crown margins should blend with the tooth structure without overextension, marginal gaps and underextension.¹⁰

CONCLUSION

The selection of final restoration for endodontically treated teeth should consider the amount of the remaining coronal tissue after root canal treatment, patient's prosthetic and esthetic needs. Moreover, a dentist should also consider the restorative prognosis, the periodontal prognosis, the skill of the dentist, and available technology. With proper considerations then a dentist can make a proper final restoration for each specific case.

The best results for restorations of endodontically treated teeth depend on the quality of the root filling and the coronal restoration, as well as the patient's

general health status. good oral hygiene, caries prevention strategies, and stable periodontal disease status should be in place to support optimal outcomes for these teeth.¹¹

REFERENCES

1. Chandra, B.S., Krishna,G.P., Grossman's Endodontic Practice Twelfth Edition, 2010, Wolters Kluwer, India, PP; 310-336
2. Schwartz R, Jordan R. Restoration of endodontically treated teeth: The endodontist's Perspective. Endodontics: Colleagues for Excellence. 2004: 1-6
3. Go'mez-Polo, M., Llido', B. , Rivero, A., del Rí'o, J., Celemi'n, A., 2010, A 10-year retrospective study of the survival rate of teeth restored with metal prefabricated posts versus cast metal posts and cores, Journal of Dentistry 38 2010;916 – 920
4. Pitt Ford TR, Harty'sEndodontics in Clinical Practice, 5th ed. , Elsevier limited, 2004; 134-139.
5. Hargreaves KM, Cohen S. Pathway of The Pulp. 10th ed., St. Louis: Mosby Inc; 2011.
6. Mohammadi Z, Dummer PMH. Properties and applications of calcium hydroxide in endodontics and dental traumatology. IntEndod J 2011;44:697-730.
7. Al-Wahadni AM, Hamdan S, Al-Omiri M, Hammed MM, Hatamleh MM. Fracture resistance of teeth restored with different post systems: in vitro study. Oral Surg Oral Med Oral Pathol Oral RadiolEndod. 2008; 106: e77-e83.
8. Dietschi, D., Bouillaguet, S., and Sadan, A., Cohen's Pathways of the Pulp, Chapter 22, 818-848
9. Nihei T, Dental applications for silane coupling agents, Journal of Oral Science, 2016; 58: 2, 151-155
10. Sadaf D, Ahmad M.Z., Porcelain Fused to Metal (PFM) Crowns and Caries in Adjacent Teeth, Journal of the College of Physicians and Surgeons Pakistan 2011, 21 (3): 134-137
11. Eliyas S, Jalili J, Martin N, Restoration of the root canal treated tooth, Br Dent J 2015, 218:53-62

CASE REPORT

APICAL RESECTION FOR PERIAPICAL CYST TREATMENT CASE

Diana Soesilo

*Department Conservative Dentistry of Hang Tuah University

ABSTRACT

Background. Radicular cysts or periapical cysts are the most common cystic lesions in the jaws. They arise from the epithelial remnants in the periodontal ligament as a result of the stimulus from periapical infection following pulpal necrosis. They found mostly near apex of the teeth. Periapical surgery can be treatment choice in extensive periapical lesion. **Purpose :** The main goal of apical surgery is to prevent bacterial leakage from the root-canal system into the periradicular tissues by placing a tight root-end filling following root-end resection. **Case.** 40-years-old male patient with # 11 and # 12 nonvital post-endodontic treatment 5 months ago, but patient still felt dull pain around the teeth and soft fluctual swelling on labial vestibular. On radiological examination, there was large periapical radiolucency in relation to #11 and #12. **Conclusion.** Various treatment option have been suggested depending on the size and location of cyst. The clinical case reported in this article was managed successfully by endodontic therapy followed by surgery.

Key words : periradicular cyst, apical resection, post endodontic treatment

Correspondence : Diana Soesilo. Faculty of Dentistry Hang Tuah University. Arif Rahman Hakim 150. Phone. +62 31 5912191. E-mail : dianasoesito@yahoo.com

BACKGROUND

Radicular cysts are the most common inflammatory jaw cysts and develop as a sequel of untreated dental caries with pulp necrosis and periapical infection. Around 60% of all jaw cysts are radicular or residual cysts. This cyst represents a chronic inflammatory process and develops only over a prolonged period of time.¹

These cysts can occur in the periapical area of any teeth, at any age but are rarely associated with primary dentition. It is

more frequent in maxillary than mandibular teeth.^{2,3}

Most of the radicular cyst are symptomless and are discovered when periapical radiograph are taken of teeth with non-vital pulps. Patient often complains of slowly enlarging swellings. Radiographically, radicular cyst appears as an oval or pear shaped unilocular radiolucency in the periapical region. The cyst may cause tooth displacement adjacent or mild root resorption. The treatment options

for radicular cyst can be conventional nonsurgical root canal therapy for smaller lesion to surgical treatment like enucleation, marsupialization or decompression for larger cysts.³

Apical surgery belongs to the field of endodontic surgery that also includes incision and drainage, closure of perforations, and root or tooth resections. The objective of apical surgery is to surgically maintain a tooth that has an endodontic lesion which cannot be resolved by conventional endodontic retreatment. A common example is a tooth with acceptable endodontics and a new post and crown restoration, but a persistent or enlarging periapical lesion.⁴

CASE

40 years old male patient with #11 and #12 post endodontic treatment 5 months ago. The teeth had already restored with all porcelain crown. After treatment, patient still felt dull pain around his anterior teeth. Palpation test there was present of soft fluctual swelling on labial vestibular #11 and #12 (Figure 1).

On radiological examination, there was large periapical radiolucency in relation to #11 and #12 (Figure 2). Affected teeth were slightly tender on percussion and showed grade 1 mobility.

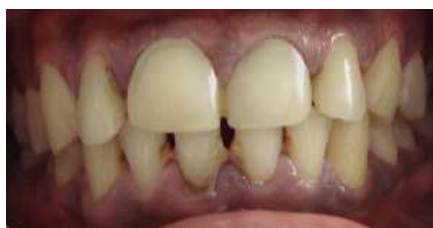

Figure 1. Intra oral condition

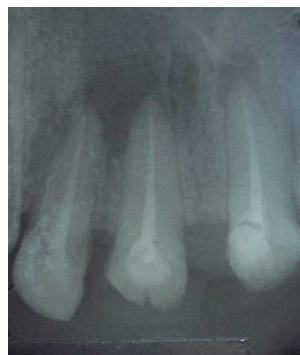

Figure 2. #11 and #12 radiographic examination

CASE MANAGEMENT

To perform the surgical procedure, suprapariosteal and subperiosteal anesthetic techniques were adopted. The topical anesthetic used was benzocaine and the local anesthetic was lidocaine with epinephrine 1:200.000. Semilunar flap was made at labial tooth #11 and #12 (Figure 3). The periapical exposure must be satisfactory, to make the injury visible. Existing cortical bone was exposed.

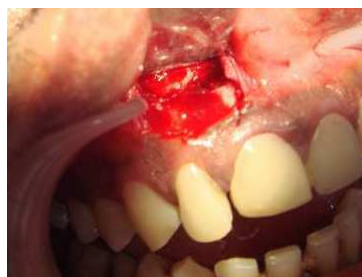

Figure 3. Semilunar flaps was made at labial tooth #11 and #12

Apical portion was cut in 45° related to tooth long axis with inverted bur. Surgical site irrigation was executed with water for injection (Figure 4)

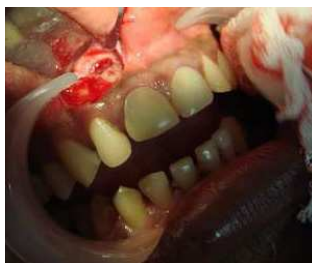

Figure 4. Apical portion was cut 45° with inverted bur

For root end filling material used MTA (Mineral Trioxide Aggregate). Material was transported using cement stopper. Cortical bone loss was filled with bone graft.

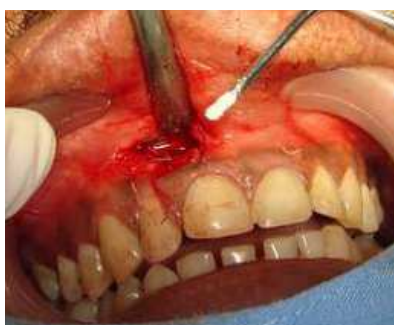

Figure 5. Root end filling material with MTA

The flap was repositioned and fixed with moderated digital pressure and moist gauze. Suturing was made with silk thread 3.0 performing simple stitches.

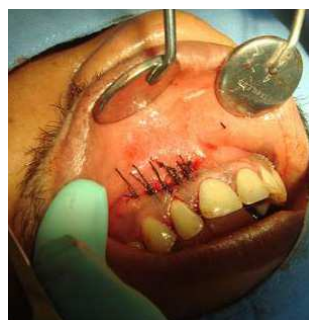

Figure 6. The flap was repositioned and sutured

The postoperative medication prescribed to the patient, was Amoxicillin 500mg every 8 hours for 5 days in therapeutic regime, kaliumdiclofenac 50mg every 8 hours for 3 days. To oral hygiene, it was prescribed 0.12% chlorhexidine solution twice a day. The patient returned after 7 days for suture removal.

DISCUSSION

Cysts form in the periradicular tissues when nests of epithelial cells, retained from tooth development, begin to proliferate due to the chronic presence of inflammatory mediators. These epithelial cell rests of Malassez are the source of the epithelium that lines cystic walls, and cyst formation may be an attempt to help separate the inflammatory stimulus from the surrounding bone. The incidence of periapical cysts has been reported to be 15% to 42% of all periapical lesions, and determining whether a periapical radiolucency is a cyst or the more common periapical granuloma cannot be done with available radiographic methods. There are two types

of periapical cysts: theperiapical true cyst and the periapical pocket cyst. True cystshave a contained cavity or lumen within a continuous epitheliallining and are therefore isolated from the tooth, whereas withpocket cysts, the lumen is open to the root canal of the affectedtooth. True cysts, due to their self-sustaining nature, probablydo not heal following nonsurgical endodontic therapy andusually require surgical enucleation.⁵

The pathogenesis of radicular cysts involves the phase ofinitiation, cyst formation, and the phase of enlargement. Initiation is mostly from the odontogenic epithelium. Cell rests of Malassez in theperiapical PDL got stimulation from the pulpal infection and they cause proliferation of the epithelium and form cellular arcades at periapicalregion. A key factor, which may initiate the inflammation and immune response and may directly cause epithelial proliferation, is now thought to be bacterial endotoxins released from the necrotic pulp. Treatment for large lesion involves tooth removal andsurgical curettage of the apical area.⁶

According to thelocation of the swelling, surgical approach is made. Indication for endodontic surgery are periradicular disease associated with a tooth where iatrogenic or developmental anomalies prevent non-surgical root canal treatment being undertaken, Periradicular disease in a root-filled tooth where non-surgical root canal retreatment cannot be undertaken or has failed, or when it may

be detrimental to the retention of the tooth (e.q obliterated root canals, teeth with full coverage restorations where conventional access may jeopardise the underlying core, the presence of a post whose removal may carry a high risk of root fracture), where a biopsy of periradicular tissue is required, where visualisation of the periradicular tissues and tooth root is required when perforation or root fracture is suspected, where it may not be expedient to undertake prolonged nonsurgical root canal retreatment because of patient considerations.⁷

Apicoectomy consists in the surgical removal of tooth apical portion. It can be indicated in several clinical situations: periapical lesions persistent to conventionaltreatment,perforations, fractured instruments, apical delta removal and external absorption presence. Apical portion was cut in 45° related to tooth long axis. Open apex were closed with MTA.⁸

For root-end filling, a variety of materials have been propagatedin the past. Almost every material that was introduced in operative and restorative dentistry as a temporary or permanent (gold, amalgam, resin composite, glass ionomerecement, compomere, etc.) restoration material was sooner or later also utilized in apical surgery. However, mineral trioxide aggregate (MTA) appears to have become the gold standard for a root-end filling material.⁴

MTA, whenused as a root-end filling material, showed evidence of healing

of the surrounding tissues. Studies have shown that osteoblasts have favorable response to MTA as compared to IRM and amalgam. With longer duration, new cementum was found on the surface of the material. MTA is a widely accepted retrograde filling material which is biocompatible, has antibacterial action and reduces microleakage. MTA plugs of four-millimeter thickness have been shown to be the most efficient with respect to root canal sealing ability and resistance to displacement.^{6,9}

CONCLUSION

Various treatment options have been suggested depending on the size and location of cyst. The clinical case reported in this article was managed successfully by endodontic therapy followed by surgery. It is suggested that the treatment of the radicular cysts should be defined according to the clinical and radiographic evaluations according to each case.

REFERENCES

1. Brave D, Madhusudan A.S, Rames G, Brave V.R. Radicular Cyst of Anterior Maxilla. International Journal of Dental Clinics. 2011;3(2):16-17
2. Mantu V.K, Mitra R. Radicular Cyst, a Case Report and its Histopathological Analysis. International Journal of Advanced Health Sciences • Vol 2 Issue 5 • September 2015; 9-12
3. Vijay P, Singhal I, Singh N, Gupta A, Bhadrawaj G, Jain J. Radicular Cyst and Its management : A Case Report. Int J Dent Med Res 2015;1(5):80-81
4. Arx T. Apical Surgery : A Review of Current Techniques and Outcome. The Saudi Dental Journal (2011) 23, 9–15
5. Cohen S. and Hargreaves KM. 2016. Cohen's Pathways of The Pulp. 11th Ed. Mosby Elsevier. Missouri. p. 646-655.
6. Raval RD, Nyklesh V, Patel HM, Patel PP, Naik PS. Management of Infected Radicular Cyst in Maxillary Anterior Region : A Case Report. International Journal of Advanced Health Sciences .1 (11). 2015. 8-11.
7. Evans GE, Bishop K, Renton T. 2012. Guidelines for Surgical Endodontics. 2nd Ed. Royal College Surgeons of England. P. 2-9
8. Verghese GM, Thomas G, Kutappa MA, Govind GK. Management of Large Apical Cyst (Apical Matrix and Surgical Compilation) – A Case Report. Was taken from medind.nic.in/eaat09/i2/eaat09i2p82.pdf. P.84-89
9. Coneglian PZA, Orosco FA, Bramante CM, Moraesl G, Gracia RB, Bernardinelli NJ. In Vitro Sealing Ability of White and Gray Mineral Trioxide Aggregate (MTA) and White Portland Cement Used as Apical Plugs. International Appliance Oral Science. 2007;15(3):181-5

CASE REPORT

THE AESTHETIC REHABILITATION OF THE MAXILLARY INCISORS AND SUPRAPOSITION OF THE MANDIBULAR CENTRAL INCISORS

Andina Irinawati Prasetyo¹, Sri Kunarti²

¹ Resident of Department Conservative Dentistry.

² Staff of Department Conservative Dentistry

Faculty of Dental Medicine–Airlangga University Surabaya –Indonesia

Background: The most common cause of tooth structure loss is caries. Normal occlusal load on structurally compromised teeth could be traumatic, thus increasing the risk of fracture. The severity of such condition in the anterior teeth can negatively affect patient confidence. **Objective:** To treat fractured maxillary incisors and mandibular central incisors with supraposition. **Case:** A 23-years-old woman came with a chief complaint of unaesthetic upper front teeth. Clinical examination found fractured teeth 11, 21 to the extend of 2/3 of the crown length. There was class III carious lesion (Black Classification) on 21, 22, and 41. 31 was on supraposition as high as 5 mm. Pulp vitality examination resulted in 11, 21 to be non-vital, while 12, 22, 31, and 41 were vital. Radiographic examination revealed a radiolucency on the periapical of 11. 11 and 21 were diagnosed as necrosed pulp, 12 and 22 as reversible pulpitis, and 31 and 41 as healthy teeth. **Treatment:** Root canal treatment on 11, 21, and intentional root canal treatment on 31, 41 were performed in one visit. Endodontic post (fiberpost) were used to reinforce the core retention and e-max crowns were used to restore those teeth subsequently. 11 and 22 were restored with composite resin restorations prior to performing indirect veneers restoration. The 3-months control shows restoration of physiologic function and aesthetics. **Conclusion:** Meticulous planning, through communication, and evidence based treatment are paramount in achieving success and satisfaction in aesthetic rehabilitation.

Keyword: Tooth crown fracture, caries, supraposition tooth, aesthetics complex.

Correspondence: Andina Irinawati Prasetyo; Resident of Conservative Dentistry, Faculty of Dental Medicine, Airlangga University, Surabaya, Indonesia. E-mail: andina.irinawati@gmail.com. Mobile: +628115380123

BACKGROUND

Caries is the most common cause of tooth structure loss. Based on RISKESDAS 2013, the prevalence of caries in Indonesia is 53,2%.¹ Caries is caused by bacterial invasion in dental plaque which formed

by food debris, causing demineralization until making tooth frail and decayed.² Caries with greater loss of enamel and dentine structure could possibly increase trauma incident.³ Trauma is the second most common cause of tooth structure

loss.⁴ Tooth trauma can increase the risk of dental pulp injury on anterior and posterior teeth.⁵ The incident of crown tooth fracture with dental pulp injury is 16% of the total incident on tooth fracture.⁵

Upper anterior teeth fracture occurred more frequently in trauma cases, most of the patient complain about the loss of upper anterior teeth make them less self-confidence, or even worse, contribute to supraposition of its teeth antagonist.^{6,7} Supraposition is a tooth growth disturbance caused by damage or loss of tooth antagonist and may results movement of tooth antagonist to compensate premature contact occlusion. The prevalence of supraposition tooth is 24%.⁸

This case needs precise and prompt treatment due to psychological and aesthetic aspect of the patient.⁸ After patient evaluation, there were two possible options treatment plan. The treatment plan could be either intentional endodontic or orthodontic. Orthodontic treatment would take a long time, while intentional endodontic is less time-consuming.⁸

Precise and prompt endodontic treatment is suitable to minimize further damage on the remaining tooth structure or periodontal tissue.⁹ One visit endodontic is a root canal treatment sequence which included clearance, sterilization, and obturation of tooth root canal in one appointment.⁹ One visit endodontic usually performed on tooth trauma or supraposition tooth case (intentional endodontic). The following case report describes one visit

endodontic, then continued by post and core build up. The following case used fiber post material and porcelain full crown restoration (e-max).

CASE

A 23-years old female attended a Conservative Dentistry Department in Unair Dental Hospital (RSGM UNAIR), her chief complaint was the presence of tooth cavity and tooth fracture on upper anterior teeth. The patient also complained her lower anterior teeth look elongated to its adjacent teeth (figure 1, 2, and 3).

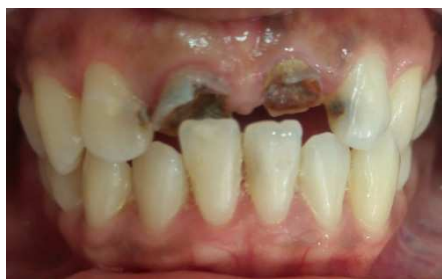

Figure 1: Labial side

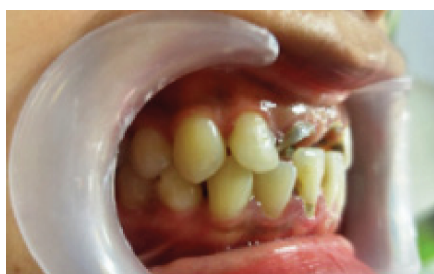


Figure 2 : Right side

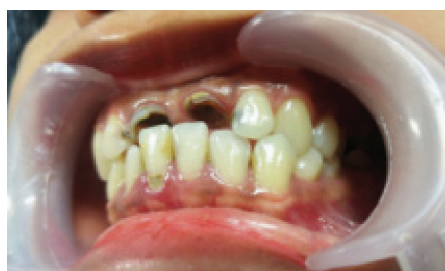

Figure 3 : Left side

The teeth involved has no history of pain. Patient hoped her teeth could be treated simultaneously.

Subjective examination revealed teeth 11 and 21 were fractured greater than 2/3 crown fracture and pulp exposed, tooth 12 and 21 was caries class III Black's with slight labioversion on distal side, tooth 31 and 41 was supraposition. Objective examination revealed tooth 11 and 21 was negative to thermal test, while tooth 12, 22, 31, and 41 were positive to thermal test. The involved teeth gave no respond to percussion test. Periapical radiograph showed periapical lesion on tooth #11.

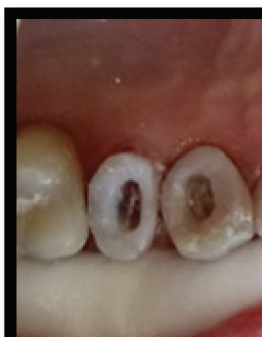

Figure 4: Periapical lesion on tooth 11

From subjective, objective and radiographic examination, a diagnosis and treatment plan was made. The diagnosis was necrotic pulp on teeth 11 and 21, reversible pulpitis on teeth 12 and 22, supraposition on teeth 31 and 41.

The treatment plan for this case was one visit endodontic for teeth 11 and 21, composite resin restoration for teeth 11 and 21, continued by indirect veneer. Intentional endodontic by one visit endodontic were performed on teeth 31 and 41.

CASE MANAGERMENTS

Model study and Wax-up model study were made from alginate Impression of upper and lower teeth. Wax-up model was made to explain current condition of teeth condition and the treatment plan to the patient (Figure 5 and 6).

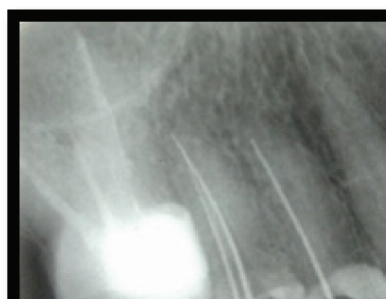

Figure 5 : Study Models

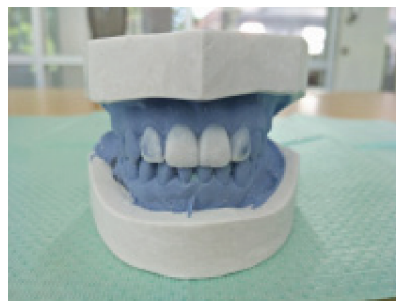

Figure 6 : Model Wax Up

In the next day, Root canal treatment was performed on teeth 11 and 21, and Intentional endodontic were performed on tooth 31 and 41. The treatments were performed on the same day. Asepsis was done using povidone iodine 10% on labial and palatal teeth surfaces before injecting local anesthesia. Local anesthesia was achieved using lidocaine 2%. Working area was isolated by using a rubber dam.

Access opening on teeth 11, 21, 31, and 41 were made using endo access bur.

Glide path was achieved using c-pilot (VDW, Germany) no 8 and 10, with 25mm length. Working length was measured using Apex Locator (Morita, Japan) and c-pilot (VDW, Germany) no 15 with 25 mm length. The working length of tooth 11 was 16mm, tooth 21 was 18 mm, and both teeth 31 and 41 were 21 mm. The Working length and root canal length were matched by using radiographic.

Glide path was confirmed using Proglider (Dentsply, Maillefer) before root canal preparation. Cleaning and shaping were achieved using crown down pressureless with Endomotor (Dentsply, Maillefer). The root canal was prepared using Proglider, continued with Protaper X4 for tooth 11, and X3 for tooth 21, 31, and 41.

During cleaning and shaping process, each instrument was coated using EDTA cream (MetaBiomed, Korea) to ease the instrument inserted into the root canal. Irrigation between instrument was done using NaOCl and request solution. After preparation, the root canal was cleaned and dried using paper point. Gutta percha trial was performed using protaper next gutta-percha matched with the last number of instrument used and confirmed by radiograph (Figure 7).

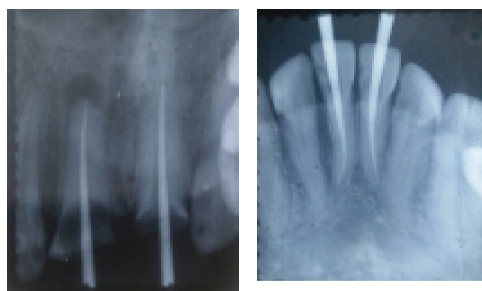


Figure 7 : Trial Guttap Photo

The root canal was sealed using single cone technique of gutta percha and AH 26 (Dentsply, Maillefer) as a sealer. Excess of gutta percha was cut using a hot excavator. Final obturation result was reviewed by using radiograph. The tooth cavity were subsequently closed by temporary restored using temporary cement and patient was instructed to be followed-up in a week. After one-week follow-up post obturation, the root canal was controlled with no complaint on subjective examination, no respond on percussion test. The follow-up of radiograph showed hermetic obturation on the root canal. On the third visit, gingival management was performed by crown lengthening technique on teeth 11 and 21. The margin of crown lengthening was determined by measuring gingival sulcus depth using a probe. Asepsis on working area was done using povidone iodine. Local anesthesia was achieved using 2%-xylocaine. Excision of gingiva was achieved using scalpel and blade no. 15. A periodontal pack was placed to close the wound for 1 week. In the fourth visit, the wound still closed by the periodontal pack. The gingival wound was reviewed and no any problem found (Figure 8).

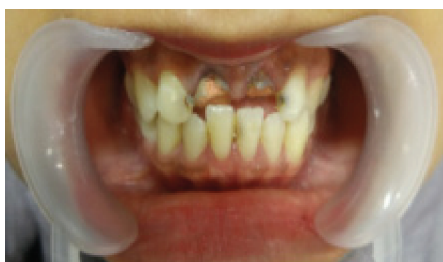

Figure 8 : Crown lengthening

Post endodontic was prepared using fiber post Luxapost (DMG, USA) material. The wide of fiber post was adjusted with fabric's template. Gutta percha point was reduced 2/3 of canal length or at least as long as crown length using drill from fiber post.

The trial of fiber post restoration was evaluated using radiograph. After fiber post matched with the root canal, insertion was performed. The root canal was etched using phosphoric acid 37% for 10 seconds and rinsed using aquadest. The root canal was dried using three-way syringe. The root canal and etched-fiber post was applied bonding agent before inserted fiber post into the root canal. Fiber post was inserted to the root canal using dual cure resin. The excess of resin was cleaned up and cured by light cure for 20 seconds (Figure 9).

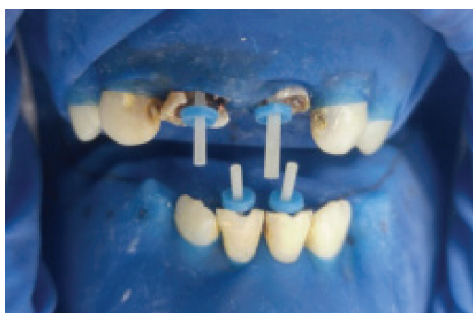


Figure 9 : Fiber Post Insertion

After fiber post cementation, excess of fiber post was removed using diamond bur. Gingival management was performed by placing ultrapack retraction cord (Ultradent, USA) around cervical tooth. Core built up achieved using Multi-core (Ivoclar Vivadent, USA) with layering technique to shape the crown. Then, teeth was impressed to make temporary crown. The labial, proximal, palatal and incisal tooth surfaces was prepared using fissure diamond bur. Chamfer was made for finish line design preparation on tooth cervical. After tooth preparation was done, temporary crown was placed using Freegenol (GC, Belgia). Patient was instructed to treat caries on the next visit. Based on diagnostic wax, teeth 12 and 22 with class III caries Black's with slight labioversion on distal side were planned for veneer indirect porcelain treatment. Removal of caries and resin composite restoration using Filltek Z 250 (3M ESPE, USA). Then, temporary veneer was made.

The Preparation started from choosing shade guide for tooth color. 2%-Xylovaine local anaesthetic solution was injected into labial and palatal of teeth 11 and 22. Veneer preparation was started by using depth cutting bur to control the preparation depth. Enamel surface was reduced using cylindrical round-end diamond bur to shape chamfer as finish line on cervical tooth. Enamel surface was reduced for 1-1,5 mm depth. Enamel surface reduction on distal side of labioversion teeth 12 and 21 were greater than mesial side. After preparation,

preparation alignment, interdental space between preparation teeth, contact relation to antagonist teeth were evaluated.

Retraction cord was placed on prepared teeth using Ultrapak 000 (Ultradent, USA). Dental impression was made using elastomer with one step technique to make die model, while teeth antagonist was impressed using alginate. Bite record was taken, and tooth shade was matched using shade guide. Temporary crown was placed on prepared tooth using temporary cement (GC, Belgia) (Figure 10 and 11).

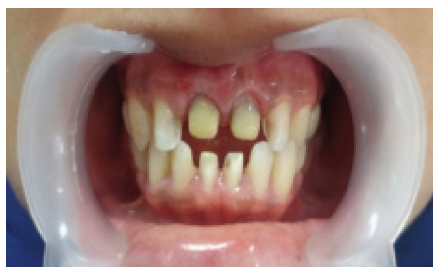


Figure 10 : Crown and Veneer Preparation

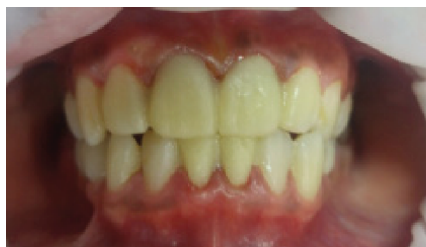

Figure 11 : Provisious Crown

On the sixth meeting, veneer and crown work result were evaluated on die model, while temporary crown was removed and remain temporary cement was cleaned up.

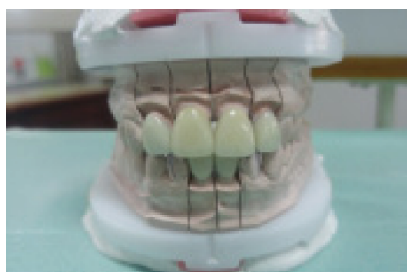

Figure 12 : Crown dan veneer e-max on work models

Veneer and Crown was inserted using Variolink veneer (Ivoclar, USA). Before inserted, Trial insertion was done to match the correct cement shade for insertion, no difference between bite mark and die model, patient comfort, and no over filling restoration. After insertion was done, the remain trial cement was cleaned up.

Crown and veneer was applied to porcelain etch (Ultradent, USA) for 90 seconds, and rinsed and dried using water, then applied to silane evenly (Ultradent, USA). The prepared teeth was also etched using phosphoric acid 37%, then rinsed and dried , and applied to bonding agent. Correct shade of self adhesive resin cement was applied to crown and veneer, then cured using light cure for 20 seconds. Control appointment was made in the next visit to evaluate restoration adaptation to oral cavity (Figure 13, 14, and 15).

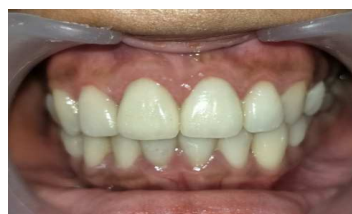
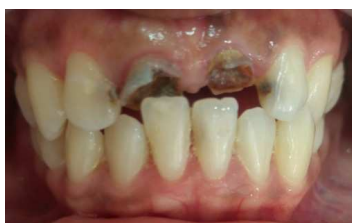
Figure 13 : Labial Side

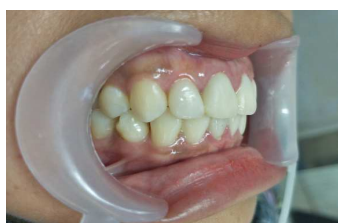
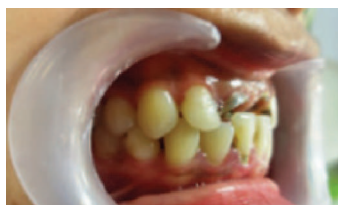
Figure 14 :Right Side

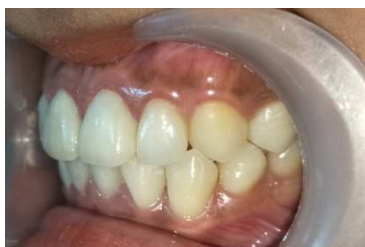
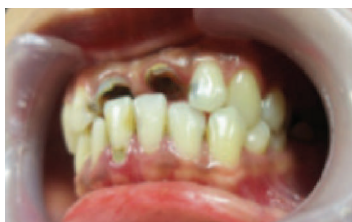
Figure 15 : Left Side

DISCUSSION

Caries on tooth can increase the damage both of tooth hard tissue and supporting tissue.¹⁰ Severe and wide caries can increase the risk of tooth fracture both from contact and force pressure. Caries with trauma in tooth which involved pulp both direct or indirect, need endodontic treatment.¹⁰

In this case, teeth 41 and 31 is experienced supraposition, which caused by teeth 11 and 21 fracture with no immediate treatment, resulting teeth 41 and 31 moved vertically transcend the occlusal plane to find contact relation with antagonist teeth. Teeth 41 and 31 have eruption force, therefore teeth will stop erupting if there are resistance from antagonist teeth.¹¹ Supraposition teeth will damage teeth position and make patient self-less confidence, therefore need to be treated.¹¹

The treatment depends on severity scale of the supraposition. If the tooth is supraposition as high as 1-2 mm, then the treatment would be coronaplasty or enameloplasty.⁸ If enameloplasty insufficient to treat the supraposition tooth, then crown vital can be an alternative choice. Crown vital making is limited to prepared tooth structure, if preparation involved pulp, the intentional root canal treatment or alternative choice of orthodontic treatment can be done.⁸

After the patient was analyzed, the intentional root canal chosen as a possible

treatment, because the patient refused orthodontic treatment with time reason. One of the indication of intentional (elective) root canal treatment is supraposition tooth, which needs as a part of restorative procedure.¹¹ The procedure of intentional (elective) root canal is similar to root canal treatment in general, but only need one visit.¹¹ The ability of the operator to located orifice is to be considered while doing access opening on intentional (elective) root canal treatment.¹¹

Root canal treatment for this is done in one visit (one visit endodontic) because patient was busy with his work and asking for prompt treatment with minimal visit . The advantages of one-visit endodontic are reducing the number of patient visits to the dentist, reducing the risk of re-infection between visits, and also minimizing the occurrence of flare-up.¹²

This treatment is indicated for patients requiring full mouth rehabilitation, intentional (elective) root canal treatment, post traumatic tooth with open apex. However, it is contraindicated in patients with a history of allergies, anatomic abnormalities, and patients with mouth opening limitation.¹³

Endodontically treated teeth will become more brittle, due to moisture loss, the amount of remaining healthy hard tissue, unformed secondary dentine and functional pressure during preparation. Therefore, they will be more prone to fracture.¹⁴

Considerations for preserving the tooth emphasized on remaining teeth, position of tooth, dental functions, and aesthetics.¹⁴ Good condition of periodontal tissue is necessary to determine the restoration type. Therefore, based on that concept, it is important to plan a post-endodontic treatment restoration that can increase the tooth resistance to fracture.¹⁴ Post-endodontic restoration of the anterior teeth often requires extra support to cervical area because it is the most vulnerable area of fracture.¹⁵

Post is defined as a rigid material and inserted into the root canal that connecting the roots in non-vital teeth to support the restoration of the coronal section.¹⁶ The application of post should consider the proportion between the length of the root canal and the length of the core to prevent the occurrence of restoration failure due to post fracture.¹⁵

The condition of periodontal tissue should also be carefully evaluated, the alveolar bone supporting the restoration should be at least two-thirds the length of the tooth root. Other factors to consider are retention and resistance.¹⁷ Retention may indicate post resistance to vertical tensile strength, while factors affecting resistance are the post length and strength, and remaining tooth tissue.¹⁷ Posts can be composed of both metallic and non-metallic elements.¹⁷ Based on the way they manufactured, posts can be distinguished into two types, prefabricated and fabricated.¹⁷

In this case, prefabricated glass fiber post was used, due to its biocompatible, aesthetic aspect, and its dentine-like elastic modulus property. The pressure transmitted from post to the dentine is lowered, minimizing the possibility of root fracture.¹⁸ All-porcelain restoration (e-max) has many advantages including good aesthetic, high functional resistance, biocompatible and good marginal seal, and no shrinkage.¹⁹

All-porcelain restoration is indicated for aesthetic need, full crown covering, large dental caries that require great strength and retention, correcting malposition of teeth, fractured teeth, and dental implants.¹⁹ The contraindications including patients with active caries, untreated periodontal disease, large pulp chamber, large occlusion contact area, patients with bruxism and clenching habits.¹⁹

In this case, the patient complained about fractured tooth and also caries. The caries was located on the proximal (Class III Black Classification) with slight labioversion. The patient requested for the treatment of the fractured tooth and caries to be conducted in a parallel way, therefore the restoration was done using composite for the proximal area. Composite as a restorative material has excellent aesthetic aspect and shades that match to natural teeth.²⁰ For the better aesthetic result, veneers either direct or indirect, can be an option. Based on patient's choice, indirect veneers using all-porcelain material were applied on teeth 12 and 21. Indirect veneers

were able to enhance the crown adaptation and achieve optimal aesthetic. Porcelain indirect veneer has several advantages due to good aesthetics, stable color, good resistance to abrasion, as well as minimally invasive preparation.²¹

A number of studies explain that the indirect veneer can last for 5 years (92%), and even up to 10 years (64%) .²²

CONCLUSION

Treatment of decayed teeth and fractures in the maxillary anterior region was done with the condition of supraposition teeth on the lower anterior central incisors. Simultaneous treatment can reduce the number of patient visits and also help the operator provide optimal and best care to the patient. Successful endo-restoration can be achieved if the treatment plan is conducted properly and also with good cooperation between the operator and the patient.

REFERENCES

1. Pratiwi, Niniek Lely. *The Trend Analysis of the Availability of Dental and Dental Health Personnel in Indonesia*. Dentistry. 2016; 6:30.
2. Maulana, dkk. *Faktor yang Mempengaruhi Kehilangan Gigi Pada Usia 35-44 Tahun di Kecamatan Juai, Kabupaten Balangan Tahun 2014 (Tinjauan dan Sosial Ekonomi*. Dentino (Jur.Ked.Gigi), Vol I. No I. Maret 2016 : 98-103.

3. Shing, Diong Charng. *Prevalensi Fraktur Gigi Premolar Berdasarkan Umur dan Jenis Kelamin yang Dicabut di Departemen Bedah Mulut dan Maksilofacial RSGMP USU Tahun 2010-2012*. Skripsi. 2014. FKG Universitas Sumatra Utara.
4. Siqueira, et al. *Predisposing Factors for Traumatic Dental Injury in Primary Teeth and Seeking of Post-trauma Care*. Brazil Dent J. 2013, 24(6) : 647-54.
5. Andreasen ,et al. *Traumatic Dental Injuries:a Manual, 3rd edition*. 2011. Chichester, West Sussex: Wiley-Blackwell.
6. Sardana, et al. *Delayed Replantation of Avulsed Tooth with 15-hours extra-oral time : 3 year follow-up*. Singapore Dent J. 2014; 35: 71-6
7. Zaleckiene, et al. *Traumatic Dental Injuries : Etiology, Prevalence and Possible Outcomes*. Stomatologica, Baltic Dental and Maxillofacial Journal. 2014; Vol 16. No.1 : 7-14.
8. Marhookar, et al. *Management of Supra-erupted Posterior Teeth-A Review*. International Journal of Dental Clinics. 2010; 2(3) : 27-30
9. Grossman LI, Oliet S, Del Rio CE. *Ilmu Endodontik Dalam Praktek*. 14th Ed. Jakarta : Penerbit Buku Kedokteran EGC. 2014; hal : 196-380.
10. Torabinejad M, Fouad A, Walton, RE. *Prinsip dan Praktek Ilmu Endodontia*. 5th ed. 2014. Jakarta : Penerbit Buku Kedokteran EGC
11. Ahmed, Hany Mohamed Aly. *Elective Root Canal Treatment : A Review and Clinical Updates*. ENDO (Lond Engl). 2014; 8 (2) :139-44.
12. Chan, D. *Single-visit Endodontic Treatment in the Management of Pulpal Disease*. J Dent Res Rev. 2016; 3:2.
13. Ahmed, F et al. *Single Visit Endodontic Therapy : A review*. Austin J Dent. 2016; 3(2):1-4.
14. Dhamayanti I dan Nugraheni T. *Restorasi Fiber Reinforced Composite pada Gigi Premolar Pertama Kanan Mandibula Pasca Perawatan Saluran Akar*. Maj Ked Gi. 2013; 20(1) : 65-70.
15. Awaru, BT dan Nugroho, JJ. *Restorasi pada Gigi Anterior Setelah Perawatan Endodontik*. Dentofasial. 2012; Vol 11 , No. 3: 189-91.
16. Ariani, R dan Hadriyanto, W. *Perawatan Satu Kunjungan Restorasi Pasak Fiber Reinforced Composite Pada Gigi Insisivus Atas*. Maj Ked Gi. 2013; 20 (1) : 45-51.
17. Wijayanti, N. *Pasak Fiber Reinforced Composite sebagai Penguat Restorasi Resin Komposit Kelas IV Pada Gigi Insisivus Lateralis Kanan Maksila Nekrosis Pulpa disertai Lesi Periapikal (Laporan Kasus)*. IDJ . 2014; Vol 3 No 1 :64-70.
18. Mona, D dan Sukartini, E. *Restorasi Pasak Fiber dan Porcelain Fused*

- to Metal Pada Fraktur Gigi Insisif Rahang Atas Pasca Perawatan Endodontik*. Andalas Dental Journal. 2013; Hal : 71-77.
19. Anusavice K, *et al.* *Philips's Science of Dental Materials*, 12th Ed. 2012. Saunders, Elsevier Science, St Louis.
 20. Ratri, M. *Perbandingan Kekuatan Tarik Resin Komposit Nanofill pada Kavitas Kelas V dengan Bahan Adhesif Self-Etch dan Total-Etch*. Jurnal Ilmiah FKG UMS. 2015; Hal 1-10.
 21. Re, D *et al.* *Esthetic Rehabilitation of Anterior Teeth with Laminates Composites Veneers*. Hindawi Publishing Corporation. Case Reports in Dentistry. 2014; P :1-10
 22. Peumans M, De-Munck J, Fieuws S, Lambrechts P, Van Meerbeek B. *A Prospective Ten-year Clinical Trial of Porcelain Veneers*. The Journal of Adhesive Dentistry. 2004; 6(1) : 65-76.

CASE REPORT

CROWN LENGTHENING AND ALL PORCELAIN JACKET CROWNS WITH THE PREFABRICATED FIBER POST REINFORCEMENT ON THE 12TH TOOTH OF THE CLASS IV ELLIS FRACTURE.

Istikhomah Darmawati* ; Yulita Kristanti**

* Conservative Dentistry Resident, Faculty of Dentistry, Gadjah Mada University

** Staff of Conservative Dentistry Departement Faculty of Dentistry, Gadjah Mada University

ABSTRACT

Background : A subgingival crown fracture with pulp involvement required crown lengthening treatment. Ferulle effect was essential to create a monoblock restoration. **Purpose** : This case report was to show that crown lengthening and all porcelain crown could be a treatment of choice to restore tooth with subgingival Clas IV Ellis fracture to build a functional aesthetic restoration. Case report : A 23 years old female patient came to RSGM Prof Soedomo wanted her fractured tooth to be treated. Clinical examination showed on the buccal side of 12 only 3mm tooth remained supragingivally. On the palatal side the margin of the fractured tooth was located below gingival margin. Percussion and palpation showed negative respons with positive vitality test. This tooth was diagnosed for Class IV Ellis fracture with pulpitis irreversible. **Case Management** : Crown lengthening with gingivectomy and bone reduction was done in the palatal side, followed by one visit root canal treatment using Crown Down tehnikue. There was no complain during one week control. The tooth was restored using prefabricated fiber post and all porcelain crown. **Conclusion** : Crown lengthening and all porcelain crown with prefabricated fiber post could effectively restore upper Incisor with Clas IV Ellis fracture.

Keyword : crown lengthening, all porcelain crown, fiber post, class IV Ellis fracture, one visit root canal treatment

Preliminary

A simple (excluding the pulp) and complex (involving the pulp) crown fracture is the most common dental trauma in the permanent tooth. In general, the trauma of the maxillary tooth has a higher percentage because the maxillary tooth is more prominent than the mandibular tooth. Restoration of the fractured tooth includes

a composite resin or a jacket crown for the simple fracture with a healthy pulp, but if there is a pulp involvement, the tooth should be treated with root canals and the restoration of the jacket crown with or without post and core reinforcement. In the fractured tooth with involvement of the sub-gingival area, it can involve the procedure of the crown lengthening

or an intentional extrusion (orthodontic extrusion). Ferrule effect is very important to create the concept of monoblock restoration. If it is not achieved, a remaining option is tooth extraction followed by prosthetic rehabilitation. If the ferrule effect can not be met, the biological width can be disturbed and it causes gingival inflammation and alveolar bone damage and it has risks of the restoration leakage. Biological width required is 2.04 mm. If the distance between the edge of the restoration and the edge of the bone is less than 2 mm, then the crown lengthening is required. The distance limit of the restoration with the bone edge should not be less than 3 mm.

Tooth that has been done PSA will experience some changes; that is, the loss of many tooth structures, changes in physical characteristics, and changes in terms of aesthetic cases. Therefore, the dentist should plan the restoration that will be used. The restoration requires a design that can protect the residual of the tooth tissue toward the fracture, prevent reinfection through the root canal, and replace the missing tooth structures. One of the restorations on the tooth that has been done by PSA is required a retention in the form of the post to unite with the core, as a final restoration support. The post is also indicated in the case that there is a minimum coronal hard tissue residual which is impossible for core production. In the early 1990s, the fiber post was introduced. The post has some advantages compared to the metal post, one of the elastic modulus

is similar to dentin. It can reduce the risk of the tooth fracture. The use of an adhesive cementation material allows the formation of a monoblock bond between the post and the root canal wall. The restoration of all porcelain full crowns is one of the optimal care options for restoring anterior tooth fracture cases. The reason for using this type of restoration is to obtain the high mechanical strength with good aesthetic qualities. The aim of the case report is to notify the treatment of the subgingival fracture of the maxillary anterior teeth with a conservative approach on the residual of the healthy hard tooth tissue. In this case, the patient's agreement to be taken here data as the material of the case report has been got.

Method

On April 24th, 2017, a 27-year-old female patient came to the RSGM Prof. Soedomo FKG UGM Dental Conservation Clinic. She complained that her front tooth was broken because of a traffic accident 2 months ago. The accident caused a problem in the mandibular tooth and then a fixation was performed to the maxillary tooth by the Oral Surgery Section of RSGM Prof. Soedomo FKG UGM. The fixation to the maxillary tooth was removed a week ago, but the mandibular tooth had not been removed yet. The patient did not want the tooth to be removed.

In a clinical examination, it was found that there were 3/4 fracture of the 12th dental crown and 1/4 fracture of the 11th dental

crown (Figure. 1A). Non-vital tooth with pulp space opened (vertical percussion: -, horizontal percussion: -, luxation: -). The end of the palatal surface fracture was located at sub-gingiva.

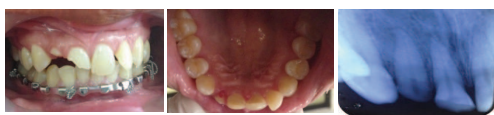

Figure 1. Fracture on the 12th tooth, facial directions (a), it seems sub gingiva fracture on the tooth palatal (b), a radiographic feature (c)

Preoperative radiograph examination showed the tooth of 11 fractures. Until reaching the pulp space, the fracture line in the root area was invisible. It seemed thickening on the periodontal ligament tissue and 21 dental fractures (Figure. 1B).

Based on the subjective, the clinical and diagnosis radiographic examination of the teeth with 11 Ellis fractures in class IV and 21 Ellis fractures in class II, with the following treatment plan, gingivectomy and octovotomy (crown lengthening) of the palatal region were performed and followed by root canal treatment. The treatment was completed with the restoration of all porcelain full crowns (E-maxx) with the fiber post prefabricated and Dental Health Education (DHE). After considering subjective, objective and supportive examination, the prognosis of this case is good.

At the first visit, the subjective and objective examination, taking the clinical

and radiographic photos, determining the diagnosis, treatment plan, and signing the informed consent were performed. The first treatment was the procedure of the crown lengthening on the palatal surfaces of the teeth. Examination of vital signs of the patient was done, including blood pressure (120/75 mmHg), pulse (90x / min), respiration (15x / min). *Duk* cloth was worn in the work area. It was continued by disinfection in the area of operation and surrounding tissue. Anesthesia was performed by an infiltration technique on the palatal part of the tooth 12 by using *cytoject* with articaine anesthesia materials 1: 100.000. The area that will be incised was characterized by a periodontal pocket marker on the palatal part and it was assisted with *sonde* at the proximal part according to the desired margin height. The gingiva of the palatal part was incised with scalpel # 15, and the proximal part of the tooth with Orban in 1 mm.

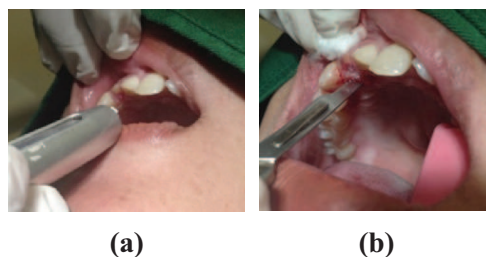


Figure 2. Phase (a). Infiltration anesthesia on the 12th dental palatal; (b). Gingival incision of the palatal part

Flap was made with the bush or the small raspatorium to facilitate the reduction of bone. Bone reduction (osteotomy) used a bone bur in the form of skeleton in 2.5 mm, the bone was mashed

by using the micro bone file, then the debris was cleaned again by using a curette. During bone reduction, irrigation was performed with the sterile saline solution. The gingiva was irrigated with saline and pressed slightly, while periodontal packs were prepared. Application dressing with the periodontal pack (Coe-Pak, GC) was in surgical area.

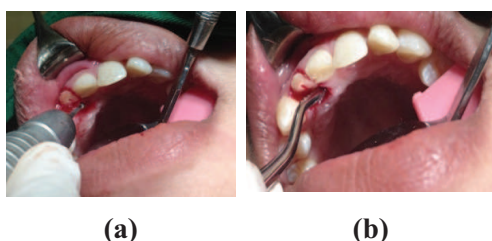


Figure 3. Bone reduction by using a round bone bur (a); refining the bone by using the micro bone file (b)

The patient was given medicines including antibiotics (amoxicillin 500 mg, 15 pcs that's drunk every 8 hours and consumed up to 5 days), analgesic and antiinflammatory (potassium diclofenac 50mg, consumed every 12 hours for the first 3 days and if the patient's ill after the third day). Post-operation instructions were given to the patient. The instructions included the avoidance in brushing the work area, caution at meals, giving cold compresses in case of swelling, controlling 1 week later and doing direct control when dressing off.

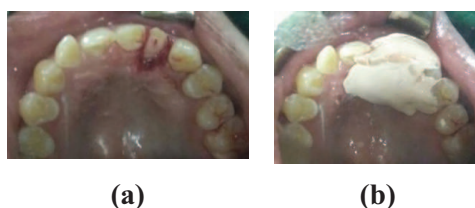


Figure 4. Operation area after finishing the crown lengthening procedure (a); the periodontal pack application on the operating area (b)

One week later, the patient was in control, and there was not ill complaint on the objective examination. On the objective examination: the periodontal pack was still installed well. The taken action was to remove the periodontal pack slowly, then the operating area was irrigated with sterile saline.

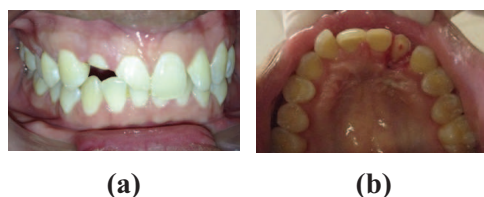

Figure 5. The clinical appearance of the 12th tooth after opening the periodontal pack from the facial directions (a); the clinical appearance of the palatal (b)

The following treatment was for the root canal . The first phase performed the local anesthesia lidocaine with the adrenaline and the tooth was isolated by using the rubber dam. Then the extirpation of the pulp tissue was performed. Root canal irrigation on the 12th tooth used 2.5% NaOCl solution. Furthermore, there are several procedures such as measuring the length of the estimation work. The

estimated tooth length of the preoperative radiograph was 18.5 mm, so it was obtained an estimated working length of 17.5 mm. Root canal preparation by using the crown down technique and protaper hand use (Dentsply) was begun with the coronal root canal preparation using Sx, S1 was followed by S2, for 2/3 coronal dilation.

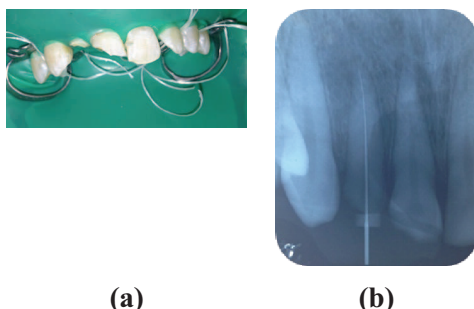
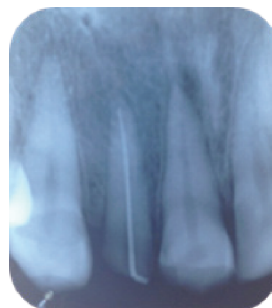

Figure 6. (a) the installation of the rubber dam; (b) the radiograph to measure the length of the work.

Work length measurement was actually done by using the direct observation method. The method also entered K-file #15 in length 17.5 mm, confirmed by Electronic Apex Locator (Morita). This result was then confirmed by using the radiographic image (Figure 2). The preparation was continued on the apical part of the root canal; that is, the file of S1, the file of S2 with 17.5mm working length and finishing by using F1, F2 and ending with K-file no. 25 with a fixed working length of 17.5mm. Every change of the tool, root canal was irrigated with 2.5% NaOCl solution and saline.

The match of the gutta-percha points by asize which was suitable with the last used file of F2. It was marked according

to the working length (17.5 mm) and then confirmed in taking the radiographic photos (Figure 4).



Gambar 7. The match of the gutta-percha points by asize which was suitable with the working length confirmed by the radiograph

The preparation of the root canal obturation: the protaper gutta percha points were sterilized by immersing in a 5.25% NaOCl solution for 1 minute, then those were rinsed with 70% alcohol and dried. The root canal was irrigated with 2.5% NaOCl solution, 17% liquid EDTA, then it was disinfected with 2% chlorhexidine digluconate for 1 min and dried with paper point. The obturation technique with a single cone technique used the resin-based siler. The resin-based (Topseal, Densply) siler was inserted into the root canal by using the lentulo attached with a rubber stop for 2/3 of the working length. The protaper gutta percha points were inserted into the root canal after one-third of the apical part was smeared with the siler, then the gutta percha was cut 2 mm from the orifice direction to the apical direction by using a plugger heated and lightly done the vertical compaction to a solid charge. After that, it was applied the glass ionomer

cement over the orifice (Fuji II, GC) and then filled with the temporary tooth filling (Cavition). The investigation of the results of the root canal fulfillment with taking the radiograph (Figure 8)

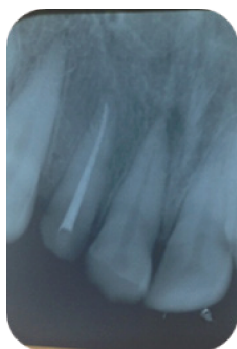

Figure 8. The radiography of the obturation results showed the root canal to be filled hermetically

On the next visit, there were no complaints on the subjective examination. The objective examination showed both vertical and horizontal percussion and the negative palpation. In opening the temporary tooth filling, The first step was the temporary filling to be cleaned up and done the installation of the rubber dam and taking the gutta percha in 12.5 mm length by leaving the gutta percha in the apical of 4,6 mm. Taking the gutta percha used the peeso reamers in the number 1 up to 3, which had previously been marked with a rubber stop. The postal channel preparation was continued with the precision drill of the yellow ribbon (the fiber post in the number 1). This determination was made by tracing the precision drill with the root canal diameter on the preoperative radiograph, and the stipulated post diameter was 1/3 of

the root canal diameter. Furthermore, the root canal was irrigated with the saline and dried with sterile paper points.

Matching the prefabricated (Dentsply) fiber post size in the number 1 and the radiographic examination (Figure. 9c) were performed. Furthermore, the post fiber was cut 2/3 of the clinical crown length and seen the occlusion and the position of the tooth. The post cementation was performed after the post channel was irrigated by the sterile distilled water and dried with sterile paper points. The cementation used the resin cement (Build IT-FR, Pentron). Bonding was applied to the post channel wall by using a microbrush. Then, it was left for 20 seconds and exhaled to the air over the post channel. After that, it was activated for 10 seconds. The silane was smeared on the post and left for 10 seconds. Then, It was indirectly exhaled to the air and allowed to dry. While the resin cement was applied to the wall of the post channel by using the lentulo, the post surface was smeared with a thin layer of the resin cement. Then, the post was inserted into the post channel. After that, it was shined for 20 seconds.

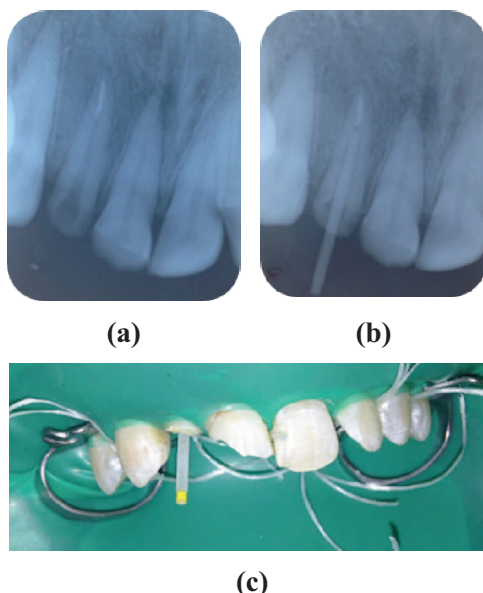


Figure 9. the post channel preparation radiography (a); matching the post radiographically (b); matching the post (c)

Furthermore, Making the core post crown with a composite resin was performed. The etching material with the 35% phosphoric acid was applied to the prepared surface. The surface was sterilized for 15 seconds. Then, it was rinsed with water and dried. The surface of the tooth is thinly smeared with the bonding material in the 5th generation (Stae, SDI) by using a microbrush. Then, it was silenced for 20 seconds and blown the wind gently around the tooth. After that, radiating for 20 seconds was done on the surface of the tooth. The composite resins were applied to the tooth 12 to make the dental crown cores. Furthermore, the reduction of the labial surface and the formation of the nucleus by using a diamond fissure

bur were done. Printing was done by the double impression. Choosing colours for the full crown restoration of all porcelain by using Vita Lumin shade guide was got A2 colour. Then, the colour was sent to the dental engineering laboratory to be made the restoration of all porcelain full crowns. Furthermore, the installation of a temporary crown with the cementation materials of phosphate zinc cement.

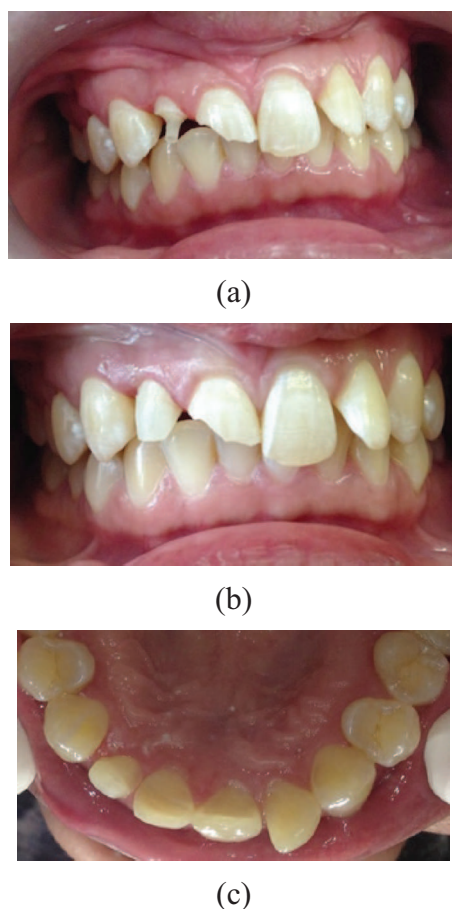
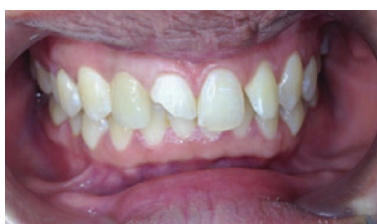
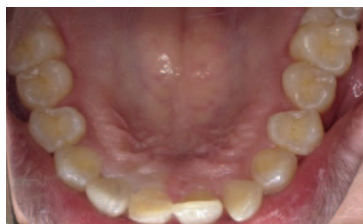
Figure 10. the fiber post cementation (a); the core of the composite resin post from the facial direction (b); the core of the composite resin post from the palatal direction (c)

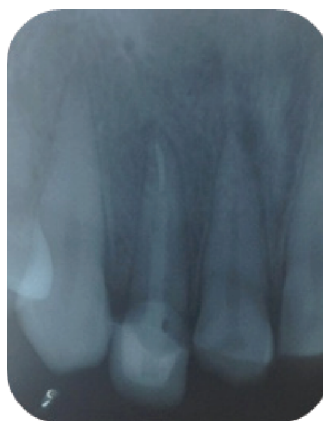On the next visit, the restoration of all porcelain full crowns had been ready to be inserted. The temporary crown was taken by using a crown remover and matching all porcelain full crowns by examining the colour, contour, embrasure, articulation, edge density, occlusion, and proximal contact was performed. The disinfection of the milestone with 2% chlorhexidine digluconate was done for 1 minute and the area around the milestone was dried by the air blast and isolated with the cotton roll. The self adhesive resin cement was applied to the palatal and labial inner wall of the full crown of all porcelain. The crown is then inserted and the pumping motion to prevent the occurrence of air bubbles was performed and held for 10 seconds. The excess cement was cleaned and activated with the light for 20 seconds. The adjustment of the occlusion was performed and the patient was instructed for control one week later. The result of the insertion can be seen in Figure 11.



(a)



(b)



(c)

Figure 11. The insertion of all porcelain jacket full crowns of the 12th tooth from the facial direction (a); The insertion of all porcelain jacket crowns of the 12th tooth from the palatal direction (b); the radiography after inserting all porcelain full crowns (c).

Discussion

In this case, the fracture extends until it involves the pulp. The case of fractures with pulp tissue involvement is a complex fracture that should be paid attention to successful aspects of the root canal treatment before the restorative efforts. In this case, the fracture ending on the palatal surface is located on the sub-gingiva, so it requires the procedure of the crown lengthening. Crown lengthening in this case is done to take the gingiva that covers the hard tissue of the tooth and also reduce the bone on the palatal surface of the tooth to obtain a ferrule effect where the end of the restoration must be located on the hard tissue of the undamaged and healthy tooth with 2 mm in minimum length from

the end of the post core side. Preparation with the formation of preparation ending of the milestone on the hard tissue of the tooth (ferrule preparation) has a higher fracture resistance. In this case, the post is required as an intra-radical retention in order to form a core to replace the damaged or missing dentine. Prefabricated fiber post is preferred in this case because this lateral incisive tooth does not require the restoration of the inclination, the fiber post has a modulus tendency and its elasticity resembles the dentine. The fiber post has good adaptability. It can spread the pressure thoroughly, so it prevents the occurrence of the root fracture, if it is compared to metal or casting post .

The component of the fiber post consists of a reinforcing component and a support matrix. The reinforcing component includes fibers from glass, polyethylene, or carbon, while the support matrix is made of metal, ceramic, or resin matrix. Fiber has a function as a source of strength and matrix has a function as the adhesive of all the fibers into a single unit to distribute the pressure between the fibers from the mechanical damage and the moisture of the oral cavity. The selection of all porcelain jacket crowns as a final restoration in this case is based on the consideration of the high mechanical strength, metal free, and the crown can provide a protection to the dental supporting tissues while it still maintains its aesthetic value.

Controlling one week after treatment shows the successful treatment.

Inconclusion, crown lengthening accompanied by all porcelain jacket crowns and the reinforcement of the prefabricated fiber post is a correct answer to solve the problem of incisors that experienced the class IV Ellis fracture, because it returns four dental functions: (1) mastication function, (2) aesthetic function, 3) speech function, and (4) protective function toward the support network.

References

1. Garg N, Garg.,A. *Textbook of operative dentistry*. New Delhi: Jaypee Brothers Medical Publishers; 2013. H. 264.
2. Saputra, C.S., and Nugraheni, T., 2015, restorasi Mahkota jaket porselin fusi metal dan crown lengthening pada gigi pasca trauma, *MKGK*, (12): 140-146
3. Pary, F. C., and Kristanti, Y., 2015, perawatan gigi insisivus lateralis kanan maksila fraktur Ellis kelas III., *MKGK*, 1(2): 155-162
4. Ingle, Bakland. *Endodontics. 6th ed*. London: Decker; 2013.

EFFECT OF ADDITION OF WHITE SHRIMP SHELL'S NANO CHITOSAN (LITOPENAEUSVANNAMEI) IN CALCIUM HYDROXIDE AGAINST FIBROBLAST CELL CYTOTOXICITY (MTT Test)

¹Dewa Made Wedagama, ²Yusfitra

Faculty of Dentistry, Mahasaraswati University Denpasar

ABSTRACT

The development of new biomaterials by combining organic and inorganic structures will produce various advantages with characteristics in which the sol-gel process (formation of inorganic compounds) will provide an opportunity to produce new materials. Calcium hydroxide has a biocontability (not to contaminate other substances) on tissues either with pH 12, has good antimicrobial properties. Chitosan is a homopolymer of N-acetyl-D-glucosamine residue which is bonded through β -1,4glycosidic bonds, biodegradable, biocompatible, and non-toxic. Terms of material in dentistry, especially what is used in the oral cavity must be biocompatible, not toxic, not irritant, not carcinogenic and does not cause allergic reactions. The cytotoxicity of fibroblast cells is the percentage of cell death based on OD (Optical Density) values using ELISA plate reader in MTT test. MicrocultureTetrazolium Salt Test (MTT) is a method to test the cytotoxic activity of research sample on cell culture, principally that is MTT (3- (4,5-Dimethylthiazol-2-yl) -2,5-diphenyltetrazolium bromide) is reduced to formazan salts by the succinic dehydrogenase enzyme present in living cell mitochondria. The purpose of this study is to determine the cytotoxicity of the addition of white shrimp shell'snano chitosan (L. vannamei) in calcium hydroxide to fibroblast cells. Experimental laboratory was used in this research methodology.10% powdered nano chitosan and nano chitosan + calcium hydroxide were used as samples. Toxicity test using MTT [3- (4,5-dimethylthiazol-2-yl) -2,5-digeniltetrazolium bromide), against fibroblast cells. Formazan density shows the number of living cells. The results showed that the percentage of cell life in nano chitosan powder 10%, nano chitosan + calcium hydroxide was 11499.98, 12899.97. ANOVA test results obtained $p > 0,05$ which means not significant. It can be concluded that the addition of white shrimp shell'snano chitosan (L.vannameii) to calcium hydroxide does not cause toxic.

Keywords: Nano chitosan, calcium hydroxide, cytotoxicity, MTT test

Introduction

The development of science and technology in dentistry is maintained and even quality can be improved to provide dental and oral health services, especially

conservation of teeth. New biomaterials by combining organic and inorganic structures will produce various advantages with unique characteristic and sol-gel process produces new material. Calcium hydroxide,

for pulp capping, pulpotomy, non-vital teeth, sterilization, sealer, biocompatibility, with pH 12 can change the environmental situation to a base. Shrimp contains 25-40% protein, 40-50% CaCO₃, and 15-20% chitin. Chitin (chitosan) are biocompatible, biodegradable and non toxic. Purpose of knowing the effect of toxicity from the addition of white shrimp shell's chitosan (*L. vannamei*) to calcium hydroxide if used as biomaterials in dentistry.

Research methods

The research which was used in this study was laboratory experimental, conducted 08 February 2017 at Central Laboratory of Life Sciences, Brawijaya University of Malang. 10% white shrimp shell's nano chitosan (*L.vannamei*), nano chitosan + calcium hydroxide were used in this study. Each sample is treated in 3 times repetition. 1 treatment were done for 3 days, and fibroblast cells (cells of the ape's kidneys).

Tools and Materials

The tools used in this research were: ESCO incubator, microplate reader, multichannel microphone, Laminar Air Flow (LAF), Pasture Pipe, Shaker Vari Shaker (Dyanatech), Flask bottle 25 cm², Plate well 96, polypropylene tube.

The materials used in this study were MTT (Sigma), saline, dimethyl sulfoxide (DMSO) or sodium dodecyl sulphate (SDS) solvent, white shrimp shell's nano chitosan (*L.vannamei*), Vero cell culture preparations, calcium hydroxide.

Way of Research

Cytotoxicity test by MTT assay method which will be performed with 96-well microplate, each well at 96-well microplate was filled with fibroblast cell suspension with cell density 2x10⁴ cell / 100 µL. Cell culture was incubated for 24 hours. Nano chitosan powder 10% exposure, and nano chitosan + calcium hydroxide were administered on cell culture. Suspense was incubated for 24 hours. Each well was given 10 µL MTT, left for 4 hours, then 100 µL SDS-HCL. In the MTT test, the OD (Optical Density) value was obtained from the calculation of 38 formazan were formed using ELISA plate reader at 550 nm wavelength. Fibroblast culture, TCM medium 1x, FBS 10%, antibiotic Penicillin streptomycin 10%.

Culture Procedure: Cells from the vial were thawed with waterbath at 37°C then were brought into the LAF to be planted in a 25cm² flask bottle until 90% confluent. Medium was replaced every 2 days with complete medium. Treatment Procedures: Cells that have been propagated, transferred into plate well 96 by trypsinization. The cells in the flask bottle were washed 2x with PBS and then added 2ml Trypsin, incubated in a CO₂ incubator for 2 minutes while gently shaken until the cell was separated from the substrate. After the cells were separated, complete medium was added to stop trypsin work. Then the cells are transferred into a 15 ml polypropylene tube for centrifugation at 800 rpm for 4 minutes. Then the supernatant was

removed, the pellet was added with the complete medium and planted in platewell 96 (counted 104 cells per well). After 90% confluent cells, cells were treated. The treatment was incubated for 24 hours in the CO₂ incubator. After 24 hours, MTT procedure is performed.

Data Analysis

ANOVA statistic test was used to determine the effect of addition of white shrimp shell's nano chitosan (L.vannamei) on calcium hydroxide to fibroblast cell cytotoxicity with MTT test. If there is a significant equation then it will be continued with LSD (Least Significant Difference).

Analysis of Research Result

Research on the effect of adding nano chitosan of white shrimp shell (L.vannamei) on calcium hydroxide to cytotoxicity of fibroblast cells was done experimentally by laboratory. The mean value and standard deviation percentage of fibroblast cell life after the addition of white shrimp shell's chitosan (L.vannamei) on calcium hydroxide for 24 hours can be seen in Table 1

Table 1: The average percentage of fibroblast cell life and standard deviation with the addition of white shrimp shell's (L.vannamei) nano chitosan on calcium hydroxide for 24 hours treatment.

Treatment	Repetition			% live cells	SD
	1	2	3		
Medium control	0,038	0,037	0,035		0,001528
Cell control	0,039	0,036	0,035	100	0,002082
NK powder 10%	0,118	0,041	0,064	11499,98	0,039526
NK+KH	0,094	0,084	0,059	12899,97	0,01803

Information:

% = Mean of live cells percentage

SD = Standard deviation

Table 1 shows that the mean percentage of live cells was increasing after the treatment of 10% NK powder and NK + KH samples in which the highest percentage of live cells in the mixing of nano chitosan and calcium hydroxide. The requirement to analyze data using parametric statistical test of ANOVA is data

whose variance is homogeneous and has a normal distribution. Normality tests were conducted to see if the data were normally distributed and homogeneity tests were performed to find out whether the sample data obtained came from a homogeneous population. Normality test results can be seen in table 2.

Tabel 2 Normality test results using
Shapiro-Wilk test

Sample	Statistic	Significant
Medium Control	0,964	0,637
Cell Control	0,923	0,463
NK powder 10%	0,949	0,564
NK+KH	0,942	0,537

From table 2 can be seen the results of normality test using Shapiro-Wilk test ($n < 50$) for all groups show $p > 0.05$

which means normal distributed data. Homogeneity test results of variance of live cells showed a statistical value of $p = 0.070$ ($p > 0.05$) indicating that the sample came from a homogeneous population. Based on the normality and homogeneity test, the research data is qualified for ANOVA test to determine the effect of the addition of white shrimp chitin (*L.vannamei*) nano chitosan on calcium hydroxide to the cytotoxicity of fibroblast cells. The summary of ANOVA test results is listed in table 3.

Table 3: ANOVA test result

	Sum of Squares	Free Degrees	Mean of squares	F	Significance
Between Groups	0,005	3	0,002	3,402	0,074
In Groups	0,004	8	0,000		
Total	0,009	11			

The result of ANOVA in table 3 showed insignificant results ($p > 0,05$) indicated variation of addition of white shrimp nano chitosan (*L.vannamei*) on calcium hydroxide had no effect on fibroblast cell cytotoxicity.

Discussion

The results of the study in Table 2 showed the average percentage of live cells of fibroblasts on the addition of white shrimp nano chitosan (*L.vannamei*) to calcium hydroxide which showed an increase after mixing in nano chitosan, indicating that the nano content of white shrimp shell chitosan (*L.vannamei*) in calcium hydroxide boosts the living cells. In this study, the effect of nano chitosan exposure on white shrimp

shells (*L.vannamei*) on calcium hydroxide to fibroblast cells did not cause toxic effects which there is no disruption of cell enzymatic activity especially mitochondrial dehydrogenase. This is supported by Woolf's 1998 theory which states that a process that almost always cause cell death is enzymatic degradation, and manifests with various nuclear and cytoplasmic changes. Howling et al., 2001 explains that the stimulation of toxic substances can cause injury to cells by destroying cell membranes, mitochondria, and disrupting cellular endogenous enzymes or substrates, and oxidative phosphorylation reactions in mitochondria is one of the most vulnerable systems and this did not

occur in fibroblast cells in this study. Live cells increased after the addition of white shrimp nano chitosan (*L.vannamei*) to calcium hydroxide due to deacetyl degrees affecting chitosan biodegradable and its immunological activity, chitosan also plays a role in cell regeneration and affect against cell proliferation. ANOVA test results (table 5.3) showed that variation of chitosan addition of nano in calcium hydroxide had no effect on the cytotoxicity of fibroblast cells ($p > 0,05$). Based on this, it can be concluded that the results of the study in accordance with the hypothesis that the effect of shrimp's nano chitosan (*L.vannamei*) on calcium hydroxide did not affect the cytotoxicity of fibroblast cells indicated by the increase of live cell percentage. This is also supported by Yuliati research results in 2005 using chitosan with a 0.25% consentation; 0.5%; 0.75%; and 1% in which chitosan is not toxic to the BHK-2110 cell structure. Terms of material in dentistry especially used in the oral cavity must be biocompatible, meaning that it can be accepted by the host, not toxic, not irritant, not carcinogenic and does not cause allergic reactions.

Conclusion

Based on the results of research which has been done in vitro on fibroblast cell culture can be concluded that the addition of white shrimp nano chitosan (*L.vannamei*) on calcium hydroxide using MTT test was not toxic on fibroblast cells which was evidenced by the increase of live cell percentage of fibroblast cells.

Suggestion

1. Further in vitro research is needed on the addition of white shrimp chitin (*L.vannamei*) nano chitosan to calcium hydroxide with a concentration greater than 10% ($10\% <$).
2. Need further research on the cytotoxicity of NK + KH using experimental animals in vivo with the addition of larger concentrations.
3. Need to do further research by using more samples.

Reference

1. Silalahi P F S. 2014. *Efek penambahan kitosan molekul tinggi nano partikel pada abusekam padi nano partikel terhadap viabilitas sel pulpa (in vitro)*, Tesis. Fakultas Kedokteran Gigi. Universitas Sumatra Utara, Medan.
2. Irawan, B., 2005. Chitosan Dan Aplikasinya Sebagai Biomaterial. *Jurnal Dental Indonesia*, Vol 12, No. 3: 146-151
3. Makmur, A.A., Martino, J.M., Brock, T.D, 2016. Brock Biologi Of Micro organisme. New Jersey: Pearson Prentice
4. Prashanth, K.V.H, dan Tharanatha, R.N. 2007, Chitin/Chitosa: Modification and their unlimited application potential-an overview. *J Trends in Food Siences & Technol*, vol. 3, hlm. 117- 131
5. Sidharta, W. 2000. Penggunaan Kal-sium Hidroksida dibidang Konserasi

- Gigi, *JKGUI Edisi Khusus*; 7; 435-437
6. Emmanuel., Adeyeye, I., Habitat, O, Adubiarro, Awodolla, O.J. 2008, Comparability of chemical composition and fungtional properties of shel and flesh of *Penaeusnotabili*. *Journal of Nutrition*. Vol. 7. No. 6, hlm 741-747
 7. Arif, .R., Ischaidar., Natsir. 2013. Isolasi Kitin Dari Limbah Udang Putih (*Peneausmerguiensis*) Secara Enzimatis. *Seminar Nasional Kimia*, Jurusan Kimia Fakultas MIPA, Universitas Hasanuddin, Makassar
 8. Wiyarsi, A dan Priyambodo, E. 2010, *Pengaruh Konsentrasi Kitosan dari-Cangkang Udang terhadap Efisiensi Penyerapan Logam Berat*, Jurusan Pendidikan Kimia FMIPA Universitas Negeri Yogyakarta, Yogyakarta
 9. Howling, G.I., Dettmar, P.W., Goddard, P.A., Hampson, F.C., Dornish, M., Wood, E.J. 2001. The effect of chitin and chitosan on proliferation of human skin fibroblas and keratinocytes in vitro. 22:2959-66
 10. Yulianti, A. 2005. Viabilitas selffibroblas BHK-21 pada permukaan resin akrilik rapid heat cured. *Majalah kedokteran gigi (Dent. J)*, Vol. 38. No. 2: 68-72
 11. Yunarsih, N.M. 2013, *Efektivitas membrane kitosan dari kulit udang-galah (Macrobanchium rosenbergii) untuk menurunkan fosfat dalam air limbah laundry*. Tesis, Universitas Udayana, Denpasar
 12. Makmur, A.A., Martino, J.M., Brock, T.D, 2016. Brock Biologi Of Microorganisme. New Jersey: Pearson Prentice

CASE REPORT

INTERNAL BLEACHING AND RESTORATION USING PREFABRICATED FIBER POST COMBINED WITH POLYETHYLENE FIBER AND DIRECT COMPOSITE RESIN IN ENDODONTICALLY TREATED TOOTH WITH FLARED CANAL.

Yohannes Dian Indrajati*; Tunjung Nugraheni**

*) Conservative Dentistry Resident, Faculty of Dentistry, Universitas Gadjah Mada;

**) Staff of Conservative Dentistry Departement Faculty of Dentistry, Universitas Gadjah Mada

Correspondence:

Yohannes Dian Indrajati

Residen PPDGS Konservasi Gigi FKG UGM, Jl. Denta No.1 Sekip Utara, Bulak sumur, Sleman, Yogyakarta. Email: yohannesdian@gmail.com

ABSTRACT

Background : Endodontically treated tooth are often prone to decreased fracture resistance due to hard tissue loss that occurred during or prior to endodontic treatment procedure. Common cause of hard tissue loss is due to caries or traumatic injury prior to endodontic treatment but sometimes, hard tissue loss can occur during treatment. This condition leads to the need toward intracanal reinforcement for endodontically treated tooth restoration.

Purpose: This case report was presented to evaluate the usage of prefabricated fiber post combined with polyethylene fiber as intracanal reinforcement on endodontically treated tooth. **Case Report:** 19 years old female patient complained about her upper left central incisor. Her tooth was previously treated with pulpotomy but was failed. Radiograph showed maxillary left central incisor with flare shaped to the root canal coronal one third. No radiolucency found on the periapical tissue. Clinical findings showed widely opened access opening in palatal surface. Negative result found on palpation and percussion test. Slight discoloration also found on the tooth **Case Management:** Root canal was prepared biomechanically using step back technique and obturated using cold compaction technique. The tooth was then bleached intracoronally. Two weeks afterwards, the tooth was restored using composite resin with prefabricated fiber post combined with polyethylene fiber as intracanal reinforcement due to great loss of intracoronary hard tissue. One week evaluation showed that the tooth was in good condition and no symptoms found.

Conclusion: Combination of fiber post and polyethylene fiber can be used as intracanal reinforcement for endodontically treated tooth.

Keywords : endodontically treated tooth, fiber post, root canal post, polyethylene fiber, root canal treatment, flared canal

Introduction

The key to success of endodontic treatment depends on Endodontics Triads: (1) Cleaning and Shaping or Instrumentation; (2) Disinfection of Pulp Chamber and Root Canals; and (3) Three Dimensional Obturation.^{1,2,3,4} Failure in establishing one of those three triads could lead into endodontic treatment failure. Cleaning and shaping is the first step that plays important role in Endodontic Triads. The main aim of cleaning and shaping is to eliminate microbes and their substrates from root canal system including removal of necrotic pulp and tissue debris, inflamed pulp tissue and healthy pulp tissue in intentional endodontic treatment.⁴ Canals that are poorly obturated are often incompletely shaped and thus, cleaned. The outcome from this treatment phase is to establish root canal space that is smooth, free-flowing channel, tapered, clean and provide adequate space for root canal irrigation materials, medicaments and obturating material inside the root canal.^{5,6}

Cleaning and shaping procedure commonly done using rotary instrument in modern endodontics although in several cases, hand instruments provide more beneficiary outcome and more safety better than rotary instruments (i.e.: curved root canals in apical one thirds, large root canal diameter, etc.). Root canal disinfection is achieved by root canal irrigation during cleaning and shaping procedure and dispensing intracanal medicaments between visits. Intracanal

medication commonly used are calcium hydroxide paste, phenolic compounds (e.g. chlorhexidine monochlorophenol), aldehydes (formocresol), corticosteroids, chlorhexidine gels, antibiotics and various combination. The majority of these preparations are not used in contemporary endodontic practice due to the reported toxicities; however, calcium hydroxide and antibiotic-containing preparations remain the most commonly used root canal medicaments.¹

Three dimensional obturation also plays important role in the end of root canal treatment procedure. Overfilled or underfilled root canals often become causative factors why the tooth problems persist in endodontically treated teeth. Obturation must be done just right at the apical constriction (approximately 0.5 to 1mm from the apical foramen).¹ Obturation material used in modern endodontics is guttapercha, although historically silver cones, zinc oxide eugenol, and resin based material were used as obturating material. Various methods have been introduced to obturate root canal using guttapercha, e.g. lateral compaction, vertical compaction, thermoplasticized injection, solvent-softened custom cones, and core-carrier system.^{1,7} Lateral compaction has been chosen as common method for root canal obturation because of its simple instrumentation needed, fit to the most root canal (except for the severely curved one), and easy to manage guttapercha length control.

Endodontically treated teeth are often prone to fracture due to great loss of remaining tooth structure.⁸ This situation leads to the need of intracanal reinforcement in order to maintain tooth integrity and to retain the final restoration during its functional movement. Pre-fabricated fiber post widely used in modern dentistry as intracanal reinforcement due to its esthetically accepted appearance, modulus elasticity that is similar to dentin, and no metallic compound in composition material, thus no corrosion occurred.⁸⁻¹⁰ Fiber posts inserted into root canal and act as 'shock absorber' by distribute the mastication force into periodontium alongside the root, and thus prevent root from fracture. Intracanal retention also can be achieved by using fiber reinforced composite that is inserted inside the root canal.

Tooth discoloration is one of many problems related to pulp necrosis. In non vital tooth, tooth discoloration come from within. Chromogenic materials penetrate into dentine tubuli and thus give darker appearance as the chromogens interact with lights. Chromogens in non vital tooth commonly caused by degraded pulp remnants inside the pulp chamber. Pulp remnants that reside inside the pulp chamber degraded with time. Pulp remnants contain hemoglobin that is degraded into various colored compounds such as hematin, hematoidin, hemin, hematoporphyrin and hemosiderin.¹¹ The tooth is darkened by the presence of hydrogen sulfide produced

by bacteria that incorporated with those colored compounds.⁵

Case Report

A 19-years old female patient complained about her upper left central incisor. Past dental history told that her tooth was previously treated with intracanal treatment in Primary Healthcare Center (Puskesmas) but the treatment was failed three days after. Patient experienced swelling and mild pain and then she went to Puskesmas once again. Previous dentist then opened the root canal access and removed all medicaments within the root canal and pulp chamber. Patient then referred to Department of Conservative Dentistry in RSGM Prof. Soedomo for further proper treatment. Radiograph showed maxillary left central incisor with flared canal to the root canal coronal one third. No radiolucency found on the periapical tissue. Clinical findings showed widely opened access opening in palatal surface. Negative result found on palpation and percussion test. Slight discoloration also found on the tooth.

Case Management

1st Visit

Patient was examined thoroughly and several clinical photographs were taken for case documentation. Periapical radiograph was taken afterwards to make sure that there were no periapical abnormalities, reviewing root canal system and projection of the root, and evaluating whether there

were any external or internal root resorption or not.

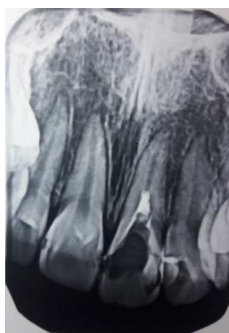

Figure 1. Pre-operative periapical radiograph showed broad access opening at orifice. No radiolucencies found at the periapical and root canal abnormalities as well.

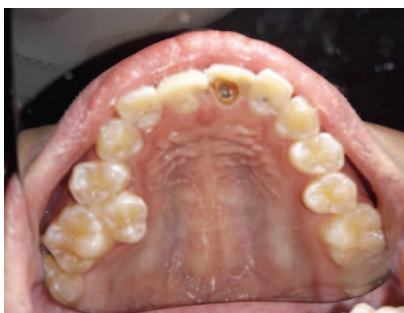

Figure 2. Clinical appearance of the tooth that become chief complain. Broad access opening found at the palatal aspect of the tooth.

Patient was then instructed to fill and sign the informed consent documentation sheet after given complete explanation about treatment planning, risk, treatment cost, and time needed for the treatment. Rubberdam was placed to provide isolation from saliva. Root canal debridement was done using sodium hypochlorite solution 2.5% and physiological saline solution 0.9% for root canal irrigation; and

using hand files #8 and #10 (m-access, DentsplyMaillefer). Working length (WL) determination was established using hand files #15 and electronic apex locator (ApexID, Sybron Endo). WL determined at 24mm when electronic apex locator indicator showed apical constriction at 0.5. WL is then confirmed using periapical radiograph and showed that the tip of the #15 hand file rest at approximately 0.5mm from the apex.

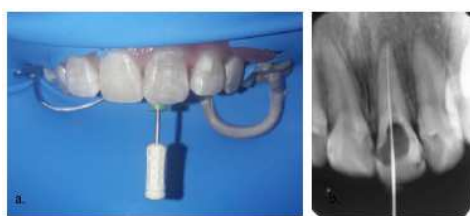

Figure 3. Working length confirmation using radiograph (a). Hand file #15 inserted into root canal at specified length (24mm). (b) Radiograph taken showed the tip of #15 hand file stop at 0.5mm from the apex.

Initial apical file (IAF) was determined at #25 then cleaning and shaping procedure started using hand file #25 at working length 24mm. Cleaning and shaping was done using step back technique and aided by sodium hypochlorite 2.5% and physiological saline solution 0.9% as root canal irrigants. Chelating agent (Glyde File Prep RC, Dentsply) was applied to help softening root canal walls and also aiding the cleansing of root canal system. Master apical file (MAF) determined at hand file #45. Root canal's coronal two thirds were shaped until final instrument

handfile #60 at 21mm. Coronal flaring was done using Hedstroem file #60 at 21mm and then finishing was done using hand file #45 at 21mm with circumferential filing movement. Final rinse was done using copious amount of sodium hypochlorite solution 2.5%; EDTA solution 17%, and chlorhexidine digluconate 2% alternating with physiological saline solution 0.9% before each irrigation. Root canal was then thoroughly dried using paper point and then medicated with calcium hydroxide paste. Cavity was then sealed using temporary restoration and patient instructed to visit dental office again in 2 weeks.

2nd Visit

Patient was asked and examined for any symptoms occurred between visit. No symptoms and complaint found. Percussion and palpation test was negative. Tooth isolation was done using rubber dam. Temporary fillings removed and so intracanal medication as well. Root canal was then rinsed with sodium hypochlorite 2.5% and physiological saline solution 0.9% afterwards. Root canal was then dried using paper point. Master apical cone corresponds to master apical files was inserted into root canal and radiographically checked for its apical adaptation.

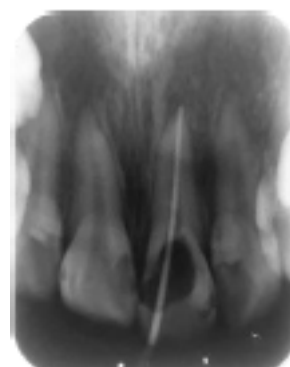


Figure 4. Master apical cone radiograph checking. Radiograph showed good adaptation between master cone and apical constriction.

Obturation was done using lateral compaction method using resin based endodontic sealer (Top Seal, DentsplyMaillefer). Excess gutta-percha was seared off using heated endodontic pluggers and the cervical portion of the gutta-percha is vertically compacted using endodontic plugger until 2mm below the orifice. Orifice is then sealed temporarily using zinc phosphate cement and temporary filling was applied.

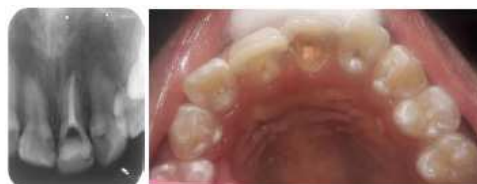

Figure 5. Post Obturation Periapical Radiograph and Clinical Appearance. Radiograph showed hermetic obturation.

3rd Visit

No symptoms were reported between visits, temporary fillings were still intact and negative result found in percussion and palpation test. Patient were planned to undergo non-vital bleaching procedure. Tooth color was evaluated using shade guide and clinical photographs are taken at the beginning of procedure. Temporary fillings were removed along with the temporary seal as well. Gutta-percha was then removed to a level just apical to the gingival margin ($\pm 2\text{mm}$) using Peeso Reamers (Largo, Dentsply). Protective cervical barrier from Cavit temporary filling material was applied at 3mm thick to prevent bleaching agent leakage into periodontal tissue. Periapical radiograph was taken to confirm gutta-percha removal and cervical barrier placement.

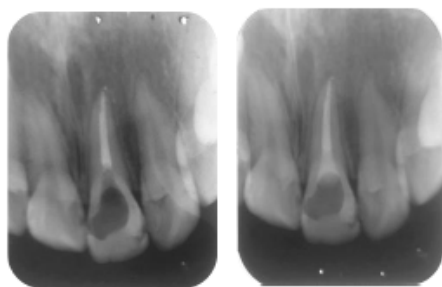


Figure 6. (a.) Removal of gutta-percha 2mm apical to gingival margin. (b.) Application of cervical barrier using hydraulic temporary filling material (Cavit).

Rubber dam was then placed to protect soft tissue from bleaching agent. Thin layer of dentin at the facial part of the pulp chamber was shaved using round bur as it also done to clean pulp horn. Bleaching agent (Opalescence Endo, Ultradent) then applied to the pulp chamber at sufficient amount. Cotton pellet then inserted into pulp chamber and then sealed using double seal. Patient was instructed to check her tooth everyday and report if there was color change.

4th visit

Patient reported that there was a slight color change in her tooth after 7 days of application. Patient then came to the dental office. After regular subjective and objective examination (found no abnormalities) and also clinical photograph taken rubber dam was once again placed to prevent soft tissue irritation by bleaching agent. Double seal was removed and the bleaching agent as well. Pulp chamber was then rinsed with sterile water and dried using cotton pellet. Pulp chamber then filled with calcium hydroxide paste as dressing and sealed with temporary filling. Patient then instructed to come 2 weeks after.

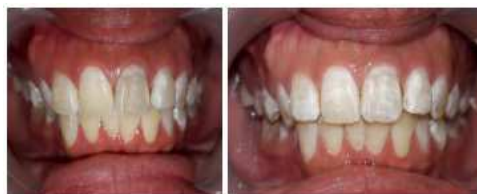

Figure 7. Tooth Shade Difference Before and After Application Internal Tooth Bleaching

5th Visit

Patient reported no sign of pain and discomfort experienced between visits. Palpation and percussion test showed negative result. Patient was planned to undergo post endodontic restoration. Temporary filling then removed and so did with the cervical barrier as well. Slot was created by removing gutta-percha. Gutta-percha was initially removed using heated instrument to make insertion path for reamer rotary instrument. Gutta-percha then removed two thirds from the length of the root canal, using reamers gradually until reamers that has diameter fitted to the root canal diameter (traced upon periapical radiograph). Pre-fabricated fiber post then tried to the root canal and then radiographically checked. Root canal then prepared and rinsed using EDTA solution 17% and chlorhexidine digluconate solution 2% with physiological saline solution 0.9% as intermediary solution in between. Root canal is then dried using paper point.

Due to larger diameter in coronal portion of the root canal, using single piece of fiber post was insufficient to fill in root canal space. Braided polyethylene fiber reinforcement ribbon (Construct, Kerr) was then added to fill in the spaces between prefabricated fiber post and dentin. Resin cement (Relyx U200, 3M ESPE) was applied to the root canal using paste carrier (Lentulo, Dentsply Maillefer). Prepared polyethylene fiber was then spanned in facial-palatal direction with the middle part

of the fiber positioned upon tooth orifice. Prepared fiber was then inserted slowly into the root canal to prevent air bubble trapped inside the root canal until reached its specified length. Excess of polyethylene fiber was then packed into the orifice and was then light cured.

Periapical radiograph was taken to evaluate the fiber post and polyethylene fiber adaptation inside the root canal. Fiber post was then cut to the one thirds from the incisal, leaving two thirds part inside the clinical crown of the tooth. The tooth was then restored using low shrinkage stress flowable composite resin (SDR, Dentsply) combined with packable restorative composite resin (Z 350 XT, 3M ESPE).

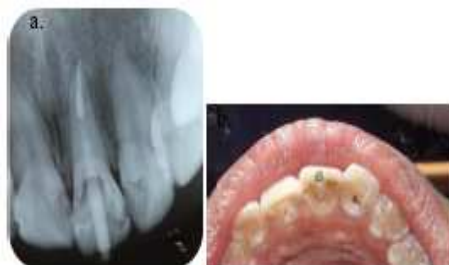

Figure 8. (a.) Periapical radiograph showed good adaptation between post systems and root canal. Packed excess polyethylene fiber is shown at the orifice. (b.) Clinical photograph from occlusal aspect. Orifice was filled with packed polyethylene fiber.

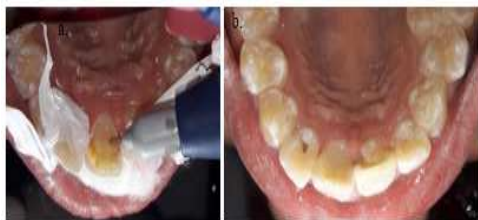


Figure 9. (a) Application of SDR as a dentin replacement; (b) Post operative clinical photograph.

6th Visit

Patient was recalled 6 months post treatment for evaluation. No symptoms were reported. Percussion and palpation test were all negative. Periapical radiograph was also taken to check the periapical and periodontal tissues. The result showed that there was no abnormalities.

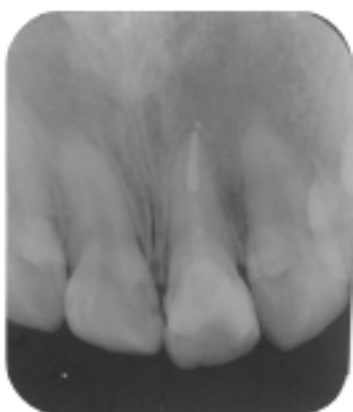


Figure 10. Three Months Recall Periapical Radiograph

Discussion

Restoration of the endodontically treated tooth sometimes bring the dentists to the situation that he/she should overcome using combination of two or more restorative material and/or

intraradicular reinforcement. Loss of the tooth structure during endodontic treatment can significantly decrease tooth ability to withstand mastication force.^{8,9} Intracanal reinforcement is mandatory if there was any loss of the tooth structure. The most common intracanal reinforcement used in restoration of endodontically treated teeth is pre-fabricated fiber post. Fiber post is more preferred than metal post due to its excellent properties. Fiber post has modulus of elasticity similar to dentin, make it more safely to use in order to prevent tooth cracking when mastication force applied.¹² In contrast, metal post has more rigid structure compared to dentin, thus when force applied to the tooth, it tends to crack tooth structure.^{12,13}

When restoring anterior teeth, dentist should consider aesthetic aspect because it could affect patient appearance and thus affecting patient's self-confident. Fiber post is also aesthetically acceptable due to its transparency compared to metal posts so that more preferred as intraradicular retention.⁹ Although has several superior properties, the disadvantage using pre-fabricated fiber post is it could not fit in all root canal diameters since they have specified sizes and tapers. In root canal that has large diameters, or in flared canals, sometimes one fiber post is not sufficient to act as intraradicular retention. In this case, several suggestions could be considered, e.g. using fiber reinforced custom dowel core instead of pre-fabricated, using auxiliary pre-fabricated fiber posts

alongside the main post to fill in root canal space, or by applying chemically activated resin cement to fill in spaces between post and dentin. polyethylene fiber band into the space between post and dentin.^{9,13,14}

Combination of fiber post and polyethylene fiber band has been reported by Barutcigil et al. (2009). They used fiber post as intraradicular retention and polyethylene fiber as supporting structure in prosthetic crown direct composite restoration.¹³In this case report, polyethylene fiber band was used combined with main fiber post as intracanal retention because the author wanted to combine the superiority of these two materials to fill in root canal space.

Discoloration is commonly found in non-vital tooth. This condition appears as a result from the breakdown of the pulp tissue. Necrotic pulp tissue decomposed through time giving tooth darker appearance. This due to hemoglobin in the pulp tissue breaks down into globin and heme protein. The later contains iron atom that would react with hydrogen sulfide to form iron sulfide that has dark appearance.⁵Dealing with such condition, non-vital bleaching is the treatment of choice to overcome the problems. Commonly used bleaching agent in contemporary endodontics is 35% hydrogen peroxide. Dispensed in ready-to-use syringe to accommodate ease of application. The mechanism behind the bleaching process is free radicals formation which are then undergo oxidizing reaction with the discoloring agent. Free radicals

are highly unstable compound because of unpaired electrons activity, so that they would interact with organic compound to attain stability. Pigmented carbon chains react with free radicals then break down double bond and aromatic rings and replace it with hydroxyl group. Change in compound structure also change its properties in absorbing light.^{5,16} Hence the tooth appears lighter in color.

Cervical barrier is mandatory when performing internal bleaching protocol. It prevents bleaching material leaking into cervical part of the tooth and penetrate into periodontium that could lead external resorption. Materials could be used as cervical barrier are hydraulic filling materials (Cavit), composite resins, photo-activated temporary resin materials, zinc oxide eugenol cement, and zinc phosphate cement have been suggested as an interim sealing agent during bleaching techniques.¹⁵ Several publications suggested that cavite was good material to be used as cervical barrier.

Restoration using composite resin in bleached tooth may result in microleakage due to bonding system failure.¹⁷ Free radicals that reside inside the dentin tubules may interfere polymerization process of the resin. Several studies suggested that delaying restoration until 2 weeks or more is ideal time for internally bleached tooth, although study conducted by Sundfeld et al. (2004) showed one week delay was sufficient to restore bonding strength.^{18,19} Calcium hydroxide applied as dressing

after bleaching procedure finished to act as buffer acid pH that can occur on cervical root surfaces after intracoronary application of bleaching agents. Calcium hydroxide suspension does not affect with the adhesion of composite materials used for final restoration of the access cavity.¹¹

Conclusion

With limitation to the case report, it was concluded that combination of pre-fabricated fiber post and polyethylene fiber could be used as an alternative way to achieve intracanal retention in endodontically treated tooth that has flared root canal.

References

1. Torabinejad, M. dan Walton, R.E., 2009, *Endodontics: Principles and Practice 4th Edition*, Saunders Elsevier, St. Louis-Missouri, p.259
2. Musani, I., Goyal, V., Singh, A., dan Bhat, C., 2009, Evaluation and comparison of two endfiles and irrigants as judged by microbial quantification in primary teeth-an in vivo study, *International Journal of Clinical Pediatric Dentistry*, 2, (3), p15-22.
3. Chugal, N., dan Lin, L.M., 2017, *Endodontic Prognosis: Clinical Guide, for Optimal Treatment Outcome*, Springer International Publishing, Switzerland, p.141-142
4. Chong, B.S., 2010, *Harty's Endodontics in Clinical Practice 6th Edition*, Churchill Livingstone-Elsevier, London, p.97
5. Hargreaves, K.M. and Berman, L.H., 2016, *Cohen's Pathway of The Pulp 11th Edition*, Elsevier, St. Louis-Missouri, p.209-210
6. Ingle, J.I., Bakland, L.K., and Baumgartner, J.C., 2008, *Ingle's Endodontics 6th Edition*, BC Decker Incorporated, Hamilton, p.877
7. Chandra, B.S., dan Khrisna, V.G., 2010, *Grossman's Endodontic Practice 12th Edition*, Wolters-Kluwer, New Delhi, p. 279-300
8. Dikbas, I., dan Tanal, P., 2013, An overview of clinical studies on fiber post systems, *The Scientific World Journal*, p1-7
9. Li, Q, Xu, B, Wang, Y, and Cai, Y., 2011, Effects of auxiliary fiber posts on endodontically treated teeth with flared canals, *Operative Dentistry*, vol. 36, (4), p. 380-9.
10. Hegde, J., Ramakhrisna, Bashetty, K., Sirekha, Lekha, and Champa, 2012, An in vitro evaluation of fracture strength of endodontically treated teeth with simulated flared root canals restored with different post and core systems, *J Conserv Dent*, 15, p. 223-7
11. Zimmerli, B., Jeger, F., and Lusi, A., 2010, Bleaching of non-vital teeth, *Schweiz Monatsschr Zahnmed*, vol 120, (4), p.306-13.
12. Plotino, G., Grande, N.M., Bedini, R., Pameijer, C.H., and Somma, F., 2007,

- Flexural properties of endodontic posts and human root dentin, *Dental Materials*, 23, p.1129-35.
13. Barutçigil, C., Harorli, O.T., and Yildiz, M., 2009, Restoration of crown fractures with a fiber post, polyethylene fiber and composite resin: a combined restorative technique with two case reports, *Rev ClinPesqOdontol*, vol. 5, 1, p.73-7
 14. Arora, V., Nikhil, V., Suri, N.K., and Arora P., 2013, Reinforcement of Flared root canals with fiberpost and auxillaryprepolymerisednanohybrid composite posts: a clinical report, *IJRSET*, vol. 2,(12), p.7210-3
 15. Plotino, G., Buono, L., Grande, N.M., Pameijer, C.H., and Somma, F., 2008, Nonvital Tooth Bleaching: A Review of the Literature and Clinical Procedures, *J. Endod*, vol. 34, p.394-407.
 16. Alqahtani, M.Q., 2014, Tooth Bleaching Procedures and Their Controversial Effects: a Literature Review, *The Saudi Dental Journal*, 26: 33-46
 17. Han, Y., Mo, S., Jiang, L., Zhu, Y., 2014, Effects of Antioxidants on the Microleakage of Composite Resin Restorations After External Tooth Bleaching, *European Journal of Dentistry*, 8(2): 147-153
 18. Shinohara, M.S., dkk., 2005, Shear Bond Strength Evaluation of Composite Resin on Enamel and Dentin after Nonvital Bleaching, *J EsthetRestor Dent*, 17, h.22–29
 19. Sundfeld, R.H.,Briso, A.L.F., Marra De Sá, P., Sundfeld, M. and Bedran-Russo, A., 2005, Effect of Time Interval between Bleaching and Bonding on Tag Formation, *Bull Tokyo Dent Coll*, 46 (1–2),h.1–6

CASE REPORT

APICAL SURGERY FOR PERIAPICAL LESION MANAGEMENT CAUSED BY TRAUMATIC INJURY

Ni Luh Putu Sri Widani¹, Firmansyah² dan Wignyo Hadriyanto³

¹Resident of Conservative Dentistry, Faculty of Dentistry,
Gadjah Mada University

²Resident of Oral & Maxillo facial, Faculty of Dentistry, Gadjah Mada University

³Staff of Conservative Dentistry Departement, Faculty of Dentistry,
Gadjah Mada University

Jl. Denta No. 1 Sekip Utara, Yogyakarta, Indonesia; e-mail koresponden: s.widani@yahoo.co.id

ABSTRACT

Background: Traumatic dental injury can caused necrosis to the pulp and develop to periapical lesion. Apical surgery is a surgical procedure on a tooth with an endodontic lesion that cannot be managed with conventional endodontic (re-)treatment. **Objective:** This case report aims to present apical surgery procedure conducted to treat the radicular cyst on tooth 21 and granuloma on tooth 11, and using MTA as a retrograded filling material.

Clinical features: A 22 year old male patient was brought to RSGM Prof. Soedomo FKG UGM clinic for treatment. Tooth 11 shows the presence of the periapical lesion and a root canal treatment has been conducted for the past five months. This tooth 11 went to surgery three years ago without previously being treated with root canal treatment. The tooth 21 has necrosis with radicular cysts. **Management:** As a start, the tooth 21 were treated with root canal treatment. The following procedure is applying apical surgery to enucleate the cyst and apicoektomi procedure by filing an MTA as root end filling material in tooth 21 and conducted apical kuretase to deprive granulated tissues in toth 11. **Treatment result:** Five months post-surgery, periapical lesion on the tooth 11 has been healed, and post cyst enucleation cavity on the tooth 12 has shrunk.

Conclusion: Apical surgery is a chosen treatment for radicular cysts and lesion which cannot heal with conventional endodontic procedure.

Keywords: apicoectomy, apical surgery, MTA, radicular cyst

INTRODUCTION

Apical surgery belongs to the field of endodontic surgery, which also includes incision and drainage, closure of perforations, and root or tooth resections.

The objective of apical surgery is to surgically maintain a tooth that primarily has an endodontic lesion that cannot be resolved by conventional endodontic (re-)treatment¹. This surgery aims to

remove irritants from the root canal system and to eliminate the causes of inflammation in periradicular and surrounding areas². This goal should be achieved by root-end resection, root-end cavity preparation, and a bacteria-tight closure of the root-canal system at the cut root end with a retrograde filling¹. The term "apicoectomy" consists of only one aspect (removal of root apex) of a complex series of surgical procedures³.

According to the updated guidelines by the European Society of Endodontology, indications for apical surgery comprises (1) radiological findings of apical periodontitis and/or symptoms associated with an obstructed canal (the obstruction proved not to be removable, displacement did not seem feasible or the risk of damage was too great), (2) extruded material with clinical or radiological findings of apical periodontitis and/or symptoms continuing over a prolonged period, (3) persisting or emerging disease following root-canal treatment when root canal re-treatment is inappropriate, and (4) perforation of the root or the floor of the pulp chamber and where it is impossible to treat from within the pulp cavity^{1,3}. Modified indications have been published by Wu et al. (2006). Post-treatment disease following root-canal treatment is most often associated with poor quality procedures that do not remove intra-canal infection. This scenario can be corrected via a non-surgical approach. However, infection remaining in the inaccessible apical areas, extraradicular infection including apically extruded

dentin debris with bacteria present in dentinal tubules, true radicular cysts, and foreign body reactions require surgical intervention. Contraindications for apical surgery include the following: the tooth has no function (no antagonist, no strategic importance serving as a pillar for a fixed prosthesis), the tooth cannot be restored, the tooth has inadequate periodontal support, or the tooth has a vertical root fracture. Additional general contra-indications may be an uncooperative patient or a patient with a compromised medical history for an oral surgical intervention¹.

The main goal of apical surgery is to prevent bacterial leakage from the root-canal system into the periradicular tissues by placing a tight retrograde filling following root-end resection. Only a tight and persistent apical obturation will allow periapical healing with good long-term prognosis¹.

CASE

A 22 years old male went to Conservative Dentistry clinic, RSGM Prof. Soedomo Yogyakarta recommended by Oral & Maxillofacial clinic with references to undertake root canal treatment for tooth 21, and treatment control for tooth 11. He report a root canal treatment and restoration for right maxillary incisor five months ago. In 2013 (for about three years ago) a surgery performed for tooth 11 because of the swollen on the gingiva. The surgery was conducted in RSUD Wates with local anastesi. The patient reported an accident

during his junior year and knocked his front teeth and broke two of it. He reports no pain and no swollen gum. He did not has a history of sistemic disease, and no pain reported from those teeth. Tooth 11 examination: percussionand palpationare negative. Tooth 21 examination: percussion, palpation, mobility and vitality test with electric pulp testerare negative.

Radiograph examination (periapical-land OPG) on tooth 11 shows the finished root canal treatment. The rootlength of tooth 11 looks shorter than the tooth 21. In the periapical area of tooth 11, we can see a circular radiolucent area with ± 3 mm diameter with irregular radiopaque area in it. Other than that, there are radiolucent image surrounded by radiopaquearea which expands from lamina dura on periapical tooth 21 and 22. The maxilla and mandibula bone structure was good and no sign of fracture (Figure 1). Tooth 21 diagnosis is pulp necrosisaccompanied by a radicular cyst, and tooth 11 diagnosis is non-vital tooth after root canal treatment with granuloma.

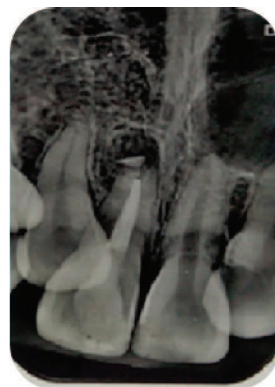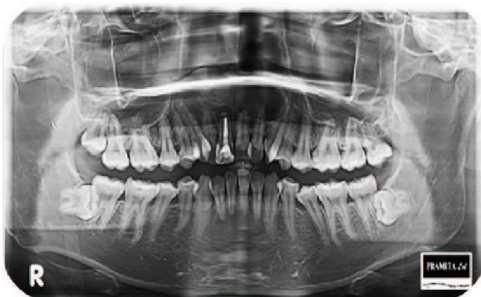


Figure1. Radiograph examination shows radiolucen area on the periapical tooth 11 and 21

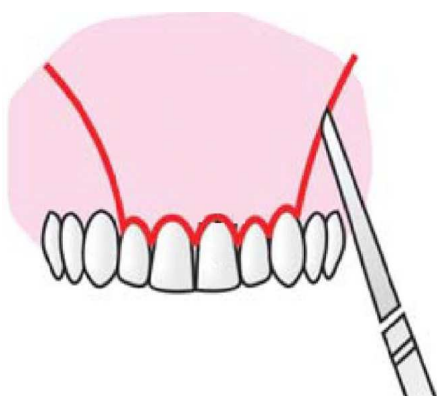After subjective and objective examination, radiographic, diagnosis, treatment plan, and pre-treatment documentation, the patient is given the explanation regarding the examination plan procsedure, the cost and the time of care, and then sign the informed consent.

CASE MANAGEMENT

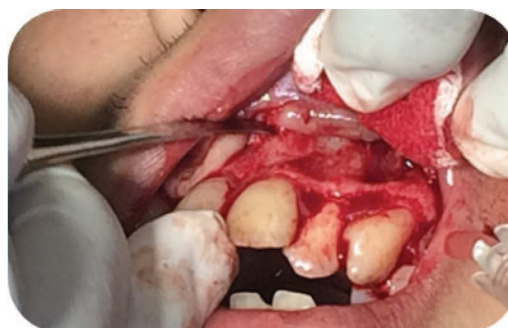Tooth 21 undergo a root canal treatment. Access to cavity was performed using endoaccessbur(Dentsply),and dilated using a non-cutting ended fissure bur (Diamendo, Dentsply). Explorationwasperformedusingsmooth broach (Mani),and debridement using barbed broach (VDW). After debridement, root canal irrigated with NaOCl 2,5% and aquades.Work length measurement wasconducted withperiapical radiographexamination with result 21 mm. The works continued with root canal preparation usingastep backmethodwith K-File (SybronEndo) taper 0.2. After finishing the preparation, the root canal

will be irrigated with 2,5 ml NaOCl 2,5% solution for ± 5 minutes, EDTA 17% solution (Smear Clear, SybronEndo) for 1 minute followed by disinfection with chlorhexidine digluconate 2% (Cavity Cleanser, Bisco) for 30 seconds. Hereafter, root canal was dried using sterile paper point followed with guttapercha obturation in lateral condensation with endometason siler (Septodont). Resin composite restoration on tooth 21 was performed on the second visit.

Apical surgery was performed on the third visit. Before the periapical surgery, the vital sign of patient was measured. The blood pressure was 110 /70 mmHg, respiratory rate: 19x/min, pulse: 70x/min, temperature : afebris (36,5°C). Following adequate local anesthesia and surface disinfection of the surgical site, the trapezoidal mucoperiosteal flap extending from distal of tooth 11 to distal of tooth 21 was elevated (Figure 2).



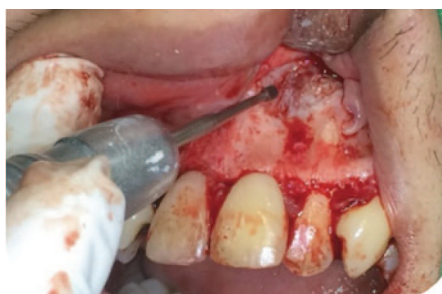(a)



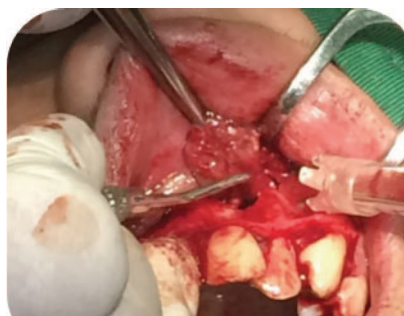
(b)

Figure 2. (a) Design scheme of trapezoidal flap; (b) dissection flap with traspatorium

After flap dissection, the alveolar bone around apical of left central and lateral incisor was removed using round metal bur under saline irrigation. Cystic enucleation was undergone with curette until all the cyst capsule were taken or cleaned (Figure 3).



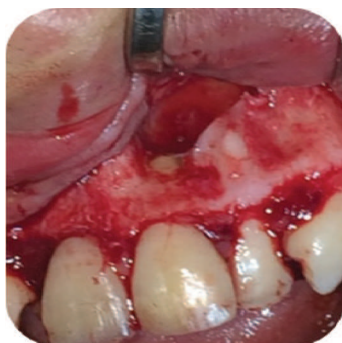(a)



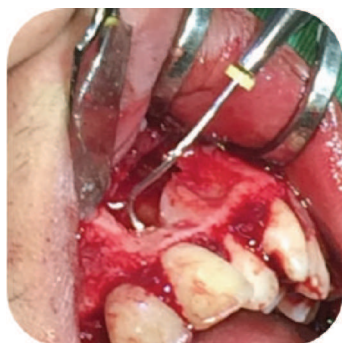(b)

Figure3.(a) The reduction of bone around apeks 21 and 22 using round metal bur;
(b) Cysticenucleation using curette.

Following enucleation, the resection was performed ± 3 mm from apical using fissure steel bur perpendicular to the long axis of the tooth. The canal was prepared with round diamond bur in 3mm depth. The sharp bone and the apicals smoothed using freezer bur and bone file. The blood around cavity was dried. MTA was applied using Micro Apical Placement (MAP, Dentsply) as retrograde filling material (Figure 4). After MTA being applied, moist sterilized kassaare placed on the MTA.



(a)



(b)

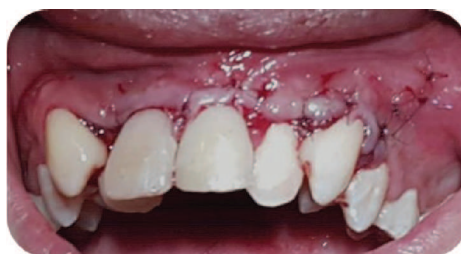Figure4. (a) Apeks condition after apicoektomi; (b) MTA applied using MAP system

The alveolar bone around apeks tooth 11 removed using round steel bur under saline irrigation. Periapical area of tooth 11 being curetted until granulated tissues were clean and the bone looks white. The granulated tissue of tooth 11 and cyst of tooth 21 preserved on the formaldehyde for Pathology Anatomy examination (Figure 5). Histopathological features were consistent with the clinical diagnosis of the radicular cyst with granuloma cholesterol ester for tooth 21 and granulomatous inflammatory for tooth 11.

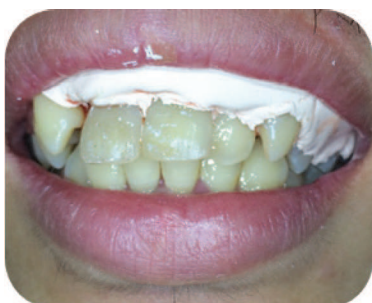


Figure5. Specimen of granulated tissue and cyst were preserved in formaldehyde solution for further examination.

Surgical area was irrigated with saline until clear. The flap is returned to the previous position and sutured with interrupted technique. Afterward, surgical area was covered with the periodontal pack for 7 days (Figure 6).



(a)

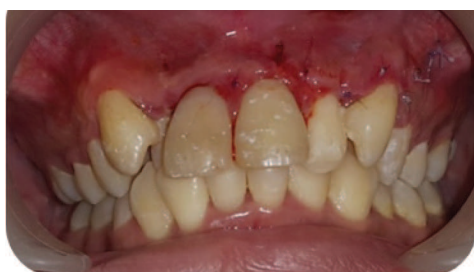

(b)

Figure 6. (a). The flap that has been returned to the previous position and undergo sutured with interrupted technique; (b). periodontal pack application to the surgical area.

The patient prescribes antibiotic (Clindamycin 300mg, taken three times a day for five days), analgesic (Paracetamol 500 mg, taken three times a day for three days), anti inflammation (KaliumDiklofenak 50 mg, taken two times a day for three days) , and recommended to always taking care off his oral hygiene.

The patient reported a periodically pain on the surgical area during the 7th day visit. During an objective examination, there are bleeding in some location where hecting previously performed (Figure 7).



(a)



(b)

Figure 7. (a). Clinical view on 7 days after surgery, showing a bleeding in some location where hecting previously performed; (b). Radiograph examination shows radiolucent area on periapical tooth

21

Clinical examination after 5 monthspostoperative showed a complete gingival healing,the patient did not complain about the pain andpercussion test revealed nonresponsive result. Periapical radiograph shows the reduction ofradiolucent in apex area.

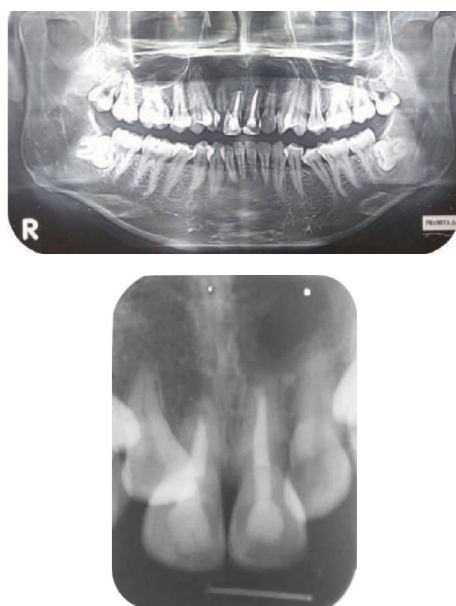


Figure 8. Radiograph examination view on OPG and periapical shows the radiolucen area in apex 21 looks smaller and significant healing on hard tissue

DISCUSSION

In many cases, after a traumatic dental injury, endodontic treatment is provided to caries-free, single-rooted, young permanent teeth. If quick and correct treatment for these teeth is provided after injury, the potential for a successful endodontic outcome is very good⁴. Dental Injuries or trauma may take on many shapes but generally can be classified as enamel fractures, crown fractures without pulp involvement, crown fractures with pulp involvement, crown-root fracture, root fracture, luxation, and avulsion⁵. One of the most common types of dental trauma is crown fractures. Complicated crown fractures occur in 0.9% to 13% of all dental injuries. A crown fracture involving

the pulp, if left untreated, always results in pulp necrosis. However, the manner and time sequence in which the pulp becomes necrotic allow a great deal of potential for successful intervention to maintain pulp vitality. The first reaction after the injury is hemorrhage and local inflammation. Subsequent inflammatory changes are usually proliferative but can be destructive over time. A proliferative reaction is favored in traumatic injuries because the fractured surface is usually flat, allowing salivary rinsing with little chance of impaction of contaminated debris. Unless impaction of contaminated debris is obvious, it is expected that in the first 24 hours after the injury, a proliferative response with inflammation extending not more than 2 mm into the pulp will be present. In time, the bacterial challenge results in local pulpal necrosis and a slow apical progression of the pulpal inflammation⁴.

If pathogens in the root canal are not eliminated, the symptomatic apical periodontitis may progress to become an asymptomatic apical periodontitis. Asymptomatic apical periodontitis is characterized by the persistence of inflammatory stimuli, adaptation of the host's response to stimuli, the presence of adaptive immune responses, and initiation of the repair process⁴.

Radicular Cysts are the most common inflammatory cysts arising from the odontogenic remnants. It is usually associated with carious, non-vital, or fractured tooth⁶. The radicular

cyst is unique because no cysts in the body have similar pathogenesis. It is believed that the radicular cyst is likely formed by inflammatory proliferation of epithelial cells rests in the inflamed periodontal ligament. The radicular cyst is a pathologic cavity completely lined by the nonkeratinized stratified squamous epithelium of variable thickness in a three-dimensional structure in an apical periodontitis lesion. Radicular cysts are lined by hyperplastic, nonkeratinized stratified squamous epithelium of variable thickness, which is separated from the fibrovascular connective tissue capsule by a basement membrane. Both the lining epithelium and the connective tissue capsule are usually infiltrated with inflammatory cells, indicating that inflammatory cells are attracted to these tissues by chemotactic irritants, either in the root canal system or the periapical tissues. The lumen of cysts may contain inflammatory exudates, cholesterol crystals, clear fluid, or bacterial colonies⁴.

The Radicular cysts are the most common inflammatory odontogenic cysts and are commonly found in the maxillary anterior region. Small cysts are usually found associated with non-vital teeth which are frequently involved with trauma. Treatment of choice is endodontic treatment or extraction of the offending tooth and enucleation of the cyst⁶.

Although nonsurgical endodontic treatment is a likely predictable option in most cases, surgery may be indicated for

teeth with persistent periradicular pathoses that have not responded to nonsurgical approaches. Apical surgery, when indicated, should be considered an extension of nonsurgical treatment, because the underlying etiology of the disease process and the objectives of treatment are the same: prevention or elimination of apical periodontitis. However, microorganisms can survive even in apparently well-treated teeth in dentinal tubules, canal irregularities, deltas, and isthmus areas. If residual microorganisms remain completely entombed in the root canal system, periradicular healing should occur. Sealing off all potential routes of microbial escape from the root canal system is the goal of both nonsurgical and surgical treatment. When microorganisms of sufficient pathogenicity and number gain access to the periradicular tissues, pathosis develops⁴. The success rates were reported for apical surgery varying between 44% and 90%. Based on a weighted average calculation of reviewed studies, a success rate of 81% was found for apical surgery with simultaneous orthograde treatment³.

In surgical endodontic therapy, a clinician removes irritants, such as necrotic cells, tissue debris, and bacteria in the periapical lesions, which is called *surgical debridement*. Surgical debridement is very effective and of course quite rapid, whereas biologic debridement takes time. However, endodontic surgery is more invasive. In addition, proper case selection is more important in endodontic surgery

than in nonsurgical endodontic therapy. The goal of surgical endodontic therapy is often to seal microbial etiology within the root canal system by retrograde filling in most cases⁴.

Retrograde filling materials used, ideally will provide apical seal and facilitate periapical tissue reparation. An ideal retrograde filling material must possess suitable adhesion to dentin, appropriate sealing, dimensional stability, insolubility to tissue fluids, fair compressibility, adequate working time and rapid setting⁷. Mineral Trioxide Aggregate (MTA) possesses the excellent sealing capacity and provides suitable long-term results. MTA has been recognized as a bioactive, osteoconductor and biocompatible material^{1,4}. MTA also appears to induce cementogenesis with new cementum deposition on the surface of the retrofilling material. In cases with inadequate hemorrhage control, MTA has been reported to be superior to other retrograde filling materials³. Several reviews on MTA's chemical properties, biocompatibility and clinical applications have been published. The present study revealed that with MTA cytotoxicity was almost nil in its fresh state, this concurs with other recent published where MTA has been deemed as a highly biocompatible retrograde filling material. Likewise, Kim and Kratchman mention in their article that MTA is the most biocompatible retrograde filling material, and that it can be used with predictable results in endodontic surgery procedures⁴.

CONCLUSION

Apical surgery is a chosen treatment for radicular cysts and lesion which cannot heal with the conventional endodontic procedure. Apical surgery is usually followed by retrograde filling such as MTA, with the purpose of closing the entrance of irritants into the root canal system.

REFERENCES

1. Arx T Von. Apical surgery : A review of current techniques and outcome. Saudi Dent J [Internet]. 2011;23(1):9–15.
2. Ratih DN, Putri AR. Effect of Blood Contamination on Push-Out Bond Strength of Mineral Trioxide Aggregate Mixed with Different Liquids. J Med Biol Eng [Internet]. 2017.
3. Controversies C, Oral IN. Failed Root Canals : The Case for Apicoectomy (Periradicular Surgery). 2005;832–7.
4. Tobergte DR, Curtis S. COHEN'S PATHWAYS of the PULP. Vol. 53, Journal of Chemical Information and Modeling. 2013.
5. Al-fouzan KS. A New Classification of Endodontic-Periodontal Lesions. 2014.
6. Parkar MI, Belgaumi UI, Suresh K V, Landge JS, Bhalinge PM, Dawoodbhoy RI. Bilaterally symmetrical infected radicular cysts: Case report and review of literature. J Oral Maxillofac Surgery, Med Pathol [Internet]. 2017.

7. Martínez-cortés M, Tinajero-morales C, Rosales C, Uribe-querol E. Cytotoxicity assessment of three endodontic sealing cements used in periapical surgery: In vitro study. Rev Odontológica Mex [Internet]. 2017;21(1):e40–8.

Literature Review

PH CHANGES OF ROOTS FOLLOWING ROOT CANAL DRESSING WITH HYDROGEL CHITOSAN, CONVENTIONAL CALCIUM HYDROXIDE AND A COMMERCIAL CALCIUM HYDROXIDE PASTE : LITERATURE REVIEW

Dwi Yani Sastika G* Trimurni Abidin **

* *Resident of Specialist Program of Conservative Dentistry*

***Lecturer of Specialist of Conservative Dentistry*

Faculty of Dentistry, University of Sumatera Utara
Jln. Alumni No.2 Kampus USU Medan 20155

ABSTRACT

Background: The use of a root canal medicament in the endodontic field is still needed today especially in cases with tertiary infection, the occurrence of flare-ups or the presence of large periapical lesions. Calcium hydroxide as a medicament in endodontic has been used in recent decades. **Review :** Antibacterials are associated with alkalinity of calcium hydroxide which can alter the integrity of the bacterial cytoplasmic membrane. The diffusion of calcium ions and hydroxyl ions into the periapical region through the apical foramen followed by the dentinal tubules around the apical region conditions the pH around the roots to be neutral. It then stimulates the defense cells, fibroblasts and stops resorption in the apical region as well as stimulates healing and repair. Some chitosan research as antibacterial root canal by invitro has been widely performed, both against *Streptococcus mutans*, *Enterococcus faecalis*, *Fusobacterium* and *Candida Albicans*. However, it is not yet known how the mechanism of action of chitosan as a medicament material in neutralizing the pH around the apex of a tooth that has periapical lesions. Therefore, research needs to be done if chitosan is used as an antibacterial root canal invivo. **Conclusion :** This article describes the mechanism of action the root canal treatment of Conventional Calcium Hydroxide, Commercial Calcium Hydroxide and Hydrogel Chitosan when used as a root canal medicament whether it can reach the periapical region and changes pH so that there is a healing and repair mechanism.

Keywords: pH Changes, Chitosan, Conventional Calcium Hydroxide, Commercial Calcium Hydroxide

Introduction

Bacteria play a major role in the development and progression of pulp and periapical diseases, as shown by many authors.¹⁻⁵ Bacteria can exist within the root canal itself, or within other related regions such as the dentinal tubules, accessory canals, canal ramifications, apical deltas, fins, and transverse anastomoses.^{1,2}

Periapical lesions of endodontic origin are produced by an inflammatory response at the root apices of teeth with nonvital pulps. After pulp necrosis, the root canal system becomes increasingly susceptible to colonization by the microorganisms. Due to close physiopathological relationship between the pulp and the periapical region, bacteria, fungi, and cell components may trigger an inflammatory process in periapical tissues, progressively affecting them through the resorption phenomenon. Subsequently, immunopathological mechanisms lead to the formation of abscesses, granulomas, and periapical cysts. Seltzer, Soltanoff, and Bender observed in a series of studies, that pulpo-periapical lesions have the potential for healing without surgical intervention. Cvek, Heithersay, Messer, and Stock have demonstrated successful clinical management of large periradicular lesion by the use of calcium hydroxide used as an interim dressing. Infections within the root canal system of a tooth cause periapical inflammatory responses which usually manifest as periapical radiolucencies on radiographs.³

The main goal of endodontic therapy is to eliminate or at least achieve a significant reduction of microorganisms present in the root canal system. It is well recognized that chemomechanical instrumentation alone is unable to completely disinfect the root canal system. The bacteria surviving root canal instrumentation proliferate between appointments. Therefore, the use of intracanal medication with antimicrobial activity between appointments has been recommended to eliminate possible persistent micro organisms, particularly in case of pulp necrosis with periapical lesions and periradicular bone loss. Calcium hydroxide with its antimicrobial property has been widely used in endodontics for interappointment intracanal dressing. It has been demonstrated that treatment with calcium hydroxide as an interim dressing in the presence of large and chronic periapical lesions can create an environment more favorable to healing and encourage osseous repair.⁴

Chitosan is a naturally occurring polysaccharide biopolymer that is produced by alkaline partial deacetylation of chitin. Chitosan, as a cationic natural polymer, has been widely investigated as an antimicrobial agent for preventing and treating infections owing to its intrinsic antimicrobial properties, and also its ability to effectively deliver extrinsic antimicrobial compounds into the infected area.⁵⁻⁸ The exact mechanisms of the antimicrobial actions of chitosan are still uncertain, but many new developments have been made

in exploring this aspect .

This article provides an explanation of the antimicrobial capability of calcium hydroxide when used as an intracanal root canal medicament and the antibacterial mechanism of chitosan.

Medicament in root canal treatment

According Weine, a medicament is an antimicrobial agent that is placed inside the root canal between treatment appointments in an attempt to destroy remaining microorganisms and prevent reinfection.¹ Farhad and Mohammadi stated medicament may be utilized to kill bacteria, reduce inflammation (and thereby reduce pain), help eliminate apical exudate, control inflammatory root resorption and prevent contamination between appointments.² Medicaments are used as an aid to improve the predictability and prognosis of endodontic treatment. They are used in endodontic therapy in order to:

1,2

1. eliminate or destroy any remaining viable bacteria in the root canal system that have not been destroyed by the chemomechanical preparation processes (i.e., instrumentation and irrigation),
2. reduce periradicular inflammation and hence reduce pain,
3. help eliminate apical exudate if it is present,
4. prevent or arrest inflammatory root resorption if it is present, and

5. prevent re-infection of the root canal system by acting as both a chemical and a physical barrier if the temporary or interim restoration breaks down.

Some medicament can be used in root canals to prevent or reduce the incidence of pain following initial canal debridement. Medicaments can exert their influence on the periradicular structures via diffusion of the active components through the root dentine and the apical foramen. A suitable environment may be achieved by destroying the bacteria (for example, with antibiotics or antiseptics) or by changing the pH (for example, with calcium hydroxide).¹ In essence, medicaments are used as an aid to improve the prognosis of endodontic treatment and to improve patient comfort.^{1,2}

Many material have been used as root canal medicaments throughout the past century. These material can be placed in two groups : those containing antiseptics and those containing antibiotics. Many of these agents contain a number of therapeutic or active components to increase their range of activity.

Calcium Hydroxide

Medicament material most commonly used today is calcium hydroxide $\text{Ca}(\text{OH})_2$ and still be a “gold standard”. This material is used as a medicament for endodontic treatment visit and have a good antibacterial properties.^{1,2}

The efficacy of calcium hydroxide in endodontic therapy stems mainly from its bactericidal effects, its ability to stimulate the formation of calcified tissue and its ability to denature protein which aids dissolution of pulpal tissue. It is believed that calcium hydroxide stimulates calcification by causing limited cell death adjacent to the material. This resultant sterile necrotic layer then undergoes passive calcification. When calcium hydroxide is placed in a root canal, it will cause an increase in the pH of root dentine which indicates that the hydroxide ion diffuses through the dentine. This is advantageous in that it will help to destroy bacteria present in the inaccessible areas of the root.^{1,2,10-13}

The antimicrobial activity of calcium hydroxide is due to the release and diffusion of hydroxyl ions (OH⁻) leading to a highly alkaline environment which is not conducive to the survival of microorganisms. The rate of diffusion of hydroxyl ions is slow due to the inherent buffering capacity of the dentine. Availability of calcium ions at the site of action appears to be useful for exerting therapeutic effects which are mediated through ion channels.¹ The role of calcium ions in cell stimulation, migration, proliferation and mineralization is well established. Calcium hydroxide also inactivates LPS and in so doing can assist periapical tissue repair.^{1,2,10-13}

Another important characteristic of the dissociation of calcium hydroxide into hydroxyl ions is the ability of these ions to inactivate bacterial lipopolysaccharide

(LPS), a toxin produced by gram-negative bacteria, commonly found in the root canal system. Thus, when applied in the root canal, calcium hydroxide should be able to diffuse through the apical foramen, secondary and accessory canals, as well as through the dentinal tubules, reaching areas of root resorption, areas contaminated by microorganisms and surrounding tissues, thereby exerting its action.¹⁰

Souza *et al.* suggested that the action of calcium hydroxide beyond the apex may be four-fold: (a) anti-inflammatory activity, (b) neutralization of acid products, (c) activation of the alkaline phosphatase, and (d) antibacterial action. A success rate of 80.8 and 73.8% has been reported with calcium hydroxide, when used for endodontic treatment of teeth with periapical lesions. It has been suggested that the presence of a cyst may impede or prevent root-end closure of an immature pulpless tooth even with the use of calcium hydroxide. Contrary to this, Çalışkan and Türkün have reported a case in which apical closure and periapical healing have occurred in a large cyst-like periapical lesion following non-surgical endodontic treatment with calcium hydroxide paste and a calcium hydroxide-containing, root-canal sealer. Extrusion of calcium hydroxide beyond the apex was suggested as a factor for the lack of early healing of periapical lesions. However, many investigators advocate that direct contact between calcium hydroxide and the periapical tissues is beneficial for the inductive action of the material. A high

degree of success has been reported by using calcium hydroxide beyond the apex in cases with large periapical lesions. It is barium sulphate that is added to the calcium hydroxide paste for radiopacity, which is not readily resorbed when the paste extrudes beyond the apex. However, it has been reported that even though complete resorption of the paste does not occur in some cases, the periapical radiolucency around the paste resolves.¹⁶

Nerwich et al. demonstrated that when calcium hydroxide dressings were placed into the root canals of extracted teeth, the hydroxyl ions diffused more quickly through dentine in the cervical third of the root than in the apical third because there are less tubules and they have a smaller diameter in the apical third. They also showed that the hydroxyl ions diffused in a matter of hours into the inner root dentine (i.e., adjacent to the root canal). However, a time period of 1-7 days was required for the hydroxyl ions to reach the outer root dentine (i.e., near the cementum), and 3-4 weeks to reach peak pH levels and to stabilize at these levels. It took nearly seven days for the pH to rise to 9.0, a level at which many bacteria do not grow. A study by Esberard et al. showed similar results. The pH in cavities on the root surface rapidly increased from control values pH 7.8 to greater than pH 9.0 within three days, followed by a small decline to pH 9.0 over the next 18 days before finally rising and remaining near pH 10.0 for 120 days without paste

replacement. Of note, aqueous calcium hydroxide and calcium hydroxide mixed with camphorated monochlorophenol released hydroxyl ions more rapidly than a commercial form of calcium hydroxide (*Pulpdent paste*, Pulpdent Corporation of America, Watertown, Massachusetts, USA), particularly in the apical region where the pH in canals filled with Pulpdent paste remained almost a full pH unit below the pH levels attained with the other two medicament preparations.¹

Estrela et al. studied the biological effect of pH on the enzymatic activity of anaerobic bacteria and concluded that hydroxyl ions from Ca(OH)_2 developed their mechanism of action in the cytoplasmic membrane. This membrane is responsible for essential functions such as metabolism, cellular division and growth, and it takes part in the final stages of cellular wall formation, biosynthesis of lipids, transport of electrons and oxidative phosphorylation. Extracellular enzymes act on nutrients, carbohydrates, proteins and lipids that, through hydrolysis, favour digestion. Intracellular enzymes located in the cell favour respiratory activity of the cellular wall structure. The pH gradient of the cytoplasmic membrane is altered by the high concentration of hydroxyl ions from calcium hydroxide acting on the proteins of the membrane (protein denaturation). The high pH of Ca(OH)_2 alters the integrity of the cytoplasmic membrane through chemical injury to the organic components and transport of nutrients or by means of the

destruction of phospholipids or unsaturated fatty acids of the cytoplasmic membrane, observed in the peroxidation process, which is a saponification reaction.¹³

Gomes et al. showed that the concentration of calcium ions peaked and stabilized at 2-3 weeks after packing root canals with calcium hydroxide. When calcium hydroxide comes into contact with carbon dioxide or carbonate ions (e.g., from bacterial metabolism), calcium carbonate is formed. This material has a very low solubility, creates only a mildly alkaline pH of 8.0, and as a result has neither biological nor antibacterial properties.¹

Chitosan

Chitosan composed of randomly distributed poly (1-4) β -linked D-glucosamine and N-acetyl-D-glucosamine, is an abundant natural positively charged, hydrophilic bipolymer. It contains more than 5000 glucosamine units and is derived from alkaline deacetylation of chitin that is obtained from the shells of crustaceans and is available in a variety of physical forms: film, fiber, bead, powder, or as nanoparticles. Chitosan is insoluble in most solvents, including water, but is soluble in organic acids such as acetic acid and lactic acid. In addition, chitosan contains high nitrogen content (6.89%), making it a useful chelating agent. The amines on chitosan become protonated at acidic pH and transmit a positive charge to the chitosan chains.⁵⁻⁹

Chitosan was first discovered in 1811

by Henri Braconnot, a French chemist and pharmacist. Bracannot observed that a certain substance (chitin) found in mushrooms did not dissolve in sulfuric acid. Later in the century, chitin was found in crustaceans (such as crabs, lobsters, shellfish and shrimp), the indigestible outer skeleton of insects and the material from which the cell walls of the mycelial fungi are made. It is also found in the radulas of mollusks, and the beaks of cephalopods (including squid and octopuses). Over the last 200 years, the study and application of chitosan has taken on many different forms. Researchers continue to build on the original finding of Bracannot, discovering new uses for chitin and chitosan as they find different forms of it in nature.⁹

Chitosan is a weak base and is insoluble in water, but soluble in dilute aqueous acidic solutions below its pKa (~ 6.3), in which it can convert glucosamine units ($-\text{NH}^2$) into the soluble protonated form ($-\text{NH}^{+3}$). The solubility of chitosan depends on its biological origin, molecular weight and degree of acetylation. Since chitosan is soluble in diluted acid solutions, films can be readily prepared by casting or dipping, resulting in dense and porous structure.⁹

In common with many cationic polymers, chitosan has pronounced antimicrobial effects due to destabilization of the outer membrane of Gram-negative bacteria and permeabilization of the microbial plasma membrane. It has been proposed that interaction between positively

charged chitosan molecules and negatively charged microbial cell membranes leads to the disruption of microbial membrane, and subsequently the leakage of proteinaceous and other intracellular constituents. At a lower concentration (<0.2 mg/ml), the polycationic chitosan binds to the negatively charged bacterial surface to cause agglutination, while at higher concentrations, the larger number of positive charges have imparted a net positive charge to the bacterial surfaces to keep them in suspension.⁹

Chitosan has been recognised as an antimicrobial agent, however its ability to act in this way is not completely elucidated as several different mechanisms have been attributed to this nature of chitosan. One proposed mechanisms for its antimicrobial activity is an electrostatic interaction between positively charged chitosan molecules and the negatively charged surface of a microbial cell that causes the leakage of proteins and other intracellular constituents from the cytosol, eventually leading to cell death.⁶⁻⁸ Yadav and Bhise report that when exposed to bacterial cell wall, chitosan promotes displacement of Ca^{++} of anionic sites of the membrane, resulting in cellular destruction.^{6,7}

Other studies suggest that the antimicrobial action is closely related to the physical-chemical properties of the polymer and the features of the cell wall of the microorganism. Another postulate is the interaction between the positive load of the chitosan and the negative load of the

microbial cell wall, because it causes the rupture and loss of important intracellular constituent of the microorganism life. Chitosan with low molecular weight penetrates in the cell and is linked to the microorganism DNA inhibiting the transcription and consequently the translation, whereas the chitosan of high molecular weight acts as a chelant agent, binding to the cell membrane.⁶

Lim and Hudson stated the antimicrobial activity for Chitosan is pH dependent. Not just because chitosan is only soluble in an acidic environment, and the molecule becomes polycationic as pH below the molecule's pKa. It has been reported that chitosan displayed antibacterial activity only in an acid environment, as is not proven to be strictly correct. Chitosan definitely shows stronger inhibitory effect at lower pHs, with inhibitory activity weakening with increasing pH. According Yang et al. antibacterial activity of the N-alkylated chitosan derivates (DS 30-40%) against E.Coli increased as the pH increased from 5.0 and reached a maximum around the pH of 7.0-7.5. This results also verify that positive charge on the amino groups is not the sole factor resulting in antimicrobial activities.⁵

For soluble chitosan, pH is a crucial factor relating to solubility, and can further alter antimicrobial activity. Another pH effect is protonation of chitosan and its derivatives. Antimicrobial activity of chitosan and its derivatives is exhibited

only when the pH is below the respective pKa, the value at which the soluble molecule could be disassociated as ions in solution. This mechanism is not restricted to soluble chitosan, but extends to solid chitosan.⁵

Kong et al. regarding the antimicrobial activity chitosan has demonstrated low toxicity and the resistance development has not occurred. The antimicrobial action of the chitosan and its derivatives suffers influence from factors, that depending on the performed role may be classified in four main categories: 1. Microbial factors (microbial species, age of the cell); 2. Intrinsic factors of the chitosan (positive charge density, molecular weight, hydrophobic and hydrophilic characteristics, chelation capacity); 3. Physical state factors (soluble and solid state) and 4. Environmental factors (pH, ionic forces, temperature, time). The antimicrobial action mechanism of the chitosan is not yet fully elucidated, being several action mechanisms suggested in literature. Some authors tell that the amino groups of the chitosan when in contact with physiological fluids are protonated and if bind to anionic groups of the microorganisms, resulting in the agglutination of the microbial cells and inhibition of growth.⁸

Trimurni A and Ivanti TI, reported the effect of high molecule chitosan blangkas with glycerin as an alternative of root canal dressing to candida albicans showed the largest drag zone was at concentration of

1% with mean inhibition zone diameter of 13.25 mm then 0,55% by 13.15 mm and 0.25% by 12.85 mm. Meaned the more high concentration of chitosan blangkas with glycerin more effective in inhibiting the growth of Candida albicans.¹⁴

Chitosan nanoparticles in endodontics

A new area of research has been created due to numerous reports of applications of chitosan, as well as, nanodiamond-based films to build drug delivery systems in medicine. Ribeiro et al. evaluated the applicability of chitosan hydrogel as a wound dressing. The results showed that chitosan hydrogel was able to promote cell adhesion and proliferation. Chitosan's positive charge allows for electrostatic interactions with glycosaminoglycans, which attract growth factors that enhance cell growth and proliferation. Cell viability studies showed that the hydrogel and its degradation by-products are non-cytotoxic. The evaluation of the applicability of chitosan in the treatment of dermal burns in Wistar rats was performed by induction of full-thickness transcutaneous dermal wounds. Macroscopic analysis revealed that the wound beds of the animals treated with chitosan were considerably smaller than those of the controls. Histological analysis revealed a lack of a reactive or granulomatous inflammatory reaction in skin lesions with chitosan and the absence of pathological abnormalities in the organs obtained by necropsy, which supported the local and systemic histocompatibility of the biomaterial. Application of ultraviolet light

irradiation to a photocrosslinkable aqueous chitosan solution resulted in an insoluble and flexible hydrogel . In order to evaluate its accelerating effect on wound healing, full-thickness skin incisions were made on the backs of mice and subsequently a photocross-linkable chitosan aqueous solution was added into the wound and irradiated with ultraviolet light for 90 seconds. Application of the chitosan hydrogel significantly induced wound contraction and accelerated wound closure and healing compared with the untreated controls. Histological examination showed an advanced contraction rate on the first two days and tissue fill rate on days 2 to 4 in the chitosan hydrogel-treated wounds. Furthermore, in cell culture studies, chitosan hydrogel culture medium supplemented with 5% fetal-bovine serum was found to be a chemo-attractant for human dermal fibroblasts in an invasion chamber assay using filters coated with matrigel and in a cell migration assay.¹⁵

Nanoparticle preparations have exhibited higher antibacterial activity than standard preparations. Chitosan nanoparticles (CSnp) are able to reduce biofilm bacteria, disrupt biofilm structure, and retain the antibacterial property after aging. CSnp also have displayed an increased polycationic/polyanionic interactions with the bacterial cell wall that leads to an increase in antibacterial activity). In a study by Shrestha et al. efficacy of CS and ZnO nanoparticles against *Enterococcus faecalis* bacteria

grown in planktonic and biofilm phases was evaluated. The rate of bacterial killing by CSnp was shown to be related to their concentration and their time of action. In this study bacteria in planktonic form were completely eliminated, but bacteria in biofilm managed to survive even after 72 hours of exposure. Interestingly, the nanoparticles tested retained their antibacterial properties for 92 hours.¹⁵

Nanoparticles can also be incorporated into root canal sealers to improve their antimicrobial properties. Kishen et al. investigated the antimicrobial properties of zinc-oxide eugenol (ZnOE) and resin-based sealers loaded with Chitosan and ZnO nanoparticles. Findings indicated an improvement in the sealers direct antibacterial property and increased ability of the antibacterial components of the sealers to leach out with the addition of nanoparticles. Furthermore, the addition of nanoparticles did not alter the flow characteristics of the sealer.¹⁵

Discussion

The antimicrobial activity of calcium hydroxide is due to the release and diffusion of hydroxyl ions (OH⁻) leading to a highly alkaline environment which is not conducive to the survival of micro-organisms. The rate of diffusion of hydroxyl ions is slow due to the inherent buffering capacity of the dentine. Availability of calcium ions at the site of action appears to be useful for exerting therapeutic effects which are mediated through ion channels.¹

The role of calcium ions in cell stimulation, migration, proliferation and mineralization is well established. Calcium hydroxide also inactivates LPS and in so doing can assist periapical tissue repair.^{1,2,10-12}

The lethal effects of calcium hydroxide are due to several mechanisms, namely : (a) chemical action through : damage to the microbial cytoplasmic membrane by the direct action of hydroxyl ions, suppression of enzyme activity and disruption of cellular metabolism, inhibition of DNA replication by splitting DNA, and (b) physically by : acting as a physical barrier that fills the space within the canal and prevents the ingress of bacteria into the root canal system, and killing the remaining micro-organisms by withholding substrates for growth and limiting space for multiplication.^{1,2}

The biological properties of calcium hydroxide include : biocompatibility (due to its low solubility in water and limited diffusion), the ability to encourage periapical hard tissue healing around teeth with infected canals, inhibition of root resorption and stimulation of periapical healing after trauma.¹

Chitosan is considered to be a bacteriocidal (kills the live bacteria or some fraction there in) or bacteriostatic (hinders the growth of bacteria but does not imply whether or not bacteria are killed), often with no distinction between activities. Recent data in literature has the tendency to characterize chitosan as bacteriostatic rather than bactericidal, although the exact

mechanism is not fully understood and several other factors may contribute to the antibacterial action.⁸

The overall mechanism(s) of action of an antimicrobial may be defined according to the target component of the bacterial cell against which it has its main activity. Thus, three levels of interaction can be described: (i) interaction with outer cellular components, (ii) interaction with the cytoplasmic membrane and (iii) interaction with cytoplasmic constituents. The mechanisms underlying the antimicrobial activity of chitosan have only been studied comparatively recently and the amount of information available is limited, although increasing. Several studies purport to have identified such mechanisms; but only few were supported by experimental evidence. These mechanisms of action are not mutually exclusive, since microbial inhibition by chitosan is thought to be a result of a sequence of molecular processes, resulting in random multiple detrimental events that ultimately lead to cell inhibition/killing.⁷

The polycationic structure of chitosan is a prerequisite for antibacterial activity. As environmental pH is below the pKa of chitosan and its derivatives, electrostatic interaction between the polycationic structure and the predominantly anionic components of the microorganisms' surface (such as Gram-negative lipopolysaccharide and cell surface proteins) plays a primary role in antibacterial activity.⁹

The polycationic structure forms

unnecessarily in acidic conditions, because the grafted groups of specific derivatives may change the pKa of chitosan and cause protonation at higher pH value. When the positive charge density of chitosan strengthens, the antibacterial property will increase consequently, as is the case with quaternized chitosan and chitosan complex. If the polycationic property of chitosan is deprived or reserved, the corresponding antibacterial capacity will be weakened or lost. It is generally assumed that the polycationic nature of chitosan, conveyed by the positively charged $-NH^{+3}$ groups of glucosamine, might be a fundamental factor contributing to its interaction with negatively charged surface components of many fungi and bacteria, causing extensive cell surface alterations, leakage of intracellular substances, and ultimately resulting in impairment of vital bacterial activities.⁸⁻⁹

Based on this, it has not been described the role if chitosan is used as a root canal medicament, the mechanism chitosan reaches the external root to alter the pH of the environment to the tooth with periapical lesions, so that there is a healing and repair mechanism.

Conclusions

Bacterial infection of the dental pulp may lead to periapical lesions. The use of intracanal medication with antimicrobial activity between appointments has been recommended to eliminate possible persistent microorganisms, particularly in case of

pulp necrosis with periradicular lesions.

Calcium hydroxide with its antimicrobial property has been widely used in endodontics for interappointment intracanal dressing. It has been demonstrated that treatment with calcium hydroxide as an interim dressing in the presence of large and chronic periapical lesions can create an environment more favorable to healing and encourage osseous repair. Chitosan has a recognized antimicrobial activity. The antimicrobial action mechanism of the chitosan is not yet fully elucidated, being several action mechanisms suggested in literature. The antimicrobial activity of chitosan may be accounted for by the contribution of the polymers to each elementary process in the biocidal action.

Further laboratory and clinical investigations are required to examine the pH changes of chitosan as uses an intracanal medicament compared with changes in pH of the root using calcium hydroxide as a root canal medicament.

REFERENCES

1. Athanassiadis M, Jacobsen N, Parashos P. The use of calcium hydroxide, antibiotics and biocides as antimicrobial medicaments in endodontics. *Australian Dental Journal Supplement* 2007;52(Suppl):S64-S82
2. Abbott PV. Medicaments : Aids to success in Endodontics. Part 1. A review of the literature. *Australian Dental Journal* 1990;35(5):438-48

3. Dharavath R, Veeramachaneni. Non-surgical endodontic approach for management of periapical lesions. *International Journal of Scientific Study*; March 2015;Vol 2:193-96
4. Dixit S, Dixit A, Kumar P. Case report : Nonsurgical treatment of two periapical lesions with calcium hydroxide using two different vehicles. *Hindawi Publishing Corporation-Case reports in dentistry* 2014; 901497
5. Kong M, Chen XC, Xing K, Park HJ. Antimicrobial properties of chitosan and mode of action : A state of the art review. *International Journal of food microbiology* 2010;144:51-63.
6. Carvalho M, Stamford T, Santos E, Sampaio F. Chitosan as an oral antimicrobial agent. *A. Mendez-Vilas (Ed)* 2011:542-50
7. Raafat, Sahl HG. Minireview. Chitosan and its antimicrobial potential – a critical literature survey. *Microbial Biotechnology* 2009;2(2):186-201.
8. Goy RC, Brito D, Assis BG. A Review of the antimicrobial activity of chitosan. *Polimeros : Ciencia e Tecnologia* 2009;Vol 19:241-47
9. Dai T, Tanaka M, Huang Y, Hamblin M. Chitosan preparations for wounds and burns : antimicrobial and wound healing effects. *NIH-PA Author Manuscript* July 2011;9(7): 857-79
10. Siqueira JF, Lopes HP. Review Mechanisms of antimicrobial activity of calcium hydroxide : a critical review. *IEJ* 1999;32:361-69
11. Sathorn C, Parashos P, Messer H. Review Antibacterial efficacy of calcium hydroxide intracanal dressing : a systematic review and meta-analysis. *International Endodontic Journal* 2007;40:2-10
12. Mohammadi Z, Dummer PMH. Properties and applications of calcium hydroxide in endodontics and dental traumatology
13. Estrela C, Pecora JD, Silva RS. pH analyse of vehicles and calcium hydroxide pastes. *Brazilian Endodontic Journal* 1998;3(2):41-7
14. Trimurni A, Ivanti TI. Effect of High molecule chitosan blangkas with glycerin as alternative of root canal dressing to *Candida albicans*. *Dentika Journal* July 2010;Vol 15;No.1:71-4
15. Persadmehr A. Thesis : Bioactive Chitosan Nanoparticles and Photodynamic Therapy Inhibit Collagen Degradation in vitro. *Faculty of Dentistry University of Toronto*: 2013
16. Fernandes M, Ataide I. Nonsurgical management of periapical lesions. *J Conserv Dent* ; Oct-Dec 2010;13(4): 240-45

MULTIPLE DIASTEMA CLOSURE USING DIRECT VENEER RESTORATION COMBINED WITH EXTERNAL BLEACHING: A CASE REPORT

Edra Brahmantya Susilo*, Ira Widjiastuti**

*Resident, Departement of Conservative Dentistry

** Staff Department of Conservative Dentistry

Faculty of Dental Medicine, Universitas Airlangga Surabaya, Indonesia

ABSTRACT

Background: One of the most common aesthetic problems is the discoloration and multiple diastema of the anterior teeth. This can make the patient's appearance disturbed and can lead to confidence in influential patients in the complex interaction of social, cultural and psychological disorders. **Purpose:** The purpose of this case report is to explain the management of anterior diastema closure treatment with external bleaching combined with the direct veneer. **Case:** A 27-year-old man came to the Departemen Conservative Clinic of RSGM UNAIR with complaints of discoloration on his front teeth and tucked food. **Management:** Patients performed external teeth whitening first to get better tooth color. Then, the treatment of multiple diastema closure using a direct veneer technique. **Conclusion:** Multiple diastema preservation with veneer direct restoration begins with external bleaching is able to produce good aesthetic results.

Keywords: tooth discoloration, multiple diastema, external bleaching, direct veneer

Correspondence : Edra Brahmantya Susilo, Resident of Conservative Dentistry, Faculty of Dental Medicine, Airlangga University. Email : edrabrahmantya@gmail.com

INTRODUCTION

Esthetics is the field that studies the nature of beauty and seeks to enhance the particular details of static and dynamic objects to make them more visually appealing. The artistic nature of dentistry and the growing esthetic demands of dental patients have led to the specialty of "esthetic dentistry".¹

Treatment of tooth discoloration is one of the most important fields of esthetic dentistry. In ancient cultures and their artworks, white teeth symbolized beauty and good health. Past dental surveys revealed that 28 to 34% of surveyed subjects are dissatisfied with the color of their teeth and seek bleaching treatment. Dental bleaching has been reported as the most conservative method. simplified, and low cost approach

to change the color of discoloured teeth. Bleaching techniques have been markedly improved, from using pure chemical peroxidess, until reaching the recent light/laser-assisted bleaching systems.¹

The pigments oxidation is responsible for tooth bleaching and can be carried out with two different products; carbamideperoxide and hydrogen peroxide.¹

Vital whitening is performed on teeth that have live nerves. The most common type of vital tooth whitening uses a gel-like whitening solution that is applied directly to the tooth surface. This product contains some form of hydrogen peroxide, Vital bleaching is an in-office procedure and the most popular systems for in-office bleaching use high concentration hydrogen peroxides and are often referred to as “one-hour bleaching”. These high concentration hydrogen peroxides range from 25% to 35%. In-office bleaching can be provided to patients as either a one-visit of 1–1.5 hour treatment or a multiple visit procedure.¹

The other problem on esthetic dentistry is anterior diastema. The presence of multiple spaces in the anterior aesthetic zone can produce discomfort for patients and its treatment can be difficult for dental professionals. A variety of treatment options are available and these include orthodontic movement, prosthetic indirect restorations or direct composite resin build-ups. Among these, the closure of interdental spaces using composite build-ups combined with orthodontic treatment

is considered to be most conservative. This type of treatment has several advantages like the maximum preservation of tooth substance (no tooth preparation), no need for anesthesia, no multiple time-consuming visits, no provisional restorations and also comparably low costs.²

Tooth size discrepancy or inappropriate distribution of space in the anterior region is a major esthetic issue for patients of all ages. The anterior spaces have a multifactorial etiology like microdontia, lateral incisor agenesis, habits like a finger sucking or tongue thrusting, lip sucking, dental–skeletal discrepancies and many more. As dental patients are becoming increasingly conscious about their appearance, they demand for aesthetic and minimal invasive high quality restorations.³

The improvement of adhesive and composite technology it became possible that direct composite build-ups are able to withstand great masticatory forces without suffering from fracture or loss. Recent aesthetic composite resin materials provide great optical properties and offer a wide range of shades and varying opacities, translucencies and textures.³

This case report describes combine of external bleaching for treatment the tooth discoloration and the clinical restorative procedure of direct composite resin build-ups for the closure of multiple anterior spaces.

CASE

A twenty-seven years old men patient came to the Conservative dentistry clinic of Airlangga University. He complained the discoloration teeth with that large spaces between his maxillary anterior teeth. (Figures 1)

The patient's medical history did not reveal any systemic diseases, but he have smoke and drink coffee habit. Intraoral clinical examination revealed irregular spaces between the maxillary central incisors and lateral incisors on both sides. The largest interdental spaces were approximately 1 mm in width. The general tooth shade (VITA) of D3 (Figure 2). Additionally, questions about any history of tooth sensitivity were asked. The importance of this is that patients with a history of tooth sensitivity occasionally experience mild to moderate tooth sensitivoty for 24 hours after in-office bleaching. In the case of this patient, he had no history of any tooth sensitivity.

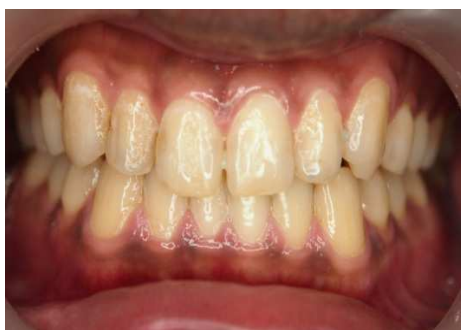

Figure 1. Pre-Operative Intraoral Condition

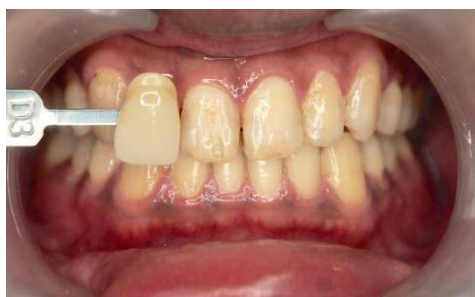

Figure 2. Pre-Operative Tooth Shade Guide

CASE MANAGEMENT

On first visit, anamnesis, clinical examination, thorough explanation, make a model study to prepare a wax-up and patient's consent about esthetic treatment procedure were done.

For this patient, Opalboost was choosen (Ultradent). This material contains 40% hydrogen peroxide, which facilities significant whitening procedure with a start to finish time of less than an hour. The shorter treatment time and and the inclusion of potassium nitrate in the composition, provides patients with less treatment and/or post-operative sensitivity than other in-office system. The teeth was cleaned with pumice slurry. After this, gingival barries was place into to the sulcus gingiva on the work area to safe the gingiva from the bleaching gel. With one Opalboost syringe, tip was firmly attached, and carefully plugger was pulled back to release the pressure. Contents of the syringe was carefully extrude into the pot and immediately mixed using a brush applicator until gel turns homogeneous. A thick layer of gel was then aplied to all teeth undergoing treatment (Figure 3).

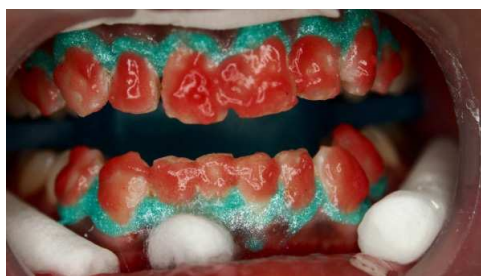

Figure 3. Application of the bleaching gel

Optional curing light was used according to manufacture's instructions, suction was performed using a surgical aspirator tip. Four applications were used to complete the in-office procedure. After the last application, all the applied gel was suctioned, washed with water. After the completion of the procedure, the gingival barrier was removed. In this case, a bleaching LED curing light was used as this is a cost effective and easy to use light source for augmenting the in-office procedure. Using standard visual examination and confirmation with VITA Shade Guide, a shade change increase until to B1. Final polishing of the teeth was performed after the desired shade improvement. (Figure 4).

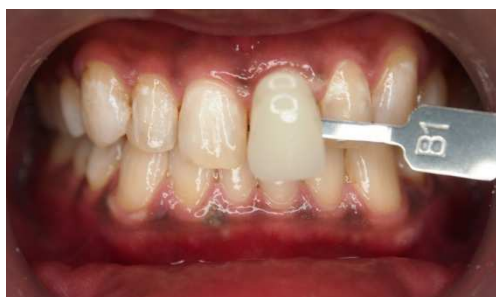

Figure 4. Final shade after bleaching application

Patient was recalled after 2 weeks for follow-up and prepare to the next treatment. Show the diagnostic wax-up to confirm to him (Figure 5).

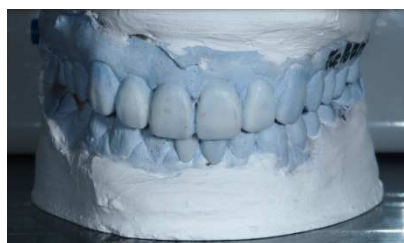

Figure 5. Diagnostic Wax-Up

After that, shade selection was considered A2 shade of VITA guide for the teeth to be restored. In order to simulate a natural A2 shade outlook, the shades AO2, A2 and JE (Gaenial, GC, Japan) were decided to be used together as layers. Minimal preparation were performed because on several teeth any Class III caries. All maxillary were isolated with rubber dam. The adjacent anterior maxillary was covered with Teflon band while the other was restored. 37% phosphoric acid (Coltene) was applied on the tooth surface to be restored for 15 seconds, rinsed and dried with air slightly. Then a single bottle bonding agent (Adper Single Bond, 3M ESPE, USA) was applied and polymerized for 20 seconds with a LED light cured. A thin layer CT (3M Z350) shade transparent composite resin was used palatally shell (Figure 6).

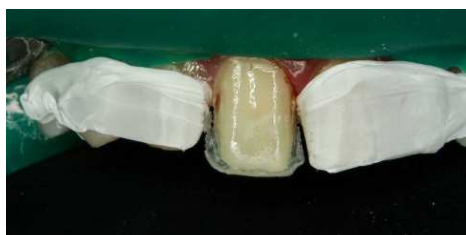

Figure 6. Palatal Shell

A thin layer of AO2 shade opaque composite resin was placed roughly as second layer. A2 shade composite resin was used as dentin layer and a thin layer JE shade was used the top enamel layer.

Labial surface of the restoration were flattened by using yellow banded knife-edge tip diamond bur (Figure 7).

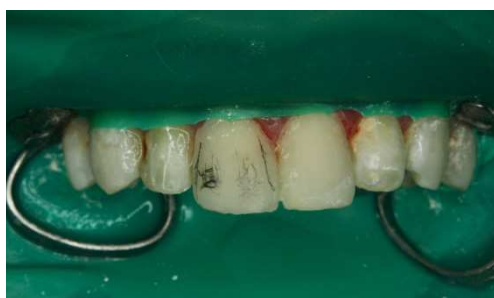

Figure 7. Create Texture of Enamel Surface

Polishing discs (EVE) were used for detailed polishing from rough to fine grains and composite polishing (EVE Diacomp) by using a low speed handpiece (NSK) (Figure 8).

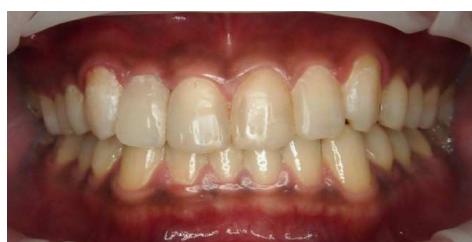

Figure 8. Polishing Enamel Surface

DISCUSSION

Tooth colour is determined by the combination of different optical properties of enamel, dentin and pulp. Extrinsic discolorations can be removed with a prophylactic cleaning procedure, but intrinsic staining necessitates various treatment options to completely eliminate or even mask the discoloured areas of teeth.¹

Various methods have been suggested to remove or mask discoloration such as microabrasion, macroabrasion, vital or non-vital bleaching, direct or indirect veneering and full crowns. Conservative treatments like microabrasion, bleaching, and macroabrasion offer advantages over the conventional treatments involving partial or complete coverage restorations.⁵

In this case treatment is done by vital bleaching and direct composite veneer. Vital bleaching is the first step to correct the color of teeth are not done by direct composite veneer (mandible anterior and canine to premolar maxila). Then, the direct composite veneer is to correction the multiple space on second right insisive to second left insisive maxila.

Teeth exhibiting yellow or orange intrinsic discolouration seem to respond best to vital bleaching. Most of the bleaching gels contain 35-40% hydrogen peroxide because it has a low molecular weight to easily pass through the enamel and dentin. Use of a light to generate heat may accelerate the oxidation reaction of the

hydrogen peroxide owing to an immediate whitening of the teeth. This can increase the tooth sensitivity occasionally but that effect is transient.²

Composite veneers which require minimal removal of tooth structure by single appointment are one of the best treatment choices for discolored teeth. Although ceramic laminate veneers have some advantages like color stability and high resistance against abrasion, they have also some disadvantages including high cost and long chair side time.⁵ So, vital bleaching and direct full composite veneers were indicated for this case. G-Aenail from GC was used due to its superior mechanical properties and esthetics.

CONCLUSION

Combined between vital bleaching external and direct veneer composite can be a valuable treatment option in treatment of midline diastemas due to tooth size discrepancies. The utilization of a diagnostic wax-up, palatal index and customized matrix can greatly improve the control of the operator over the fine reproduction of anatomic details and will result in easily achievable aesthetic restorations. Besides, this can be seen as an economic treatment option for discolor treatment and aesthetic correction of midline diastemas.

REFERENCES

1. Frese C, Staehle HJ, Wolff D. The assessment of dentofacial esthetics in restorative dentistry: a review of the literature. *J Am Dent Assoc*, 2012; 143:461-466.
2. Higley LB. Maxillary labial frenum and midline diastema. *ASDC J Dent Child*, 1969; 36:413-414.
3. Huang WJ, Creath CJ. The midline diastema: a review of its etiology and treatment. *Pediatr Dent*, 1995; 17:171-179.
4. Wirsching E. Contemporary options for restoration of anterior teeth with composite. *Quintessence Int*, 2015; 46:457-463.
5. Astvaldsdottir A, Dagerhamn J, van Dijken JW, et al. Longevity of posterior resin composite restorations in adults - A systematic review. *J Dent*, 2015; 43:934-954.

A CASE REPORT

HEALING OF LARGE PERIAPICAL LESION WITH NON SURGICAL ENDODONTIC TREATMENT APPROACH: A CASE REPORT

Ellyda Nasution * Dennis **Trimurni Abidin **

** Resident of Specialist Program of Conservative Dentistry*

***Lecturer of Specialist of Conservative Dentistry*

Faculty of Dentistry, Universitas Sumatera Utara

Jln. Alumni No.2 Kampus USU Medan 20155

ABSTRACT

Due to pulp tissue necrosis the pulp chamber is transformed into unprotected environment. This unprotected environment becomes susceptible to colonization by numerous microorganisms. Development of periapical lesions is associated with the presence of microorganisms in the root canal system. To treat such cases there are surgical and non-surgical methods. Healing of periapical lesions will not be achieved only through surgical removal of the periapical lesion without proper root canal disinfection. Proper cleaning, shaping, disinfection, and proper obturation of the root canal system aid in the success of non-surgical endodontic treatment. This clinical case report highlights follow-up results of cases demonstrating the resolution of periapical lesion through nonsurgical approach, confirms that periapical lesions respond favorably to non-surgical treatment. The case of a 22-year old female patient presented with complaints of pain in the maxillary central incisor, came to the clinic of RSGM FKG USU. Based on the subjective and objective-examination, the tooth showed no respond on vitality test and radiography showed large periapical lesion. Non surgical endodontic treatment was performed in patients. Clinical evaluation on follow-up period showed no complaint of pain, the resolution of periapical lesion through non surgical approach confirms that periapical lesion respond favorably to non-surgical treatment.

Keywords: Healing, Large Periapical lesion, Non Surgical Endodontic Treatment

INTRODUCTION

Pulpal necrosis as a result of trauma and caries is the main cause of large periapical lesions. Varieties of lesions mimic the large periapical radiolucency, but most of them are the cyst, granuloma, or abscess.¹ Most of these lesions remained asymptomatic for years and diagnosed during the routine radiographic

examination or during acute exacerbation of chronic lesion. Apart from the periapical abscess which can be easily diagnosed based on the clinical symptoms combined with a radiographic examination, it is difficult to differentially diagnose between periapical granuloma and periapical cyst. The cyst has a well-defined radiolucent lesion more than 200 mm² in size and

contains straw colored fluid. However, definitive diagnosis between the periapical granuloma and periapical cyst can be made by histological examination only.²

Periapical surgery is the first treatment choice that comes to our mind to manage a large cyst like lesion. However, nonsurgical endodontic approach should be considered first.³ Surgical intervention is considered only when nonsurgical approach fails. Moreover, the surgical intervention has many limitations such as the medical condition of patient, proximity to anatomical structures, psychological trauma to the patient and is not possible in every patient.⁴

Periapical lesions are mainly inflammatory in origin and expand by epithelial proliferation and increase in hydrostatic pressure inside the lesion.⁵ Microorganisms and their by-products are the main cause of inflammation. After removing the microbiological etiology of inflammation epithelial lining undergoes the process of apoptosis. The hydrostatic pressure of the lesion can be reduced by decompression and aspiration of lesion contents through the cortical plate or the aspiration through the root canal. Aspiration and decompression of the lesion contents through the root canal is more conservative approach and preferred over decompression and aspiration through cortical plate since it creates the buccal or palatal wound.⁶ So reducing microbial load by long-term use of intracanal medicament after the evacuation of lesion content leads

to regression of the lesion.

Most periapical lesion (> 90%) can be classified as dental granuloma, cyst / abscess.^{7,8} Treatment options to manage such periapical lesions range from non-surgical root canal treatment and/or apical surgery to extraction. Various studies have reported a success rate of up to 85% after endodontic treatment of teeth with periapical lesions.^{9,10} A high percentage of 94.4% of complete and partial healing of periapical lesions following nonsurgical endodontic therapy has also been reported.¹¹ Large periapical lesions have been routinely treated surgically but a more conservative non-surgical approach that can be treated by calcium hydroxide can't be overlooked. The basic premise of any endodontic treatment is to have a conventional orthograde approach than to have more invasive surgical treatment modality. Calcium hydroxide is the intracanal medicament extensively used in endodontics for many years due to its antimicrobial properties and mineralization potential.¹²

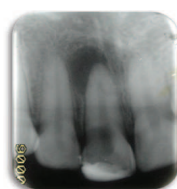
In view of that calcium hydroxide definitely has an advantage, when we look at its outstanding action as an intracanal medicament in nonsurgical management of a case. However it is not a panacea. But, can still be argued to be successful in 75 % of cases.¹³ This paper presents a case series of non-surgical management of large periapical lesions in which calcium hydroxide were used as an intracanal medicament.

CASE

A 22-year-old female patient referred to the Department of Conservative Dentistry Clinic, RSGMP FKG USU with the chief complaint of intermittent pain in central incisor for 5 days which subsides after taking an analgesic. Her medical history was non-contributory. Dental history reported trauma occurred 2 years ago for which she had undergone dental treatment. Intraoral examination revealed no swelling in the region of tooth #11. It was tender on percussion. Vitality testing reveals nonvital #11. Radiographically largeperiapical radiolucency was noticed around #11 with diameter 7 mm (fig. 1a, 1b) with a well-defined border. The tooth had already been filling by some general practitioner before. A diagnosis of the periodontitis apikalis kronis etcausa trauma with large periapicallesion, and non-surgical root canal treatment was decided.

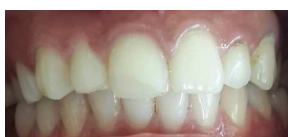

Figure 1a.Pre-
Operative,



1b. Pre op
Radiography

Case management

Teeth #11 is planned for then root canal treatment is proceeded. Patients are given information about the procedure to be performed and sign a medical consent (was signed informed consent). On the first visit after tooth has isolated, with access

cavity and preparation was done (Figure 2).

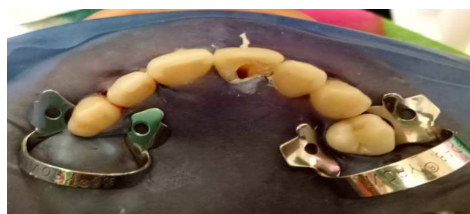

Fig. 3 Access Opening

Exploring orifice done with the aid of endodontic explorer and orifices were found. Then, the negotiation was done with K-file number #10 or #15. Working length of the root canals was determined with the help of using an electronic apex locator (Raypex 6, VDW Endodontic Synergy, Germany) and confirmed radiographically with initial apical file (#20/22 mm) Figure 3.

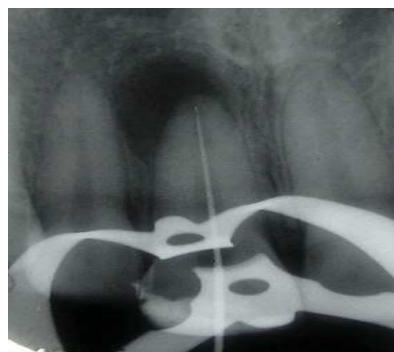

Figure 3. IAF

Chemo-mechanical preparation of root canal was done with iRace rotary instrument files of sizes R1, R2 until R3 and copious irrigation with 2.5% sodium hypochlorite and activated irrigation solution for 1 minute (Endoactivator), then dried the root canal with paper points.

Intracanal medicament using Calcium Hydroxide(Viopaste, Spident, By Engold Co., Ltd) for 1 month and temporary filling with glass ionomer cement (Figure 4).

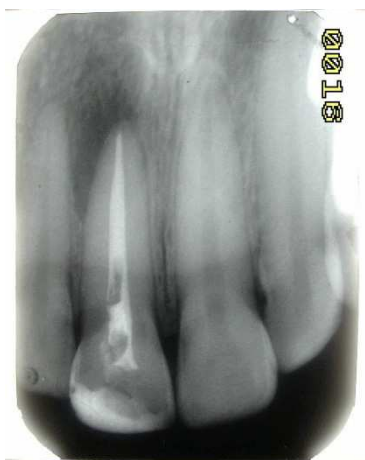

Figure 4. Medicament Intracanal Calcium hydroxide

On the second visit, patients still felt a little discomfort. Remove temporary filling was removed and canal was cleaned with 2.5% sodium hypochlorite. The canal was dried with paper points and given intracanal medicament calcium hydroxide (Viopaste, Spident, By Engold Co., Ltd) for 1 month and temporary filling with glass ionomer cement (Fuji I, GC Corp.)Figure 5.

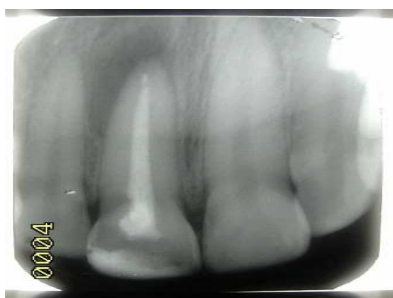

Figure 5. Medicament Intra canal Calcium Hydroxide

On the three visits there were no exudates from the canal. After irrigation with sodium hypochlorite and temporization, the tooth was checked after 1 month and was found to be totally asymptomatic. Canal was dried, and calcium hydroxide (Viopaste, Spident, By Engold Co., Ltd) was intentionally pushed slightly into the lesion and checked radiographically. The patient was monitored radiographically every month. After 4 months the lesion reduced in size considerably and viopaste inside the lesion got resorbed. Calcium hydroxide (Viopaste, Spident, By Engold Co., Ltd) was removed from the canal, and root canal treatment was ready for obturation(fig.5a, 5b). The patient was recalled after three month when most of the lesion was found to be healed.

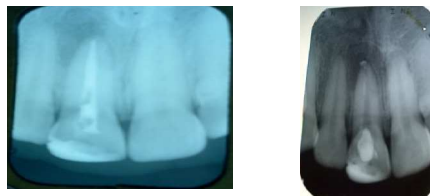


Figure 5a.three month b. four month

On the fourvisits, tooth was #11 was asymptomatic and the tooth showed healing in periapical lesion. Temporary filling removed and dressing materials cleaned once again and irrigated with 2.5% sodium hypochlorite. 2.5% sodium hypochlorite solution was activated for 1 minute per canal. Then, rinsed with saline and irrigated again with EDTA + CHX (Smearoff) which is activated for 1 minute

the canal. The canal was dried with paper points and non ISO gutta-percha# 30/4, master apical cone inserted into the root canal to working length and confirmed by radiographs (Figure 7). Access cavity filled with temporary filling.

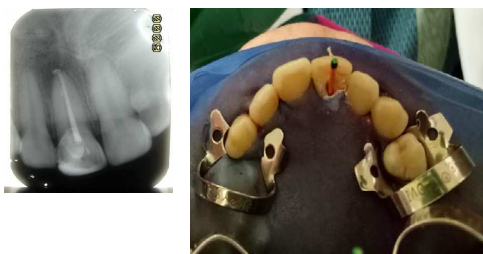


Figure 7. MAC

The canal was obturated with lateral condensation technique and using sealer (AH Plus, DENTSPLY). Then, the result of obturation was evaluated radiographically (Figure 8).

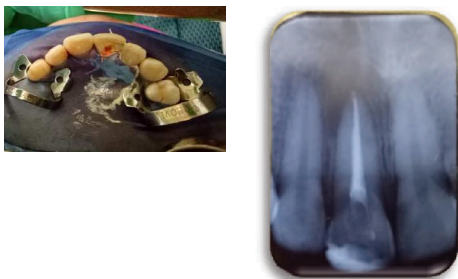

Figure 8. Obturation

After that, the orifice barrier was done with RMGIC (Ionoseal NDT) and access cavity was sealed with temporary filling (Fuji I, GC Corp.). After one week of follow up, the tooth had no complaint. A final restoration of the #11 was veneer direct with resin composite (Filtek Z350 XT, 3M) figure 9.

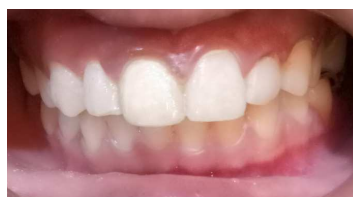

Figure 9. Final Restoration

After obturation, teeth #11 was controlled for 3 month, 6 month and 1 year. Visible lesion was under the process healing (figure 10a,b, c, d)

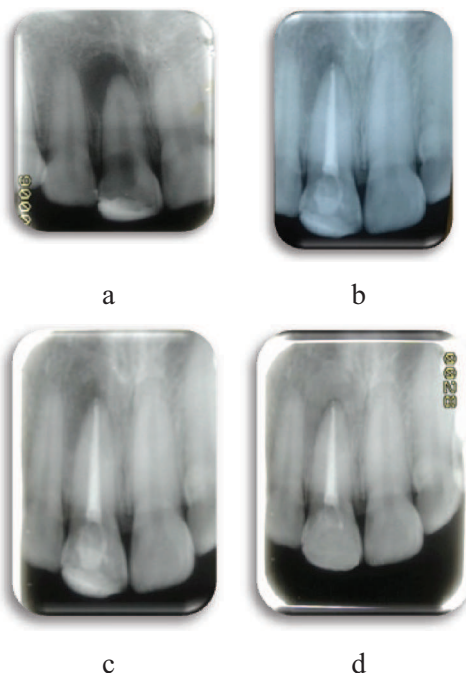


Figure 10a. Pre- operative, b. follow up 3 month, c. follow up 6 month, d. follow up 1 year

DISCUSSION

Necrosis of pulp due to trauma or caries that creates a favorable environment for different bacteria to grow is the main reason behind the formation of a large periapical lesion.¹ A proper diagnosis of these lesions can only be made through

histological examination, but a preliminary diagnosis can be made based on clinical and radiological examination. Non-surgical treatment protocol of these lesions whether a granuloma, cyst or abscess are almost similar. These lesions were considered to be inflammatory in origin, and inflammatory lesion can be healed after the removal of etiology of inflammation.⁸ Irrigation of the canal is very important. However, medicament with bactericidal action is still needed to ensure optimum disinfection.⁹ A good root canal substance has several conditions: having broad spectrum antimicrobials capable of fighting anaerobic and facultative microorganisms in the form of biofilm, dissolving leftover pulp tissue, capable of disabling endotoxin, preventing the formation of its smear layer during instrumentation or dissolving it if formed. when contacted with healthy tissue irrigation does not cause toxicity, is not caustic to periodontal fingers and has little potential for anaphylactic reactions. NaOCl is a commonly used irrigation fluid which is a broad-spectrum antibacterial capable of killing all forms of bacteria such as vegetative and spore forms, as well capable of killing fungi, protozoa and viruses.⁶ Calcium hydroxide is the most commonly used intracanal medicament to disinfect the canal. So for the success of treatment of large periapical lesions, two things are important. Calcium hydroxide has long-acting antimicrobial properties and good biocompatibility. Calcium hydroxide has a pH range between 12.5-12.8 and water solubility. The low solubility of calcium

hydroxide was useful for slow dissolved in the cell liquid. Calcium hydroxide works by releasing hydroxyl ions which increased the pH and inhibit microorganisms to grow. Calcium hydroxide can also hydrolyze lipopolysaccharides (LPS), which is a bacterial virulence factor.¹⁶

There are several mechanisms contributes to the lethal effect of which owned by calcium hydroxide with physically and chemically. Physically the calcium hydroxide acts as protective filling in the root canal that will minimize the space of bacteria to grow and prevent the entry into the root canal. Chemically calcium hydroxide causes damage to the cell membrane of bacteria, inhibits the action of enzymes, cell metabolism and inhibits DNA replication.¹⁶

It has also been reported that especially in young patients treatment with Ca(OH)_2 resulted in a high frequency of periapical healing.¹⁰ It may takes many months for healing of lesions. Caliskan and Sen¹⁴ have reported that high frequency of periapical healing showing completed resorption of the periapical defect is observed with the treatment of calcium hydroxide. The exact mechanism of action of calcium hydroxide is still speculative. The efficacy of calcium hydroxide, owing to its antiseptic, anti-exudative, and mineralization inducing properties depends on the sustained release of calcium and hydroxyl ions to the root canal and periapical region. Regular renewal of the root canal dressing is fundamental in reducing the

intensity of the periapical inflammatory process as they are progressively resorbed by the periapical fluids. Root canal dressing transforms the inflammatory granulation tissue into reparative granulation tissue, and simultaneously the differentiation of undifferentiated mesenchymal cells into reparative cells.¹⁵

CONCLUSION

The surgical approach is not the only treatment option that remains for treating the large periapical lesions. These lesions can be successfully treated with the nonsurgical endodontic approach along with long-term calcium hydroxide therapy. Barium sulphate and iodoform along with calcium hydroxide do not have the detrimental effect on healing process if extruded periapically. Healing of periapical lesion is effectively achieved through calcium hydroxide interim dressing. It is necessary to observe and monitor the prognosis of periapical lesions.

REFERENCES

1. Bhaskar SN. Periapical lesions-types, incidence, and clinical features. *Oral Surgery Oral Medicine and Oral Pathology* 1996; 21: 657–71.
2. Gbadebo SO, Akinyamoju AO, Sulaiman AO. Periapical pathology: comparison of clinical diagnosis and histopathological findings. *J West Afr Coll Surg* 2014; 4(3): 74–88.
3. Lin LM, Ricucci D, Lin J, Rosenberg PA. Nonsurgical root canal therapy of large cyst like inflammatory periapical lesions and inflammatory apical cysts. *J Endod* 2009; 35: 607–15.
4. Neaverth EJ, Burg HA. Decompression of large periapical cystic lesions. *J Endod* 1982; 8: 175–82.
5. Toller PA. Newer concepts of odontogenic cysts. *Int J Oral Surg* 1972; 1: 3–16.
6. Hoen MM, LaBounty GL, Strittmatter EJ. Conservative treatment of persistent periradicular lesions using aspiration and irrigation. *J Endod* 1990; 16: 182–6.
7. Bhaskar SN Periapical lesion – types, incidence and clinical features. *Oral Surgery, Oral Medicine and Oral Pathology* 1966; 21, 657–71.
8. Lalonde ER, Leubke RG. The frequency and distribution of periapical cysts and granulomas. *Oral surg oral med oral pathol* 1986; 25: 861–8.
9. Sjogren U. Hagglund Sundqvist G. Wing K. Factors affecting the long term results of endodontic treatment. *J Endod*. 1990; 16: 31– 7.
10. Hali'Ikan MK, en BH. Endodontic treatment of teeth with apical periodontitis using calcium hydroxide: a long term study. *Endod Dent Traumatology* 1966 ;12:215–21.
11. Murphy WK, Kaugars GE, Collet WK, Dodds RN. Healing of periapical radiolucencies after nonsurgical endodontic therapy.

- Oral Surg Oral Med Oral Pathol. 1991;71:620–4. Sjogren et al 1990, Caliskan & Sen 96—IEJ 2004.
12. Hauman CH, Love RM. Biocompatibility of dental materials used in contemporary endodontic therapy: a review. Part 1. Intracanal drugs and substances. *Int Endod J* 2003; 36: 75–85.
 13. Tronstad L, Andreasen JO, Hasselgren G, Kristerson L, Riis I : pH changes in dental tissue after root canal filling with calcium hydroxide. *J Endod* 1981;7:17-21.
 14. Caliskan MK, Sen BH. Endodontic treatment of teeth with apical periodontitis using calcium hydroxide: A long-term study. *Endod Dent Traumatol* 1996;12:215-21.
 15. Soares JA, Brito-Júnior M, Silveira FF, Nunes E, Santos SM. Favorable response of an extensive periapical lesion to root canal treatment. *J Oral Sci* 2008;50:107-11.
 16. Mustafa M, Saujanya KP, Jain D *etal.* Role of calcium hydroxide in endodontics: a review. *GJMEDPH* 2012 ; 1 (1) : 66-70.

CASE REPORT

REPLANTATION AND REPOSITION OF IATROGENIC AVULSION IMPACTED CANINE DUE TO NEGLIGENCE EXTRACTION: A CASE REPORT

Eltica Oktavia * Dennis ** Trimurni Abidin **

*Resident of Specialist Program of Conservative Dentistry

** Lecturer of Specialist of Conservative Dentistry

Faculty of Dentistry, University of North Sumatra

Jln. Alumni No.2 Kampus USU Medan 20155

ABSTRACT

An impacted canine is a canine that is prevented from erupting into its normal functional position by bone, tooth or fibrous tissue. Maxillary canine is the second most commonly impacted tooth after the third molar with prevalence 0.8%-5.2%. The word 'negligence' is derived from the Latin word 'nelego' or neglect which means lack of proper care and attention, culpable and carelessness. Avulsion of permanent tooth due to negligence extraction constitutes a dental emergency. Immediate replantation is the best treatment. Tooth avulsion results in attachment damage and pulp necrosis. Although a necrotic pulp itself is not of consequence, the necrotic tissue is extremely susceptible to bacterial contamination. If revascularization does not occur or effective endodontic therapy is not carried out, the pulp space will inevitably become infected. The combination of bacteria in the root canal and cemental damage on the external surface of the root results in an external inflammatory resorption that can be very serious and lead to rapid loss of the tooth. In the case of a closed apex, revascularization is not expected, therefore, endodontic treatment must be initiated 1 to 2 weeks after the tooth is replanted. If quick and correct treatment is provided after injury, the potential for a successful endodontic outcome is very good. This paper presents case of endodontic treatment of iatrogenic avulsed permanent impacted canine due to negligence extraction which was replanted and reposition in 20 year old female patient at Conservative Dentistry Clinic, Faculty of Dentistry, University of Sumatera Utara. The root canal was thoroughly cleaned and shaped, irrigated, and then disinfected with calcium hydroxide. The canal was obturated and receive a permanent restoration. The result obtained is very satisfactory and the tooth remain in good functional status one year after replantation.

Keyword : Iatrogenic avulsion, Endodontic treatment, Negligence extraction, Replantation, Reposition

Introduction

An impacted canine is a canine that is prevented from erupting into its normal functional position by bone, tooth or fibrous tissue.¹Maxillary canine is the second-most frequently impacted tooth after the third molars with prevalence from 0.8-5.2 %. Maxillary canine impaction occurs twice as often in females than in males.^{1,2}The cause of canine impaction can be the result of localized, systemic or genetic factor(s).²The diagnosis and localization of the impacted canine is the most important step in the management of impacted canines based on clinical and radiographic examinations.²

Diagnosis is similar to a jigsaw puzzle—diagnosis cannot be made from a single isolated piece of information. The clinician must systematically gather all of the necessary information to make a “probable” diagnosis. When taking the medical and dental history, the clinician should already be formulating in his or her mind a preliminary but logical diagnosis. The clinical and radiographic examinations confirm the preliminary diagnosis.³

The word ‘negligence’ is derived from the Latin word ‘nelego’ or neglect which means lack of proper care and attention, culpable and carelessness. Negligence is the act of omission or submission of an act that is done by a doctor or a dentist who has not done his job or who has done his job carelessly. Due to the lack of updating knowledge by the professionals, there is an increased risk of malpractice. Dr

Baxter conducted a study on 243 cases and found that most of the dental negligence cases were due to complications due to extraction.⁴

Avulsion is known as complete displacement of tooth from the alveolus.⁵Avulsion of permanent tooth due to negligence extraction constitutes a dental emergency. Immediate replantation is the best treatment. Avulsion often result in pulp necrosis and damage to the cemental protective layer of the root.⁶The clinical strategies are aimed at limiting inflammation as a result of protective layer damage and infection as a result of pulp necrosis.⁷ Choice of treatment is related to the maturity of the root (open or closed apex) and the condition of the periodontal ligament cells.⁸

Prognosis of transplanted tooth depends on the following factors: the condition of the remaining periodontal ligament attached to the extracted tooth, the adaptation of the tooth to the socket, the duration and the method of splinting after transplantation, and the timing of endodontic treatment of the transplanted tooth.⁶

This case report presents successful management of replantation, reposition, and endodontic treatment on iatrogenic avulsed maxillary impacted canine due to negligencetooth extraction.

Case Report

A 20-year-old female patient referred to conservative dentistry clinic, Faculty of Dentistry, University of Sumatera Utara. There was a history of negligence extraction of maxillary canine by co-ass at oral surgeon clinic because he supposed impacted canine was radiks. After inform consent, patient chose replantation and reposition. Tooth replantation and reposition was carried out by rinsing avulsed tooth with saline and all contaminants were removed. Avulsed tooth slowly reimplanted with gentle pressure, reposition tooth without occlusion interference and splinting teeth #15-25 used the wire and composite resin splint and tooth #23 had sutured (Figure 1 & 2).

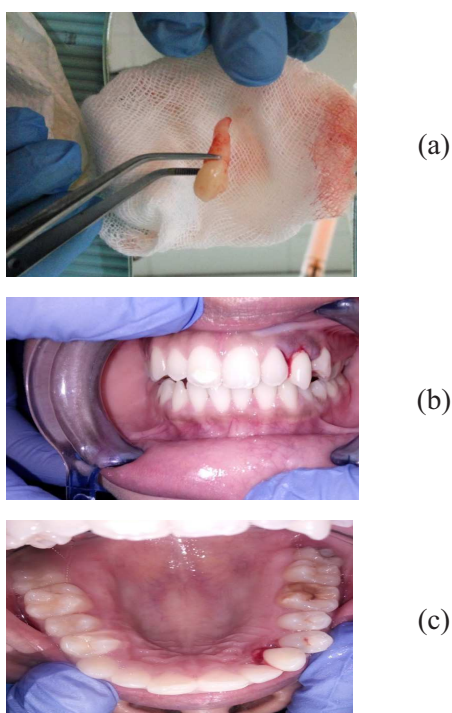


Figure 1. (a) Avulsed tooth before replantation. (b) Replantation and

reposition tooth without occlusion interference in frontal view. (c) Replantation and reposition in occlusal view

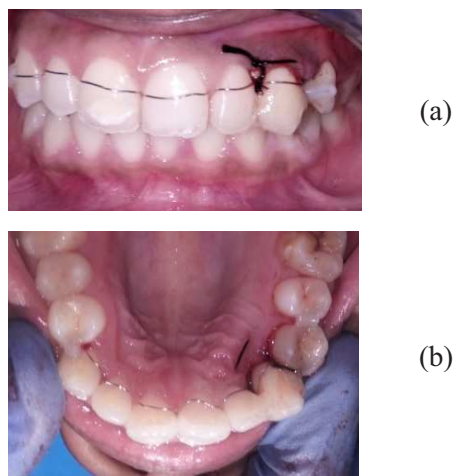
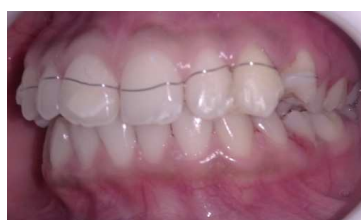
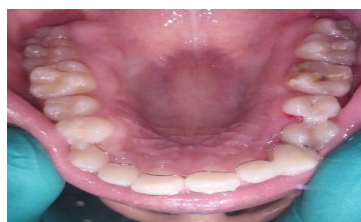
Figure 2. (a) Splinting teeth 15-25 with wire and CR splint and sutured tooth 23 in frontal view. (b) Splinting teeth and sutured tooth #23 in occlusal view

Intraoral examination 10 days later revealed splinting was stable and sutured was removed (Figure 3). Percussion and palpation was negative. Vitality test using Electric Pulp Tester (EPT) was negative. Radiographic examination showed radiolucent along root#23 (Figure 4). Diagnosis of tooth #23 was non vital pulp after replantation. Treatment plan of endodontic treatment was planned because the tooth had a closed apex so revascularization was not possible. The goal of endodontic treatment is prevent or eliminate toxins from the root canal space. The patient was given informations on the procedure to be performed and she signed the informed consent.



(a)



(b)

Figure 3. (a) Preoperative intraoral 10 days later in frontal view. (b) Preoperative intraoral 10 days later in occlusal view

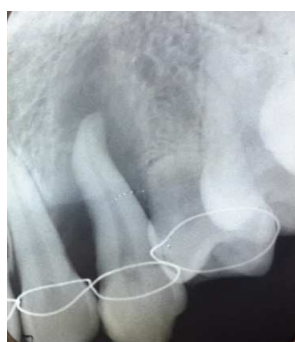
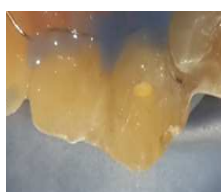
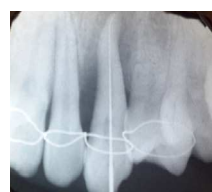Figure 4. Radiographic examination showed radiolucent along root #23.

Endodontic treatment was performed. Tooth was isolated with rubber dam, then open access (Figure 5a). The root canal was negotiated with K-file No. 15 and the working length was determined with an electronic apex locator (Raypex 6, VDW) and was confirmed radiographically with K-file No.25 (Figure 5b).



(a)



(b)

Figure 5.(a) Open access. (b) Working length determination

The root canal was chemo-mechanically prepared with a rotary NiTi instrument (iRace, FKG Dentaire) from 15/.06 to 35/.04 file with crown down technique, irrigated with copious 2.5% sodium hypochlorite, and then dried with sterile paper points. Intracanal medicament $\text{Ca}(\text{OH})_2$ (Viopaste, Spident) was placed for two week and the cavity was sealed with temporary filling (Fuji I, GC Corp).

Two weeks later, tooth #23 was asymptomatic. The canal was thoroughly irrigated with copious 2.5% sodium hypochlorite, saline, and 17% EDTA solution. The canal was dried with paper points, then Master Apical Cone was determined (Figure 6a). Canal was obturated with a resin-based sealer (AH Plus, Dentsply) and using lateral condensation technique (Figure 6b). Take the radiographs to assess the quality of obturation. Place resin modified glass ionomer cement as a protective seal over the GP. It was restored with direct composite resin (Filtek Z350 XT, 3M) (Figure 7).

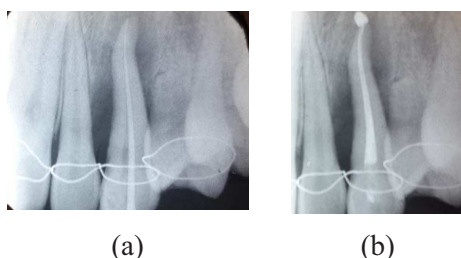


Figure 6. (a) Master Apical Cone determination. (b) Canal was obturated with a resin-based sealer (AH Plus, Dentsply) and using lateral condensation technique.

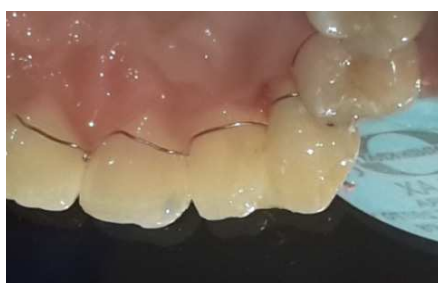

Figure 7. Restoration composite resin

Follow up 1 month later after endodontic treatment showed a remarkable enhancement of bone density in 1/3 apical root (Figure 8a) and probing depth was 7 mm in all location (Figure 8b).

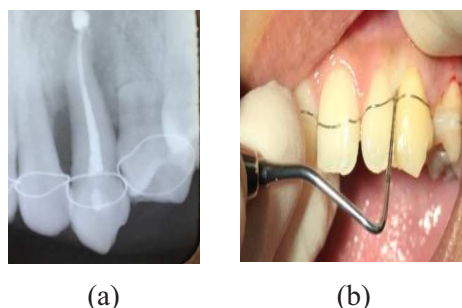


Figure 8. (a) Follow up 1 month later after endodontic treatment showed a remarkable enhancement of bone density in 1/3 apical root. (b) probing depth was 7 mm.

Two month later, regenerative periodontal treatment with Freeze Dried Bone Xenograft (FDBX) and absorbable membrane was done by periodontist. Sutured was removed after 1 week (Figure 9).

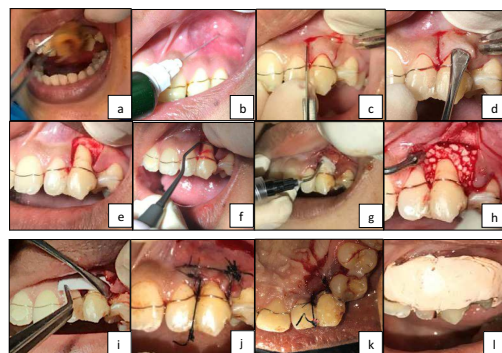


Figure 9. Procedure of regenerative periodontal treatment : (a) Asepsis (b) Local anaesthesia (c) Full thickness mucoperiosteal flap (d) retraction of flap (e) Clinical view showed a remarkable enhancement of bone density in 1/3 apical root (f) Curettage and debridement (g) Root conditioning (h) Bone grafting (i) Absorbable membrane was placed (j) Sutures were placed (frontal view) (k) Sutures were placed (occlusal view) (l) COE pack surgical dressing

Follow up was performed every 1 month, 3 months, 6 month and 1 year after regenerative periodontal treatment. A radiographic image was taken each time follow up and showed a remarkable enhancement of bone density around the avulsed tooth (Figure 10). Splinting was removed after 6 month regenerative periodontal treatment.

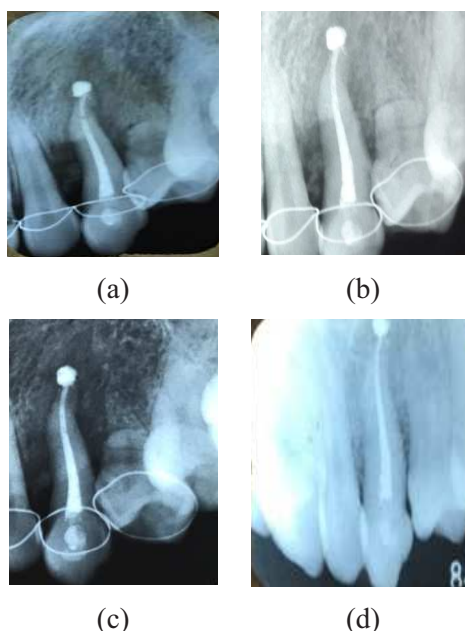


Figure 10. (a) Follow up after 1month, (b) 3month,(c) 6month and (d) 1 year after regenerative periodontal treatment

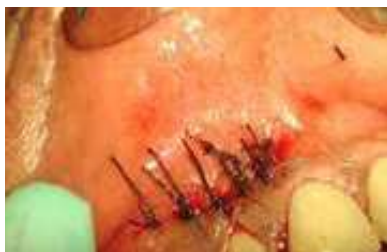

Figure 11. Intraoral view 1 year follow up

Discussion

Mistakes occur in every profession, as it does in life. It is probably every individual's duty to avoid errors and foresee the potential for mistake but, on occasions, it simply may become unavoidable. Unfortunately, in the health profession mistakes could result in serious consequences for the patient and, in turn, lead to the doctor/dentist being made answerable. Dentist should be well

qualified to diagnose and treat patients that are related to his field and refer the patient when necessary. Following examination, the dentist should carefully decide what line of treatment to adopt. The radiograph is one of the most important tools in making a diagnosis.⁴

Avulsion often result in pulp necrosis and damage to the cemental protective layer of the root.⁶ The clinical strategies are aimed at limiting inflammation as a result of protective layer damage and infection as a result of pulp necrosis.⁷ Choice of treatment is related to the maturity of the root (open or closed apex) and the condition of the periodontal ligament cells.⁸ Andreasen et al. concluded in their studies about the most significant factors in PDL healing were the stage of root development, the length of extra alveolar dry storage, the length of wet storage, and recommended immediate replantation where possible.⁹ The time outside of the socket for an avulsed tooth is the most critical factor its survival.^{8,10} A dry time of less than 15 to 20 minutes is considered optimal, where periodontal healing would be expected.^{6,8} In the ideal situation, one would hope PDL cells on the root surface to differentiate into cementoblasts and induce dentine formation, whereas PDL cells on the side of bony socket wall surface to differentiate into osteoblasts thus inducing bone formation. Genetically the PDL cells can differentiate into fibroblasts, cementoblasts and osteoblasts thus explaining this osteoinducing phenomenon.¹¹

Before replant, the root should be rinsed of debris with water or saline. Investigators found in monkeys that soaking the tooth in doxycycline (1 mg in approximately 20 ml of physiologic saline) for 5 minutes before replantation significantly enhanced complete revascularization. A study found that covering the root with minocycline which attaches to the root for approximately 15 days, further increased the revascularization rate in dogs. Although animal studies do not provide us with a prediction of the rate of revascularization in humans, it is reasonable to expect that the same enhancement of revascularization that occurred in two animal species will occur in humans as well.⁶

The socket should be left undisturbed before replantation and removal of obstacles within the socket to facilitate replacement of the tooth into the socket. It should be lightly aspirated or rinsing with physiological serum if a blood clot is present.^{6,9} If the alveolar bone has collapsed or may interfere with replantation, a blunt instrument should be inserted carefully into the socket in an attempt to reposition the wall.⁶ The replanted tooth should be held in place with a flexible splint made with stainless steel wire and composite resin.⁹ Semirigid (physiologic) fixation for 1 to 2 weeks is recommended.^{6,10} Studies have shown that periodontal and pulpal healing is promoted if the replanted tooth is given a chance for slight motion (allow movement of the tooth), the splinting time is not too long, should have no memory

(so the tooth is not moved during healing), and should not impinge on the gingiva and/or prevent maintenance of oral hygiene in the area.^{6,8} The reason of splinting 6 months in this case because replantation and reposition was done in not actually of its normal position.⁶

Inflammation will be minimised when the transplanted tooth is sealed with tight suturing of the gingival cuff around the tooth to prevent ingress of infective agents.¹¹ Systemic antibiotics (tetracycline, doxycycline, penicillin) given at the time of replantation and prior to endodontic treatment are effective in preventing bacterial invasion of the necrotic pulp and therefore subsequent inflammatory resorption.^{6,9} In addition to stressing to the patient the need for adequate oral hygiene, the use of chlorhexidine rinses for 7 to 10 days are helpful.⁶

In the open apex tooth, all efforts are made to promote revascularization of the pulp, thus avoiding pulp space infection.⁶ If the tooth has a closed apex, revascularization is not possible, all treatment efforts are made to prevent or eliminate toxins from the root canal space.^{6,10} Although a necrotic pulp itself is not of consequence, the necrotic tissue is extremely susceptible to bacterial contamination. If revascularization does not occur or effective endodontic therapy is not carried out, the pulp space will inevitably become infected. The combination of bacteria in the root canal and cemental damage on the external

surface of the root results in an external inflammatory resorption that can be very serious and lead to rapid loss of the tooth within a few weeks or months.^{6,7}

Endodontic treatment must be initiated 1 to 2 weeks after the tooth is replanted and prior to removal of the splint.^{6,10} The interim period of 2 weeks is chosen to minimise trauma to the PDL in the initial reattachment healing phase, yet further delay will increase the chance of complication of inflammatory resorption secondary to pulpal infection.¹¹ Endodontic therapy with an effective interappointment antibacterial agent over a relatively short period (1 to 2 weeks) is sufficient to ensure effective disinfection of the canal.^{6,8} Calcium hydroxide is an effective antibacterial agent and changes the environment in the dentin to a more alkaline pH, which may slow the action of the resorptive cells and promote hard-tissue formation. However, the changing of the calcium hydroxide should be kept to a minimum (not more than every 3 months) because it has a necrotizing effect on the cells attempting to repopulate the damaged root surface. Calcium hydroxide is not the only medicament recommended. The antibiotic-corticosteroid paste, Ledermix (DeNTSPLY [Australia], Melbourne, Australia), is effective in treating inflammatory root resorption by inhibiting the spread of dentinoclasts without damaging the periodontal ligament; however, its ability to diffuse through human tooth root has been demonstrated,

and its release and diffusion is enhanced when used in combination with calcium hydroxide paste. The tooth should receive a permanent restoration as soon as possible. A post should be avoided if possible. Follow-up evaluations should take place at 3 months, 6 months, and yearly for at least 5 years.^{5,6}

The hydrated periodontal ligament cells will maintain their viability, allowing healing with regenerated periodontal ligament cells when replanted without causing much destructive inflammation.⁷ If excessive drying occurs before replantation, the damaged periodontal ligament cells will elicit a severe inflammatory response over a diffuse area on the root surface.⁶ The slower-moving cementoblasts cannot cover the entire root surface in time, and it is likely that in certain areas, bone will attach directly onto the root surface.⁷ This has been termed osseous replacement or replacement resorption.⁶ Replacement resorption occurs when osteoclasts in contact with the root resorb dentin that is eventually replaced with new bone by osteoblasts. Clinically, the tooth will be immobile and have a high-pitched sound when percussed. Radiographically, there is absence of the lamina dura.⁵ In the case of ankylosis, the crown of the tooth will appear to be in an infraposition.^{5,8,9}

Conclusion

The understanding of the healing process of a transplanted tooth is imperative to its success. The potential complication

of pulp infection in a root that has lost its cemental protective layer makes these injuries potentially catastrophic. Correct emergency and follow-up evaluation, which may include timely endodontic treatment, is critical. Favorable healing after an avulsion injury requires quick emergency intervention followed by evaluation and possible treatment at decisive times during the healing phase.

REFERENCE

1. Nurlian BT, Tata MD, Ena S, et al. Management of The Palatally Ectopic Canine. Oral Health Division 2016; 2:1-2
2. Aslan BI, Neslihan. Clinical Consideration and Management of Impacted Maxillary Canine Teeth. Intech.2015; 21: 1-2
3. Schweitzer JL. The Endodontic Diagnostic Puzzle. Gen Dent 2009: 560-7.
4. Jasuma JR , Rajash VA. Dental Negligence and Its Liabilities in a Nutshell. IJDS 2014; 5(6):84-7
5. Muhammad AH, Nezar W, Azzaldeen A. Replantation of Avulsed Permanent Anterior Teeth: A Case Report. RRJDS; 4(2): 43-5
6. Sigurdsson A, Trope M, Chivian N. The Role of Endodontics After Dental Traumatic Injuries. Mosby 2011; 17:647-52
7. Martin Trope. Avulsion of Permanent Teeth: theory to practice. Dental Traumatology 2011:1-12
8. Andersson L, Andreasen J, et al. Guidelines For The Management Of Traumatic Dental Injuries:2. Avulsion of Permanent Teeth. American Academy Of Pediatric Dentistry 2013: 333-8
9. Ilnes K, Nabiha D. Delayed Tooth Replantation After Traumatic Avulsion Resulting In Complete Root Resorption. JPD 2016;1(4):18-23
10. Sigurdsson A. The Treatment of Traumatic Dental Injuries. AAE 2014:2-7
11. Eddie CK YAU. Tooth Autotransplantation as A Treatment Option. Medical Diary 2009; 6(14): 21-2

APEXIFICATION USING MINERAL TRIOXIDE AGGREGATE AND COMPOSITE CROWN RESTORATION WITH FIBER REINFORCED CUSTOMIZED DOWEL CORE ON LEFT CENTRAL INCISOR MAXILLA

Erlita Hapsari*; Diatri Nari Ratih**

*) Conservative Dentistry Resident, Faculty of Dentistry,
Gadjah Mada University;

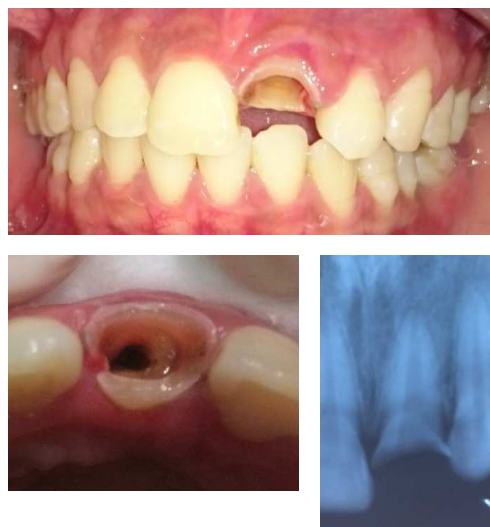**) Staff of Conservative Dentistry Departement, Faculty of Dentistry,
Gadjah Mada University

ABSTRACT

Background: Fracture or traumatic injuries on immature permanent tooth often results in pulp necrosis and arrest of root development and causes an open root apex on the tooth. Apexification is a nonsurgical method of inducing a calcific barrier at the open root apex of the nonvital tooth. Mineral trioxide aggregate (MTA) is a biocompatible material used as an apical barrier for a tooth with immature apices. The treated tooth has a short root, wide root canal and there only left 1-2 mm corona from cervical, this treated tooth need the right choice of final restorations. **Purpose:** This case report was presented to show the success of apexification using MTA and the right choice of final restorations using composite crown restoration with fiber reinforced customized dowel core. **Case Management:** Root canal was prepared biomechanically using a conventional technique, has given an intracanal medicament of calcium hydroxide for one week. The next week was an application of MTA on the open root apex of the nonvital tooth. Two weeks after apical closure with MTA, the teeth were restored using composite crown with fiber reinforced customized dowel core due to the great loss of intracoronal hard tissue. This restoration is to create a 'monobloc' restoration. **Conclusion:** MTA showed a good result for apical barrier formation. Final restoration of a composite crown with fiber reinforced customized dowel core is the right choice of restoration for this case to compensate the great lost of hard tissue with the only left of hard tissue.

Keywords: apexification, mineral trioxide aggregate, composite crown restoration, fiber customized dowel core.

A common cause for the interruption of root development is trauma. However, the majority of injuries occur in young individuals when the root development is incomplete (1). The rehabilitation of dental structure lost by trauma or caries requires an adequate planning based on the clinical situation. The restoration of endodontically treated and severely damaged teeth has been a concern of the clinicians and the researchers still seek an adequate technique and material to restore these teeth.

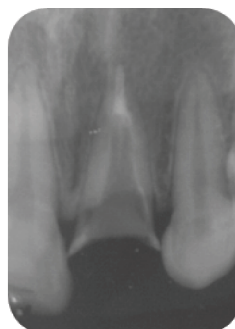


CASE

22-years old female patient presented to conservation clinic of RSGM Prof Soedomo Dentistry Faculty of Gadjah Mada University to check her upper right anterior tooth (tooth 21) which had fractured to the cervical of the crown. The tooth had been treated by a dentist and used immediate prosthesis. Clinical examination on tooth 11 showed class IV Ellis fracture with a large opened root canal. Radiographic examination showed a wide open apex and root canal. The investigation revealed a trauma (12 years ago) on the upper front tooth but 7-years later the crown was to the cervical crown. The patient then went to the dentist and received immediate prosthesis to replace crown of tooth 21. At present time the tooth felt uncomfortable, the patient go to RSGM and then referred to Conservation Clinic.

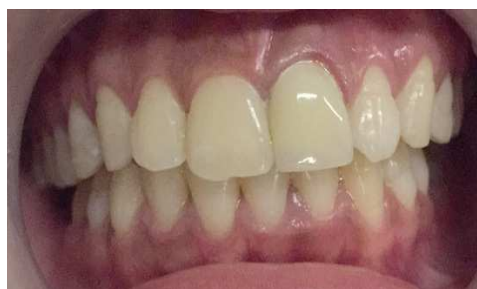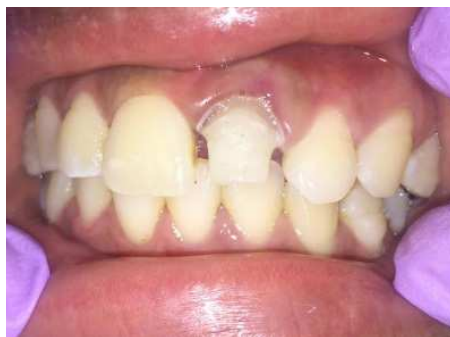CASE MANAGEMENT

At the first visit patient subjected to subjective, objective and radiographic examination. Preparation of treatment planning and then treatment planning is delivered to the patient. During the second visit the root canal treatment using conventional methods and then performed a dressing with calcium hydroxide. One week later an MTA application was performed on the root canal apex as thick as 2-3 mm. Then the cavity was given a damp cotton swab and cursed with temporary filling. Two days later control of the apices of the teeth 21, subjective and objective examination showed good results.



The next visit is done making for the manufacture of fiber costom dowel post. The root cannal is mold using 0.4 mm wire covered with inlay wax and mold to the bottom of the root cannal. The dentition part is molded using alginate, the wire-inlay wax mold is taken out along with alginate mold, then the negative mold is filled with a double impression material to form a positive print of putty. Putty mold are sent to the dental technique laboratory to be made the composite post/ fiber post customized dowel.

The next visit, a custom dowel fiber post inserted into the patient's root canal for adjustment, after adjustment showed good results, then cemented with cement resin (*Rely X U-200, 3M*). Performed core preparation of the post then done by double impression molding. The double impression mold result is sent to the dental technic laboratory to make the composite crown. After the composite jacket crown is finished, the next visit is inserted the composite crown and done cementation using resin cement (*Rely X U-200, 3M*). Control was performed after 6 months later, the results showed good results.



DISCUSSION

The traditional use of calcium hydroxide apical barriers has been associated with unpredictable apical closure, time taken for barrier formation, patient compliance, risks of re-infection resulting from the difficulty in creating long term seals with provisional restorations and susceptibility to root fractures arising from the presence of thin roots or prolonged exposure of the root dentin to $\text{Ca}(\text{OH})_2$ (2). MTA has been described as a good material for this procedure owing to its good canal sealing property, biocompatibility and ability to promote dental pulp and periradicular tissue regeneration. It has been reported that MTA root fillings placed at the cemental canal limit showed better results than overfillings. This report demonstrates the use of MTA apical plug in immature open apex where, an apical matrix was inadvertently created by calcium hydroxide use.

Customized fiber posts that are well adjusted into the root canal and have mechanical properties similar to those of dentin may be a suitable treatment for severely compromised endodontically treated teeth. Customized posts can be

affected by the volume of core, the dentin bonding area on the coronal portion of the posts, and the size of the canal. The strength of the customized post is directly proportional to the amount of fiber and composite at the coronal portion of the posts. On widened post-space preparations in severely compromised roots, a customized post may present a better clinical result, mainly because flared canals allow the placement of more fiber and more composite compared with the narrow canals (4).

4. Newman MP, Yaman P, Dennison J, Rafter M, Billy E. Fracture resistance of endodontically treated teeth restored with composite posts. *J Prosth Dent*. 2003;89:360–367.
5. Gangamwar N., Chandak, M., Nikhade, P., Ikhar, A., Kela, S., Chandak, R., Apexification with MTA placement – case report, *IOSR-JDMS*, 2015, 14 (10): 70-73.

DAFTAR PUSTAKA

1. Andreason, J.O., Andreason, F.M., *Luxation Injuries in Textbook and the Color Atlas of Traumatic Dental Injuries to The Teeth*. Third edition. Munksgaard. Chapter 9. 315-378.
2. Abu-Hussein, M., Abdulghani, A., Abu-Shilabayeh, A., Mineral Trioxide Agregate (MTA) in Apexification. *Endodontology*, 2013, 2 (2): 97-101.
3. Da Costa, R, G., De Morais, E. C. C., Leao, M. P., Bindo, M. J. F., Campos, E. A., Correr, G.M., Three-Year Follow Up of Customized Glass Fiber Esthetic Posts, *Eur J Dent.*, 2011, 5 (1): 107-112.

DILACERATED ROOT CANAL TREATMENT USING HYFLEX CM ROTARY FILES

Erliyana¹, Endang Suprastiwi²

¹ Resident, Department of Conservative Dentistry, Faculty of Dentistry,
Universitas Indonesia

² Professor, Department of Conservative Dentistry, Faculty of Dentistry,
Universitas Indonesia

E-mail address: erliyamin@gmail.com

ABSTRACT

This case report aims to provide an alternative procedure in completing endodontic treatment at a dilated root. To avoid the occurrence of iatrogenic errors, it is important for the dentist to determine the degree of curvature of the root canal, before making any action, and to choose the right instrument for the management of the curved root preparation and perform the correct instrumentation techniques. The end result of endodontic treatment of a curved root canal is depends heavily on the flexibility of the instrument, diameter of the instrument, and the instrumentation technique. In this case report, the first step was to measure the degree of curvature at the distal root using Schneider method. It was done before performing any endodontic treatment. The root canal preparation uses a combination of K-file Iso and rotary Hyflex CM instruments. K-file Iso instrument used was a small sized file and 3mm from the the tip was pre-curved 45° first. The preparation result was good and the curvature of the root remain intact. Then on the following visit, the radiographic images showed signs of healing.

Key Words: dilaceration, curved root, schneider methods, pre-curved file, hyflex cm

INTRODUCTION

The root canal morphology is not always as straight and simple as it appears on the radiographs. Various curves are present along the length of the canal and in all regions of the oral cavity. Dental root variations can occur both from the number and shape of the roots.[1]

The term dilaceration was first used by Tomes in 1848, and it is defined as a deviation or bend in the linear relationship

of a crown of a tooth to its root (Latin: dilacero = tear up). According to this definition, dilaceration is thus distinguished from the rarely used term flexion, which is defined as a tooth with a hooked or a bent root. A tooth is considered to have a dilaceration toward the mesial or distal direction if there is a 90-degree angle or greater along the axis of the tooth or root, whereas others defined dilaceration as a deviation from the normal axis of the tooth

of 20 degrees or more in the apical part of the root.[2]

These curved canals may also restrict the mechanical and chemical preparation of the curvature or may lead to some iatrogenic damage affecting the prognosis of the endodontics treatment, particularly in its apical third, resulting in errors like ledge, elbow or zipping of the canal.[3][4]

To avoid occurrence of such errors, before initiation of treatment, clinician shall make an estimate about the degree of curvature of canals by seeing the radiograph. Also, it is also important to choose the correct instruments and instrumentation techniques as the final outcome of endodontic treatment in curved canals depends largely on the flexibility of the instruments used, diameter of the instrument, and technique of the instrumentation.[6], [7]

CASE REPORT

A 34-year-old female patient was came to Klinik Konservasi Gigi Universitas Indonesia, complaining with pain at her lower left back tooth when used for chewing since a week ago. The teeth had once been patched, but the patch was broken few months ago. Patients have no history of systemic disease.

Clinical examination showed occlusal caries in 38th tooth, negative vitality test, and were tender on percussion. (Figure 1a). Radiographic examination showed that caries already reached the pulp, visible radiolucent with unclear borders and

widening of lamina dura in periapical. In the apical third the distal root appears as a sharp curve toward the distal (Fig. 1b). Based on anamnesis, clinical examination and radiographic examination of the 38th molar tooth then the diagnosis of this case is a chronic apical abscess et causa necrosis of the pulp.

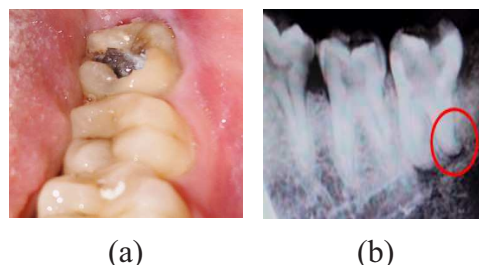


Figure 1. (a) Preoperative clinical picture, (b) Radiographic diagnostic picture.

CLINICAL APPROACH

Prior to initiation of endodontic treatment, the first step was determine the degree of curvature at the distal root using the Schneider method. The results of the calculation of the root dilatation was 95° , which means that the dilatation of the tooth is very (extreme) directed to distal area. After obtaining the degree of curvature of the root canal, the next step was the selection of instruments that will be used for the preparation of the root canal later. ProTaper XS hand use were used for widening the orifices (preflaring). Glide path was done using ISO file #06, and ISO number #06 to #10 were used for initial manual preparation. After that, Hyflex CM files number #15/0.04, #20/0.04, #25/0.04, and #20/0.06 were used to finish the task.

At the first visit an access opening was performed by removing the caries and necrotic tissue in the pulp chamber using a round diamond bur, and dental loupe with 3.5x magnification was used as a visualization aid. Then the orifices search were done using a straight dental probe. Two orifices were found namely mesial and distal. After that orifices enlargement (preflaring) were done using Protapper XS Hand Use. The root canal paths were determined using K-file ISO #06 on the mesial and distal root canals (Figure 2a). Then a measurement of the working length was confirmed using a radiograph. The working length for mesial root was 19 mm and for distal root was 22 mm.

After obtaining the working length, mesial and distal root canals cleaning were done using K-file ISO (Mani, Inc, Japan) starting from file #06. This file #06 was the initial file to start root canal preparation, because it can fit in along the working length. For distal roots, the file was pre-curved by 45° approximately 3 mm from the tip of the file. Then the file was inserted into the root canal, and easily following the curvature of the root canal until it reaches the working length. The subsequent preparation was done using file #08, and for distal root the file was also pre-curved by 45° approximately 3 mm from the tip of the file. The next step was done using file #10, but for the distal root the file was too rigid to achieve the working length. If the preparation using file #10 was continued, it could lead to ledge or perforation.

Therefore the preparation process on the distal root canal was repeated using a more flexible file #08, until the root canal became wide enough to be continued using the smallest size of Hyflex CM (#15/0.04). Initial root canal preparation in this case was done using a small size ISO file with filling motion. Each replacement or change of preparation tool, the root canals were irrigated by following standardized irrigation solution using sodium hypochlorite (NaOCl) 2.5%. After that root canal preparation was continued by using Hyflex CM rotary instrument starting from file #15 with taper 0.04, followed by file #20 with taper 0.04, file #25 taper 0.04, and the last was file #20 with taper 0.06. The preparation technique used was single length technic, which mean all files of the instrumentation sequence should be used to the full length of the working length.

Each replacement or change of file size, the pulp chamber was irrigated by following standardized irrigation solution using sodium hypochlorite (NaOCl) 2.5% and recapitulated with the initial file or one smaller number. After preparation was completed, a Master Apical Cone (MAC) was inserted and photographed, using a single cone gutta percha from Hyflex CM #20 taper 0.06 (figure 2b). Then the root canal was rinsed using a saline solution, after that the root canal was flooded with 17% EDTA and activated by endoactivator for approximately 20 seconds. Then the root canal was rinse again using a saline solution.

The root canal was medicated using a cotton pellet, dripped with ChKM and squeezed dry, and placed in the pulp chamber and then covered with a temporary filling material (Cavit) for a week.

In the next visit, patient were tested; percussion test negative, palpation test negative and no subjective complaints from patient. After that, the temporary filling material was taken out, the root canal was cleaned and rinsed with saline solution and dried with papper points. Furthermore, the root canal was filled using gutta percha from Hyflex CM #20 tapper 0.06, using a lateral condensation technique with MTA Filapex sealer on both root canals (figure 2c). The bottom of cavity was covered with RMGIC (Resin Modified Glass Ionomer Cement) as a base material . Patients were asked to return one week after root canal filling for control and fixed restoration post endodontic treatment.

On subsequent visit, patient was examined (one week after post root canal filling); percussion test negative, palpation test negative and no subjective complaints from patient. Radiographic signs of healing were seen in periapical with radiolucent images become slightly more opaque (figure 2d). After that, restoration after endodontic treatment was made. Due to the patient's schedule, only two days left from the schedule to return to her hometown, it was decided to restore the tooth using temporary direct composite onlay. Then patient was advised after arriving at her hometown, to immediately go to the dentist

and replace the temporary direct composite onlay with permanent indirect onlay (Figure 2e).

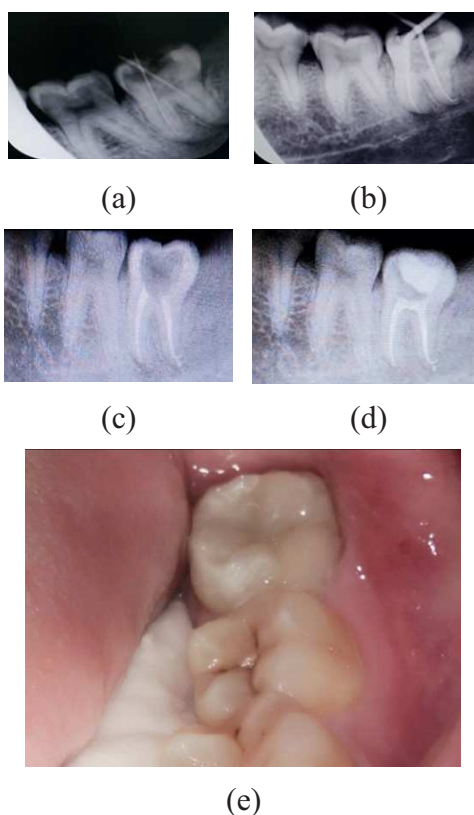


Figure 2. (a) Radiographic image of root canal glide path, (b) Radiographic image of master apical cone, (c) Radiographic image of root canal filling, (d) Radiographic image of follow up visit control, (e) Clinical image of direct composite onlay restoration

DISCUSSION

In this case report, there was a dilaceration at distal root in radiographic image of the third molar tooth that the patient complained about. Before starting endodontic treatment, it was ascertained the degree of root curvature of the tooth to be treated, as this was closely related

to the selection of the instruments to be used. In the case presented we have followed Schneider method of curvature determination, because of its simplicity and wide acceptance. The curvature was categorized as straight if the degree of curvature was $\leq 5^\circ$, categorized as moderate if the degree of curvature was 10° - 20° and categorized as severe or extreme if the degree of curvature was $\geq 25^\circ$. [5] The result of calculation of distal root curvature in this case was 95° , which means the root curvature of the tooth was categorized as severe or extreme to distal direction.

The widening of the orifices (pre-flaring) was done using ProTapper XS Hand Use until reach the middle thirds of the working length. The purpose of pre-flaring was to make sure that the file can easily inserted into the root canal, and irrigation on debris materials can flushed out easily. The use of ProTapper XS Hand Use for pre-flaring in this case was possible because root canal curvature was on apical third. [6]

Initially, the plan were using combined instruments of ISO files #0.6 - #10 and Hyflex CM #15 - #20. But in implementation, when preparation was conducted using ISO file #10, it was not able to follow the anatomy of root canal curvature. If the preparation was continued using ISO file #10, it might causing ledge or perforation. Therefore the root canal preparation was taken back one step by using a more flexible ISO file #08, until the root canal became wide enough to

be continued using the smallest sized file Hyflex CM (#15 / 0.04). In the early stage of preparation for this case, ISO file instruments with a small size were selected because according to Sakkir et al. (2014) [4] it was said that ISO file under size #15 were quite flexible and can be used for manual preparation of curved root canals. This was also confirmed by Gupta et al in 2016. [1] While the reason for choosing Hyflex CM because based on the results of studies conducted by Pongione et al. (2012) [8], Saber et al. (2014) [9], and Capar et al. (2014) [10], Hyflex CM had better physical properties when compared to other files. Few Hyflex CM physical properties were: has excellent fatigue resistance, very flexible, can be used many times, and has a controlled memory system. By having good fatigue resistance, it was expected that the file will not be broken when used on the curved root canal.

The irrigation material used in this case report were 2.5% sodium hypochlorite solution (NaOCl) 2,5% and ethylenediaminetetraacetate solution (EDTA) 17% as both were considered to be effective as a disinfectant and as solvent for organic and inorganic tissues.

The sealer material used in this case report was MTA Filapex, because it have good seal, binds to dentinal tubules, biocompatible, antibacterial, and have a good flow. And in a case of curved root canals, good flow was considered as a very important physical property.

The obturation technique used in this case was lateral condensation, using a single cone gutta percha from Hyflex CM of size #20 / 0.06 and added with a gutta percha accessory. At the apical third gutta percha cone can fill the root canal completely, but at middle third of root canal still had empty space, so it was filled with gutta percha accessory from ISO. However, in a case like this, it would be more effective if the root canal filling was done using Thermafil technique.

CONCLUSION

In this case of dilacerated root canal treatment, with the diagnosis of chronic apical abscess et causa necrosis of the pulp, a successful root canal treatment has been performed after preparation using the Hyflex CM instruments and obturation with lateral condensation techniques. The evident for successful treatment was the presence of sign of healing in periapical area shown in radiographic images where radiolucent spectrum in periapical area become slightly more opaque during post-obturation recall.

REFERENCES

- [1] F. L. Calberson, R. J. De Moor, and C. A. Deroose, "The Radix Entomolaris and Paramolaris : Clinical Approach in Endodontics," vol. 33, no. 1, pp. 58–63, 2007.
- [2] "Management of Dilacerated and S-shaped Root Canals - An Endodontist ' s Challenge," vol. 8, no. 6, pp. 22–25, 2014.
- [3] A. Gupta and P. Kabra, "Endodontic Management of Dilaceratd Roots : A Case Series," vol. 5, no. 3, pp. 2014–2017, 2016.
- [4] H. Jafarzadeh and P. V. Abbott, "Dilaceration: Review of an Endodontic Challenge," *J. Endod.*, vol. 33, no. 9, pp. 1025–1030, 2007.
- [5] P. Balani, F. Niazi, and H. Rashid, "A brief review of the methods used to determine the curvature of root canals," pp. 57–63, 2015.
- [6] "Managing curved canals," vol. 3, no. 2, pp. 2–6, 2012.
- [7] T. S. Kumar, M. Kiran, P. Tripathi, and S. Murthy, "REVIEW ARTICLE INSTRUMENTATION OF CURVED CANALS : A REVIEW," vol. 2, no. 8, pp. 875–891, 2013.
- [8] G. Pongione *et al.*, "Flexibility and resistance to cyclic fatigue of endodontic instruments made with different nickel-titanium alloys : a comparative test Corresponding author ;," pp. 119–122.
- [9] S. E. D. M. Saber and M. M. Nagy, "Comparative evaluation of the shaping ability of ProTaper Next , iRaCe and Hyflex CM rotary NiTi files in severely curved root canals," pp. 1–6, 2014.
- [10] I. D. Capar, H. Ertas, and H. A. Dds, "Comparison of cyclic fatigue resistance of novel nickel-titanium," pp. 1–5, 2014.

CASE REPORT

MANAGEMENT OF C-SHAPE CANALS : TWO CASE REPORT

Gary Wijaya* Trimurni Abidin**

*Resident , Department of Conservative Dentistry.

**Profesor of endodontic at Department of Conservative Dentistry.
Faculty of Dentistry, University of Sumatera Utara.

ABSTRACT :

Thorough knowledge of the root canal morphology is essential for successful endodontic therapy. C-shaped canal configuration is commonly seen in mandibular second molars. These canals are challenging to negotiate, debride and obturate because of the high incidence of anastomoses, lateral canals, and apical deltas. Inability to detect and debride C-shaped canal anatomy can lead to endodontic failure. This case report highlights the management of two different cases of C- shaped canal configurations using thermoplasticised gutta-percha technique and management of associated pulpal floor perforation.

Keywords: C- shaped canal, perforation, thermoplasticised gutta-percha

Introduction

C-shaped canal anatomy was first documented by Cooke and Cox in mandibular second molar (1979)¹. Canal configuration has a high prevalence in mandibular second molars (2.7% - 45.5%)². The main anatomical feature of C-shaped canals is the presence of a fin or web connecting the individual root canals with the orifice may appear as a single ribbon-shaped opening with a 180° arc, linking the two main canals (Gulabivala 2002). Failure of the Hertwig's epithelial sheath to fuse on the buccal side will result in the formation of a lingual groove, and failure to fuse on the lingual would result in a buccal groove. Failure of the sheath to fuse on both the buccal and lingual sides will result in the

formation of a conical root (Manning 1990)³. The C-shaped canal configuration has racial predilection. Higher incidence reported in countries belonging to the Asian continent like Chinese (31.5%) and Koreans (44.5%)^{4,5}.

The first classification of the C-shaped root canals was done by Melton and co-authors in 1991. Later based on it, Fan made an anatomic classification and modified by Zapata in 2009⁶:

1. Category 1 (C1) : an uninterrupted C-shape with no separation or division
2. Category 2 (C2) : the canal shape resembled a semicolon, resulting from a discontinuation of the C-shaped outline, but either angle a

or b should be less than 60° .

3. Category 3 (C3) : two or three separated canals and both angles, a and b, were less than 60° .

4. Category 4 (C4) : only one round or oval canal was present in that cross-section.

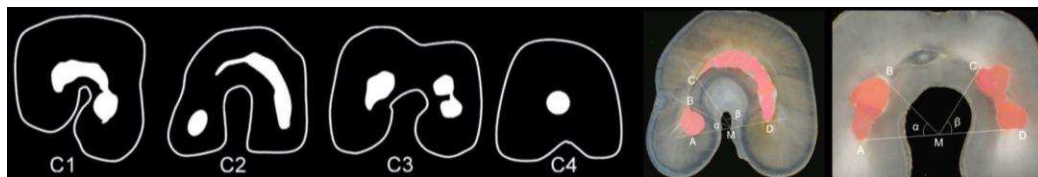


Fig1. Zapata C-shape classification

Fan et al (2004) also classified C-shaped roots according to their radiographic appearance into three types ⁶:

1. Type I : Conical or square root with a vague, radiolucent longitudinal line separating the root into distal and mesial parts. There was a mesial and a distal that merged into one before exiting at the apical foramen (foramina).
2. Type II : Conical or square root with a vague, radiolucent longitudinal line separating the root into distal and mesial parts. There was a mesial and distal canal, and the two canals appeared to continue on their own pathway to the apex.
3. Type III : Conical or square root with a vague, radiolucent longitudinal line separating the canal root into distal and mesial parts. There was a mesial and distal canal, one canal curved to and superimposed on this radiolucent line when running toward the apex, and the other canal appeared to continue on its own pathway to the apex.

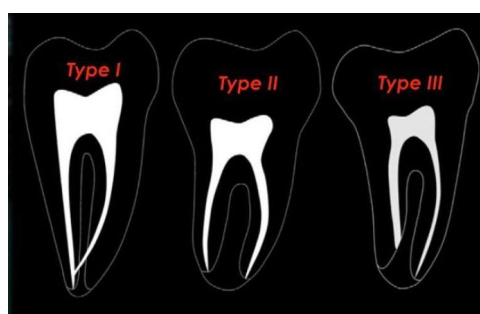


Fig2. Fan C-shape classification by radiographic appearance

Case

Case 1

A 32 year old male Chinese patient reported to the department of Conservative Dentistry FKG USU, a chief complaint of pain in lower right back tooth. Intraoral examination revealed cavity on the occlusal has been closed with temporary filling and dental caries on the distal side of tooth 37 and there was food impaction (Figure 3a). According to the patient, his wisdom tooth operated 6 months ago. Radiographically, a small sign of radiolucency was seen on the distal tooth 37 closely approximating the pulp space (Figure 3b). After proper

isolation and anesthesia, an access cavity was prepared and unable to confirm the category.

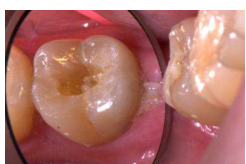

Fig 3a . Pre-op intra oral examination

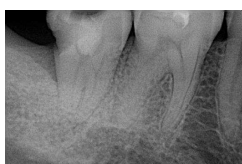

Fig 3b . Pre-op Radiograph

Of c-shape canal (Figure 4a & 4b). Due to the lack of time, artificial wall was made by Glass

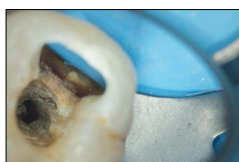

Fig 4a . Access

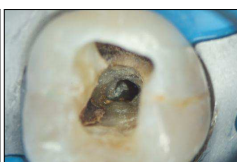

Fig 4b . Proper Isolation

Ionomer Cement on the distal side cavity of the tooth (Figure 5a), followed with confirmation

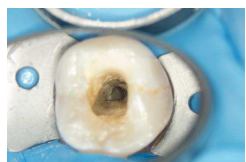

Fig 5a . Artificial wall with GIC

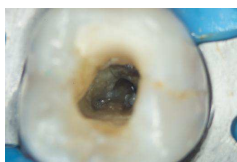

Fig 5b . C3 C-shape classification

C-shape category (Figure 5b) by using Endosonic tips (Satelec; ETBD & ET18) (Figure 6).



Fig 6 . Endosonic tips ETBD & ET18

After working length determination with EAL and confirmed by radiograph (Figure 7), C+file #10 were used to make the glide path, and canals were prepared with Mtwo rotary files (VDW, Munich, Germany) up to #25.06 (Figure 8). 5,25% sodium hypochlorite was used as an endodontic irrigant which was activated with Endo activator and Calcium hydroxide (Ultradent, USA) was placed as an intracanal medicament. After 1 week, the artificial wall with Glass Ionomer Cement was changed to resin composite with circumferential matrix (RealMatrix, Garrison)(Figure 9).

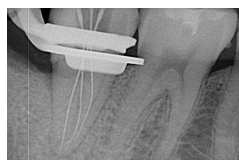


Fig 7. Initial Apical Finding

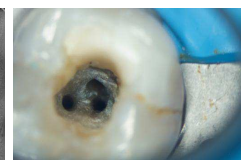


Fig 8. After shaping with Mtwo system

Isolation was made again for proper cleaning procedure with 5,25% sodium hypochlorite, followed with master cone trial, which evaluation done by radiograph (Figure 10) and obturation was completed with continuous wave and thermoplastic injection technique (Element Obturation, SybronEndo)(Figure 11a,11b), AH plus (Dentsply) as the sealer, Orifice

barrier was made by flowable composite and Resin composite (3M filtek 350XT) as the final restoration.

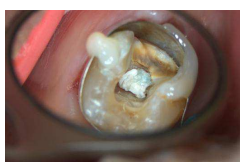

Fig 9. Real Matrix Garrison

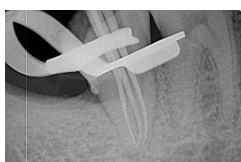


Fig 10. Master Apical Cone

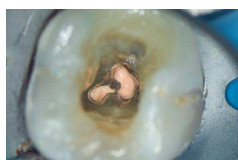

Fig 11a. Clinical view obturation

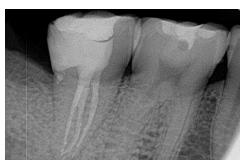

Fig 11b. Radiograph view obturation

Case 2

A 28 year old male Chinese patient was referred to the department of Conservative Dentistry FKG USU, a chief complaint of pain in lower right back tooth, although it had been done some treatment with the referred dentist. Intraoral examination revealed cavity on the occlusal has been closed with Glass Ionomer cement. Radiographically, a small sign of radiolucency was seen on the distal tooth 37 as a suspected iatrogenic error perforation involvement (Figure 12). After the treatment plan has been agreed with the patient, which is to save the tooth no matter what is the consequences. A proper Isolation & anesthesia was performed, Access was made on occlusal of the tooth to locate the orifices, soon the orifice was located, working length was determined

by EAL and confirmed with radiography (Figure 13), perforation involvement was confirmed (Figure 14) and perforation management was performed by closing it with bioactive material, in this particular case Biodentine was used (Figure 15). Shaping was done with mtwo system up to 25.06 (Figure 16). Intra medicament was placed and after 1 week, obturation (Figure. 17) as performed using continuous wave technique follow with thermoplastic injection, AH plus as the sealer and the restoration is done with Resin composite.

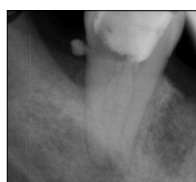

Fig 12. Pre-op radiography

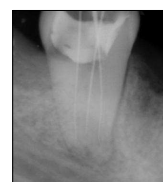


Fig 13. Initial apical finding

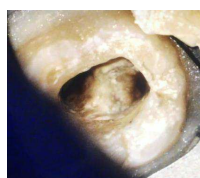

Fig 14. Perforation involment

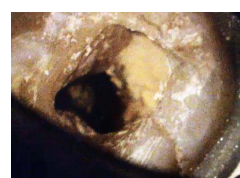

Fig 15. Perforation management using Biodentine

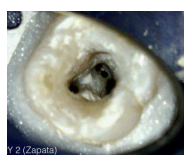

Fig 16. Shaping with Mtwo

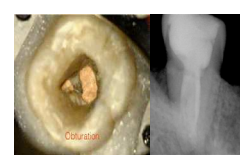

Fig 17. Obturation with Warm Vertical Compaction

Discussion

Clinical cases of a C-shaped pulp

chamber and root canal system show that this root canal aberration occurs in a wide variety and variability with a single root canal up to two, three and four separate root canals. The diameter of the root canal themselves also varies from very wide to such with a small diameter.

In literature have found single publications of cases with a C-shaped canal^{7,9,11}. According to different authors their frequency varies from 2.7% to 8%. The teeth with C-shaped root canal configuration are usually mandibular second molars, and more rarely the mandibular first premolars, the maxillary first molars, as well as the mandibular wisdom-teeth (third molars). The C-shaped configuration of the pulp chamber and the root canal system affects more often Asians than Caucasians¹¹ with frequency of distribution up to 30%. The probability of finding C-shaped configuration in the contralateral tooth is up to 70%^{7,9,11}.

Successful endodontic treatment of a tooth with a C-shaped configuration is difficult and a real challenge considering decontamination and successful filling of the root canal system. The canal instruments, which use, mainly rotating and the processing of an elliptical canal is difficult and inefficient. The creation of systems, with reciprocal motion for machine preparation, is a significant step forward. It is inappropriate to apply separately the standard technique, step-back or crown-down technique for the preparation of a C-shaped root canal. Secure shaping

and cleaning of such type of root canals require knowledge of various techniques for instrumentation and their combination. Qualitative filling of teeth with a C-shaped root canal system only with the methods of the central point technique or cold lateral condensation is impossible. The difficulties arise from the fact that with the C-shaped root canals it is possible to have a thin net of anastomoses in root canal system¹⁰. All this requires good knowledge of and combining different techniques of root canal extension from manual to machine ones. It is important to choose the method of irrigation, because the endodontic space is complicate with net of anastomosis. Ultrasonic activation of the irrigation solution with 2.5 sodium hypochlorite may be advantageous in removing the infected tissues from the canal system, because the volume endodontic contains greater amount of infected channel contents and extrusion of debris or irrigant is possible⁷. Regarding the filling of root canal system one method is not enough to seal the endodontic space. It is necessary to use also cold lateral condensation through combined technique of filling the continuous wave of condensation using Element Obturation¹¹. It is recommended that cases with C-shaped configuration of root canal system should be referred to a specialist for complete treatment.

Conclusion

Due to the unusual root canal system of teeth with a C-shaped root canal system, for successful sealing of endodontic space, it's necessary to know and learn different techniques of filling and appropriate equipment with suitable appliance.

REFERENCES

1. Cooke HG 3rd, Cox FL. C-shaped canal configurations in mandibular molars. *J Am Dent Assoc.* 1979;99:836–9.
2. Weine FS. The C-shaped mandibular second molar: Incidence and other considerations. Members of the Arizona Endodontic Association. *J Endod* 1998;24:372–5.
3. Manning SA. Root canal anatomy of mandibular second molars. Part II: C shaped canals. *Int Endod J.* 1990;23:40–5.
4. Seo MS, Park DS. C-shaped root canals of mandibular second molars in a Korean population: Clinical observation and in vitro analysis. *Int Endod J.* 2004;37:139–44.
5. Zhang R, Wang H, Tian YY, Yu X, Hu T, Dummer PM. Use of cone beam computed tomography to evaluate root and canal morphology of mandibular molars in Chinese individuals. *Int Endod J.* 2011;44:990–9.
6. Janet K., Snezhanka T.P. C-shaped configuration of the root canal system - problems and solutions. *Journal of IMAB*, 2014, vol.20, issue 1.
7. Kirilova J. The cases with rare configurations of root canals of the mandibular second molar. *Problems of dental medicine.* 2009; 35(part II): 73-9.
8. Kuzmanova Y. Prospective application of the clinical and X-ray analysis in endodontics. *Stomatology.* 1998;80(1):63-68.
9. Kuzmanova Y. Rare endodontic variations in the permanent molars in the Bulgarian population. *Dental medicine.* 2014; 96(1):30-41
10. Loh HS. Incidence and features of the mandibular second molar in Singaporean Chinese. *Austr Dent J.* 1991 Dec;36(6):442-44.
11. Manning SA. Root canal anatomy of second molars. Part II. C-shaped canals. *Int Dent J.* 1990 Jan;23(1):40-45.

MANAGEMENT OF ANTERIOR DENTAL TRAUMA (TWO YEARS AFTER TRAUMA) : A CASE REPORT

Hanny Aryani¹, Bernard O. Iskandar², Dina Ratnasari²

¹ Resident at Department of Conservative Dentistry, Faculty of Dentistry, Trisakti University

² Lecturer at Department of Conservative Dentistry, Faculty of Dentistry, Trisakti University

Background

Accidents is one cause of anterior dental trauma. Dental trauma can result in injuries involving the tooth, the supporting structure and leads to esthetic problem, influencing tooth vitality and often tooth discoloration.^{1,2} Root canal treatment performed to preserve remaining tooth structure. Intracoronary bleaching and composite restoration are conservative treatments for esthetic rehabilitation. Conservative treatment which is including minimally invasive procedure is choosed because of sufficient remaining tooth structure for composite restoration, to preserve remaining tooth structure and the advance in dental adhesive techniques. Minimally invasive procedure can save remaining structure from invasive preparation like crown.^{3,4}

Objective

The aim of this case report is to present how to manage of 1/3 coronal fracture teeth 2 years after traumatic injury followed with intracoronary bleaching and composite restoration for esthetic rehabilitation.

Case and management

This case report is present of a 20-year-old male patient with fracture on 1/3 coronal upper front teeth after accident 2 years ago (Fig. 1). Objective assessment showed negative on thermal test, positive on percussion, and normal tooth mobility. Slight darker on tooth 11 (Fig. 2). The radiographic examination showed the absence of lamina dura on apical tooth #11 and #21, periapical radiolucency on tooth #11, #21, external root resorption on tooth 11, no root or bone fractures (Fig. 3). The diagnosis on tooth #11 and 22 based on clinical and radiographic examination was asymptomatic apical periodontitis *et causa* pulp necrosis and requiring root canal treatment.

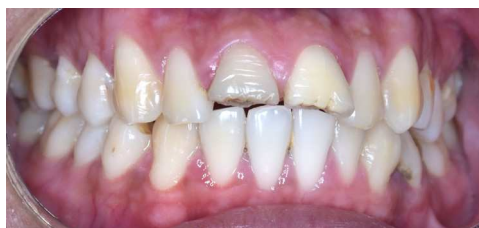

Fig.1. Fracture on 1/3 coronal upper front teeth after accident.

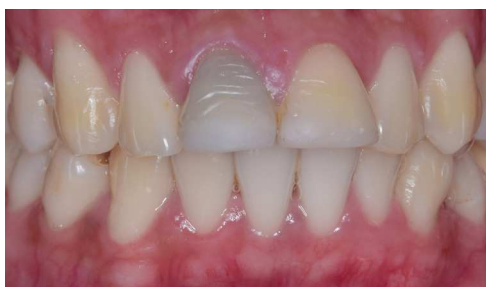

Fig 2. Slight darker on tooth #11

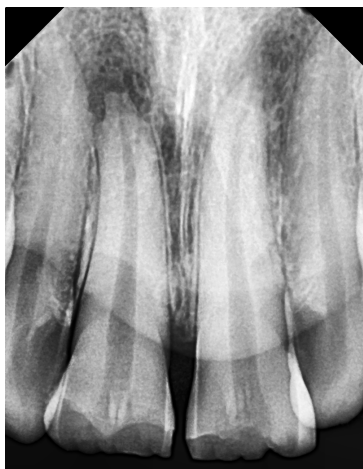

Fig 3. Preoperative radiograph show 1/3 coronal fracture, extending to pulp chamber, the loss of lamina dura on apical tooth #11, #21, periapical radiolucency tooth #11, #21.

On first appointment, composite restoration was performed on tooth 11, 21 before biomechanical preparation for esthetic matters then continued with access opening, followed by isolation of the tooth using rubber dam. Root canal exploration using K-Files (SybronEndo) size #8, #10, #15. Working length was determined using DentaPort ZX II electric apex locator (Morita) and confirmed with radiograph. After establishing glide path with M4 handpiece (SybronEndo) and K-Files (SybronEndo) size #8, #10,

#15, root canal of tooth #11 and #21 were shaped with crown down technique with TF Adaptive (SybronEndo) size ML1 #25/.08, ML2 #35/.06, ML3 #50/.04. In between instrumentation, copious irrigation was done with 2.5% NaOCl and aqdest, and apical patency with K-Files size #10. Calcium hydroxide (Ultracal XS, UltraDent) was used as an intracanal medicament and cavity sealed with temporary restoration (Cavit).

On second appointment, objective assessment showed negative on percussion test, followed by obturation the root canal using warm vertical compaction technique (Fig. 4).

On third appointment, one week later intracoronary bleaching was performed on tooth #11. Wing shaped barrier was made on pulp chamber with resin modified glass ionomer cement (Fig. 5) and whitening performed with in-office bleaching hydrogen peroxide 35% gel (Opalescence Endo, Ultradent). Cavity sealed with double seal fillings using temporary restoration and glass ionomer cement. Instruct the patient to return 5 days later.

Next appointment, tooth #11 color looks like adjacent tooth (Fig. 6), then remove the whitening material from pulp chamber, and pulp chamber rinsed with aqdest and the cavity sealed with temporary material for permanent restoration 2 weeks later.

On last appointment, tooth color stability reached then continuing with final

restoration with resin composite (Ena HRI, Micerium) (Fig. 7).

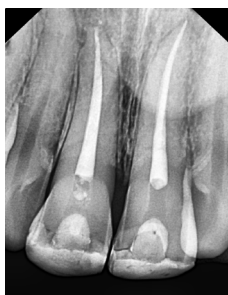

Fig 4. Obturation with warm vertical compaction technique

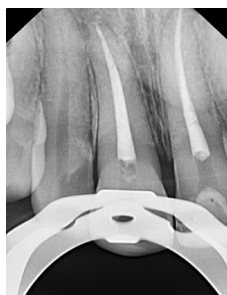

Fig 5. Wing barrier with resin modified glass ionomer cement

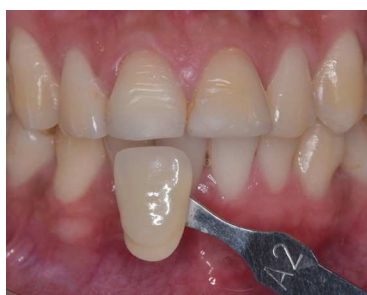

Fig 6. Tooth #11 color same with adjacent tooth

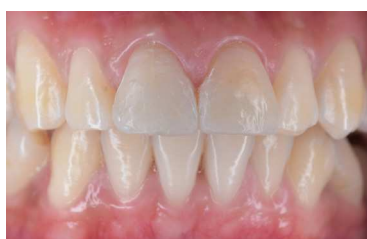

Fig 7. Final restoration with resin composite

Discussion

Loss of tooth structure due to dental trauma can cause intrusion of bacteria through tubuli dentin, causing inflammation of the pulp, and if left untreated causing pulp necrosis and then apical periodontitis.¹The

force of trauma can rupture the capillary vessel and lead to ischemic and tooth become non vital and causing intrapulpal hemorrhage on pulp chamber then diffusion blood component into dentinal tubules. The lysis of erythrocyte will result degradation of hemoglobin into globin and heme containing iron. Bacteria produce hydrogen sulfide. Iron sulfide causing discoloration of dentin.^{1,2}

The management of anterior trauma with non-vital tooth not only related with root canal treatment but we also concern the effect of trauma to esthetic such as tooth discoloration and loss of tooth structure. Nowadays minimal intervention dentistry become popular. This principal is a conservative treatment and focused to restore form, function and esthetics with minimal removal of tooth structure and obtain successful outcome.³ Esthetic rehabilitation on dental trauma can be performed with this procedure but first we have to assess tooth loss severity, this assessment useful to make appropriate treatment plan and to predict the outcome of the treatment. On this case, only 1/3 coronal loss and the remaining tooth structure and sufficient for direct restoration with composite resin. This procedure can save remaining structure from invasive preparation like crown.^{3,4}

Conclusion

Endodontic treatment of 1/3 coronal fracture teeth 2 years after traumatic injury followed with intracoronal bleaching and

composite restoration showed a successful treatment outcome. Minimal intervention dentistry is chosen to minimize extensive preparation of remaining tooth structure and to protect tooth structure from further damage.

References :

1. Trope M., Barnett F., Sigurdsson A, Chivian N. 2016. *The role of endodontics after dental traumatic injuries*. In: Cohen's Pathways of The Pulp. Hargreaves, K.M., Berman, L.H. (editor). 11th Ed. Elsevier, St. Louis, pp.764.
2. Setzer F. 2016. *Bleaching procedur*. In: Cohen's Pathways of The Pulp. Hargreaves, K.M., Berman, L.H. (editor). 11th Ed. Elsevier, St. Louis, pp.e.98.
3. Malterud MI. Minimally invasive restorative dentistry: a biomimetic approach. *Pract Proced Aesthet Dent*. 2006; 18(7):409-414.
4. King PA. Adhesive techniques. *Br Dent J*. 1999; 186(7):321-326.

CASE REPORT

ENDODONTIC TREATMENT OF MAXILLARY LATERAL INCISOR WITH SUSPECTED RADICULAR CYST AND EXTERNAL APICAL ROOT RESORPTION: A CASE REPORT

Hasti Dwi Setiati¹, Endang Suprastiwi²

¹Resident, Department of Conservative Dentistry, Faculty of Dentistry,
Universitas Indonesia

² Lecturer, Department of Conservative Dentistry, Faculty of Dentistry,
Universitas Indonesia

E-mail address: hastidwisetiati@live.com

ABSTRACT

Introduction and objective: Radicular cysts are the most common inflammatory cysts and arise from the epithelial residues in the periodontal ligament as a result of inflammation, following necrosis of the pulp. Cysts arising in this way are found most commonly at the apices of the involved teeth, but may also be found on the lateral aspects of the roots in relation to lateral accessory root canals. Periapical lesion such as cyst can cause apical root resorption.

Case report and conclusion: The case of a radicular cyst combined with external apical root resorption associated to the right maxillary lateral incisor is reported. Nonsurgical root canal therapy was performed, a dressing of calcium hydroxide was applied and replaced two times over a period of 1 month, the open apex was managed by placing an apical plug using mineral trioxide aggregate, and lesion healing was confirmed radiographically after 4 months.

Key Words: endodontic therapy, radicular cyst, apical plug, external periapical resorption

INTRODUCTION

By definition, cyst is a pathologic cavity, lined by epithelium that contains a liquid or semisolid material.¹ Radicular cyst is an inflammatory cyst of the periodontium of a tooth with infected and necrotic pulp.¹ Radicular cysts are the most common cysts of the jaw and comprise about 52% to 68% of all the cysts affecting the human jaws.¹ The prevalence of radicular cysts is highest among patients

in their thirties, higher among males, and more frequent in maxillary anterior region.¹

Radicular cyst is caused by dental caries (bacterial infection) and traumatic injuries.² Radicular cyst develops from a preexisting periapical granuloma³ but not every periapical granuloma will develop into radicular cyst.¹ Radicular cysts are usually asymptomatic and often are discovered during dental radiographic examination³ but some cases may develop

signs and symptoms such as swelling and tooth mobility.⁴

Radicular cyst can be managed by root canal treatment and/or surgical treatment such as enucleation, marsupialization, and decompression.⁴ The choice of treatment depends on site and size of cyst, possibility of damaging adjacent *anatomic structures*, clinical characteristics of the lesion, cooperation, and systemic condition of the patient.⁴

The exact healing mechanism of radicular cyst is not clearly understood.⁵ According to Simon (1980) and Nair et al. (1996) radicular cyst such as pocket cyst is open to the root canal, therefore it is likely to heal after conventional root canal treatment due to the removal of intracanal irritants.^{1,5,6} The pressure from the expanding radicular cyst causes resorption of the surrounding bone and may lead to apical root resorption.⁷

Root resorption is associated with an additional clinical problem through the development of an 'open apex'.⁸ The absence of apical stop may lead to extrusion of root filling materials into the periapical region.⁸ According to Nair et al (1990) and Sjögren et al. (1995) this may in turn initiate a foreign body reaction and possibly induce further root resorption.⁸

Prior to root canal obturation, a treatment must be employed due to the presence of an open apex.⁹ According to Seltzer (1988) the conventional approach to induce apexification is by using calcium

hydroxide following disinfection of the root canals.⁹ Therefore root canal obturation is delayed until root-end closure has been completed through apexification.⁹ The speed of barrier formation varies from 3 to 24 months.⁹ The long exposure of root dentin to calcium hydroxide can decrease dentin's ability to withstand fracture (Andreasen, 2006).⁹ According to Walia et al. (2005) the structure of the formed calcified bridge following apexification was porous.⁹

Given the complexity of apexification using calcium hydroxide, clinicians have frequently sought an alternative treatment protocol.⁹ Recently bioactive material such as mineral trioxide aggregate (MTA) has emerged as a reliable material due to its biocompatibility, sealing ability, and it induces regeneration of periradicular tissues such as periodontal ligament bone and cementum.¹⁰ Hence, this paper will discuss the nonsurgical management of suspect radicular cyst and the management of external apical root resorption.

Case

A 33-year-old male patient reported with a chief complaint of cavity in his upper front tooth. Patient confirmed history of restoration on the same tooth 19 years ago and spontaneous pain but he cannot remember the exact year and the tooth has been accessed endodontically 1 month prior to dental visit.

Clinical examination revealed tooth 12 was temporarily restored and has been

restored with a tooth-colored restoration on mesial, buccal, and distal and tender to vertical percussion.

Periapical radiograph examination of tooth 12 revealed a well-defined radiolucency approximately 6 mm indiameter involving the periapical region of tooth 12, well-defined sclerotic border was present around the radiolucency, and apical root resorption.

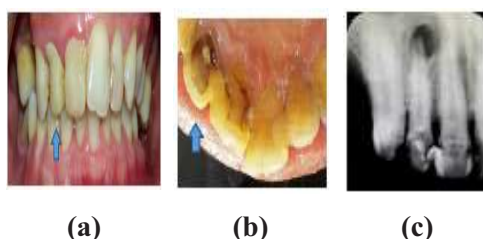


Fig 1.(a) and (b) Preoperative photograph showing tooth 12. (c) Radiograph showing radiolucency involving apex of 12.

Based upon clinical and radiographic findings diagnosis of suspect radicular cyst of tooth 12 was made.Treatment plan comprised of root canal treatment and MTA plug.

Case Management

The distal wall of tooth 12 was built with GIC and the proximal contact of tooth 12 was adjusted. The existing access cavity was enlarged and working length of the tooth was determined with the help of periapical radiograph.

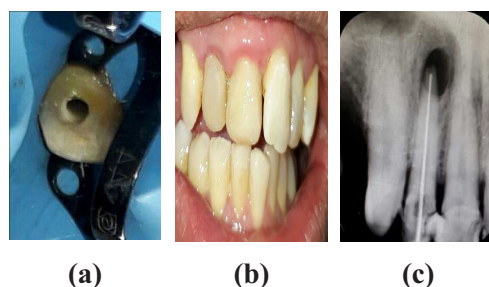


Fig 2. (a)Access cavity of tooth 12. (b) Adjusted proximal contact and distal artificial wall build-up of tooth 12, (c) Radiograph showing verification of working length with initial file

Canals were cleaned and shaped with circumferential filing technique withk-file ISO #55, irrigating with copious amount of 2,5% sodium hypochlorite followed by irrigation with sterile saline solution to remove any remnants of sodium hypochlorite. Canals were also irrigated with EDTA 17% solution. The canal was dried with absorbent paper point and calcium hydroxide was inserted into the root canal space as intracanal medicament followed by temporary restoration for 2 weeks.

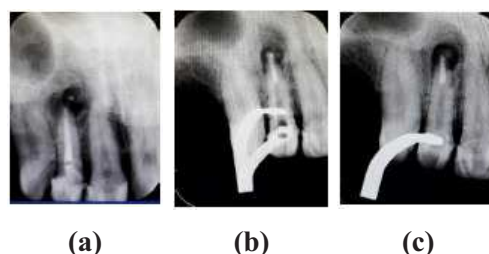


Fig 3. (a) Radiograph showing periapical evaluation and the condition of calcium hydroxide at the second visit. (b) MTA apical plug. (c) Radiograph showing 1 week follow-up post application of MTA plug.

After 2 weeks, radiograph revealed no reduction in the size of periapical radiolucency.

Temporary restorations were removed, canal were irrigated with 2,5% sodium hypochlorite followed by irrigation with sterile saline solution and 17% EDTA solution. Afterwards the canal was dried with absorbent paper point. Calcium hydroxide was inserted into the root canal space and the access cavity was sealed with GIC.

On the third visit (3 weeks after the second visit) clinical examination revealed no tenderness to percussion and no subjective complaints. Radiographic examination revealed the reduction of lesion size. The root canal was cleaned and dried. MTA (MTA Angelus) was manipulated according to manufacture instructions. MTA was placed on the apical root with MTA carrier (MAP System) and was condensed vertically with hand plugger. Afterwards radiographic examination showed dense apical plug 4mm in thickness. Afterwards the orifice was sealed with cotton pellet and temporary restoration.

Follow-up was scheduled for 1 week, 1 month, and 4 months post application of MTA plug. One month follow up showed signs of periapical healing such as the reduction of lesion size and periapical radiolucency. Four months follow-up showed further reduction in periapical radiolucency and lesion size. Furthermore prefabricated fiber post was inserted inside

root canal and composite resin core build-up material was applied. The patient was scheduled for porcelain crown restoration.

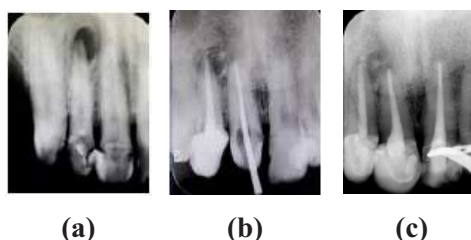


Fig 4.(a)Pre-operative radiograph. (b) Radiograph showing 1 month follow-up post application of MTA plug. (c) Radiograph showing 4 months follow-up post application of MTA plug.

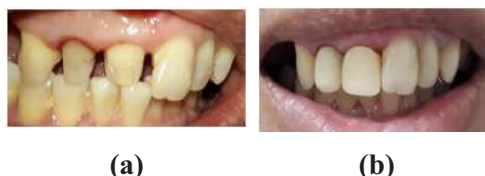

Fig 5.(a) Tooth preparation for porcelain crown. (b) Temporary crown for tooth 12 and 11.

DISCUSSION

In this case, bacterial endotoxins released from the necrotic pulp may initiate the inflammation and immune response and may directly cause epithelial proliferation,⁶ Afterwards the cyst cavity may form within a proliferating epithelial mass in an apical granuloma by degeneration and death of cells in the centre.⁶ Hence, the radicular cyst may be a direct sequel to apical granuloma.¹ The third phase of pathogenesis is osmosis that may contribute in the increasing size of cysts.⁶ Lytic products of the epithelial and inflammatory cells in the cyst cavity provided greater numbers of smaller

molecules which raised the osmotic pressure of the cyst fluid.⁶ As a result, the osmotic pressure of the cyst fluid rises to a level higher than the tissue fluid.¹ The increased intracyst pressure may lead to bone resorption and expansion of the cyst¹ and the pressure from the expanding cyst may contribute to apical root resorption.¹⁴

Although the definitive diagnosis have to be made by histological examination,⁵ however, a preliminary clinical diagnosis of radicular cyst can be made if the lesion at the apex of the nonvital tooth is more than 5 mm in diameter.¹⁵

Radicular cyst can be treated by surgical and/or nonsurgical methods.⁵ Ideally, a nonsurgical method should be initiated, especially in cases where lesions are in close proximity to important anatomical structures.⁵ According to endodontic literature a great majority of cysts heal after nonsurgical root canal therapy, “success rates” of 85% to 90% have been reported.¹ The success of nonsurgical endodontic treatment method is based on appropriate cleaning, shaping, asepsis and filling of the root canal.⁵ The aim of nonsurgical root canal therapy is the elimination of infection from the root canal (necrosis pulp tissue and bacteria).¹

In this case, 2,5% sodium hypochlorite was used because of its antibacterial effect and the ability to dissolve necrotic tissue, and the organic components of dentin and biofilm,¹⁶ 17% EDTA solution to eliminate the mineralized material of the smear layer, EDTA extracts bacterial surface proteins

by combining with metal ions from the cell envelope, which can eventually lead to bacterial death,¹⁶ and calcium hydroxide was used as intracanal medication.¹⁶ Calcium hydroxide has antibacterial action, antiinflammatory activity, neutralizes acid products, activates alkaline phosphatase, and creates favorable conditions for periapical repair and stimulates hard tissue formation.⁵

The absence of natural apical constriction increased the risk of extrusion of the root filling materials.²² Therefore mineral trioxide aggregate (MTA) was used to create artificial apical barrier to prevent root canal overfilling and increase the fracture resistance of immature teeth.²² MTA has the ability to induce cementum-like hard tissue when in contact with periradicular tissue and the sealing ability wasn't affected by the presence of moisture,²² In this case, 4 months follow-up radiographic examination showed the formation of hard tissue structure adjacent to the apical plug.

The exact healing mechanism of radicular cysts heal is not clearly understood.²³ It is suggested that if the calcium hydroxide is confined to the root canal, it is possible that the inflammation created by the diffusion of the calcium hydroxide through the apical foramen may be sufficient to cause break-up of the cystic epithelial lining, thereby allowing a connective tissue invagination into the lesion with ultimate healing.²³

In the healing of radicular cyst such as pocket cyst, the cyst will undergo regression.²⁴ Based on the previously described studies, regression of epithelial strands in periapical granulomas and the lining epithelium of radicular cysts are most likely caused by programmed cell death.²⁴ After endodontic therapy, the restricted-potential basal stem cells in the epithelial strands or lining epithelium of cyst will stop proliferating because of a reduction in inflammatory mediators, proinflammatory cytokines, and growth factors.²⁴ Furthermore, the terminally differentiated squamous cells in the epithelial strands and the lining epithelium of a cyst will die of programmed cell death.²⁴ Eventually, most basal cells will regress or become atrophic through programmed cell death because of deprivation of survival factors or receiving death signals during progressive wound healing of periradicular lesions.²⁴ It is also possible that epithelial cells in epithelial strands and in apical cysts may be biologically similar to autoreactive T lymphocytes and are deleted by programmed cell death.²⁴

At the absence inflammation caused by bacterial infection, the space that has gone through bone resorption because of the expanding lesion are filled with delicate cancellous bone in their apical two thirds at 10 weeks, and they are completely filled with bone at 15 weeks.²⁵ Increased radiopacity is demonstrated as soon as 38 days and radiopacity similar to that of the surrounding bone at 105 days.²⁵ Following

1 month post MTA plug application, the radiograph revealed of the reduction of periapical radiolucency. Furthermore, following 4 months post MTA plug application, the radiograph showed even further reduction of periapical radiolucency and lesion size. Therefore it shows signs of alveolar bone healing.

CONCLUSION

Suspect radicular cyst and external apical root resorption on tooth 12 managed by root canal treatment and application of MTA apical plug. Signs of success based on radiographic examination of 1 and 4 months follow up that revealed reduction in periapical radiolucency and lesion diameter, the appearance of hard tissue barrier adjacent to the MTA apical plug. Clinical examination revealed negative to percussion and palpation and the absence of subjective.

REFERENCES

1. Ingle JJ. *Ingle's Endodontics*. 6th ed. Ontario: BC Decker Inc; 2008.
2. Tak O, Yilmaz S, Ozel E, Kavak M. Five Year Clinical Follow Up of a Patient with Radicular Cyst in the Maxillary Anterior Region. *Eur J Prosthodont*. 2016;4:17-21.
3. Regezi J. *Oral Pathology : Clinical Pathologic Correlations*. 7th ed. St. Louis, Missouri: Saunders Elsevier; 2017.

4. Kr H, Vk V, Deepa C. Radicular cyst : A case report. *Int J Appl Dent Sci.* 2015;1(4):20-22.
5. Bansal R, Khursheed I, Bansal T. Review Article Endodontic Management of a Periapical Cyst- A Review. *J Adv Med Dent Scie Res.* 2013;1(1):7-16.
6. Shear M, Speight P. *Cysts of the Oral and Maxillofacial Regions.* 4th ed. Oxford: Blackwell Publishing; 2007.
7. Garg N, Garg A. *Textbook of Endodontics.* 3rd ed. New Delhi: Jaypee Brothers Medical Publishers; 2014.
8. Abbott PV. Apical inflammatory root resorption : A correlative radiographic and histological assessment Apical inflammatory root resorption : a correlative radiographic and histological assessment. *Int Endod J.* 2000;33:483-493. doi:10.1046/j.1365-2591.2000.00338.x.
9. Torabinejad M. *Mineral Trioxide Aggregate Properties and Clinical Applications.* 1st ed. Iowa: Blackwell Publishing; 2014.
10. Ashwini T, Namrata H, Patil C, V Y. Role of mineral trioxide aggregate in management of external root resorption. *J Conserv Dent.* 2013;16(6):579-581.
11. Aggarwal, V. Singla M. Management of inflammatory root resorption using MTA obturation – a four year follow up. *Br Dent J.* 2010:287-289.
12. Pawar A. Management of a large periapical lesion using Biodentine™ as retrograde restoration with eighteen months evident follow up. *J Conserv Dent.* 2013;16(6):573-575. doi:10.4103/0972-0707.120934.
13. Soundappan S, Sundaramurthy JL, Raghu S, Natanasabapathy V. Biodentine versus Mineral Trioxide Aggregate versus Intermediate Restorative Material for Retrograde Root End Filling: An Invitro Study. *J Dent Tehran Univ Med Sci.* 2014;11(2):143-149.
14. Prein J, Remagen W. *Atlas of Tumors of the Facial Skeleton.* Berlin: Springer-Verlag; 1986.
15. J. Prein, W. Remagen, B. Spiessl EU. *Atlas of Tumours of the Facial Skeleton. Odontogenic and Nonodontogenic Tumours.* Berlin: Springer-Verlag; 1986.
16. Peters OVEA, Peters CI, Basrani B. Cleaning and Shaping the Root Canal System. In: *Cohen's Pathways of the Pulp.* 11th ed. Elsevier Inc.; 2016:209-279. doi:10.1016/B978-0-323-09635-5.00006-3.
17. Murray P. *A Concise Guide to Endodontic Procedures.* Berlin: Springer-Verlag; 2015.
18. Mathew BP. Management of non vital immature teeth – case reports and review. :18-21.
19. Hargreaves K, Cohen S. *The Role of Endodontic After Dental Traumatic*

- Injuries. In: Pathway of The Pulp.*
10th ed. St. Louis, Missouri: Mosby
Elsevier; 2011. doi:10.1016/B978-0-
323-09635-5.00033-6.
20. Mohammadi Z, Dummer PMH. Properties and applications of calcium hydroxide in endodontics and dental traumatology. *Int Endod J.* 2011;(44):697-730. doi:10.1111/j.1365-2591.2011.01886.x.
21. F W. *Endodontic Therapy.* 5th ed. St Louis, Missouri: Mosby; 1996.
22. Pace R, Giuliani V, Nieri M, Nasso L Di, Pagavino G. Mineral Trioxide Aggregate as Apical Plug in Teeth with Necrotic Pulp and Immature Apices : A 10-year Case Series. *J Endod.* 2014;1-5. doi:10.1016/j.joen.2013.12.007.
23. Caliskan MK. Prognosis of large cyst-like periapical lesions following nonsurgical root canal treatment : a clinical review. *Int Endod J.* 2004;37:408-416.
24. Lin LM, T-J Huang G, Rosenberg PA. Proliferation of Epithelial Cell Rests , Formation of Apical Cysts , and Regression of Apical Cysts after Periapical Wound Healing. *J Endo.* 2007;33(8):908-916. doi:10.1016/j.joen.2007.02.006.
25. Pagni G, Pellegrini G, Giannobile W V, G R. Postextraction Alveolar Ridge Preservation : Biological Basis and Treatments. *Int J Dent.* 2012;2012:1-13.

CASE REPORT

MANAGEMENT OF NARROW CANAL ON MAXILLARY RIGHT LATERAL INCISIVUS (A CASE REPORT)

Hendro Santoso Malimas¹, Tien Suwartini², Anastasia E. Prahasti²

¹ Resident at Department of Conservative Dentistry, Faculty of Dentistry,
Trisakti University

² Lecturer at Department of Conservative Dentistry, Faculty of Dentistry,
Trisakti University

Background : Discovering glide path is the key to have a successful cleaning, shaping and filling steps on root canal treatment. It becomes more important on a narrow canal configuration due to calcification which is usually happened on molar teeth. **Objective** : The aim of this case report is to present a successful root canal treatment of maxillary right lateral incisivus. **Case** : A root canal treatment was planned for maxillary right lateral incisivus which was non vital upon pulp testing. Small canal and periapical lesion were detected on radiographic. Access opening was established by small round bur and #08 K-file for locating the canal. After discovering the glide path, cleaning and shaping were performed with crown down technique using protaper universal hand file. The root canal was obturated with warm vertical compaction technique using guttapercha. Coronal seal was established with resin composite as restoration. **Conclusion** : The right management in discovering glide path on narrow root canal will increase successful rate of root canal treatment.

Keyword : root canal treatment, narrow canal, second insisivus

Introduction

Narrow canal represents a serious problem which we often found in clinical practice, especially in molar teeth. Narrow / calcified root canal is difficult or even impossible to find and treat conservatively. An effort needs to locate the residual canal may remove large amounts of dentin and there's a risk of perforating or fracturing the root.¹

Primary goal in endodontic treatment is to prevent and to treat microbial contamination of pulps and root canal systems and also to cure or prevent periradicular periodontitis. This can be achieved by chemo-mechanical debridement, disinfection and obturation of the root canal system. However it will become challenge when treating obstructed, narrow or calcified canal.³

Chronic inflammatory processes (example caries) often cause pulpal degeneration and concomitant narrowing of the root canal system. Although the coronal portion of the canal may appear diminished significantly, canals often become less calcified as they approach the root apex. Pulp chamber and root canal that demonstrate significant calcifications may present problems with locating, penetrating and negotiating root canal.²

Calcification is defined as a pulpal response to trauma that is characterized by deposition of hard tissue within root canal. It may occur following mineralization in response to various irritants, aging and trauma. This calcification is called calcific metamorphosis and is commonly found in young adults in the anterior region of the mouth.¹

Glide path can be done either manually or with special rotary instruments. An enlargement to a size approaching the subsequent rotary tips, at least larger than the file's core diameter, prevents breakage and allows assessment of the canal size. Adequate glide path, a detailed knowledge of anatomic structures, with avoidance of extreme canal configurations, and specific instrumentation sequences may also improve shaping results.³

Case Report

A 30 years old female patient came to Department of Conservative Dentistry & Endodontics Trisakti University with chief complaint of discomfort of her

tooth especially when there's food inside but without any history of pain. Clinical examination revealed there was cavity on tooth 12. (Fig.1A) Vitality test showed no response to cold test. Tooth had no tenderness on palpation, percussion and periodontal probing and mobility was within physiologic limits. Preoperative radiograph revealed the presence of a single root with no visible root canal space in right lateral incisor compared to other teeth. Periodontal ligament space widening around apex tooth 12 was observed and there were periodontal lesion. (Fig.1B). From clinical and radiograph examination led to diagnosis of apical periodontitis et cause necrosis pulp and it required root canal treatment.

Root canal treatment was planned for lateral incisor after building artificial wall (Fig.1C). An access preparation was done with endo access bur. No canal was visible during access opening initially. Negotiating the canal was started with K-file #08 and K-file #10. EDTA gel (RC Help, Prime Dental products Pvt, Ltd) was used as a chelating agent each time while file was inserted..

After several attempts, patency was gained with K-file #10. A radiograph was taken to verify the file position in the canal. The working length was measured with apex locator (Dentaport ZX, Morita) and confirmed with radiograph (Fig.1D). After establishing smooth glide path with K file #10, mechanical preparation was done with Protaper Universal Hand File (Dentsply)

and was confirmed radiographically by Master cone F3 (Dentsply) (Fig.1E). In between instrumentation, root canal was irrigated with 5,25% sodium hypochlorite (Chloraxid, Cerkamed) and final flush was done with 17% EDTA (Endo solution, Cerkamed) and 2% chlorhexidine

(Cerkamed) and saline. Obturation was performed with gutta-percha protaper F3 (Dentsply, Maillefer) and calcium hydroxide sealer (Saelapex, SybronEndo) using vertical compaction technique (Fig.1F). The tooth was then restored with resin composite (Fig.1G,amd 1H).

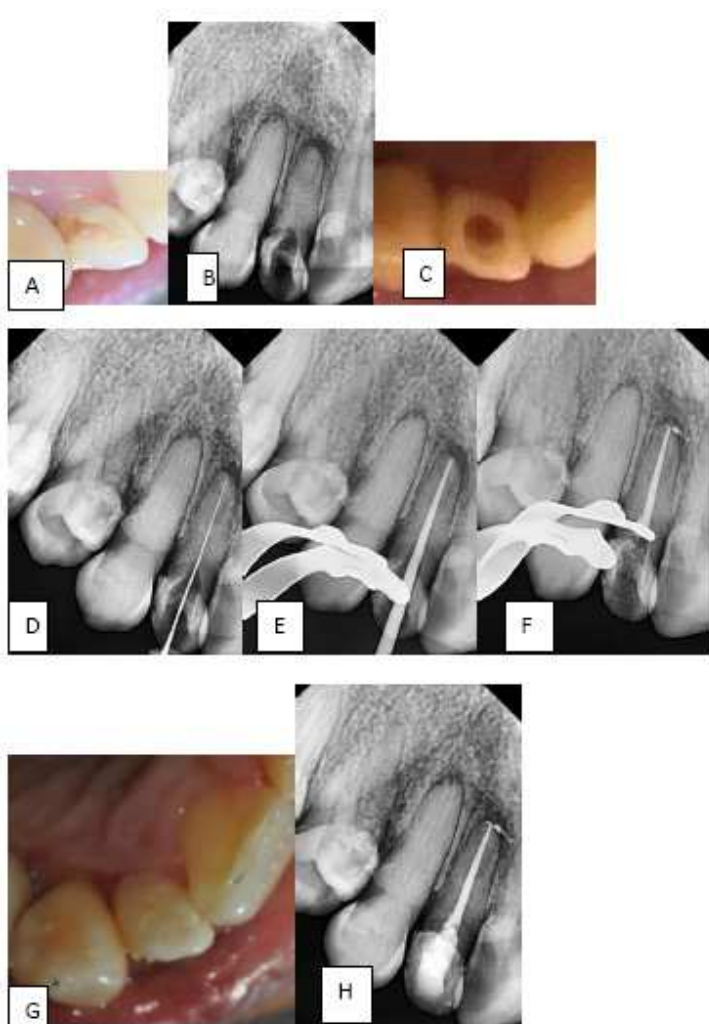


Fig 1. (A) Clinical showing a cavity on tooth (B) Pre-operative radiograph (C) Access opening after re-walling (D) Working length radiograph (E) Master cone radiograph (F) Obturation (G) restoration resin composite post endodontic (I) Restoration post endodontic radiograph

Discussion

Locating canals also applies during access preparation. There's a chance that the canal may be very tiny or it may be difficult or impossible to find or negotiate, but it is present. Also canals are frequently not visible on radiograph. A single canal will lie in the center of the root. Pre-operative radiograph contains a lot of useful information as size, curvature, position of root canal in relation with pulp chamber.³

Location and penetration of the canal orifice are often difficult and time-consuming in calcified and narrow canals. Small files (K-files #06,#08,#10) are usually required for initial pathfinding. However K-files #06 lacks of stiffness in its shaft and easily bends and curls under gentle apical pressure.⁴ Exploring root canal also can be done with thin ultrasonic tips, endo explorer, pathfile CS. If the canal still can not be negotiated, drill 1-2 mm into the center of orifice with no.2 round bur low speed and use explorer to re-establish the canal orifice.¹

Glide path can be done either manually or with special rotary instruments. An enlargement to a size approaching the subsequent rotaries tips, at least larger than the file's core diameter, prevents breakage and allows assessment of the canal size. Adequate glide path, a detailed knowledge of anatomic structures, with avoidance of extreme canal configurations, and specific instrumentation sequences may also improve shaping results.³.

Chelating agent have been advocated frequently as adjuncts for root canal preparation, especially in narrow and calcified root canal. Apical dentin is more frequently sclerosed and is more mineralized. Several authors recommend liquid EDTA solution be introduced into the pulp chamber to identify the entrance to calcified canals.³ The effect of chelators in negotiating narrow, tortuous, calcified canals to establish patency depends on both canal width and the amount of active substance available, since the demineralization process continues until all chelators have formed complexes with calcium.³ The effectiveness of EDTA is related to time of application, the pH and concentration.⁵

Sodium hypochlorite has systematically used as an endodontic irrigants for the chemo mechanical preparation of root canal because of its excellent antimicrobial action, capacity of dissolving organic tissue fragments, and improving the action of instruments and drill. Sodium hypochlorite may also be used to identify calcified canal enhanced using the 'bubble' or 'champagne' test by placing 5% into pulp chamber over a calcified canal containing remnants of pulp tissue will result in a stream of bubble emerging from oxygenation of the tissue. It can be seen under microscope and be used to identify the canal orifice.⁶

Final irrigation with EDTA, and chlorhexidine will help to obtain a clean environment and enhance hermetic sealing during obturation.⁵

Conclusion

The right management in discovering glide path on narrow root canal will increase successful rate of root canal treatment. Although knowledge of tooth morphology, patience, use of appropriate instruments and materials are essential to increase the success of endodontic treatment.

References

1. Bernice T, Manoj Chandak, Adityavardhan P, Bharat D, Harshit K. Calcified Canals – a Review, IOSR Journal of Dental and Medical Sciences (IOSR-JDMS), 13(50),2014,38-43.
2. Gutmann, JL, Fan B. 2016. Tooth Morphology, Isolation and Access. In Hargreaves KM, Berman LH (eds). Cohen pathway of the pulp 11th. Elsevier. St. Louis. P.162-163
3. Peters OA, Peters CI, Basrani B. 2016. Cleaning and shaping the root canal system. In Hargreaves KM, Berman LH (eds). Cohen pathway of the pulp 11th. Elsevier. St. Louis. P.209-258
4. Allen MJ, Glickman GN, Griggs JA. Comparative analysis of endodontic pathfinders. JOE 33(6).2007;723-726.
5. Johnson W, Kulilid JC, Tay F. 2016. Obturation of the cleaned and shaped root canal system. IN Hargreaves LM, Berman LH (eds). Cohen pathway of the pulp 11th. Elsevier, St. Louis. p287-289
6. Ruddle CJ. Identifying root canal endodontic strategies. Endodontic practice US;4(6);5-6.

ENDODONTIC RETREATMENT OF MAXILLARY FIRST MOLAR WITH ADDITIONAL OF MB 2 ROOT CANAL

A CASE REPORT

Hernika Harperiana¹, Juanita A Gunawan², Anastasia E Prahasti²

Departement of Conservative Dentistry, Faculty of Dentistry, Trisakti University

¹ Resident in Departemet Conservative Dentistry and Endodontics Trisakti University

² Lecturer in Departemet Conservative Dentistry and Endodontics Trisakti University

Background : The main objective of the root canal treatment is to clean the entire pulp cavity and to obture it with a solid filling material. For a complete healing of periradicular tissues, all of the root canals must be located and treated. Missing root canals like second mesiobuccal canal and infected spaces like under obturation is one of the reasons of endodontic failure. To eliminate such problems, clinicians need to know thoroughly the morphology of the external and internal anatomy of teeth and atypical root canal configuration and its variation. Maxillary first molar usually exhibits a second mesiobuccal canal. This canal provides a great challenge for clinicians to recognized. Failure to locate this extra canal may result in endodontic failure. **Objective** : The aim of this case report is to demonstrate a succeed retreatment of maxillary first molar in which an extra canal in mesiobuccal root was located using visual, tactile and magnifying devices. **Case Management** : A 23-years-old female patient came with a chief complaint on the maxillary first molar. Patient felt uncomfortable in chewing. The tooth was tender to percussion but the palpation and mobility was normal. A radiographic examination showed that the tooth has been treated endodontically but the obturation showed uncompleted and there was a miscanal in mesiobuccal. **Conclusion** : A complete cleaning and obturation the entire pulp cavity on maxillary first molar showed a successful treatment outcome.

Keywords : root canal retreatment, second mesiobuccal canal, endodontics failure.

INTRODUCTION

The general purpose of the endodontic treatment is to maintain teeth duration as long as possible in the oral cavity.¹The major goals of root canal treatment are to clean and shape the root canal system and

seal it in 3 dimension,²so that any possibility of a secondary infection occurrence due to the mouth cavity or periradicular tissue leakage into the root canal system can be avoided.¹

Although initial root canal therapy has been shown to be a predictable procedure with a high degree of success, failures can occur after treatment. Recent publications reported failure rates of 14%–16% for initial root canal treatment.² The causes of the endodontic failures can be variations in the anatomy of the teeth, the presence of additional root canals, lateral canals, depend on technical, biological and iatrogenic factors which contribute to accomplishment of treatment.¹

Studies have shown that unprepared areas of the root canal system may harbor bacteria and necrotic tissue that may result in root canal treatment failure. Thus the primary goal of root canal treatment should be to eliminate completely or reduce the microbial population within the root canal system and to prevent re-infection by providing tight seal.³ Knowing and understanding the relation between these factors may help in increasing the chances of preventing the possible endodontic treatment failures.¹

Endodontic failures must be evaluated so a decision can be made among nonsurgical retreatment, surgical retreatment, or extraction. The goals of nonsurgical retreatment are to remove materials from the root canal space and if present, address deficiencies or repair defects that are pathologic or iatrogenic in origin. Additionally, nonsurgical retreatment procedures confirm mechanical failures, previously missed canals. Importantly, disassembly and corrective

procedures allow clinicians to shape canals and three dimensionally clean and pack root canal systems.⁴

The success of endodontic treatment also requires adequate knowledge of the internal anatomy of the teeth and possible variations in relation to those teeth. Inadequate access can lead to canals being left untreated and may lead to the failure of the treatment.⁵ The most common cause of treatment failures in permanent maxillary first molars have been attributed to failure in detecting additional canals especially in the mesiobuccal root.⁶ Missed canals hold tissue, and at times bacteria and related irritants that inevitably contribute to clinical symptoms and lesions of endodontic origin.⁴

A thorough knowledge of the anatomy of root canal systems is required to achieve successful root canal treatment. Extra roots or root canals if not detected are a major reason for failure.⁷ The maxillary first molar has some of the highest failure rates in endodontic treatment. The failure often is due to the presence of a second canal in the mesiobuccal root that the operator fails to explore, prepare and obturate three dimensionally.⁸ Maxillary first molar largest in volume and has a complicated details in root and root canal configuration, and possibly the most treated teeth endodontically.⁷

CASE REPORT

A 23 year old female was referred to department of conservative dentistry

Trisakti University with the chief complaint of pain on her upper left molar. Clinical examination revealed a large resin composite restoration on the occlusal area of tooth #26 (Fig.1a). The tooth had no tenderness on palpation, percussion was positive, and mobility was normal. No fistulae and edema was observed. Radiographic examination revealed a large restoration extending to the pulp chamber,

the tooth had previously endodontically treated, but the obturation revealed inadequate and there was a miscanal on mesial. Also it found aperiapical lesion on the apical of the mesial root canal (Fig.1b). The clinical and radiographic examination led to a diagnosis of symptomatic apical periodontitis of previously treated teeth and requiring root canal retreatment.

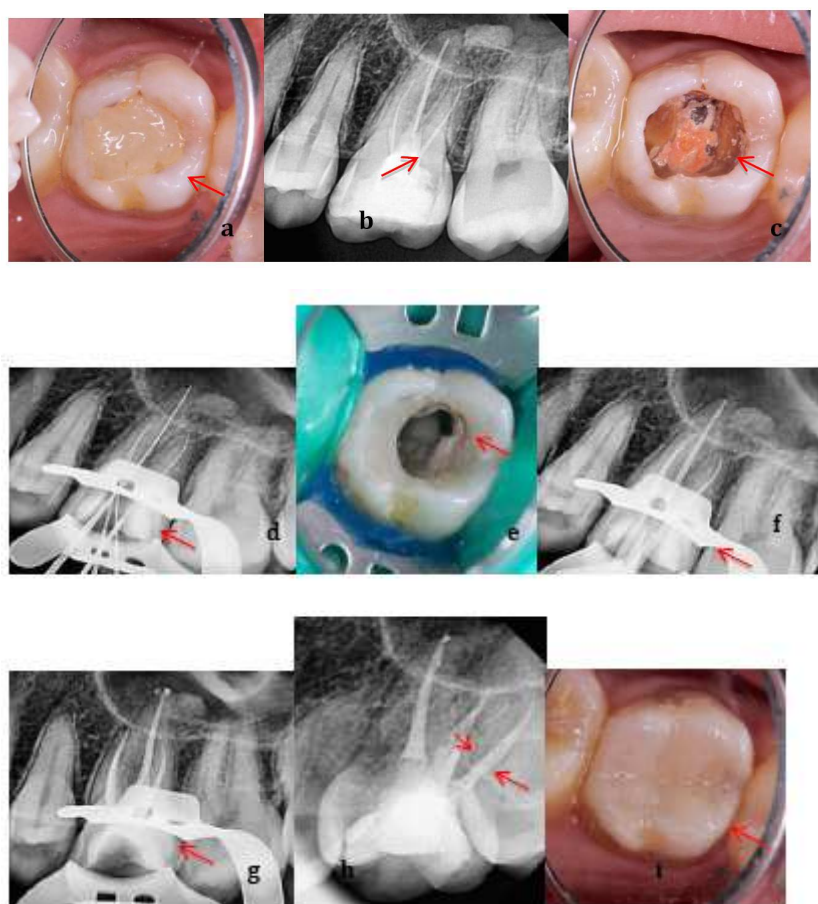


Figure 1. a) preoperative on occlusal view. b) initial radiograph. c) access opening. d) radiograph conformation of working length. e) preparation result of second mesiobuccal. f) radiograph confirmation of master cone gutta percha. g) obturation result. h) obturation result in different angle with object buccal rule technique. i) final restoration with resin composite.

Previously resin composite restoration was removed. Access cavity was prepared with a round diamond bur followed by isolation with rubber dam. The old gutta percha was removed with solvent (xylol) and Hedstrom file #15. All canals were negotiated with k-file #10 and #15 and a second mesiobuccal canal was found. After negotiating all canals and then the working length was determined using Propex Pixie apex locator (Dentsply, Maillefer) and confirmed with radiograph (Fig. 1d). After establishing glide path with Proglider (Dentsply, Maillefer), all canals were shaped with Protaper Next (Dentsply, Maillefer) file X1 and X2, respectively. In between instrumentation, copious irrigation was done with 5.25% NaOCl (Chloraxid, Cerkamed) and saline, and recapitulated with k-file #10. Final irrigation was done with 5 mL NaOCl 5.25%, 5 mL EDTA 17%, and 5 mL Chlorhexidine 17% and activated with sonic Eddy (VDW, Germany), respectively, for 20 second. Calcium hydroxide (Ultracal XS, UltraDent) was used as an intracanal medicament.

Second visit was seven days later, patient was clinically evaluated and the tooth revealed asymptomatic. Rubber dam was placed and followed by removal of calcium hydroxide with NaOCl 5.25% and activated by sonic eddy (VDW, Germany). Trial master cone gutta percha was done with gutta percha Protaper Next X2 and confirmed with radiograph (Fig. 1f) and followed by final irrigation with 5 mL NaOCl 5.25%, 5 mL EDTA 17%, and

5 mL Chlorhexidine 17% and activated with sonic Eddy (VDW, Germany), respectively, for 20 second. Obturation was performed with gutta-percha Protaper Next X2 (Dentsply, Maillefer) and root canal sealer (Saelapex, SybronEndo) using warm vertical compaction technique (Fig. 1g and 1h). The tooth was then restored with resin composite (Fig. 1i).

DISCUSSION

The main objective of endodontic treatment is thorough mechanical and chemical debridement of necrotic tissue and its complete obturation with an inert filling material. The major cause of endodontic failure when treating the first maxillary molar is failure to debride the entire root canal system, which usually occurs because the clinician was unable to detect additional root canals.⁸

The permanent first maxillary molar and permanent second maxillary molar are the teeth that present the greatest complexity and variation in the root canal system and this is reflected in them having the highest rates of endodontic failure and being a constant challenge for the clinician.⁹ Extra roots or root canals if not detected are a major reason for failure.⁷

The maxillary first molar has some of the highest failure rates in endodontic treatment.⁸ A high percentage of treatment failures is due to the impossibility of detecting the presence and location of the secondary mesiobuccal canal (MB2), located in the mesiobuccal root of the

first maxillary molar, which prevents the correct implementation of biomechanical instrumentation, irrigation and obturation.⁹First molar largest in volume

and has a complicated details in root and root canal configuration, and possibly the most treated teeth endodontically.⁷

Table 1. Incidence of two canals in the mesiobuccal root in laboratory and clinical studies.⁸

No. of canals and apices	No. of studies cited	No. of teeth (canal studies)	1 canal	≥ 2 canals
Mesiobuccal root (Laboratory studies)	24	3235	38.9% (1259)	61.1% (1976)
Mesiobuccal root (Clinical studies)	13	5280	45.3% (2393)	54.7% (2887)

Table 2. Result of investigation of second mesiobuccal canals.⁸

Teeth	3 canals		4 canals (MB2)	
	No.	%	No.	%
Maxillary first molar (<i>n</i> = 308)	97	31.5	211	68.5

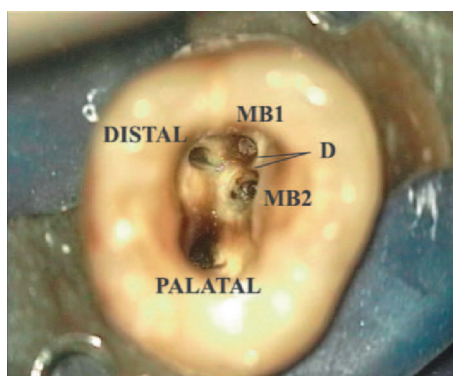


Figure 2. Occlusal view of maxillary first molar with MB1 and MB2.
D = distance between MB1 and MB2.⁸

Morphologic variation in the anatomy of the root canal system should always be considered at the beginning of a treatment. Each case, independent of the type of tooth, should be examined clinically and radiologically in a thorough manner to detect possible anatomic anomalies. Endodontic treatment should be initiated with proper preparation to allow access to the cavity, which can ease the process of

investigating and successfully detecting all root canal orifices.⁸

CONCLUSION

The success of endodontic treatment also requires adequate knowledge of the internal anatomy of the teeth and possible variations in relation to those teeth. Inadequate access can lead to canals being

left untreated and may lead to the failure of the treatment.⁵

The most common cause of treatment failures in permanent maxillary first molars have been attributed to failure in detecting additional canals especially in the mesiobuccal root.⁶ Missed canals hold tissue, and at times bacteria and related irritants that inevitably contribute to clinical symptoms and lesions of endodontic origin.⁴ Remnants of pulp tissue can be a reservoir for the growth of microorganisms, which may affect and compromise treatment outcomes.⁸

A thorough knowledge of the anatomy of root canal systems is required to achieve successful root canal treatment.

REFERENCES

1. Chaurasiya S, Yadav G, Tripathi AM, Dhinsa K. Endodontic Failures and its Management: A Review. *Int J Oral Health Med Res.* 2016;2(5):144-148.
2. Torabinejad M, Handysides R, Shabahang S. Outcome of Nonsurgical Retreatment and Endodontic Surgery : A Systematic Review. *JOE.* 2009 ; Vol. 35 No. 7.
3. Khan M, Rehman K, Saleem M. Causes of Endodontic Treatment Failure – A Study. *Pakistan Oral & Dental Journal.* 2010 ; Vol. 30 No. 1.
4. Ruddle CJ. Nonsurgical Endodontic Retreatment. *CDA Journal.* 2004.
5. Arora D, Nagpal A, Paul R, Hans M. Missed Canal : The Usual Suspect of Endodontic Failure. *International Health Care Research Journal.* 2017 ; 1(6):12-5.
6. Kakkar P, Singh A. Maxillary First Molar with Three Canals Confirmed with Spiral Computer Tomography. *J Clin Exp Dent.* 2012;4(4):e256-9.
7. Faraj BM. Prevalence of MB2 Canal in Maxillary First Molar : An In Vitro Study on the Sulaimani Population. *International Journal of Medicine and Medical Science Research.* 2014 ; Vol. 2(3), pp. 039-042.
8. Peeters HH, Suardita K, Setijanto D. Prevalence of a Second Canal in the Mesiobuccal Root of Permanent Maxillary First Molars from an Indonesian Population. *Journal of Oral Science.* 2011 ; Vol. 53, No. 4, 489-494.
9. Betancourt P, Navarro P, Munoz G, Fuentes R. Prevalence and Location of The Secondary Mesiobuccal Canal in 1.100 Maxillary Molars Using Cone Beam Computer Tomography. *BMC Medical Imaging.* 2016 ; 16:66

CASE REPORT

RETROGADE FILLING USING MINERAL TRIOXIDE AGGREGATE (MTA) AFTER APICOECTOMY IN ENDODONTIC FAILURE CASE WITH OVERFILLED OBTURATION, ACRYLIC CROWN, AND CUSTOM DOWEL POST-CORE

Ida Fitri Setiyowati*, R. Tri Endra Untara**

*Resident of Conservative Dentistry, Faculty of Dentistry,
Universitas Gadjah Mada

** Lecturer of Department of Conservative Dentistry, Faculty of Dentistry,
Universitas Gadjah Mada

*Jl. Denta No.1 Sekip Utara, Yogyakarta, Email: idafitrisetiyowati84@gmail.com

ABSTRACT

Background: Endodontic treatment does not always successfully work. Endodontic treatment failure can be caused by various factors, one of them is caused by overfilled obturation. Endodontic treatment failure that is on a case of blocked coronal access needs to be handled by apicoectomy. **Objective:** The aim of this study is to evaluate retrograde filling using Mineral Trioxide Aggregate (MTA) after apicoectomy on the left maxillary central incisor that have been endodontic treated with overfilled obturation, acrylic crown, and custom dowel post-core. **Case:** The patient was a 26-year-old woman. She complained about her upper left tooth which had been sore since one month before. The pain came if the tooth touched the lower teeth. It increased if she used her front teeth to bite something. The treatment was conducted around 6 months ago. Based on radiographic evaluation, there were an overfilled obturation, a radiolucent in the periapical and a radiopaque on two third coronal of root canal that showed post. The tooth was treated with apicoectomy continued with retrograde filling using MTA. Acrylic crown was replaced with composite crown. **Result:** After six months of evaluation and surgical approach, it was found that there was no more overfilled obturation material and periapical lesion. The patient also said that she never complained on her upper-left tooth again and it could function properly. Mineral Trioxide Aggregate was used because it was easily manipulated, it had hydrophilic, and could induce tissue healing. **Conclusion:** Mineral Trioxide Aggregate can be used as retrograde filling material.

Keyword: Mineral Trioxide Aggregate (MTA), apicoectomy, overfilled obturation, retrograde filling

Introduction

Apicoectomy is a treatment that is mostly conducted as retreatment after failure of non-surgical root canal treatment¹. According to the updated guidelines by the European Society of Endodontology, indications for apical surgery comprise (1) radiological findings of apical periodontitis and/or symptoms associated with an obstructed canal (the obstruction proved not to be removable, displacement did not seem feasible or the risk of damage was too great), (2) extruded material with clinical or radiological findings of apical periodontitis and/or symptoms continuing over a prolonged period, (3) persisting or emerging disease following root-canal treatment when root canal retreatment is inappropriate, and (4) perforation of the root or the floor of the pulp chamber and where it is impossible to treat from within the pulp cavity².

Success rate of apicoectomy at 77,81% for 2 to 4 years and 71,8% for 4 to 6 years were found¹. The prognosis depends on several factors such as: different surgical procedures and materials, clinical and radiographic evaluation, systemic conditions, local factors such as involved teeth and their anatomy, previous treatment, and its quality³.

The procedure for apicoectomy includes the following steps such as: designing of flap, localization of apex (exposure of the periapical area and removal of pathological tissue), resection of apex, retrograde filling, wound cleansing,

and suturing⁴. The ideal root-end filling material seals the contents of the root canal system within the canal, preventing egress of any bacteria, bacterial by products, or toxic material into the surrounding periradicular tissues. The material should be nonresorbable, biocompatible, and dimensionally stable over time⁵. Mineral Trioxide Aggregate (MTA) has been one of the most studied root-end filling materials because of its tissue biocompatibility, good marginal sealing, low cytotoxicity, ability to induce deposition of mineralized tissues, and capacity to form a structural interface with other materials⁶.

The purpose of this article is to report evaluation in a clinical case of retrograde filling using Mineral Trioxide Aggregate (MTA) after apicoectomy on the left maxillary central incisor that has been endodontic treated with overfilled obturation, acrylic crown, and custom dowel post-core.

Case Report

A 26-year-old woman came to clinic of conservative dentistry of RSGM Prof Soedomo, Faculty of Dentistry, Universitas Gadjah Mada, Yogyakarta. She complained about her upper left tooth which had been sore since one month before. The pain came if the tooth touched the lower teeth. It increased if she used her front teeth to bite something. Her tooth was endodontically treated around 6 months ago.

Clinically, there was an acrylic crown on left maxillary central incisor, that was

poorly adapted and contoured (fig.1A). Radiographic examination showed overfilled obturation material on apex, that was about 5 mm in length, in which root canal treatment had failed (fig.1B). There was also a radiolucent area, showed periapical lesion, about 5 mm in diameter (fig.1B). There was a radiopaque on two third coronal of root canal that showed post (fig.1B). The length of the post was not conformed to the minimum requirement for length of post work. But the root canal was seen radiopaque showing the root canal filled with cement.

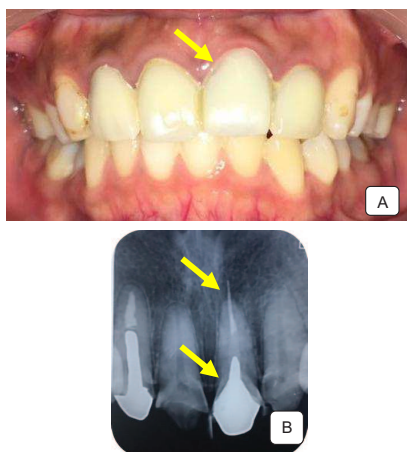


Fig. 1. A. Clinical dentition photograph showed acrylic crown on left maxillary central incisor that was poorly adapted and contoured, B. Radiographic photograph showed overfilled obturation material, periapical lesion, and post on two third of coronal root canal.

The treatment option was the removal of overfilled obturation material by apicoectomy. The next treatment was the replacement of crown. The crown had poor adaptation and contour. There was no

replacement of existing post because the middle third of root canal was filled with cement. Patient had no systemic alteration and allergy to certain drugs or ingredients.

The surgical area was disinfected with iodine solution. Lidocaine with epinephrine was used for local anesthesia. An infiltration anesthesia was performed on the alveolaris superior anterior (fig.2A) and nasopalatinus nerve (fig.2B). The flap design was a semilunar flap. Incisions were done by scalpel #15 (fig.2C) and was dissectioned with rasparatorium (fig.2D). The labial bone was opened using a round bur. After this procedure, overfilled obturation materials and all pathological tissues were removed by curettage (fig.3A). The root end was resected approximately 1 mm of the total root length with a fissure bur and beveled at a 0-10° angle to the long axis of the tooth (fig.3B). The cavity might be prepared with a round microbur for retrograde filling material (fig.3C). Mineral Trioxide Aggregate (MTA) as retrograde filling material was placed on prepared cavity using hand instrument (fig.3D). Finally, the flap was repositioned and sutured with simple interrupted suture (fig.3E). The operation area was covered with periodontal dressing (fig.3F).

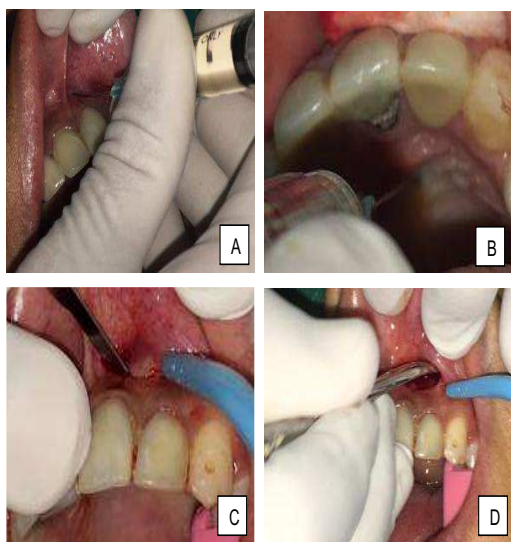


Fig. 2. Clinical photograph showed an infiltration anesthesia on alveolar superior anterior nerve (A) and nasopalatinus nerve (B), semilunar flap incisions using scalpel #15 (C), and flap dissection using raspatorium (D).

After the surgical procedures, radiographs were taken to verify the quality of the root-end treatment. The patient was received antibiotics and analgetics-antiinflammations. A follow up evaluation was performed after 7 days to hecting up the suture. The next evaluation was performed after 1 month (fig.4C), 3 months (fig.4D), and 6 months to confirm the clinical and radiograph aspects.

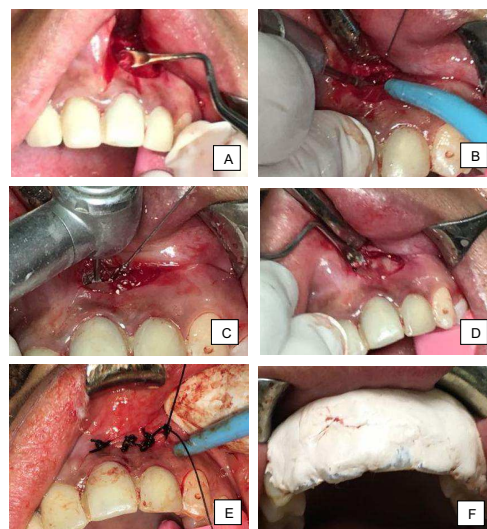


Fig. 3. Clinical photograph showed curettage of overfilled obturation material and all pathological tissues (A), resection of root end with fissure bur (B), preparation of cavity with round microbur (C), application of MTA as retrograde filling material using hand instrument (D), reposition and suture of the flap with simple interrupted suture (E), and cover of operation area with periodontal dressing (F).

Discussion

Endodontic failures may arise due to inadequate obturation such as overfilled obturation. This failure which is irretrievable root canal filling material, was the indication for surgical treatment⁷. On the other hand, surgery may be the first choice even if a tooth can be treated nonsurgically if the risks and costs of retreatment are considered excessive⁵. Especially apicoectomy was indicated to tooth with presence of posts or cores in root canal. Apicoectomy is the surgical

resection of the root tip of a tooth and its removal together with the pathological periapical tissues. The overfilled obturation material was also removed, which might be considered responsible for failure of an endodontic therapy⁴.

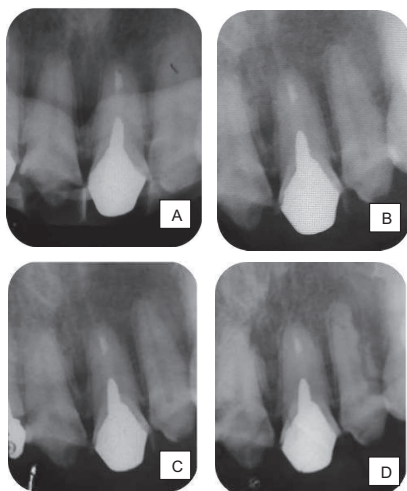


Fig. 4. Periapical radiographic images showed the tissues healing. After the surgical procedures, there was no longer overfilled material and radiolucent area on periapical are began to disappear (A). Follow up evaluation showed tissues healing after 7 days (B), 1 month (C), and 3 months (D), marked by the disappearance of the radiolucent area on periapical.

There are several flap designs suggested by endodontics. However, all the flap designs have both the advantages and disadvantages⁸. When apicoectomy was performed in the anterior region like in this case, and the size of the lesion is small, the semilunar flap was preferred⁴. After the flap was retracted, it was continued with osteotomy, that was involved the removal

of cortical plate to expose the root end.

The root end was resected approximately 1 mm of the total root length with a fissure bur and beveled at a 0-10° angle to the long axis of the tooth. Advantages of a zero degree bevel are exposure of fewer dentinal tubules, maintains maximum root length, reduced osteotomy size, and lesser apical leakage⁷. Two main principles dictated to extent of the root end resection are the cause of an ongoing disease process that must be removed and adequate room must be provided for inspection and management of the root end⁵. All pathological tissues and overfilled obturation materials were removed by curettage.

After the resection plane, a retrocavity was prepared into the root-end. While the conventional technique of root-end cavity preparation, i.e., the use of a small round bur or of an inverted cone bur in an angled micro-handpiece⁹. Various material had been used as root end filling materials. The choice of a root end filling material could be governed by handling properties, biocompatibility, apical seal, long term clinical success³, nonresorbable, antibacterial, and dimensionally stable¹⁰. Mineral trioxide aggregate appeared to have become the gold standards for a root end filling materials. Many clinical comparative studies published to date have reported higher success rates for MTA than for the competitor material⁹.

Mineral trioxide aggregate is a bioactive inorganic compound consisting

of calcium silicate, calcium aluminate, calcium aluminoferrite, calcium sulfate, and bismuth oxide¹¹. Although MTA is an expensive material, it has major advantages. The advantages include excellent biocompatibility, ideal adherence to the cavity walls, low solubility, and induce cementogenesis at the cut root face with deposition of new cementum onto the exposed dentin and MTA surfaces⁹. Mineral trioxide aggregate also has good physical and biological properties, and it becomes hydrophilic in nature³.

The treatment outcome of apical surgery should be assessed clinically and radiographically. A small periapical defects (<5 mm) might heal within a few months. Clinical healing is based on the absence of signs and symptoms such as pain, swelling, and tenderness to palpation or percussion. Standard radiographic healing classes include complete healing, incomplete healing (scar tissue formation), uncertain healing (partial resolution of postsurgical radiolucency), and unsatisfactory healing (no change or an increase in postsurgical radiolucency)⁹. In this case, clinically and radiographically it appears to be healing. Clinically, there are no complaints of pain experienced by the patient. Radiographically, there is no radiolucent area in the periapical area indicating complete healing.

Conclusion

Apicoectomy is the treatment of choice when a conventional retreatment is not possible. Its success is largely determined by the closure of the apical density using retrograde filling material. The use of MTA as a retrograde filling material has many advantages and results in good healing after several months of apicoectomy based on clinical and radiological examination.

Acknowledgement

The author is grateful to drg. R. Tri Endra Untara, M.S., Sp.KG (K) and drg. Wignyo Hadriyanto, M.S., Sp.KG (K) as faculty supervisor for providing invaluable guidance throughout the whole operating process and also to the patient for allowing the case to be presented.

References

1. Raedel M, Hartmann A, Bohm S, Walter MH. Three-year outcomes of apicoectomy: mining an insurance database. *Journal of Dentistry*. <http://dx.doi.org/doi:10.1016/j.jdent.2015.07.016>. 2015: 1-15.
2. Von Arx T. Apical surgery: A review of current techniques and outcome. *The Saudi Dental Journal*. 2011; 23: 9-15.
3. Shaheen S, Majumder D, Chowdhury D, Mazumder P, Kumar U. Healing of periapical lesion in maxillary anterior region with Mineral Trioxide Aggregate using retrograde technique after apicoectomy - a

- case report. *Imperial Journal of Interdisciplinary Resdyearch (IJIR)*. 2017; 3(3): 1720-1724.
4. Fragiskos FD. Apicoectomy. In: *Oral Surgery*. Springer. 2007: 312.
5. Hargreaves KM and Berman LH. The Advanced Science of Endodontics. In: *Cohen's Pathways of The Pulp*, eleventh edition. Elsevier. 2016: 389, 419.
6. Linhares GS, Cenci MS, Knabach CB, Oliz CM, Vieira MA, Ribeiro AS, Zanchi CH, Jacinto RC. Evaluation of pH and calcium ion release of a dual-cure bisphenol A ethoxylate dimethacrylate/Mineral TrioxideAggregate-based root-end filling material. *J. Endod.* 2013; 39: 1603-1606.
7. Garg N, Garg A. Textbook of Endodontics. Unipress. 2014; 390.
8. Chandra BS, Khrisna VG. *Grossman's Endodontic Practice*, twelfth edition. Wolters Kluwer Health. 2010.
9. Arx T. Apical surgery: A review of current techniques and outcome. *The Saudi Dental Journal*. 2011; 23: 9-15.
10. Zhou W, Zheng Q, Tan X, Song D, Zhang L, Huang D. Comparison of mineral trioxide aggregate and iRoot BP Plus root repair material as root-end filling materials in endodontic microsurgery: A prospective randomized controlled study. *J. Endod.* 2017; 43: 1-6.
11. Maeda T, Suzuki A, Yuzawa S, Baba Y, Kimura Y, Kato Y. Mineral trioxide aggregate induces osteoblastogenesis via Atf6. *Bone Reports*. 2015; 2: 36-43.

THE SHRINKAGE DIFFERENCES OF ROOT CANAL TREATMENT USING BALANCED FORCE AND STEP BACK PREPARATION TECHNIQUE WITH THERMOPLASTICIZED FILLING TECHNIQUE (SCANNING ELECTRON MICROSCOPY)

I Gusti Agung Ayu Hartini, Gede Bintang Anugrah

Faculty of Dentistry University of Mahasaraswati Denpasar

ABSTRACT

The failure of root canal treatment due to preparation techniques as well as unfavorable admission filling induce polymerization shrinkage which causes lack of attachment to the intraradicular dentin thus reducing retention and can increase the occurrence of micro cracks. The purpose of root canal treatment at the stage of preparation is to clear necrotic tissue and allow the root canal filling as well as to get a good prognosis. Many techniques are used for root canal preparation, one of which is the balanced force technique. Other preparation technique used is the step back technique. This study aims to determine differences in shrinkage of root canal treatment using the balanced force and step back preparation techniques with thermoplastic filling technique. The study design used experimental laboratory (in vitro). Samples used are 16 units of premolar in accordance with the criteria specified sample. The data is analyzed by using Independent Sample Test (T-Test). The examination sample using Scanning Electron Microscopy (SEM). The result showed that the preparation technique of balanced force shrinkage mean is 3,9907 μm while the step back preparation technique shrinkage mean is 3,1754 μm . Based on statistical test of independent t-test t count for shrinkage of root canal treatment balanced force and step back techniques is 1,298 with propability 0,213. Propability showed $>0,05$ then H_0 is accepted, which means that the root canal preparation with balanced force technique indicates the level of shrinkage is almost the same compared step back preparation techniques.

Keyword: shrinkage, balanced force, step back, thermoplasticized, SEM

Introduction

Root canal treatment is a part of the dental pulp treatment which is performed by removing the dental pulp followed by cleaning, shaping, and obturation so that

the tooth can perform its function (Thakur *dkk*, 2013). The goal of root canal treatment is to clean the infected pulp cavities and to prepare root canals to receive fillers that will cover the entire root canal system from

periodontal tissue and from the oral cavity (Harty F.Z., 1993).

According to Bence (1990) endodontic treatment stage known as endodontic treatment triads include: Disposal of infected tissue, Treatment and sterilization of root canals, and root canal filling. In addition, the dense closure of the crown is important where the end result of an endodontic treatment is the complete closure of the crown to the apical. Conditions for filling the root canal, ie: no complaints, no clinical symptoms, good temporary congestion, no excessive exudate (dry root canal), and negative or false-positive seedlings (Subiwahjudii A, 1997). An important stage in root canal treatment is root canal preparation. This stage includes two actions, the remaining disposal of root canals and soft dentine, and preparation of apex areas for good filling (Bence, 1994).

The balanced force technique has many advantages, including cleaner root canals, the potential for impulse to pass through reduced apical foramen, can maintain the shape of the root canal, preventing the occurrence of ledge and perforation and is particularly suitable for crooked root canals and has grown perfectly.

Balanced force technique is divided into three stages: Placement, Cutting (cutting dentin tissue), and Cleaning. Indications of this technique where the root canal is crooked and grown perfectly.

Step back preparation is a frequently used technique. This concept was first introduced by Clem in 1969 and became popular after several studies reported on its superiority over standard techniques. Indications of this technique are fully grown roots, straight root canals, bent and narrow. The step back technique produces a finer funnel shape from apex to corona. At present root canal preparation with this technique is most discussed and used. The goal is to keep apex preparations as small and as practical as possible and extend to the corona along the root canal (Walton 1997).

The step back technique has several advantages over conventional techniques, including: a) reducing periapical trauma, b) facilitating more debris, c) able to prepare dentine tissue, either apical or cervical well, d) more instrumentation-generated flares (e) can use a large condensing pressure so that the root canal is denser, the void can be reduced and can prevent over-squeezing into the root canal (Grossman, 1998).

Root canal irrigation measures are one of the important endodontic treatment stages because if ignored can cause treatment failure. The main principle of root canal cleaning is that the apparatus must reach all the walls of the root canal and release debris which is then removed from the root canal by the irrigation solution. Irrigation solution in addition to functioning as a disinfectant, pulp tissue solvent, bleach, also serves as a lubricant that will reduce the possibility of broken

endodontic devices (Wintarsih et al, 2009).

Root canal filling aims to provide a perfect closure in the root canal (Akbar, 2003). This closure will prevent bacteria and toxins from flowing into the periapical tissue and vice versa so that the root canal remains sterile from irritation from the apical tissue. Obturation is obtained by creating perfect density in the root canal system from corona to apical (Hammad et al., 2009). In addition to the root canal cement used, the preparation and filling technique of the root canal is also an important factor in determining the success of root canal treatment

According to Grossman (1995) the method of filling with this thermoplastic technique involves the use of a carpule containing a low-temperature gutta-percept formulation (70%). A special heater heats the gutta of rag until it can flow when pressed, and is ejected through a needle with a suitable gauge, directly into the root canal. This technique is done by using ultrafil or obtura, a tool that looks like a gun and is able to soften the guttap point and push into the root canal toward the apical. (Subiwahjudii, A. A, 1997).

To obtain good obturation results the largest portion of the root canal is filled with solid materials such as gutta konus perca and root canal wall cracks filled with root canal silar paste that can adapt to the root canal wall (Hammad et al., 2009). Siler is a substance that helps produce a strong attachment between two surfaces. The purpose of root canal siler

is to prevent bacterial recolonisation and recontamination of the root canal system, to prevent the growth of residual bacteria in the root canal system and to remove gaps between the main filler and the root canal wall (Grossman, 1980).

In recent years, epoxy resin siler has been known and increasingly popular. This is a polymer containing epoxy amines. The use of silicone with epoxy resin material is increasingly widespread one of which is the AH26 silher. The powder components in these silers contain bismuth oxide, methenamine, silver and titanium dioxide. This powder will be mixed with a paste containing epoxy resin as an activator, and will harden through a polymerization process. The content of bismuth oxide in a silk powder acts as a filler and a radiopaque. AH26® powders and resins are mixed to produce a root canal filling material with excellent sealing capacity. As a result of adaptation to the root canal wall and very small contractions during the setting, AH26 allows for the closing of tightly rooted root canal obturations with excellent network compatibility (Dentsply, 2007).

Excess SEM is a vacuum system in electron-optical column and sample chamber which aims to: a) eliminate the effect of electron motion not sequentially due to the existence of molecules in the environment, which can lead to decrease in intensity and stability, b) minimize the gas that can react by sampling or settling on a sample, whether derived from a sample or a microscope. Because if it happens, it will

decrease the contrast and darken the detail in the picture (Prasetyo, 2011).

MATERIALS AND METHODS

The design of this study was an experimental laboratory (In Vitro), with a Post-test only control group design. This study used the premolar teeth of maxillary mandibular. The number of samples were 16 premolar teeth samples. Then divided into 2 groups: first group using thermoplastic filling technique with balanced force preparation technique and second group using thermoplastic filling technique with step back technique. Sampling was done by Random Sampling.

The sample criteria in this study were: Single rooted teeth (premolar maxilla and mandible), no caries, crooked and perfectly formed root teeth and never been treated. tools used : cement spatel, Gates Glidden Drill (GGD), Glass Lab, lentulo needle, round bur, root canal filling tool (Herofill™ Oven), fissure bur, plastic filling instrument, Mini Endo Block, Carborundum disc, Miller needle, Straight Handpiece NSK, Ekstirpasi needle, Syringe Needle, K-file needle, Handpiece contra angle, NiTi Flex needle, caliper. Preparation tools gears : hand piece contra angle, Round Bur, Fissure Bur.

Root Canal Preparation tools: Miller needle, Ekstirpasi needle, Mini Endo Blok, Gates Glidden Drill, K-File needle, Niti Flex needle, Syringe Needle. Cutting tools on apical third: Straight Handpiece, Carburundum disc.

Material: Thermoplastic gutta perca, Siler salurna root resin class (AH 26) silverfree, Cavit G (3M ESPE Germany), EDTA Solution.

Root Filler Filler: AH 26 resin silicone, Cavit, EDTA Solution, Gutta Perca Thermoplastik.

RESEARCH

Premolar teeth which were going to be sampled, each tooth sample was measured the length of the tooth first using the sliding term and record the result of the measurement in the form that is already available, then determined the length of its work by reducing 2mm from the length of the sample tooth, then do the tooth planting in the beam cast.

The sample was divided into 2 groups, each group consisting of 8 samples. Group I is the root canal filling of a balanced force preparation technique with thermoplastic filling with AH26 resin silk. Group II is root canal filling of step back preparation techniques with thermoplastic filling with AH26 siler. The sample was planted on soft cotton beam with length of 13 cm, width 4 cm and height 3 cm. Mark the working length of each sample on the plaster beam.

Group I (Balanced Force) was done root canal preparation on the tooth with balanced technique as follows: Determine the length of work on the teeth first with the way the teeth are measured then reduced by 2mm, Then make outline form on the teeth, Samples are prepared using round

bur with contra angle high speed, Use miller needle to find orifice, Use needle extirpation to lift necrotic tissue, Using file preparation tool type R-Flex or NiTi Flex, Use file no. 10 with steam wending motion, the file is rotated with a quarter-turn rotation clockwise followed by a half-turn rotation counterclockwise with light apical pressure toward the apical foramen until the length of the work is obtained. Then file no. 15 according to the length of work, File no. 20 according to the length of work, File no. 25 according to the length of work, File no. 30 according to the length of work, File no. 35 with a distance of 0.5mm shorter than the length of work, At 2/3 coronal done preparation with Gates Glidden Drill (GGD), GGD # 2 = along 3mm of the apical foramen, GGD # 3 = along GGD # 2 - 2mm, GGD # 4 = along GGD # 3 - 2mm, GGD # 5 = along GGD # 4 - 2mm, GGD # 6 = along GGD # 5 - 2mm. Preparation continued with file no. 40 minus 1mm of working length. Then file no. 45 minus 1mm of working length to get apical control zone. During the preparation carried out irrigation of the root canal. If there is a blockage in the root canal can be given EDTA solution which is inserted with needle syringe After root canal preparation is complete, dried using paper point (Samadi, 2003).

Group II (Step Back) performed root canal preparation on the tooth with step back technique as follows:

Determine the length of work on the teeth first with the way the teeth length

is measured and then subtracted 2mm, Then make outline form on the teeth, Samples are prepared using round bur with highspeed contra angle Use miller needle to look for orifice Use an extirpant needle to remove necrotic tissue, apex preparation with no file no. 15 whose length of work has been measured, followed by file no. 20 corresponds to the length of work .. Then no. 25 according to the length of work, file no. 25 This is a master apical file. Subsequently performed coronal preparation using file no. 30 with a working length minus 1mm, Then use file no. 35 with a working length minus 2mm, Then use file no. 40 to no. 55 with a working length minus 3 mm, During the preparation carried out irrigation of root canals (Tarigan, 1994).

Channel filling of the thermoplastic technique root with AH26 resin silk.

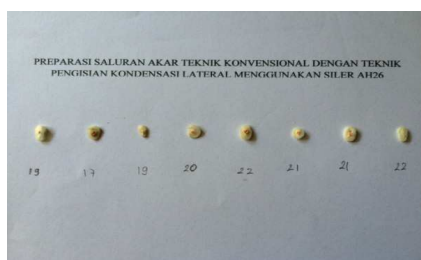
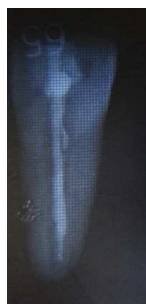
Root canal wall is grafted with AH26 root canal root with powder and resin ratio using lentulo needle until evenly distributed, Gutta perca thermofill is marked according to working length and heated in oven (Herofill™ Oven) with temperature 1100 C up to 1300 C. Gutta perca thermofill which has heated 52 seconds inserted slowly toward apical to full length of work, Stalk on obturator mounted on the root canal orifice by using excavator, cavity filled with small cotton and then temporarily caulked with cavit.

The next stage of the filling sample is then cut transversely to one third apical using a Carborundum disc. After that the sample was tested by SEM technique

(Scanning Electron Microscopy) to know the level of shrinkage that happened.



The cultivation of the sample in the beam cast software




RESEARCH RESULT


From observation by using Scanning Electron Microscopy (SEM) got result from both group.

No.	Balanced Force (μm)	Step Back (μm)
1.	3,753	4,204
2.	5,857	4,769
3.	4,679	2,606
4.	5,268	2,817
5.	3,258	1,566
6.	3,888	5,098
7.	2,488	2,749
8.	2,002	3,737

SEM analysis result of root canal preparation of balanced force technique



SEM analysis result of root canal preparation step back technique



Statistical test results by using independent t-test can be obtained the following results:

Group	N	X (μm)	SD	t	P
I Balanced Force	8	3,9907	1,27383	1,298	0,213
II Step Back	8	3,1754	1,38852	1,298	0,213

From the above statistical test results, can be seen that t arithmetic root shrinkage technique preparation balanced force and step back is 1.298 with 0.213 propability. The result of propability shows > 0.05 then H_0 is accepted, which there is no significant difference between the balanced force preparation technique and step back preparation technique using thermoplastic filling technique with AH26 silher

DISCUSSION

This study obtained statistical test results using independent t-test techniques preparation balanced force and step back can be seen that t arithmetic profit shrinkage of root canal technique preparation balanced force and step back is 1.298 with propability 0.213. The result shows that there is no significant difference between the balanced force preparation technique and the step back technique using AH26® siler. The results show that the shrinkage of root canal treatment techniques is slightly smaller than the balanced force technique. This is caused by excessive use of carburundum disc during the cutting process. Thereby causing excessive heat (over-heating) during the cutting process.

The excessive heat results in the attachment between root canal wall and filler is not good so that the retention decreases and micro gaps are created. However, this does not have a significant impact on the differences between two preparation techniques used. This is in accordance with Hayes et al (2002) study, where in the use of balanced force and step back techniques, there were no significant differences either statistically or substantially.

CONCLUSION

The result of statistical test by using independent t-test of balanced force preparation technique and step back can be seen that the result of propability shows $> 0,05$ then H_0 is accepted, there is no significant difference between the technique of balanced force preparation with step back technique using thermoplastic filling technique with AH26 siler. So it can be concluded that root canal preparation with balanced force technique shows almost the same level of shrinkage compared with step back preparation technique.

Reference

- Akbar S. M., 2003, *Perawatan Saluran Akar*, Pradnya Paramitha, Jakarta, 21-130.
- Anusavice, KJ. 1996. *Philip's Science of Dental Materials 10th edition*. Philadelphia: W.B.Saunders Company, h. 75-79.
- Bence R. Buku pedoman endodontic klinik (Terj).Penerbit Widya Medika; 1994. H. 85-101
- Dentsply, 2007, Direction For Use AH26 Root Canal Sealing and Filling Material, German, 1-3.
- Eldeniz A. U. dkk., 2007, Evaluation of pH and Calcium Ion Release of Acroseal Sealer in Comparison with Apexit and Sealapex Sealers, *Oral Surg Oral Med Oral Pathol Oral Radiol Endod*, 103:86-91
- Grossman, LI., Oliet, S., Del Rio CE, 1995. *Ilmu Endodontik dalam Praktek (Endodontice Practice) Edisi 11*. Terj. Abyono, R. Penyunting Suryo, S. Jakarta: EGC, h. 47-48,59.
- Grossman, Louis I. 1998. *Endodontics Practice* 8th Ed: Philadelphia, London; Leo and Febiger
- Hammad M. dkk., 2009, *Evaluation of Root Canal Obturation: A Three – Dimensional In Vitro Study*, *J. Endod*, 35: 541-544.
- Harty, F. Z., 1993, *Endodontis Klinis* Edisi 3, Jakarta : Hipokrates, p. 137-138.
- Prasetyo, Y. 2011. *Scanning Electron Microscope dan Optical Emission Spectroscope*. <http://yudiprasetyo53.wordpress.com/2011/11/07/scanning-electron-microscope-sem-dan-optical-emission-spectroscope-oes/> Tanggal akses 19.03.12
- Samadi 2003. *Perawatan Pulpa Gigi*. Penerbit Buku Kedokteran EGC Jakarta.
- Subiwahyudi, A., 1997. 'Pengisian saluran skar' FKG Unair.
- Sunarko, 1997. 'Perbedaan Kerapatan Penutupan Apeks Pada Pengisian Kondensasi vertical dengan Pasta Saluran Akar ChKM dan AH26'. *Dental Journal*. Vol 30, no. 2, hlm. 65-68.
- Tarigan Rasinta. 2004. *Perawatan Pulpa Gigi (Endodontic)*,Ed.Ke-2, EGC Jakarta.
- Thakur, S., Emil, J., Paulaian, B., 2013, *Evaluation of Mineral Trioxide Aggregate as Root Canal Sealer : A Clinical Study*, *J Conserv Dent.*, 16 (6) : 494-498.
- Walton RE, Rivera EM., 1997, *Pembersihan dan pembentukan saluran akar in Prinsip dan praktek ilmu endodonsi*. Edisi 2. Ahli bahasa: Sumawinata N, dkk. Jakarta. EGC,: 263-303
- Walton R. and Torabinejad M., 2003. *Principle and Practive of Endodontics*. 2nd Ed. Philadelphia: W.B.Saunders Co.
- Wintarsih, O., Partosoedarmo, M., Santoso, P., 2009, *Kebocoran Apikal pada Irigasi dengan EDTA Lebih Kecil Dibandingkan yang Tanpa EDTA (A Comparative Study of Apical Leakage on Irrigation Using and Without EDTA)*, *Jurnal PDGI.*, 58 (2) : 14-19.

LITERATUR REVIEW

ANTIBACTERIAL EFFICACY OF CHITOSAN AS ROOT CANAL IRRIGANTS IN ENDODONTICS ON ENTEROCOCCUS FAECALIS (LITERATUR REVIEW)

Imelda Darmawi * Trimurni Abidin**

* *Resident of Specialist Program of Conservative Dentistry*

** *Lecturer of Specialist of Conservative Dentistry*

Faculty of Dentistry, University of Sumatera Utara
Jln. Alumni no. 2 Kampus USU Medan 20155

ABSTRACT

Enterococcus faecalis is commonly detected in endodontic infections that are asymptomatic, persistent and recurrent. They are microorganisms mainly responsible for persistent periradicular lesion even after root canal treatment. The purpose of root canal treatment is eliminating all bacteria that cause changes in pulp and periapex tissue abnormalities. *E. faecalis* is a facultative anaerobic gram-positive bacteria and its often found in root canal treatment.. In chemomechanical preparation of irrigation solution plays an important role especially in removes the *smear layer*. Sodium hypochlorite is the most widely used endodontic irrigants as it is an effective antimicrobial and has tissue-dissolving capabilities. Chitosan have been reported broad spectrum of antibacterial properties, high chelating ability for various metal ion in acidic conditions, biocompatibility and biodegradability. chitosan-citrate solution shows antibacterial activity against *E. faecalis* and effectively and safely removes the *smear layer*. The purpose of this article to review antibacterial properties of chitosan-citrate solution as a root canal irrigant. against *E. Faecalis*.

Keywords: Chitosan, Enterococcus. Faecalis, Natrium hypochlorite (NaOCL)

INTRODUCTION

Bacteria play the primary role in the development of necrotic pulps, periapical pathosis and post-treatment disease following root canal treatment. Elimination of microbes from the pulpal tissue as well as root canals is the main goal in order to prevent and treat pulpal and periapical breakdown. Successful root canal therapy relies on the combination of proper instrumentation, disinfection and obturation of root canal.¹

Mechanical instrumentation is a way to reduce bacterial in the infected root canal, but achieving bacteria-free root canals still proves to be difficult. Various studies have demonstrated that mechanical preparation with hand instruments and irrigation with saline cannot predictably eliminate the bacteria from the infected root canals. Therefore, the current focus of interest has been the use of irrigating solutions with strong antibacterial activity.¹

Over the years, root canal irrigants have been used like sodium hypochlorite (NaOCL) 0,5-5,25%. Even after meticulous mechanical procedures along with the use of irrigating solutions, some bacteria can still form the canals. *Enterococcus faecalis*, a Gram-positive facultative anaerobe, is commonly found in the root canals of failing endodontically treated cases.¹

The search for new alternatives is necessary considering the disadvantages of the available antimicrobial irrigants. Chitosan 0,2-2% is a natural polysaccharide which is biocompatible, biodegradable, shows bioadhesion and lacks toxicity. Chitosan is a cationic biopolymer that possesses lasting antibacterial properties and low production costs. Chitosan is obtained by the deacetylation of chitin, which is found in crab and shrimp shells. To date, none of the study has consistently investigated the effects of chitosan against these microorganisms. So the aim of the study was to evaluate the antibacterial and cytotoxic effect of Chitosan a new alternative when used as root canal irrigant and to compare its action to the commonly used root canal irrigants sodium hypochlorite.²

Enterococcus faecalis

The name “enterococcus” was first used by Thiercelin in a paper from France published in 1899; the name was proposed to emphasize the intestinal origin of this organism. *Enterococcus faecalis* is a nonspore-forming, fermentative,

facultatively anaerobic, Gram-positive coccus. *Enterococcus faecalis* cells are ovoid and 0.5 to 1 µm in diameter.³

The persistence and growth of bacteria in root canal system is the main causative factor in pulpal and periradicular lesions. The success of the endodontic treatment primarily depends on successful removal of microbes from the infected root canal system. Although bacteria are the main microorganisms found in primary endodontic infections. *Enterococcus faecalis* are considered the most bacteria which are responsible for root canal treatment failures.²

Enterococci have displayed resistance to essentially every useful antimicrobial agent. The resistance may be intrinsic or acquired via gene transfer. The genes for intrinsic resistance, like other species characteristics, reside on the chromosome. Acquired resistance results from either a mutation in the existing DNA or acquisition of new gene, through the transfer of plasmids & transposons. The intrinsic resistance of enterococci to many commonly used antimicrobial agents may have allowed them a cumulative advantage for further acquisition of genes encoding high level resistance to aminoglycosides, penicillins, tetracycline, chloramphenicol, and now vancomycin. This allows the organism to survive in an environment in which antimicrobial agents are used. Indeed, in marginal periodontitis refractory to conventional treatment, an increased prevalence of bacteria resistant

to antibiotics may be found. The focus of infection is the root canal and the dentinal tubules, which are inaccessible to the elements of the host defense system.^{3,10}

One of the most important stages of treatment is root canal irrigation which is part of cleaning and shaping. In addition, irrigation materials can also have other functions, such as lubricants that can assist in cleaning and shaping the root canals (cleaning and shaping). Although chemo-mechanical preparation of the root canal system is able to reduce the number of bacteria, complete canal disinfection is difficult because of the internal complexity of root canal systems. Thus root canal irrigation forms an integral part of the endodontic therapy to ensure bacterial elimination and for the digestion of the organic tissue remnants as it allows for cleaning beyond what might be achieved by root canal instrumentation alone.⁴

According to Zehnder (2006) root canal irrigants ideally should:

1. Have a broad antimicrobial spectrum and high efficacy against anaerobic and facultative
2. Microorganisms organized in biofilms
3. Dissolve necrotic pulp tissue remnants
4. Inactivate endotoxin
5. Prevent the formation of a smear layer during instrumentation or dissolve the smear layer once it has formed

Furthermore, as endodontic irrigants come in contact with vital tissues, they should be systemically nontoxic, non-caustic to periodontal tissues and have little potential to cause an anaphylactic reaction.^{4,8}

The choice of an irrigant depends on their effectiveness to act as lubricants during instrumentation, flush debris and smear layer and efficacy on virulent bacteria present in the canal. Variations in chemical formulations of various irrigants might also have different impact with pulp, necrotic tissues and microorganisms. Sodium hypo-chlorite (NaOCl) is the most widely used irrigant due to its antimicrobial and organic tissue dissolving ability but it is toxic to the periapical tissues and weakens dentine by reducing its flexural strength and resilience by making it more susceptible to deformation and possibly fractures.^{4,7}

Sodium hypochlorite

Irrigation has played a main role in endodontic treatment. During and after instrumentation, the irrigants removal of bacteria, dentin chips from the root canal through a flushing mechanism tissue remnants. Some irrigants also possess antimicrobial activity. Irrigants can also help prevent packing of the hard and soft tissue in the apex and extrusion of infected material into the periapical area. There is no single irrigating solution that alone sufficiently covers all of the functions required from irrigants.⁶

Optimal irrigants is based on the combined use of two or several irrigating solutions in a specific, to predictably attain the goals of safe and effective irrigation. Complete removal of microorganisms from root canal is very important for success of treatment. *E. faecalis* has been only occasionally found in cases of primary endodontic infections but frequently isolated or detected in cases in which the endodontic therapy has failed. In addition, to disinfectants, physical removal of cells of *E. faecalis* through debridement of the root canal remains essential. Since remnants may sustain the inflammation. *E. faecalis* can be found at depths up to 300µm within dentinal tubules, where it is able to survive not withstanding the scant available nutrients, unlike other bacterial species.⁶

Sodium hypochlorite (NaOCl) has been used as the main irrigation agent in root canal treatment since 1920. Sodium hypochlorite is an alkaline irrigation that has pH 11-12. In 1936 the walker suggested using sodium hypochlorite for root canal treatment. The average concentration of commonly used NaOCl irrigation solution is 2.5% decreased concentrations means lowering the properties of toxicity, antibacterial effects and tissue dissolving ability. NaOCl also effectively dissolves the remaining pulp and collagen which is the main organic component of dentine.^{8,9}

The mechanical action of NaOCl causes biosynthetic alteration of cell metabolism and destroys phospholipid,

forming chloramine that interfere with cell metabolism, oxidation action by inactivation of irreversible bacterial enzymes and lipid and fatty acid degradation. NaOCl can cause unpleasant taste, tissue toxicity, unable to eliminate inorganic smear layers, often causing allergies. The use of NaOCl that penetrates the apical foramen can lead to eyes such as burning, allergic reactions, enter the maxillary sinus, swelling, pain in the apex area, nerve damage and airway obstruction. In addition, the residual NaOCl may also interfere with the resin bonding polymerization because NaOCl causes oxidation of the dentin matrix component, forming a free radical when activated by resin-adhesive rays, forms premature chains so that polymerization occurs imperfectly. Sodium hypochlorite has been used as one of the most effective irrigation materials against broad spectrum bacteria and dissolves necrotic tissue. Benefit as a disinfectant by releasing chloramines.⁸

Sodium hypochlorite is the most widely used endodontic irrigant as it is an effective antimicrobial and has tissue-dissolving capabilities. It has low viscosity allowing easy introduction into the canal, an acceptable shelf life, is easily available and inexpensive. The antibacterial and tissue dissolution action of hypochlorite increases with its concentration, but this is accompanied by an increase in toxicity. NaOCl was introduced by Dakin when he used 0.5%-0.6% NaOCl solution (Dakins solution)

for the irrigation of wounds in soldiers during World War I. Concentrations ranging from 0.5% - 5.25% are widely used. However for clinical use concentrations 2.5% . Mechanism of action of sodium hypochlorite is that the free chlorine in NaOCl dissolves vital and necrotic tissue by breaking down proteins into amino acids.^{4,9}

Sodium hypochlorite has been demonstrated to be an effective agent against a broad spectrum of bacteria and to dissolve vital as well as necrotic tissue. Beside their wide-spectrum, nonspecific killing efficacy on all microbes, hypochlorite preparations are sporicidal, virucidal, and show far greater tissue dissolving effects on necrotic than on vital tissues. However studies have proven its toxic effects on vital tissues as well. The pH level of NaOCl varies from 11-12. Decreasing the concentration of the solution reduces its toxicity, antibacterial effect and ability to dissolve tissues. Increasing the temperature of a less concentrated solution helps in improving its effectiveness . Several studies revealed that warmed NaOCl solutions dissolved organic tissues better and exhibited greater anti microbial efficacy compared to non heated solutions. The major disadvantages of this irrigant are its cytotoxicity when injected into periradicular tissues, foul smell and taste, ability to bleach clothes and ability to cause corrosion of metal objects. In addition, it does not kill all

bacteria nor does it remove all of the smear layer. It also alters the properties of dentin. Sodium hypochlorite is generally not utilized in its most active form in a clinical setting. For proper antimicrobial activity, it must be prepared freshly just before its use. In the majority of cases, however, it is purchased in large containers and stored at room temperature while being exposed to oxygen for extended periods of time. Exposure of the solution to oxygen, room temperature and light can inactivate it significantly. Most of the hypochlorite accidents are due to incorrect determination of endodontic working length, iatrogenic widening of the apical foramen, lateral perforation, or wedging of the irrigating needle. Clearly, precautions must be undertaken to prevent such mishaps.^{6,7,11}

Chitosan

Chitosan is a derivate of chitin in the presence of N-deacetylation which is a natural biopolymer, mainly as a composite crustacea, functional structure wall and low level animal. Chitosan was first discovered by Router (1859) .the cytine is common in anthropods, fungi and yeasts in chitin fungi associated with polysaccharides, whereas in chitin animals associated with proteins (Trimurni et al, 2006). Chitosan is soluble in an acid solvent such as formic acid, lactic acid, citric acid and hydrocolic acid. Chitosan is insoluble in water, alkaline and dilute mineral acids except under certain conditions, ie in the presence of

a number of acid solvents. The presence of binding amino and hyrosyl groups causes chitosan to have high chemical reactivity and contribute to the cation polyelectrolyte properties so that it can act as a replacement amino (Trimurni et al, 2006). In addition, chitosan interacts with other organic substances such as ptoein so that chitosan is relatively widely used in the field of health kaena have special properties biocompatibility, biogradability, bioadhesi, not toxic and bioactive, does not impose immunological reactions, and does not cause cancer (Sugita, 2009).^{2,5}

Chitosan has a broad spectrum with high activity kills gram-positive bacteria because it is able to alter the premeability of bacterial cells resulting in cell death. Chitosan also showed a lower toxicity to mammalian cells (Pimenta, 2012).^{2,8}

DISCUSSION

This study claims that the vulnerability of bacteria varies in degrees, to a wide range of antimicrobial agents and that the time of exposure could be decisive. NaOCl seemed to be most effectual followed by CHX and IDI while NaCl was not effective. Streptococcal species has been habitually caught up as a survivor of root canal treatment regimes Regardless of the occurrence of this species in continual infections, it is not normally utilized in antimicrobial efficacy tests. Briseno et al used *Streptococcus mutans* in infective extracted tooth and compared the efficiency at different concentrations of NaOCl

with and without ultrasonic activation. Even though there were huge reductions in figures, the microbes were not entirely eliminated and the full irrigation time was not given. Siqueira et al matched the effectiveness of 2.25% NaOCl and 0.2% CHX using an agar diffusion test along with three streptococci. Conclusions were made that NaOCl was somewhat extra efficient but dependent relatively on the species being tested. The outcome of iodine potassium iodide irrigation cannot be substantiated because no studies were reported. Nonetheless, Molander et al used 5% iodine potassium iodide as dressing and established that the most prime group of relentless organisms was streptococci, while *S. intermedius* was not recognized between them. The speculation is that individual species may counter in a different way to a range of antimicrobial agents. Evaluation and comparison of the effectiveness of NaOCl and CHX irrigants on natural root canal infections in extracted teeth is done in different number of studies Ringel et al compared the efficiency of 0.2% CHX and 2.25% NaOCl in 30 teeth, each with pulp necrosis and peri-apical lesions .It was established that NaOCl was more effectual and discrepancy was accredited to its tissue dissolving capacity. Kuruvilla and Kamath established that CHX minimized the number of microbes by almost 70% compared with 60% by NaOCl. There was a decline of 85% when both solutions were used interchangeably. Furthermore, Delany et al and Leonardo et al explored that CHX by strength 0.2%

and 2% were helpful in plummeting bacterial counts when used as irrigants. Similarly, they further concluded that these strengths were useful in decreasing inter appointment bacterial activity. The possible consequence of disrupting the connections between bacteria that sustain some species clearly has an advantageous effect past that evident from the antimicrobial tests on individual species.

(Zeeshan Qamar and Tayyaba Fatima)⁹

There are several reports that chitosan has antibacterial effect against *E. faecalis*. The antibacterial effect of chitosan nanoparticles to *E. faecalis* depended on the application time and concentration. In addition, chitosan combinations with EDTA and chlorhexidine gluconate gel enhanced antibacterial activity against *E. faecalis*. However, these chitosan combinations could not provide a complete bactericidal effect against *E. faecalis*. These findings were similar to our experimental results. Furthermore, chitosan-citrate solution resulted in significantly greater reduction of CFU/ml than 10% citric acid (60.7% reduction) at 5 min. *E. faecalis* was found to be resistant to acid and alkalis. It was observed that the antibacterial effect of the pH of chitosan-citrate solution was weak, whereas the influence of the antibacterial effect of chitosan was strong against *E. faecalis*. Therefore, it is suggested that chitosan enhanced the antibacterial activity of chitosan-citrate solution. Because chitosan is bacteriostatic rather than **bactericidal**, the most acceptable model is

the interaction between positively charged chitin/chitosan molecules and negatively charged microbial cell membranes. In this experiment, the pH was adjusted to 3.5, but a further study is necessary to experiment with a range of buffering capacity of citric acid. Further, we evaluated the effect on only planktonic *E. faecalis* in this experiment, it is necessary to evaluate the procedure using a biofilm. Shigenori Suzuki, et.al.⁵

Found MTAD was effective in killing *E. faecalis* up to 200 x dilution whereas NaOCl ceased to exert its antibacterial activity beyond 32 x dilution. Shabahang & Torabinejad (2003) showed that the combination of 1.3% NaOCl as a root canal irrigant and MTAD as a final rinse was significantly more effective against *E. faecalis* than the other regimens. Newberry et al.(2007) showed that MTAD in conjunction with 1.3% NaOCl was effective in completely eliminating growth in 7 of 8 strains of *E. faecalis*. Similar to these results, Davis et al.(2007) found that MTAD showed significantly more zones of microbial inhibition for *E. Faecalis* than NaOCl, Chlorhexidine and Dermacyn (a superoxidized water). The results of the our study done agree with these in - vitro studies and indicate that MTAD has better antibacterial activity than 2.5% sodium hypochlorite and 2 % Chlorhexidine. However there are certain studies that display less than optimal antimicrobial activity of MTAD. Kho & Baumgartner (2006) demonstrated no

difference in antimicrobial efficacy for irrigation with 5.25% NaOCl/15% EDTA versus irrigation with 1.3% NaOCl/MTAD in the apical 5 mm of roots infected with *E. faecalis*. Dunavant et al.(2006) found that 6% and 1% NaOCl were significantly more efficient in eliminating *E. faecalis* biofilms than other irrigants such as 2% CHX, MTAD and commercial preparations of EDTA. A study by Baumgartner et al.(2007) found no growth of *E. faecalis* in root canals irrigated with 5.25% NaOCl/ 15% EDTA, whereas 50% of the canals irrigated with 1.3% NaOCl/MTAD demonstrated growth of *E. faecalis*. Less than optimal antibacterial effect of MTAD in these studies could be because of the difference in simulated clinical conditions, methodology, microbial sampling procedures or because of difference in the study model

(Ramta Bansal, et.al. Kaur 2013)⁴

The results clearly demonstrated that the action of test irrigants could reduce the number of bacterial cells from the root canal. Bacterial reduction was significantly superior when NaOCl was used as irrigant. In addition to the mechanical effects, NaOCl possesses chemical effects that help in the elimination of bacteria from the root canals. The present study demonstrates the anti-bacterial efficacy of chitosan almost equivalent to 3% NaOCl, which may well be replaced by this potential animal extract as endodontic irrigant to overcome the deleterious effects of the conventional irrigants (NaOCl and chlorhexidine) on

dentine. NaOCl is known to be cytotoxic to tissues and a need for replacement with a more biocompatible irrigant is necessitated. (Pankaj Yadav, et al, Yadav 2017)²

CONCLUSION

The aim of the study was to evaluate the antibacterial and cytotoxic effect of Chitosan a new alternative when used as root canal irrigant and to compare its action to the commonly used root canal irrigants sodium hypochlorite. Further studies are required to prove the efficiency of chitosan in clinical situations.

REFERENCES

1. Noopur Kaushik, et al, Endodontic Antimicrobial Efficacy of Endodontic Irrigants against *Enterococcus Faecalis* and *Escherichia Coli*: an in vitro study, international journal of clinical pediatric dentistry;2013;6(3):178-182
2. Pankaj Yadav, et al, Evaluation of Antimicrobial and Antifungal efficacy of Chitosan as endodontic irrigant against *Enterococcus Faecalis* and *Candida Albicans* Biofilm formed on tooth substrate, J Clin Exp Dent. 2017;9(3):e361-7
3. Suchitra U, Kundabala M, *Enterococcus Faecalis* : an Endodontic Pathogen, Department of Conservative Dentistry, Manipal College of Dental Sciences, Mangalore .

4. Ramta B, et al, A Comparison of The Antibacterial Efficiency of MTAD (Mixture of Tetracycline, Citric Acid And Detergent), 2,5% Sodium Hipoklorit and 2% Chlorhexidine Root Canal Irrigants Againsts Enterococcus Faecalis In Root Canals Of Single Rooted mandibular Premolar-An In Vitro Study. IOSR Journal Of Dental and Medical Science, 2013;5(3):pp 47-53
5. Shigenori S, et al, 2014, The Study of Chitosan –Citrate as a Root canal Irrigant : A Preliminary Report, Oral Hygiene & Health, 2:4
6. Aniketh T, et al, 2015, Root Canal Irrigants and Irrigation Techniques : A Review, Journal of Evolution of Med and Dent , vol. 4 april 02,
7. Abraham S, et al, Endodontic Irrigants : A Comprehensive Review, Journal of Pharmaceutical Sciences and Research, vol. 7(1),2015, 59
8. Novelin, Y O dan Trimurni, A.2016. Pengaruh Bahan Irigasi Natrium Hipoklorit, EDTA, dan Larutan Kitosan Molekul Tinggi dengan menggunakan Protaper Universal dan iRace File *Rotary* terhadap Kebersihan Smear Layer Intrakanal pada sepertiga Apikal Saluran Akar (Penelitian *In vitro*). Skripsi. Medan: USU
9. Zeeshan Q, Tayyaba F, , Antibacterial Efficacy of Various Root Canal Irrigants Used In Endodontics : An *in vitro Study* to compare, Entomology and Applied Science Letters, 2016,3(5):104-108.
10. Rashmirekha Mallick, et al, *Enterococcus Faecalis* :A resistant microbe in endodontics, Internasional Journal of Contemporary Dental and Medical Review (2014),Article ID 011114,2 Pages.
11. Kazim Mirza, et al, A Review of Root Canal Irrigants in Endodontic Practice-Part 1, EC Dental Science 5.5 : (2016)1182-1189.
12. Vindania R, et al, *enterococcus faecalis* infection in root canals-boat-derived or exogenous source?, letters in applied Microbiology ISSN 0266-8254,2010.
13. Haapasalo M, Endal U, Zandi H, Coil JM. Eradication of endodontic infection by instrumentation and irrigation solutions. Endod Tropics 2005;10(1):77-102.
14. Arias-Moliz MT, Ferrer-Leque GM Espigares-Garcia M, Baca P. Enterococcus faecalis biofilms eradication by root canal irrigants J Endod 2009;35(5):711-714.
15. Zehder.M-Root canal irrigants-JOE-2006;32:389-98
16. Sirtegs,Waltimo T, Schaetzle M, Zehnder M. The effect of temperature on sodium hypochlorite short term stability, pulp dissolution capacity and anti microbial efficacy JOE;31:669-71.

EFFECT OF CURRENT LED LIGHT CURING ON POLYMERIZATION OF DIFFERENT PHOTOINITIATOR OF COMPOSITE RESIN :

A LITERATURE REVIEW

Juliana Siregar * Dennis Rasinta Tarigan*****

*** Resident of Specialist Program of Conservative Dentistry**

****Lecturer of Specialist of Conservative Dentistry**

Faculty of Dentistry, University of Sumatra Utara

Jln . Alumni No.2 Kampus USU Medan 20155

ABSTRACT

The success of composite curing generally depends on the characteristics of the composite (photoinitiator, filler type, shade, and translucency), the intensity and spectral output of the light-curing unit (LCU), and the mode of curing. Polymerization of Resin Based Composites (RBCs) initiated by a light curing unit activating photoinitiators. Different RBCs require different light energy levels for proper curing. Manufacturers are now producing RBCs with more than one initiator and not all of these will be properly polymerised with blue LED lights. An added problem is that manufacturers do not always indicate the type of photoinitiators in their materials. Efficient light polymerization requires that the corresponding wavelengths match the maximum absorption of the photoinitiator of the material. This article discusses the effect of current LED light curing unit (LCU) on polymerization different photoinitiator of composites resin.

Keywords: Polymerization of Composite Resins, LED Light curing, Photoinitiator.

INTRODUCTION

Light emitting diode (LED) light curing units are becoming increasingly popular in dental practice. Advances in adhesion and polymerization, coupled with new materials and conservative or 'minimal intervention' restorative treatments, have revolutionized dental practice since the introduction of light-cured composites on to the market 35 years ago. Operator proficiency, the composite material formulation (shade and opacity,

initiator system, resin matrix composition, filler type and loading, etc), the adhesive system and the polymerization method all have a strong influence on the outcome.¹

Dental composites are important materials employed in restorative procedures. However, composite resins still present some limitations, such as uncomplete polymerization. Efficient light polymerization requires that the corresponding wavelengths match the maximum absorption of the photoinitiator

of the material. In addition to technological improvements in composite resins, light-curing units have also attained better properties for complete restoration polymerization.²

Despite their popularity, the use of halogen light-curing units (LCUs) to polymerize dental composites has several setbacks over time. The halogen bulbs, reflector, and filter degrade over time due to high operation temperatures and heat produced, resulting in a limited effective lifetime of about 40 to 100 hours. Current LCUs using blue light emitting diodes (LEDs) have shown advantages, namely lower temperature, long lifetime, no filters, resistance to shock and vibration and narrow spectral output (440-490 nm) that falls within the camphorquinone (CQ) absorption spectrum.³

Polymerization of Resin Based Composites (RBCs) initiated by a light curing unit activating photoinitiators. Different RBCs require different light energy levels for proper curing. Manufacturers are now producing RBCs with more than one initiator and not all of these will be properly polymerised with blue LED lights. An added problem is that manufacturers do not always indicate the type of photoinitiators in their materials.⁴ Because its is relatively new in dentistry, the effect of LED light curing on polymerization is not well reported in the dental literature. The aim of this paper was to analysis effect of current LED

light curing on polymerization of different photoinitiator of composite resin.

LED Light curing units (LAUs)

The initial studies on LEDs started in the 1960s with the first combinations of gallium, arsenic and phosphorus (GaAsP). This set-up produced very weak emissions in the red spectrum (with a wavelength around 655 nm). In 1962, the invention of a synthetic red LED provided a new type of light that was robust, efficient and suitable for portable battery powered operation. In 1995, blue LEDs producing 4.8 mW were reported, representing more than a 600-fold increase in power compared with silicon carbide technology. Now LED light curing can be divided into four time periods or generations.¹

1. First-generation (1999–2002) and second generation LED lights (2002–2004)

First and second-generation LED lights produce a narrow spectral output that peaks in the 450 nm to 470 nm range. These wavelengths are effective when polymerizing resins that contain camphorquinone, but wavelengths in the 450 nm to 470 nm range are not very effective at polymerizing resins that use alternative photoinitiators, sensitizers, or coinitiators that are sensitive to lower wavelengths. Camphorquinone is yellow, which makes it difficult to produce translucent or light shades of composite using camphorquinone as the photoinitiator. Consequently, to achieve

adequate polymerization, some dental resins require the lower wavelengths delivered by QTH lights, plasma arc lights, or the new third-generation LED curing lights. First-generation LED curing lights usually contain multiple low power LEDs, but these lights are unable to cure resin composites as well as a QTH light. Second-generation LEDs use 1 high power LED to provide a greater light output, but the spectral bandwidth remains narrow compared with a QTH light.^{1,5}

2. Third-generation LED lights (2004–2011)

Third-generation LED lights use a combination of LEDs to produce a broader spectral output. These lights may polymerize a broader range of resins than the second-generation curing lights. The irradiance and power output of third-generation LED LCUs exceed 1.100 mW/cm² and 8 W.⁶ Consequently, to achieve adequate polymerization, some dental resins require the lower wavelengths delivered by QTH lights, plasma arc lights, or the new third-generation LED curing lights. In addition to receiving light at the correct wavelengths, a photoactivated resin must receive sufficient total energy (J/cm²) to adequately polymerize.⁵ The third generation responded to the diverse needs of daily restorative and orthodontic practice. They could cure – camphorquinone or CQ + tertiary amine, 1-phenylpropane-1,2-dione or PPD and trimethylbenzoyl-diphenyl phosphine oxide or Lucerin® TPO. Third-generation LEDs are actually

a combination of several basic LEDs, each emitting at identical, complementary or different wavelengths.¹

With a fast-curing (variously called high power, turbo or plasma emulation mode) menu, at these power levels, very short exposure of 3–5 sec can be used for sealants, multi-layering techniques, bonding brackets, tacking indirect restorations or bleaching. There is also pulse-curing which allows 8–10 seconds recovery in pseudo-fast curing (as with laser polymerization). Clinicians are able to adapt the irradiation mode and time to the material they are using and their restorative technique. Valo® from Ultradent uses LED chips at central wavelengths of 405 nm, 445 nm and 465 nm to cure all proprietary photo-initiators. The circuitry of this Polywave third-generation unit allows standard, high power and ‘plasma irradiation modes’ which are stated to offer 1,000 mW/cm², 1,400 mW/cm² and 3,200 mW/cm², respectively, for 20 s, 4 s and 3 s maximum irradiation times, respectively.¹

3. Toward Fourth-generation

LED units

Scanwave by MiniLed™ (Acteon) could be considered as the first fourth-generation LED light to come to the market. As well as incorporating many of the ideal features of the best third-generation lights, other significant improvements have been incorporated into its design.⁷ It features patented wavelength scanning technology incorporated into its mode selection, allowing the dentist to choose the most

appropriate spectral output mode and radiation time for any possible material and clinical situation. It has four different diode wavelengths, the most of any dental LED LAU to date, offering broad spectrum curing in 'Full Scan' mode for all resin-based materials, irrespective of their photo-initiator chemistry.⁷

Resin based Composites (RBCs)

Composites are essentially made of three basic components: resin based organic matrix, nonorganic filler particles or nonorganic dispersed phases and organic-nonorganic bonding agent, silane. Organic matrix is made of monomers, that, due to polymerization, bond into polymers and form a three-dimensional network, which is filled with fillers, and in this way the physical and mechanical properties of the network are improved. In addition to the mentioned components, composites contain smaller amounts of additional materials which contribute to the overall material quality, such as: polymerization initiators, various additives, stabilizers, inhibitors, pigments etc.⁸

Resin-Based Composite (RBC) is widely used in Dentistry to restore anterior and posterior teeth. There have been many advances in RBCs development to improve their clinical success rate and overcome the many disadvantages of the first materials. These materials are cured by visible light, and light curing units have also undergone considerable development. Recently, bulk-fill composite materials were introduced to

be placed in the cavity in bulk, claiming replacement of the traditional layering technique.⁹

Two types of bulk-fill materials are available in the market, viscous and flowable. The flowable BFM's have been recommended for use in low load bearing areas and was aimed to place in one layer of 4 mm thickness to reduce polymerization stress. It is considered mandatory to cover flowable materials with a 2 mm layer of conventional RBC posteriorly, because their modulus elasticity and hardness are reduced. The manufacturers of these materials stated some changes in composition in order to achieve the adequacy of bulk curing.⁹

Composite materials are composed of polymerizable organic resin monomer, inorganic fillers, and photoinitiators to initiate the polymerization reaction. Silane coupling agent is also added to bind the fillers to the matrix. When polymerized, the monomers convert from a liquid phase to a highly cross-linked solid polymer. Polymerization is initiated by visible light. Typically the base monomer is a dimethacrylate; bisphenol-A-glycidyl methacrylate (Bis-GMA) or urethane dimethacrylate (UDMA). These are viscous materials and other less viscous dimethacrylates such as triethylene glycol dimethacrylate (TEGDMA), ethyleneglycol dimethacrylate (EGDMA), hydroxyethyl methacrylate (HEMA) or bisphenol-A-dimethacrylate (Bis-DMA) are usually incorporated to reduce the

effect of its high viscosity. A reduction in the viscosity of the material allows the incorporation of fillers.⁹

Photoinitiator Of Composite Resin

1. *CQ (camphorquinone) /tertiary amine photoinitiator system*

Since its invention by Dart and Nemcek in 1972 the most common photoinitiator system in RBCs is the camphorquinone/ tertiary amine (CQ/TA). The peak sensitivity of CQ is near 470 nm in the blue wavelength range.³ Even though CQ/TA systems have good acceptance, they present some disadvantages; used in very small amounts (ppm), the yellow-colored CQ influences the composite colour. Another major problem is that the α -diketone group, derived from CQ, has peak absorption in the visible range, resulting in fast photopolymerization under ambient light (fluorescent lamps and dental lamps) and giving a short therapeutic operation time. To solve the problems of CQ/TA, other initiators are now incorporated in RBCs, for example, phenyl-propanedione (PPD) and diphenyl (2,4,6-trimethylbenzoyl) phosphine oxide (TPO) and Ivocerin.⁴

2. *Lucirin® (TPO) 2,4,6-trimethylbenzoyldiphenylphosphine Oxide*

TPO is an acyl phosphine oxide. It has been shown that TPO results in higher degree of conversion (DC) than CQ/TA when is cured with halogen, or polywave LCUs; in addition, TPO exhibits greater colour stability compared to CQ/TA.

That is the reason TPO may be especially useful in extra white shades of RBCs, often required in bleached teeth since it eliminates the unwanted yellow effect of CQ/TA. Its absorption spectrum extends from 380nm to about 425 nm.^{4,9}

3. *PPD (1-phenyl-1,2-propanedione)*

Phenyl Propanedione (PPD) is also a photoinitiator, its absorption spectrum extends from below 350 nm to approximately 490 nm. PPD can be used alone, or in combination, with CQ and at 410 nm has a shorter absorption peak than CQ. Adding PPD to composite materials has also shown promising results such as a lower rate of polymerization stress without affecting the final degree of conversion. In similarity to TPO, the presence of PPD in a RBC has been found to result in less yellowing when compared to CQ/amine materials.^{4,9}

4. *Ivocerin*

Ivocerin is a new initiator that features a high absorption coefficient and is therefore highly effective even if used in only small quantities. It is a germanium-based initiator and complements the current range of standard photoinitiators and allows for increased quantum efficiency and is therefore far more effective than CQ/AT or TPO. This photoinitiator is said to produce highly reactive polymerization and only very small amounts are required. Thus photoinitiator colour (compare CQ/TA system) is not a problem and allows it to be used in tooth-coloured materials with enamel like translucency.⁴

Polymerization Of Composite Resins

Light-cured composite materials set via a free-radical polymerization reaction which gives clinicians sufficient time for handling the material prior to curing. The polymerization process relies on the presence of a photoinitiator in the RBC which is sensitive to the blue light of the LCU, and a co-initiator which does not absorb light but interacts with the photoinitiator to initiate the polymerization reaction. On absorbing the light photons, the photoinitiator molecule becomes excited and forms free radicals which in turn trigger the polymerization reaction by converting the carbon to carbon double bond in the monomer molecules to the polymer network.⁹

Polymerization occurs through a series of chemical reactions, by which the macromolecule, or the polymer, is formed from a large number of molecules which are known as monomers. A reduction in intermolecular distance from 0.3-0.4 nm to 0.15 nm on polymerization of resin composites was reported.⁸

During polymerization, composites go through 3 phases referred to as: pre-gel phase (initial polymerization); polymerization phase; and post-gel phase. In the first phase, composites are in the viscoelastic phase and are susceptible to deforming. The material presents a low modulus elastic limit, which permits permanent deformation through the sliding of the forming polymeric chains. Volumetric shrinkage in this phase is

referred to as “pre-gel” or “non-rigid” shrinkage.¹⁰

In the polymerization phase, macromolecules are formed and the macromolecular movement of the organic matrix is inhibited. In this phase, composites no longer tend to deform. In the post-polymerization phase, the composites are in a rigid state, but still shrink, though the conversion degree does not change significantly. The shrinkage observed in the post-gel phase is clinically relevant, as the material is no longer capable of compensating for contraction by deformation, which results in the development of stresses.¹¹

DISCUSSION

Since the spectral output of the LEDs is concentrated in the blue wavelength range, high power LED curing lights are capable of polymerizing some resins as well as, or better than, some QTH lights. LED curing units are characterized by a relatively narrow emission spectrum and lower heat generation than QTH curing units.¹²

Despite their popularity, the use of halogen light-curing units (LCUs) to polymerize dental composites has several setbacks. The halogen bulbs, reflector, and filter degrade over time due to high operation temperatures and heat produced, resulting in a limited effective lifetime of about 40 to 100 hours.³ Current LCUs using blue light emitting diodes (LEDs) have shown advantages, namely lower

temperature, long lifetime, no filters, resistance to shock and vibration and narrow spectral output (440-490 nm) that falls within the camphoroquinone (CQ) absorption spectrum.³

Halogen lights offer broad spectrum output for universal curing of photo-activated dental resins irrespective of initiator formulation, unlike second-generation monowave blue LED LAUs. Manufacturers have added violet as well as blue LEDs to some third-generation units to address this limitation. To date these polywave LED units do not possess the spectral spatial homogeneity of their QTH predecessors.⁷ The monowave high power blue LED is less effective at curing a PPD-based resin and it fails to polymerize a TPO-based resin at all whereas the full spectrum (405 to 480 nm) *Scanwave* cures all three resins effectively.⁷

Traditional light-cured hybrid resin composites cannot be bulk placed because of excessive polymerization shrinkage and the inability to adequately light-polymerize the resin beyond a 2 mm depth. Manufacturers prescribe bulk placement of packable composites was claiming decreased polymerization shrinkage due to increased filler loading and a reported depth of cure reaching 5 mm. However, certain packable resin composites demonstrated polymerization contraction similar to or higher than conventional hybrid composites. The completeness of polymerization of some packable resin composites was significantly less with bulk

cure in comparison to standard incremental polymerization.¹³

Use second-generation LED light for 20 seconds (delivering 12.2 J/cm² at 2 mm), it should be aware that not all composites will be cured as well as if they had been thoroughly cured by a conventional QTH curing light used for 40 seconds (receiving 25.3 J/cm² at 2 mm). However, because the combined top and bottom hardness value of each composite irradiated by the LED light for 40 seconds was greater than 80% of the hardness value achieved with a QTH light at both 15 minutes and 24 hours after irradiation, using second-generation LED light for 40 seconds should ensure adequate polymerization of most composites to a depth of 1.6 mm.¹⁴

One manufacturer has recommended an eight-fold difference in radiant exposure for curing their composites (6-48 J/cm²) based on product choice and shade selection. It is generally recommended that a 2 mm increment of composite should receive 12-36 J/cm² radiant exposure to be adequately polymerized, but energy quality and material properties are also crucial.⁷ The higher depth of cure of the bulk fill materials may be due to the incorporation of more efficient initiator systems and higher translucency of composites.⁸ Many researchers have suggested the use of "incremental layering techniques" for resin-composite restoration to reduce the polymerization shrinkage stress and cuspal deflection.¹⁵

Park et al reported the bulk filling technique yielded significantly more cuspal deflection than the incremental filling techniques, concluding that cuspal deflection resulting from polymerization shrinkage can be reduced by incremental filling techniques to obtain optimal outcomes in clinical situations.¹⁵ The potential disadvantages of BFMs can include possibility of more voids as placed in the mass of material, difficulty of making adequate contact areas, more stress as the entire mass polymerize at one time, and inadequate curing in the deepest part of the material.¹⁶

Different photoinitiators besides camphorquinone that absorb visible light at 410 nm are being added to the bulk-fill composites. If the curing light used has an output in the range of 450 nm to 490 nm, the material will not be cured adequately.¹⁷ In one *in vitro* study, X-tra fil® (VOCO) was investigated when placed in bulk and incrementally and cured with two LED LCUs. No difference was found in Vickers Hardness between the two techniques ($P>0.05$). In another *in vitro* study, the mechanical properties, VH and DC, of SureFil SDRTM was compared with other flowable composites when cured for 10, 20 and 40 seconds respectively. Variations between the materials when cured with different curing parameters was significantly different ($P<0.05$). The recommendation was to cure the 4 mm bulk increments for 20 seconds when the total energy of 24 J/cm² was delivered to

the top surface, which was higher than the manufacturers' recommendations.⁹

The traditional photoinitiator system, which includes camphorquinone and a tertiary amine (CQ/amine) presents some disadvantages. The CQ absorbs light with a wavelength between 400 and 500 nm, with visible range maximum absorption peak at 468 nm. It presents an intense yellow coloration and requires a co-initiator molecule to optimize the polymerization reaction, which unfortunately may suffer oxidation with time, leading to higher intrinsic discoloration.¹⁸ If the RBCs contain CQ plus TPO and/or PPD, then light in both the blue (420-540 nm) and violet (360-420 nm) ranges are required. Not all curing lights deliver the required colour of light and using a spectrally mismatched combination of LCU and RBC is possible. QTH LCUs have a broad spectral range corresponding with the broad spectral absorption of CQ. Moreover, its spectral range extends into the violet range and so it can activate photoinitiators such as TPO if they were incorporated in the RBCs. The emission spectrum of commercially available single peak LCUs (420-490 nm) is limited to be effective in activation CQ/TA but not so useful when TPO type photoinitiators are present.⁴

To overcome the CQ/amine limitations, alternative photoinitiator systems which do not require a co-initiator, such as the phosphine oxide derivatives diphenyl (2,4,6-trimethylbenzoyl) phosphine oxide (TPO) and phenylbis

(2,4,6-trimethylbenzoyl) phosphine oxide (BAPO) could be a viable solution. These molecules are sensitive to wavelengths shorter than 420 nm. This could restrict the use of first and second generations of light-emitting diode (LED) sources, which produce only in the 450 - 470 nm wavelength range. Initially proposed to improve the esthetic of conventional resin composite restorations, these systems require large spectrum light sources, like quartz-tungsten halogen lamps or third generation LED. A previous study has demonstrated the potential use of alternative photoinitiators systems applied to monomeric blends employed in self-etch adhesive systems.¹⁸

The emission spectrum of commercially available single peak LCUs (420-490 nm) is limited to be effective in activation CQ/TA but not so useful when TPO type photoinitiators are present.⁴ In an attempt to overcome the problem of the emission-absorption mismatch of TPO and PPD containing materials, dual peak LED LCUs have been introduced. They have a primary emission peak at around 460 nm to cover the absorption spectrum of the CQ/TA and an additional peak at around 400 nm to match TPO and PPD. Not all of the photoinitiators have the same sensitivity. TPO is about five times more sensitive than CQ.⁴

Giorgi et al also found differences in the degree of cure between composites cured with 2nd and 3rd generation LEDs, with better results for 3rd generations LEDs

in combination with more translucent composites due to the overlap of emission spectrum with emission absorption of the composite resin. Also recently, Santini et, al. proved that the use of polywave LEDs significantly improves both DC (degree of conversion) and KHN (Knoop microhardness) of materials containing TPO.¹⁹ TPO results in higher degree of conversion (DC) than CQ/TA when is cured with halogen, or polywave LCUs; in addition, TPO exhibits greater colour stability compared to CQ/TA. That is the reason TPO may be especially useful in extra white shades of RBCs, often required in bleached teeth since it eliminates the unwanted yellow effect of CQ/TA.⁴

Richard B T Price et al reported for all 12 composites tested, the third-generation LED mode produced composites that were as hard as when the second-generation mode was used ($P = .01$). In 7 of the 12 resin composites, the top surface was harder when the third-generation LED curing mode was used ($P = .01$). Because the composites received the same total energy in both light modes and only the wavelengths were different, the results support previous research that reported that in addition to receiving sufficient total energy (J/cm^2), a photoactivated resin must receive light at the correct wavelengths to adequately polymerize. This study shows that it is not just the shade of the composite, but also the photoinitiator within the composite that is important.⁵

CONCLUSION

Resin composite has undergone continuous developments like changes in the fillers and photoinitiators. The manufacturers are producing materials with different initiators and not all of these materials could be properly polymerized with blue LED lights. Third generation LED unit completely cures all the commercially available filling composites and adhesives such as bulk fill materials (BFMs). But first-generation and the second generation LED lights had some disadvantages. The potential disadvantages of BFM can include possibility of more voids as placed in the mass of material, difficulty of making adequate contact areas, more stress as the entire mass polymerize at one time, and inadequate curing in the deepest part of the material with third generation LED unit. Despite third generation LED unit relatively expensive. Therefore, more researches are needed about effects of second generation LED unit and third generation LED unit on polymerization of BFM with the advance photoinitiator.

REFERENSI

1. Pelissier B, Jacquot B, Palin W M and Shortall AC. Three Generations of LED Lights and Clinical Implications for Optimizing their Use. 1: From Past to Present. Dent Update 2011; 38: 660–70.
2. Micali B, Basting RT. Effectiveness of composite resin polymerization using light-emitting diodes (LEDs) or halogen-based light-curing units. Braz Oral Res 2004;18(3):266-70.
3. Lopes L.G, Franco E.B *et, al.* Effect Of Light-Curing Units And Activation Mode On Polymerization Shrinkage and Shrinkage Stress of Composite Resins. J Appl Oral Sci. 2008;16(1):35-42.
4. Santini A. Photoinitiator in Dentistry: A Review. Primary Dental Journal 2013; 2(4):30-3
5. Segreto D R, Naufel FS, Brandt WC *et, al.* Influence of photoinitiators and light sources on the degree of conversion of experimental resin cements. Braz Dent Sci. 2015; 18(2); 65-72.
6. Price R.B.T, Felix C A, Andreou P. Third-generation vs a Second-generation led Curing Light: Effect on Knoop Microhardness. Compendium of Continuing Education in Dentistry.2010; 31 (5): 1-9.
7. A. Wahbi Mohammed , Aalam F A, Fatiny F. I *et al.* Characterization of heat emission of light-curing units. The Saudi Dental Journal (2012) 24, 91–8.
8. Milosevic M. Polymerization mechanics of dental composites - Advantages and Disadvantages. Procedia Engineering 149 (2016): 313 – 20.
9. Ikemura K, Endo T. A review of the development of radical photopolymerization initiators used

- for designing light-curing dental adhesives and resin composites. *Dental Materials Journal* 2010; 29(5): 481–501.
10. Luis Felipe J. Schneider, Larissa Maria Cavalcante, Nick Silikas. Shrinkage Stresses Generated during Resin-Composite Applications: A Review. *Journal of Dental Biomechanics* 2010; 1-14
 11. Shamy HE, Saber MH, Dorfer CE, Badrawy WE, Loomans BAC. Influence of Volumetric Shrinkage and Curing Light Intensity on Proximal Contact Tightness of Class II Resin Composite. *Operative Dentistry*. 2012; 37(2); 205-10.
 12. Sayed MM, Ian Meyers. Comparison of Depth of Cure, Hardness and Heat Generation of LED and High Intensity QTH Light Sources. *European Journal of Dentistry*. 2011;.5; 299-304.
 13. Prachi Singh, Nitesh Kumar et. al. Overview and recent advances in composite resin:
 14. A review. *International Journal of Scientific Study*; 2015; 3(9): 169-172.
 15. Richard B.T, Corey A. F, Pantelis A. Evaluation of a Second-Generation LED Curing Light. *Can Dent Assoc* 2003; 69(10):666.
 16. Brigitte Zimmerli, Matthias Strub, Franziska Jeger, Oliver Stadler, Adrian Lussi. Composite materials: Composition, properties and clinical applications. *Schweiz Monatsschr Zahnmed* 2010; 120: 972-9.
 17. Soo Kyung J, Dong Ae K, Hyo Jin G, Hae Hyoung L. Investigation of the correlation between the different mechanical properties of resin composites. *Dental Materials Journal* 2013; 32(1): 48–57.
 18. Deniz Cakir, Robert Sergeant, John O. Burgess. Polymerization Shrinkage: A Clinical Review. *Inside dentistry*. 2007; 3(8).
 19. Anshu M Chandurkar¹, Sandeep S Metgud², Shaikh Shoeb Yakub *et al.* Comparative Evaluation of the Effects of Light Intensities and Curing Cycles of QTH, and LED Lights on Microleakage of Class V Composite Restorations. *Journal of Clinical and Diagnostic Research*. 2014; 8(3): 221-4.
 20. Aldossary M, Santini A. Resin-Based Composite and LCU-related Factors Affecting the Degree of Cure. A Literature Review: Part 1. Resin-Based Composites. *Acta Medica Marisiensis* 2015;61(3):153-7.

CASE REPORT

APICAL CURETTAGE AND PREFABRICATED FIBER POST WITH RESTORATION OF CLASS IV COMPOSITE RESIN

Kiki Maharani Fadhilah*, Pribadi Santosa**

* Departement of Conservative Dentistry, PPDGS, Dentistry Faculty, GadjahMada University, Yogyakarta, Indonesia.

**Departement of Conservative Dentistry, Dentistry Faculty, GadjahMada University, Yogyakarta, Indonesia.

*Jl. Denta No. 1 Sekip Utara, Yogyakarta. E-mail : drgekikifadhilah@gmail.com

ABSTRACT

Background: Apical curettage is a component of endodontic surgical procedures. Failure of root canal treatment can make inflammatory processes in the periapical zone, which presents persistent periapical lesion. Conventional treatment may have negative effect over success requiring surgical intervention. Apical curettage recommended in periapical diseases treatment when conventional endodontic therapy does not obtain favorable outcomes. **Purpose:** To report a clinical case where an apical curettage was indicated due to failure in conventional endodontic treatment. **Case:** Clinical case report of a tooth with history of unsatisfying conventional endodontic treatment and since then the lesion had persisted. It was due to overfilling on obturation using guttapercha on upper front teeth. Patient has complained about the upper left front teeth that hurt when teeth clashed or bit food. Clinical examination showed a positive percussion, negative palpation, negative vitality, and negative mobility. Periapical radiograph examination showed a radiopaque image extending across the apical 3 mm long teeth surrounded by a radiolucent area of ± 4 mm in diameter. **Result:** The treatment was successful due to absence of lesion and painful symptoms and due to periapical bone repair. **Discussion:** Apical curettage is performed because of periapical lesion. Periapical lesion recover faster with surgical measures than conventional endodontic treatments. **Conclusion:** Apical curettage can be used in overfilling treatment of guttapercha obturation with periapical lesion.

Keywords : apical curettage, apical surgery, endodontic failure, endodontic surgery

INTRODUCTION

Traditional endodontic treatment aims to eliminate bacteria from root canal system and establish effective barriers against root recontamination. Failure factors in root canal conventional treatment are frequently related to the presence of residual bacteria

or reinfection in a previously disinfected canal⁽³⁾. The objective of apical surgery is to surgically maintain a tooth that primarily has an endodontic lesion that cannot be resolved by conventional endodontic re-treatment⁽⁷⁾. After failure of root canal treatment, apical surgery is the last

available resource to solve inflammatory processes in the periapical zone. This procedure consists on exposing the apex of the involved tooth and achieving curettage of periapical tissues. Ideally, this procedure should remove irritant agents from the root canal systems and periapical tissues⁽⁵⁾.

The success of endodontic surgery is quite high between 73-99% although only about 5% of all endodontic cases, commonly in a single rooted tooth of the jaw, maxillary posterior teeth when not close to the antrum, and posterior mandibular teeth if not close to the alveolar canal or foramen mentale. A dentist should be able to diagnose precisely and recognize the indications and contraindications of endodontic surgery. Not all teeth can be treated with endodontic surgery and even require interdisciplinary consultation in determining the treatment plan so the results achieved can be maximized⁽¹⁾. Apical curettage is an endodontic surgery that aims to maintain teeth with pulp and periapical disorders to remain in the oral cavity. In this case apical curettage aims to treat periapical lesions of the pulp necrosis which have been completed root canal treatment. The specialty of this case is that the tooth is maintained despite extensive periapical lesions, the treatment is successful because the lesion can be reduced so the tooth does not need to be removed and further treatment with restoration of the class IV cavity composite resin with prefabricated fiberpost⁽⁶⁾.

CASE REPORT

A 33 year old male patient attended in Endodontics Clinic of GadjahMadaUniversityon referrals from co-ass after root canal treatment. The patient complained of a constant pain in tooth number 21. He said tooth had previously been subjected to root canal treatment. Objective examination was positive percussion (pain), negative palpation, and negative mobility. Radiographic examination revealed extrusion of the endodonticsobturation material previously used in the root canal treatment towards the periapical space. Radiolucent area in periapical area, boundary not firm, 4 mm width and visible radiopaque image at root tip. It was suggested to re-treatment the tooth, targeting the full removal of filling material (Figure 1a and 1b). Nevertheless, during this procedure, it was not possible to remove material that extrude towards the periapical zone. Dental diagnosis 21 is pulp necrosis with a periapical lesion. The prognosis of this case is good because the teeth still can still be treated with root canal treatment, followed by apical curettage, and restoration of a class IV cavity composite resin with a prefabricated fiber post. Patient do not suffer from any systemic disease and thus support for apical curettage.

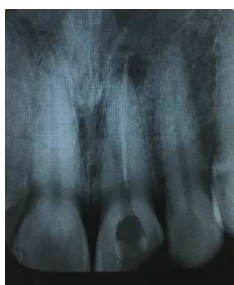

Figure 1a. Tooth 21 show that the obturation material overfilling in the apex with the radiolucent area around it.

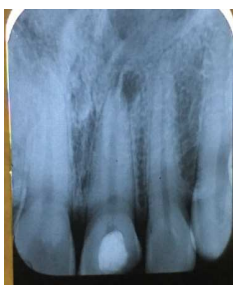

Figure 1b. Tooth 21 show that the obturation material has been removed leaving the overfilling material in the apex with the radiolucent area around it

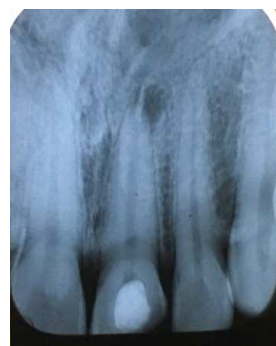

Figure 3. Tooth 21 shows that the obturation material overfilling in the apex with the radiolucent area around it.

CASE MANAGEMENT

On the first visit, the patient performed subjective and objective examination (Figure 2). Patient was referred to make X-ray photograph. Radiographic examination showed abnormalities in the apex of the teeth seen diffuse, radiolucent with a diameter of more ± 4 mm (Figure 3).

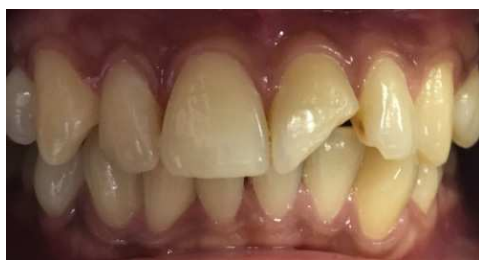

Figure 2. Preoperative clinical condition, fracture of the incisal with the cavity to the pulp

The patient was also explained about the surgical procedures caused by overfilling of endodontic obturation materials and periapical lesions will not heal with root canal treatment only. After the patient gets an explanation of the surgical procedure then the patient was told to sign the informed consent. Tooth 21 performed a root canal retreatment. General examination should be performed before apical curettage to determine the condition, risk or ability of the patient to the surgical procedure, including anesthesia. On the next visit, the patient was medicated with antibiotic and anti-inflammatory therapy before the surgical procedure. Surgical procedures to be performed on apical curettage include anesthesia, flap design, incision and desiccation, make access to the roots, curettage, flap reposition and suturing of the postoperative instruction, opening stitches and evaluation. After administering infiltration of local anesthesia, the mucogingival flap was raised with semilunar flap, this procedure purposed the aim of preserving gingival

papillae as well as acquiring adequate surgical access (Figure 4).

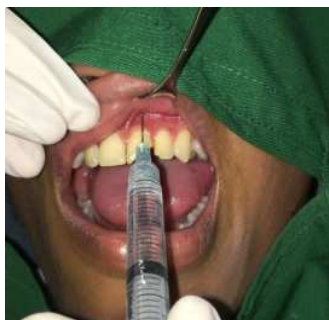

Figure 4. Tooth 21 anesthetized

Once the flap was raised, it was possible to view the buccal plate destruction of the affected tooth; this allowed easy location of the apex. Nevertheless it was necessary to perform a better access to the area that would be operated (Figure 5). Apical curettage was later conducted in order to remove granulation tissue as well as overfilling gutta-percha in the apex (Figure 6). Finally, the flap was repositioned, and the wound was sutured with 3.0 black silk (Figure 7). Periodontal pack was applied. During the surgical event, it was decided not to perform an apex incision.

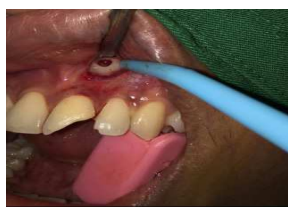

Figure 5. Curettage

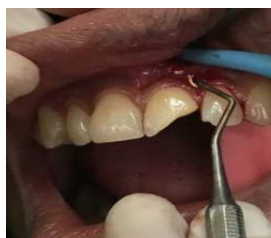

Figure 6. Make access to the roots

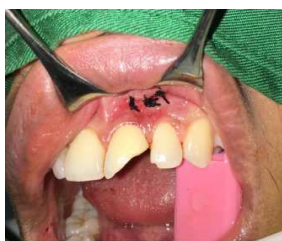

Figure 7. Flap reposition and suturing

Once the soft tissues has healed, the patient was remitted to the restorative dentistry clinic in order to complete dental rehabilitation. Control visit was scheduled 7 days later for evaluation of treatment outcome. The criteria of a successful apical curettage was evaluated after 6 months. Between the time of healing there were no complications on the surgical area, no pain or discomfort, no soft / bone tissue infection, and no mobile tooth. At a seven weeks recall visit, the patient's objective examination showed no swelling, periodontal pack was inseparable, the stitches looked well reconstituted, and the scar had begin to heal (Figure 8a and 8b).

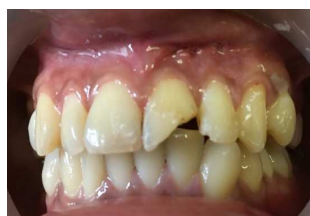

Figure 8a. Post-operative clinical condition after 7 days.

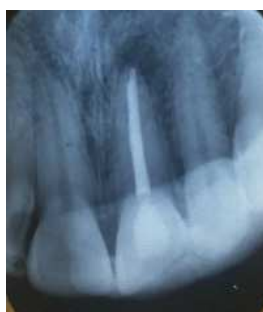

Figure 8b. Post-operative radiograph, recall after 7 days

After one and a half month, the patient showed no pain complaint and the surgical wound has healed. Radiographs showed that the radiolucent area has began to decrease (Figure 9a and 9b).

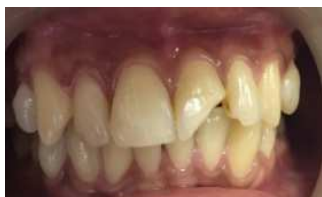

Figure 9a.
Post-operative clinical condition after 1.5 month.

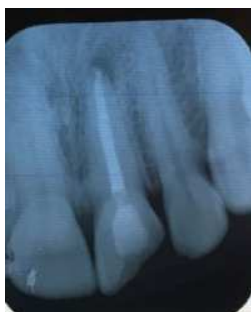

Figure 9b.
Post-operative radiograph, recall after 1.5 month.

Patient started the restoration treatment with prefabricated fiber post and class IV cavity resin composite in multiple visits. The color adjustment uses Vitapan shade guide and obtained A3 color (Figure 10). Performed long post count in the root canal was obtained 17.3 mm. The precision drill determination was obtained in blue (Fiberpost, Dentsply) (Figure 11). Gutta-percha on the root canal is reduced by peeso reamer one number below the blue fiber post. The root canal was prepared with precision drill 17.3 mm and irrigated with saline (Figure 12). The root canal is dried and a blue fiber post is tried. Radiographs were taken for confirmation of post preparation results on the tooth 21 (Figure 13). Root canal and cavity was disinfection with chlorhexidine digluconate 2% for 1

minute then dried with paper point. The application of etch with phosphoric acid 35% for 15 seconds and bonding with generation V (XP Bond, Dentsply) uses microbrush for 10 seconds.

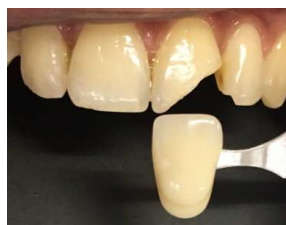

Figure 10.
The color adjustment uses Vitapan shade guide A3.

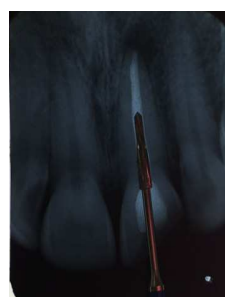

Figure 11.
Tracing precision drill.

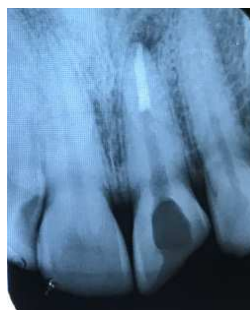

Figure 12.
Gutta-percha on the root canal is reduced by peeso reamer

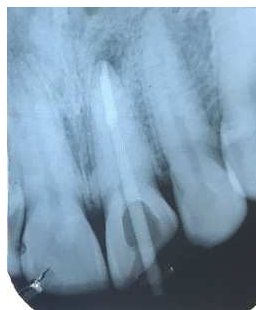

Figure 13.
Blue fiber post is tried

Fiber post application with silane for 1 minute and not too dry. The post were cut along 14.7 mm using diamond bur and then sementation into root canals using

self-adhesive resin cement (RelyX U200, 3M ESPE) (Figure 14). The cement resin is flattened at the bottom of the cavity and then the bulk-fill composite application (SureFil SDR flow, Dentsply) uses microbrush and light cure for 20 seconds.

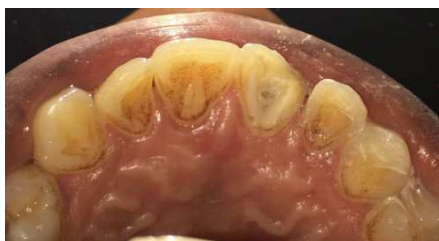

Figure 14. The post were cut along 14.7 mm using diamond bur and sementation.

Restoration with A3 composite resin material (Filtek P60, 3M ESPE) to form a central incisor contour then activated by light cure for 20 seconds. Occlusion and articulation examination using articulating paper. Finishing and polishing of composite resin restorations by using yellow bur flame, polishing disc flame (Enhance, Dentsply), rubber silicon cups, impregnated brush abrasives, and proximal parts polished with polyester strips (Optistrip, Kerr) (Figure 15a and 15b).

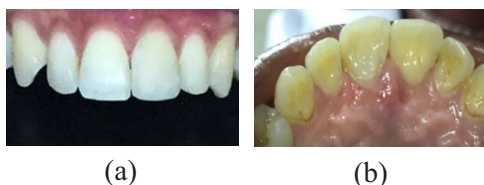

Figure 15. Restoration with A3 composite resin material in labial view (a) and palatal view (b).

At a six month recall visit, the patient did not report any symptoms and radiographic examination revealed reduction of the bone cavity size (Figures 16a and 16b).

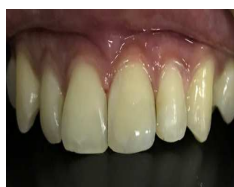

Figure 16a. Post-operative clinical condition after 6 month.

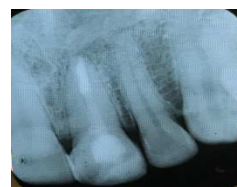

Figure 16b. Post-operative radiograph, recall after 6 month.

DISSCUSION

Endodontic treatment conventional involves cleaning, shaping, disinfecting and obturating the canal with a suitable sealant material. The tooth was endodontic treated and has failed, then reported with persistent pain and chronic infection⁽²⁾. After failure of root canal treatment, apical surgery is the last available resource to solve inflammatory processes in the periapical zone⁽⁵⁾. The surgery was performed in maxillary anterior teeth. The case showed radiographic with periapical damage and ill-defined irregular borders suggesting chronic periapical cysts or granulomas⁽²⁾.

Tooth 21 was painful for 2 weeks, previously receiving root canal treatment for a week by co-ass. The co-ass reported that the endodontic obturation of the root canal was excessive and could not be removed completely. The pathophysiology of this disease is caused by the overfilling

of the obturation material which causes the inflammatory response of the dental apical tissue and forms an acute periapical lesion. Treatment of tooth 21 is a combination of endodontic surgery and root canal treatment. The surgical procedure performed is apical curettage with two stages, the first stage is endodontic treatment, then after few days or weeks it was followed by apical curettage. The purpose of apical curettage is to eliminate overfilling obturation material and all apical necrotic tissues that could not heal with conventional endodontics⁽¹⁾.

In this case, a semilunar flap opening is made considering the small operation area, so there is no need for a wide flap opening (full mucoperiosteal). After the completion of the apical curettage, the flap was repositioned again. Positioning the tissue in its original position allows the healing process, beginning with the primary healing and tissue handling during surgery, both in the soft tissues (periosteum, gingiva and alveolar mucosa) and hard tissue (dentin, cement, ligament periodontium and bone). In this case, bone graft is not given because the lesion is small so it is expected to initiate the process of natural bone regeneration⁽⁶⁾.

Indications for apical curettage treatment include persistence of symptoms and presence of bone lesion. From the endodontic perspective, retreatment should always be considered before surgical treatment, since there is evidence of greater healing rate in cases where re-treatment was performed before apical surgery. A

study conducted on tissue healing based on radiographic changes, showed that there was a direct relationship between size of lesion and healing time. A lesion smaller than 5 mm will approximately take 6 months to heal, a lesion of 6 to 10 mm will take 7 months and lesions larger than 10 mm will require in average 11 months to heal. The present clinical case could be rated as a success since at the six month recall visit, no pain was reported, soft tissues exhibit no alterations, the tooth was in appropriate function and the size of the bone lesion had decreased⁽⁵⁾.

Intraoral periapical radiograph was evaluated by pre-operative and post-operative at the end of 1st weeks, 1st and 6th months. Preoperatively the case showed endodontically treated teeth with irregular periapical radiolucency and at the end of 1st month post-operatively showed radiolucency decreased that indicates bone healing. The 6th month follow-up shows increasing radio-opacity and haziness that indicates bone regeneration. Patients could be evaluated at the end of fifth month and radiographs showed increase in radioopacity and reduction in size of periapical radiolucency as well as normal trabecular pattern of the bone. The case was evaluated in the postoperative period with regards to infection and sinus formation. No complications was noted in the operated cases⁽²⁾. Healing is normally evaluated a year post-surgery, although small (<5 mm) periapical defects might heal within a few months. Clinical healing is based on the

absence of signs and symptoms such as pain, swelling, and tenderness to palpation or percussion. Standard radiographic healing classes include complete healing, incomplete healing (scar tissue formation), and uncertain healing (partial resolution of postsurgical radiolucency)⁽⁷⁾.

CONCLUSION

Before endodontic surgery with apical curettage techniques is performed, it must first establish a correct diagnosis. Endodontic surgical measures should consider the indications and contra indications. In this case the periapical curettage aims to extract the guttaperca overfilling and treat the periapical lesion of the pulp necrosis tooth which has been completed root canal treatment. The lesions appear to be heal after control in the fourth week postoperatively. Endodontic surgical treatment can be performed to support conventional endodontic treatment. If a periapical lesion is extensive then endodontic surgery may be considered so the tooth can be maintained without retraction. The success of an apical curettage action is strongly influenced by the knowledge of anatomy, skill, and ability in root canal treatment so that the tooth can be maintained.

SUGGESTION

A deeper study of apical closure if the apical curettage is not accompanied by apical closure using a material that has a good seal.

REFERENCES

1. LailiA.,Beda hendodontik suatu-pendekatan konservatif dalam pen-anggulungan kista yang lebih dari 2/3 panjang saluran akar gigi anterior. RSUP Hasan Sadikin Bandung. 2012.
2. Lingaraj JB, Kotrashetti SM, Gupta N.,Healing assessment of osseous defects of periapical lesions with use of freeze dried bone allograft. J Maxillofac Oral Surg. 2009; 8; 4:362–365.
3. Pedroche LO, Barbieri N, Tomazinho FSF, Ulbrich LM, Leonardi DP, Sicuro SM.,Apicoectomy after conventional endodontic treatment failure: Case report. RSBO. 2013;10; 2:182-7.
4. Peterson LJ. Principles of management of impacted teeth.3rd ed.ConemporaryOral and Maxillo-facial Surgery.St. Louis, Mosby Year-book inc.1998.
5. Salcedo MEH, Vázquez AGC, Briones JCG, Mancillas DYM, Ibarra SRZ, Ceped LAG. Apical curettage and retrograde obturation without apicoectomy. Clinical case presentation. RevistaOdontológica Mexicana. 2015; 19; 1: 48-50.
6. SetyawatiA.Periapical curretage on the right maxilla incisivus lateralis pulp necrosis, with periapical lesion. MutiaraMedika. 2007; 7; 1: 22-26.
7. vonArx. T. Apical surgery: A review of current techniques and outcome. The Saudi Dental Journal. 2011; 23: 9-15.

ROOT CANAL TREATMENT OF SUBGINGIVAL CARIES ON DISTAL MANDIBULAR SECOND MOLAR DUE TO WISDOM TOOTH IMPACTION - A CASE REPORT

Kissy Wicaksana¹, Bernard O. Iskandar², Aryadi Subrata²

¹ Resident in Departemet Conservative Dentistry and Endodontics Trisakti University

² Lecturer in Departemet Conservative Dentistry and Endodontics Trisakti University

ABSTRACT :

Background: Subgingival caries of distal mandibular second molar; often caused by wisdom tooth impaction; can lead to irreversible pulpitis condition. Root canal treatment (RCT) procedure for management of this case is quite a challenge since the isolation to make the artificial wall for subgingival caries is difficult to achieve without doing an open flap technique. Once the artificial wall is perfectly done, the RCT could be performed and the success rate would be enhanced. **Objective:** The aim of this case report is to present the success of RCT of mandibular second molar tooth caused by wisdom tooth impaction.

Case Management: A 31-year-old female patient was referred for RCT on the mandibular second molar with irreversible pulpitis after doing the odontectomy surgery. Clinical assessment showed the cavities is nowhere to be seen in the crown, the tooth was tender to percussion but has normal palpation and mobility. Radiographic examination showed radiolucency below the gingival margin on distal mandibular second molar near the pulp, extended apically to bone level, widening of periodontal ligament on the distal area and radiolucency in the periapical region. After contouring the gingival, artificial wall was made with 3-D matrix and bulkfill composite was used. Rotary instrument with short file is the right tools, because of the limited mouth opening of the patient. Obturation was done with 3-D compaction guttapercha and sealer, to fill the entire space. **Conclusion:** RCT of subgingival caries on mandibular second molar proven to be successful if performed under adequate technique.

Keywords: root canal treatment, RCT, wisdom tooth impaction, subgingival caries, mandibular second molar.

INTRODUCTION

Third molar impaction is common nowadays. Previous studies by McArdle *et al.* and Chang *et al.* pointed out that second molars caries due to impacted third

molar have a prevalence of caries ranging from 7 to 32%. Another author, Kang *et al.* reported even higher number for detection of second molar caries (52%) by using 3-Dimensional radiography cone-beam

computed tomography (CBCT). McArdle and Renton concluded that third molar position of impaction is the biggest factor for distal caries incidence, mesio-angular tilt is the most associated with caries occurrence, while other impacted position are unlikely to develop this pathology. According to Marques *et al.* the influence of the contact point location between the second and third molar is the main reason for this situation. The contact points below the cemento-enamel-junction (CEJ) are more difficult to clean, leading to higher plaque accumulation. Meanwhile, third molars are related with certain bacteria and inflammatory mediators that might stimulate the development of periodontitis and caries.¹

Impacted wisdom tooth occur because lack of the space of the tooth, obstruction, or abnormal position.² This condition can lead to caries of the adjacent tooth, if not being treated, might develop to irreversible pulpitis. Irreversible pulpitis is characterized by acute and intense pain that will not response to analgesic; hence the patient needs root canal treatment (RCT).³ one of the main principles of the endodontic treatment is disinfection of the root canal system. The successful disinfection achieved by three approach, such as cleaning and shaping, irrigation of the root canal space and usage of intra-canal medicaments. Thorough debridement of the canal system is possible only when these modalities fulfilled, because of these reason, having an access cavity that is four

walled goes a long way in helping these goals to succeed.⁴ Once the proper access cavity is created, endodontic treatment could be done. The aim of this case report is to present the success of RCT of mandibular second molar tooth caused by wisdom tooth impaction.

CASE REPORT

A 31-year-old female patient with non-contributory medical history was referred for RCT to department of conservative dentistry, Universitas Trisakti. The chief complaint was the painful sensation on the mandibular second molar. The previous dentist have done the odontectomy surgery and referred the patient while diagnose the mandibular right second molar with irreversible pulpitis (Figure 1). Clinical assessment showed amalgam restoration in the coronal, but no cavities to be seen, the tooth was tender to percussion but has normal palpation and mobility (Figure 2). Radiographic examination showed radiopaque in the coronal, while there is radiolucency below the gingival margin on distal mandibular second molar near the pulp, extended apically to bone level, widening of periodontal ligament on the distal area and radiolucency in the periapical region (Figure 3). From the objective and subjective examination, diagnosis irreversible pulpitis of tooth #47 was made. A root canal treatment plan was formulated.

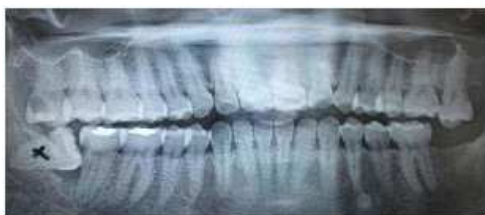

Figure 1. Panoramic radiograph

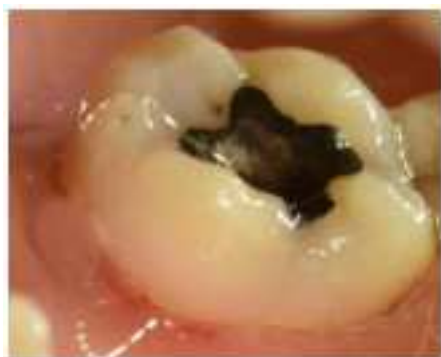

Figure 2. Visual image of tooth # 47.

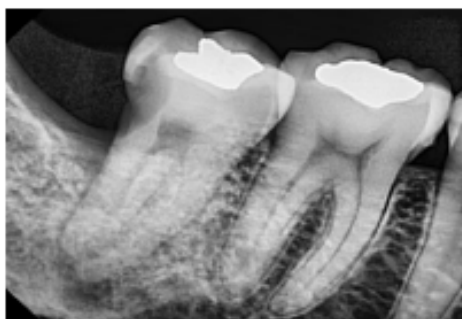

Figure 3. Periapical radiograph of tooth # 47.

The amalgam restoration and caries was removed under local anesthesia (*Septocaine* 1:80.000, *Septodont*). Gingiva that covers the cavity was contoured (Figure 4). After contouring the gingival, artificial wall was made with 3-D matrix and bulkfill composite was used (Figure 5). The working length was determined using electronic apex locator, confirmed by periapical radiographs (Figure 6). The root canal system was cleaned and shaped

by using *Protaper Next Rotary Instrument* (*Dentsply, USA*), with copious irrigation of 5,25% NaOCl between instruments. Rotary instrument with short file is the right tools, because of the limited mouth opening of the patient.

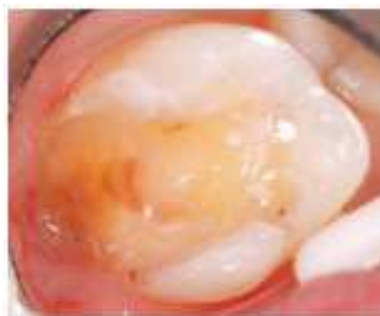

Figure 4. Countoured gingiva on tooth # 47.

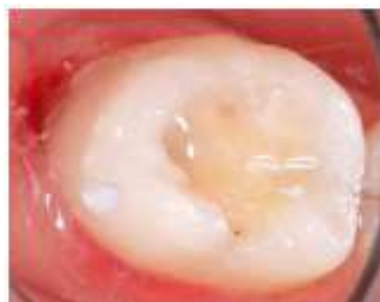

Figure 5. Artificial wall of tooth # 47.

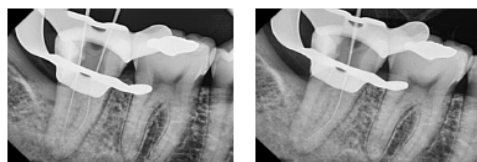


Figure 6. Periapical radiograph to confirmed the working length.

Final irrigation was made using 5,25% NaOCl, 17% EDTA, and 2% CHX; sterile saline between different solution. Obturation was done with 3-D compaction guttapercha (*Protaper Next* gutta-percha, *Dentsply*) and sealer (*Sealapex*, *SybronEndo*), to fill the

entire space (Figure 7). Final restoration using composite endocrown was placed on the tooth # 47 (Figure 8). The patient was recalled after 7 days and 3 months. Clinical and radiographic examination revealed no abnormalities.

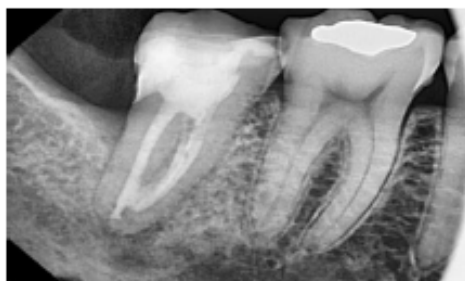

Figure 7. Obturation of tooth # 47

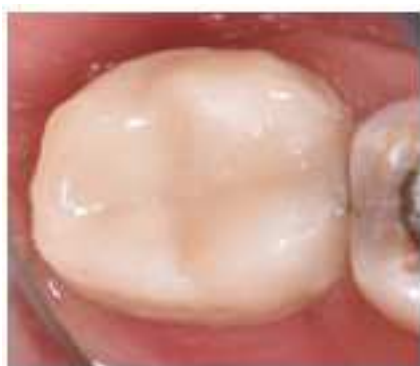

Figure 8. Final restoration of tooth # 47 with endocrown.

DISCUSSION

The objective of root canal treatment is to clean and shape the root canal system in order to obtain a 3-Dimensional sealing of the endodontic space. One of the most important variables in root canal treatment is proper tooth isolation, such as rubber dam. However, the use of rubber dam is possible if the destructed tooth is built to secure the rubber dam clamp.⁴ In subgingival caries case, the isolation of

moisture of the gingival is hardly achieved to build the artificial wall. In this case, the caries lesions were located in alveolar bone level, which couldn't be restored by placing gingival retraction cords.⁵ Hence, the placement double matrix, such as Omni-Matrix Wingless Mylar Red (*Ultradent*) and 7,5 mm sectional matrix (*Palodent Plus Dentsply, USA*) was used to solve the challenge. Once the artificial wall was made, the RCT with shorter instrument could be done. Final restoration for endodontically treated tooth is a mandatory, while the margin of sound tooth structure could determine the type of restoration needed. Composite endocrown was chosen as the final restoration for this case due to its benefits.

By definition, endocrowns are partial crowns made out ceramic or composite resin that are bonded by resin cements to the devitalized tooth. They offer a full occlusal coverage and they take advantage of the pulp chamber to increase the available adhesive surface.⁶ The material used to build the artificial wall is based on resin, while endocrown bonded by resin cements, so that both of the material could be bonded without the obligation to remove the previous artificial wall.

CONCLUSION

In endodontic treatment, multiple variables can affect the prognosis of a case. For case like this, build an adequate artificial wall is a challenge due to subgingival caries margin. Adequate

artificial wall is one of the variables that might enhance successful disinfection of root canal system, by preventing marginal leakage in subgingival region that can't be reached by some final restoration. Once the access cavity is perfectly made, root canal treatment could be done. Endocrown restoration, need to be considered as the final restoration for the case like this. Combination of adequate technique will lead to a successful outcome of root canal treatment.

REFERENCE

1. Marques J, Montserrat-bosch M, Figueiredo R, Valmaseda- E. Impact- ed lower third molars and distal car- ies in the mandibular second molar . Is prophylactic removal of lower third molars justified ? 2017;9(6):6-10. doi:10.4317/jced.53919.
2. Impacted wisdom teeth Search date July 2009 Oral health Impacted wis- dom teeth. 2010;(July 2009):1-17.
3. Radeva E. Emergency treatment of ir- reversible pulpitis. 2008:4-5.
4. Kshirsagar S, Aggarwal S, Mukhtar A, Gupta P, Rai V, Chawla M. Pre Endodontic Build-up of a Grossly Destructed Tooth : A Case Report. 2015;2(11):225-229. doi:10.17354/ ijss/2015/90.
5. Tanikonda R, Nalluru S, Koneru S, Mannem S. Comprehensive man- agement of subgingival caries : A minimally invasive interdisciplin- ary approach. 2012;1(2):130-133. doi:10.4103/2277-8632.98369.
6. Rocca GT. Crown and post-free ad- hesive restorations for endodonti- cally treated posterior teeth : from direct composite to endocrowns. 2013;8(2):154-177.

CASE REPORT

HEMISECTION OF MANDIBULAR FIRST MOLAR

Leedwin Kalyana Alison*, WignyoHadriyanto**

*Resident of Conservative Dentistry, Faculty of Dentistry,
GadjahMada University, Yogyakarta

**Staff Department of Conservative Dentistry, Faculty of Dentistry,
GadjahMada University, Yogyakarta

*Jl. Denta No.1 Sekip Utara, Yogyakarta. E-mail: leedwinkalyana@gmail.com

ABSTRACT

Background: Tooth structure remaining after root canal treatment will greatly influence the design and the selection of restorative materials that will be used to restore the function of the teeth in oral cavity.

Aim: The purpose of this study was to report a case management of hemisection to preserve occlusal rehabilitation.

Case: A 20 years old healthy female patient came to department of conservative dentistry. Her chief complaint discomfort on leftmandibular first molar since 3 years ago. The patient was willing to retain the tooth. On intra oral examination, there was gingival polyp on occlusal. There was pain when chewing. No history of trauma. On radiograph showed periodontal lesion in mesial and distal root #36.

Treatment: Root canal treatment was performed in mesial canal of the left mandibular first molar continued by insertion of fiber post prefabricated and hemisection procedure of the distal root. The tooth restored by resin bonded rochette bridge type with occlusal metal.

Conclusion : Hemisection may be suitable alternative to extraction and should be discussed with patients during consideration of treatment options.

Keywords : root canal treatment, fiber post, hemisection

INTRODUCTION

Modern advances in all phases of dentistry have provided the opportunity for patients to maintain a function dentition for lifetime^[1]. The efforts to maintain teeth as long as possible in the mouth cavity have been improving along with the increase of the patient awareness to treat their teeth. The treatment may involve combining restorative dentistry, endodontics, and

periodontics so that the teeth are retained in whole or in part.

Hemisection is a conservative way of preserving tooth. The term “hemi section” or “root amputation” are synonyms for “root sectioning” or “bisection” and is a treatment modality, which allows the preservation of tooth structure, alveolar bone and cost savings over other treatment options. The

advantage of the amputation, hemisection or bisection is the retention of some or the entire tooth. However, the disadvantage is that the remaining root or roots must undergo endodontic therapy and the crown must undergo restorative management ^[2,3]. Weine has listed the following indications for tooth resection^[4,5]. For periodontal indications: (1) severe vertical bone loss involving only one root of multi-rooted tooth (2) through and through furcation destruction (3) unfavourable proximity of roots adjacent teeth, preventing adequate hygiene maintenance in proximal areas (4) severe root exposure due to dehiscence.

For endodontic and restorative indications: (1) prosthetic failure of abutments within a splint: if a single or multirooted tooth is periodontally involved within a fixed bridge, instead of removing the entire bridge, if the remaining abutment support is sufficient, the root of the involved tooth is extracted. (2) endodontic failure: hemisection is useful in cases in which there is perforation through the floor of the pulp chamber, or pulp canal of one of the roots of an endodontically involved tooth which cannot be instrumented. (3) vertical fracture of one root: the prognosis of vertical fracture is hopeless. If vertical fracture traverses one root while the other roots are unaffected, the offending root may be amputated. (4) severe destructive process: this may occur as a result of furcation or subgingival caries, traumatic injury, and large root perforation during endodontic therapy. Contraindications:

(1) poorly shaped roots or fused roots. (2) poor endodontic candidates or inoperable endodontic roots. (3) patient unwilling to undergo surgical and endodontic treatments. This case reported hemisection on mandibular first molar where the mesial part is maintained while the distal part is pulled out^[4,5,8].

CASE

A 20 years old healthy female patient came to department of conservative dentistry. Her chief complaint discomfort and intermittent pain on left mandibular first molar and since 3-5 months ago. She felt discomfort on eating. The patient was willing to retain the tooth. There was pain while chewing. No history of trauma. On intra oral examination (fig.1), there was gingival polyp on occlusal. The diagnose of the tooth's condition was pulp necrosis. Periodontal support of mesial root of 36 was good. The patient did not wish to have the tooth removed, so conservative treatment was selected, which included hemisection of distal root of 36. On radiographic examination (fig 2.) showed periodontal lesion in mesial and distal root involved furcation, enlargement of ligament periodontal around the root canals.

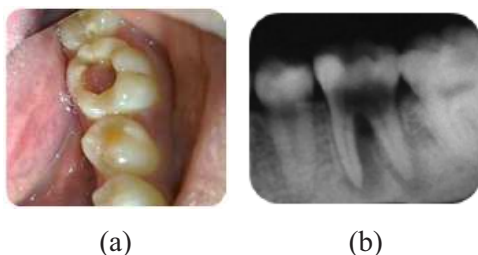


Figure 1. (a) Clinical view of the left mandibular first molar before treatment.

(b) Radiographic view of the left mandibular first molar before treatment.

CASE TREATMENT

The patient was given detailed information regarding the treatment procedure. First visit was done with anamnesis, clinical examination, radiographic examination, treatment plan, and informed consent.

Root canal treatment was performed by crown down technique. Started with initial exploration using k-file #8, #10 and #15 along the 2/3 of the temporary working length, measure working length with k-file #15 with apex locator (*SybronEndo mini*, *SybronEndo*) and confirmed with radiograph.

The mesiobuccal and mesiolingual canal was cleaned and prepared by crown down technique with ProTaper Hand Use and was irrigated with 2,5% sodium hypochlorite after each file. Canals were dried with sterile paper points, filled with calcium hydroxide paste as intracanal medicament and temporized with temporary filling.

The dressing process until the teeth are reported asymptomatic, then the root canals were obturated with the single cone technique using matching gutta-percha along the correct working length and *TopSeal* (*Dentsply*) as the sealer (fig 2).

Before obturation process, root canal system irrigated with 2,5% sodium hypochlorite, 17% EDTA, and 2% chlorhexidine and then dried with sterile paper points. The pulp chamber was filled with restorative GIC to maintain a good seal and allow interproximal area to be properly contoured during surgical separation. At the end of visit, the cavity being filled with temporary restoration.

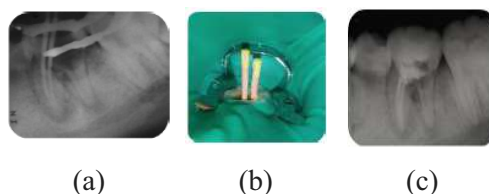


Figure 2. (a) Radiographic view trial master cone; (b) fitting of guttapercha cone; (c) Root canal treatment- post obturation.

Hemisection was performed under local anesthesia. Asepsis was done on the operation area, the block anesthesia on the left mandible nerve and infiltration anesthesia on the vestibulum #36 using pehacain. A straight fissure carbide bur directed toward the bifurcation area was used to transact the crown with distal root giving a vertical cut method. A fine probe was passed through the cut to ensure separation (fig 3). No flap needed in this procedure. After the roots are separated, the

distal root is extracted using root forceps.

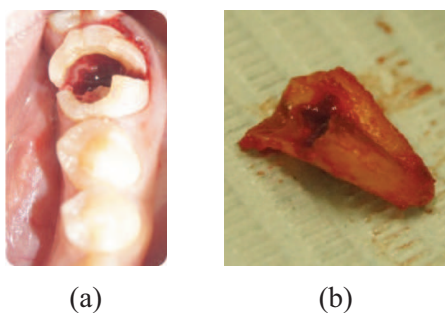


Figure 3. (a) separation mesial dan distal root (b) the distal root was extracted.

The bone graft material GamaCha is added in the defect area and the gingival are sutured using synthetic absorbable monofilament 6-0 (fig 4). The patient was prescribed antibiotics and analgesics. Two week after, patient was called to control. The healing is excellent and the tooth is asymptomatic.

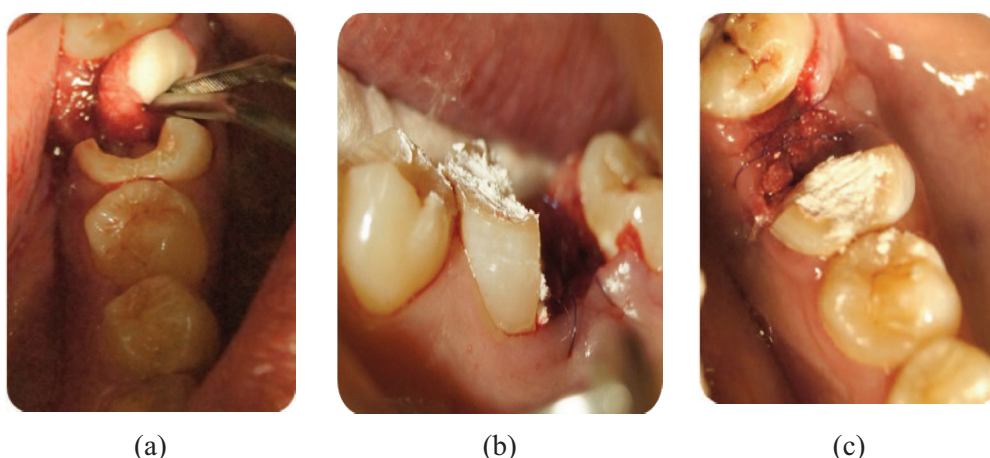


Figure 4. (a) Bone graft placed in the defectarea ; (b&c) Suturing after removal of resected piece of #36

On next appointment, subjective symptoms were negative, the condition of the suture was good, and the percussion was negative. Next step was inserting prefabricated fiber post. Prefabricated fiber post was inserted to maintain tooth's strength and retention. Prefabricated post has modulus elasticity similar to dentin. Fiber post drill was used to prepare a post space in mesiobuccal canal to depth of 10 mm. Dual-cure resin cement (RelyX-U200) was injected into the post spaces and fiber

post was inserted to length (fig.5). Excess luting agent was removed from around the posts. Preparation of the mesial root was made to accept porcelain fused to metal crown with rochette bridge type. Retraction cord was inserted to sulcus to provide better capture of margins. A temporary crown was seated during healing and to prevent drifting of the remaining root (fig 6).

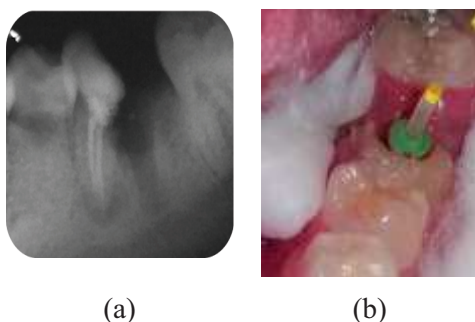


Figure 5. (a) Radiograph view after the distal root was extracted; (b) Clinical view when inserting the fiber post.

Two weeks after, the crown was ready to inserted. The crown was cemented with self-adhesive resin cement. The tooth was asymptomatic, and patient feel comfort with her new teeth. Oral hygiene instruction was given to patient for caring her teeth and check-ups regularly.

Patient was recalled after 3 months for evaluation. She did not report any complaint about the teeth. Oral hygiene was good and no redness in gingival tissue.

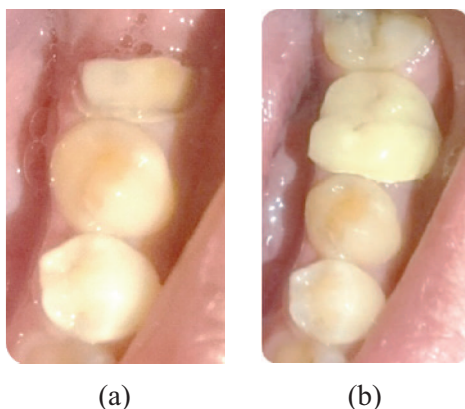


Figure 6. (a) Result of preparation #36 after inserting prefabricated fiber post (b) clinical view of temporary crown was inserted

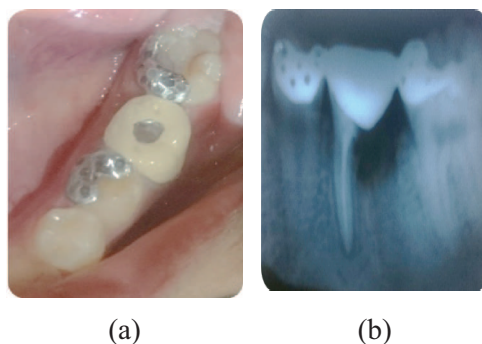


Figure 7. (a) The insertion of resin bonded rochette bridge type with occlusal metal; (b) post operative radiograph.

DISCUSSION

People want to keep their teeth for longer period, clinicians put an effort to provide a wide range of treatment options based on the clinical situation age, economical consideration of patient, and the best available clinical evidence successful treatment modality. A hemisection is a specialized dental procedure where half of an injured natural tooth is removed^[6]. A hemisection can only be performed on molars, which are the larger, flatter teeth at the rear of the mouth. Hemisection cannot be performed on smaller teeth because they lack the strength and stability required to remain functional after the procedure.

Appropriate endodontic therapy must be performed before hemisection to avoid intrapulpal dystrophic calcification and postoperative tooth sensitivity^[7]. Implant therapy is predictable option with good functionality; however, in this case, the patient chose an alternative treatment because of financial considerations. The

keys to long term success appear to be thorough diagnosis, selection of patients with good oral hygiene, careful surgical and restorative management. It was shown that such teeth can function successfully for long periods^[8].

CONCLUSION

Based on the discussion above, it can be conclude that the hemisection is an alternative, effective treatment better than extraction. Hemisection has received acceptance as a conservative and dependable dental treatment and teeth so treated have endured the demands of function.

REFERENCES

1. Moulana U, Vasanthi B, Duraivel D, Nishanthini C, Poorni S, Srinivasan MR. 2016, Hemisection: Resection for conservation – A case report. J of Pierre Pauchard Academy (India section), Elsevier.
2. Shah S, Modi B, Desai K, Duseja S.,2012., Hemisection – A conservative approach for a periodontally compromised tooth – A case report. Journal of Advanced Oral Research, Vol 3:2
3. Parmar G, Vashi P. 2003. Hemisection: A case-report and review. Endodontic. 15:26-9
4. Weine FS. 1996. Endodontic Therapy, 5th ed. St. Louis: Mosby
5. Heda, A., Gundappa, M., Mohan, R., 2014, Hemisection-A Case Report, *TMU J. Dent*, 1:149-151
6. Y.Terauchi. 2016. Managing iatrogenic Endodontic Events. Eleventh E. Elsevier inc.
7. VivekanadaPai AR, Khosla M. Root resection under the surgical field employed for extraction of impacted tooth and management of external resorption. J Conserv Dent 2012; 15:298-302
8. Verma PK, Srivastava R, Baranwal HC, Gautam A. A ray of hope for the hopeless: Hemisection of mandibular molar with socket preservation. Dent Hypotheses 2012; 3:159-63

CASE REPORT

INTRACORONAL BLEACHING FOLLOWED BY DIRECT COMPOSITE RESTORATION AS A MANAGEMENT OF DISCOLORED ANTERIOR TEETH : A CASE REPORT

Lidya Octavia¹, Sri Subekti Winanto², Elline²

¹ Resident at Department of Conservative Dentistri Trisakti University, Jakarta-Indonesia

² Staff at Department of Conservative Dentistri Trisakti University, Jakarta-Indonesia

Background: Intracoronar bleaching is a conservative alternative and the least invasive aesthetic procedures of non-vital discolored teeth. This method requires a root canal that is properly obturated and an effective bleach barrier for a successful intracoronar bleaching. Final restoration of fractured anterior teeth after intracoronar bleaching procedure also important. One of the treatment is the use of direct restoration with composite resins. Residual peroxides of bleaching agents may affect the bonding strength of composite to the tooth. Therefore, restoration procedure requires an interval of a few days after bleaching. This article reports the management discoloration of non-vital tooth using walking bleach method followed by direct composite restoration as a final restoration. **Objectives:** The aim of this case report is to demonstrate the efficacy of walking bleach technique followed by direct composite restoration as a management option in patients with a discoloured permanent incisor. **Case Management:** A 20 year old female patient came with chief complaint of discolored anterior teeth. The patient gave a history of trauma to her front teeth 4 years back. On clinical examination a discoloration was seen on right maxillary central incisor with a fracture on distal. A radiographic examination shows radiolucent image that had entered the pulp chamber. A root canal treatment and intracoronar bleaching using walking bleach method with hydrogen peroxide 35% had been performed followed by direct composite restoration few days after bleaching. **Conclusion:** Intracoronar bleaching using walking bleach method with hydrogen peroxide 35% and direct composite restoration on right maxillary central incisor showed a successful treatment outcome.

Key words: discoloration; intracoronar bleaching; walking bleach; restoration

INTRODUCTIONS

Discolored anterior teeth could be a problems for aesthetic. Because of the growing need for beautiful, giving the natural appearance of the tooth to the patient by restoration has become increasingly important in recent years. The most common causes of for tooth discolouration are intrapulpal hemorrhage beacause of trauma, pulp necrosis, intracanal medicaments and metallic restoration placed in the coronal access. The penetration of blood into the dentinal tubules, followed by haemolysis of the red cells, which results in the release of haemoglobin and its breakdown products, produces a yellowish brown discolouration. This discolouration occurs when the iron pigments get degraded to iron sulfide.¹

Intracoronar bleaching is an established, simple, cost effective and conservative method of improving the colour of discoloured teeth that have received root canal treatment. The bleaching of non vital teeth is relatively low risk treatment for improving the esthetics of endodontically treated teeth. This method was first mentioned by Garretson in 1895, who used chlorine as the bleaching agent. The intracoronar bleaching agents most commonly used are hydrogen peroxide, carbamide peroxide and sodium perborate.²

One of the undesirable consequences of intracoronar bleaching is external cervical root resorption. Because of the incidence of cervical external cervical root resorption, intracoronar bleaching requires

a root canal that is properly obturated and the placement of an effective bleach barrier which prevents the leaching of the bleaching agents into the periodontium.²

OBJECTIVES

The aim of this case report is to demonstrate the efficacy of walking bleach technique followed by direct composite restoration as a management option in patients with a discoloured permanent incisor.

CASE REPORT

A 20 year old female patient came with chief complaint of discolored anterior teeth. The patient gave a history of trauma to her front teeth 4 years back. On clinical examination a discoloration was seen on right maxillary central incisor with a fracture on distal (Fig. 1a). A radiographic examination shows radiolucent image that had entered the pulp chamber (Fig. 1b).

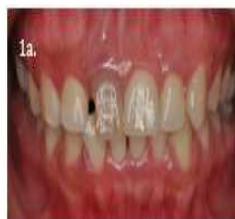

Fig 1a. Pretreatment photograph of maxillary right central incisor showing discoloration die to a necrotic pulp caused by trauma

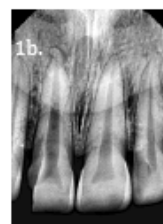


Fig 1b. Pretreatment radiograph of maxillary right central incisor

Caries was removed with round diamond bur and excavated completely. Artificial wall was made on teeth 11 followed by isolation of the tooth using rubber dam. The access cavity was prepared with round diamond bur. Working length was determined using Root ZX II apex locator (Morita) and confirmed radiographically (Fig. 2a). Cleaning and shaping was performed with TF Adaptive 25/.08, 35/.06, and 50/.04 sequentially. During the treatment, the root canal was constantly irrigated with 5% NaOCl (Chloraxid, CerKamed), saline, and recapitulated with K file size #10. Sterilization is done by filling the root canal using calcium hydroxide.

On the second visit, patient was clinically evaluated, the root canal is irrigated for cleaning calcium hydroxide using aquadest and dried with sterile paper points. Obturation was performed with gutta-percha TF Adaptive 50/.04 and root canal sealer (Saelapex, SybronEndo) using warm vertical compaction technique. Approximately 2mm of root canal gutta-percha is removed apical to the CEJ. A protective layer of 2 mm resin composite was placed over the root filling material. The protective barrier should be 1 mm coronally to the CEJ (Fig. 2b) Hydrogen peroxide 35% (Opalescence Endo) was placed in the pulp chamber then condensed with a plugger. (Fig. 2c) Excessive bleaching material was removed using cotton pellet. A piece of dry cotton was placed over the bleaching material and the

access cavity was sealed with modified zinc oxide eugenol cement (IRM, Dentsply) (Fig. 2d). The patient was recalled after 5 days for a review.

After 5 days, the tooth showed a definitive improvement in the shade (Fig 3a). Radiographs were taken to serve as a comparison for the subsequent follow up visits (Fig. 3b). The patient was recalled after 1 week for a permanent adhesive restoration. On a fourth visit, the tooth was prepared for class IV direct composite restoration as a final restoration.

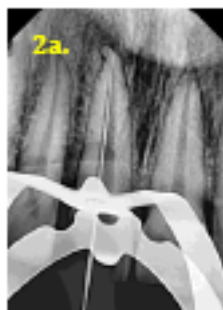

Fig 2a. Working length measurement

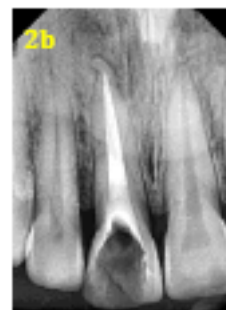

Fig 2b. Obturation and protective barrier



Fig 2c. Placement of hydrogen peroxide 35% (Opalescence Endo) in the pulp chamber



Fig 2d. Placement of temporary restoration

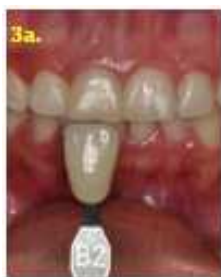

Fig 3a. Photograph
of 11, 5 days
after intracoronal
bleaching

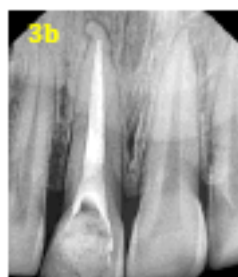


Fig 3b. Radiograph
of 11, 5 days
after intracoronal
bleaching

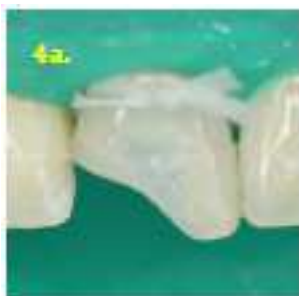

Fig 4a. The tooth was
prepared for class IV direct
composite restoration

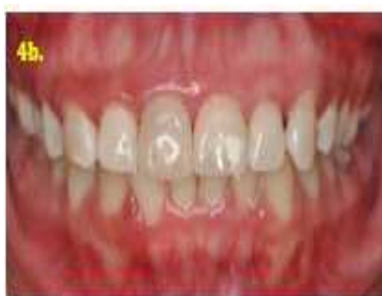

Fig 4b. Final result of direct
composite restoration

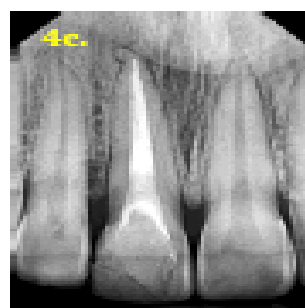

Fig 4c. Post operative
radiograph

DISCUSSIONS

In this case, the etiology of the discoloration is pathological trauma that happened to the patient 4 years ago. Clinical and radiographic examination led to a diagnosis of pulp necrosis that requiring root canal treatment and non-vital tooth using walking bleach method with hydrogen peroxide 35% followed by direct composite restoration as a final restoration few days after bleaching.

It has been suggested that hydrogen peroxide may cause damage to the tooth

and surrounding attachment apparatus then cause resorption following the procedure. Intra-coronal protective barrier should be placed to prevent hydrogen peroxide from penetrating to the periodontium. Materials that had been suggested as a protective barrier include glass ionomer cements, intermediate restorative material (IRM), cavite, resin composite, photo-activated temporary resin materials such as Fermit, zinc oxide eugenol cements, polycarboxylate cements, and zinc phosphate cements.³

The success when bleaching with 30% hydrogen peroxide varies between 80 and 93% compared with 39–53% when using sodium perborate alone. For economic and safety reasons, it would be desirable to achieve the aesthetic change in the minimum number of treatment sessions to minimize exposure of the periradicular tissue to bleaching material.² The mechanism of bleaching by hydrogen peroxide is not fully known. The most accepted theory is that peroxide diffuses into and through enamel to reach dentin then reacts with the organic chromophores that responsible for the major color factors of teeth.⁴

Intracoronar bleaching for non vital teeth has several advantages over other post endodontic treatment options like full veneer crowns. Intracoronar bleaching is a non invasive procedure and it is also economical, less time consuming, and patient's natural tooth structure is preserved.⁵

A good permanent restoration is one of the foundations of long term success, as it prevents coronal microleakage from the access cavity and avoids the risk of renewed discoloration through open dentinal tubules.³ In this case, treatment plan for final restoration is direct composite restoration. Composite resins are esthetic and easy to manipulate. The advantages of the direct technique are its low cost, that the restoration may be evaluated as a reversible treatment procedure, and that the restoration may be repaired intraorally.⁶

The problem exists because of the adhesive bond strength between composite resin to enamel and dentin is temporarily compromised after bleaching procedures caused by remnants of peroxide or free oxygen, which inhibit resin polymerization. At least 1 week was recommended to achieve adequate bonding.³

CONCLUSION

Intracoronar bleaching requires a root canal that is properly obturated, an effective protective barrier, proper isolation, and a good permanent restoration in order to achieve long term success of intracoronar bleaching. This case report shows the benefits of effective bleaching agent while eliminating the associated risks.

REFERENCES

1. Kazue Yul K C, dkk. Effect of Bleaching Agents on the Sealing of Cervical Barrier in Intracoronar Bleaching Procedures. WJD. 2013;4(4) : 235-240.
2. Lim M Y, Lum S O Y, Poh R S C, Lee G P, Lim K C. An In Vitro Comparison of the Bleaching Efficacy of 35% Carbamide Peroxide With Established Intracoronar Bleaching Agents. 2004; 37: 483-488.
3. Hargreaves K M, Berman Louis H. Cohen;s Pathway of The Pulp; Eleventh Edition. Elsevier. 2016: e96-e105.
4. Ontiveros J C and Paravina R D. Color Change of Vital Teeth Exposed

- to Bleaching Performed With and Without Supplementary Light. IJOD. 2009; 1454: 1-8.
5. Neelakantan P and Jagannathan N. Non Vital Bleaching – A Non Invasive Post Endodontic Treatment Option: A Case Report. JCDR. 2012
 6. Correia AMO , Vieira VM , Rocha DM and Mendonça AAM. Aesthetic Restoration of Maxillary Incisors with Composites: Case Report. AJD. 2015; 2(1): 1-3.

LITERATURE REVIEW

ANTIBACTERIAL POTENTIAL OF N-ACETYLCYSTEINE AS AN ENDODONTIC IRRIGANT AGAINST *ENTEROCOCCUS FAECALIS* BIOFILM

Ridzki Ridhalaksani¹, Kamizar², Nilakesuma Djauharie²

¹Conservative Dentistry Residency Program, Faculty of Dentistry,
University of Indonesia, Jakarta, Indonesia.

²Department of Conservative Dentistry, Faculty of Dentistry, University of Indonesia,
Jakarta, Indonesia.
ridzki.r@gmail.com

ABSTRACT

Enterococcus faecalis is pathogenic bacteria commonly found in secondary and persistent endodontic infections, able to adapt to unfavorable conditions, accumulate and produce biofilm. The resulting biofilm help the bacteria to become more resistant to antibacterial agents. The irrigation procedure is one of the keys to successful root canal treatment because the irrigation fluid can reach areas that cannot be touched by mechanical instruments. Antibacterial agents that are often used as irrigation materials and are able to eliminate *E. faecalis* bacteria are sodium hypochlorite (NaOCl) and chlorhexidine (CHX), but these ingredients have toxic effects on adjacent tissues. N-acetylcysteine (NAC) is a non-antibiotic and antioxidant compound that is said to have an antibacterial effect against endodontic pathogenic bacteria, and can damage the mature biofilm so that it can be considered for use as a root canal irrigation material.

Keywords: *Enterococcus faecalis*, biofilm, irrigation, N-acetylcysteine.

INTRODUCTION

The success of root canal treatment according to YL Ng (2007) and Elemam (2011) is between 31% to 88%. (1,2) Failure of well-managed root canal treatment is usually associated with bacterial persistence in the root canal and periradicular system. (3) Bacteria in persistent infections that are commonly found are *E. faecalis*. This

bacteria is 9 times more common in cases of secondary infection than in primary infections. Meanwhile, the prevalence of *E. faecalis* species in root canal tubes can reach 90% of cases. (4) The presence of *E. faecalis* indicates the ability of these bacteria to adapt and have good tolerance to difficult environments. (5)

Some of the durability characteristics of *E. faecalis* are the various genetic forms that it possesses, its ability to invade into the dentin tubule, its ability to adapt to unfavorable conditions, which taken together, supports the formation of highly organized communities in biofilm. (6) The biofilm itself helps the bacteria to become more resistant to phagocytosis, antibodies and antibacterial agents (6,7). To remove bacteria in planktonic or biofilm form in the root canal, a thorough cleaning process should be performed. In addition to careful instrumentation procedures, the remnants of infected tissue and biofilm in the oval or narrow root canal can only be reached using irrigation fluids. (8)

The irrigation fluid often used in irrigation procedures, which is capable of eliminating *E. faecalis* bacteria and is considered as a golden standard antimicrobial agent is chlorhexidine (CHX) 2%. (9) However, CHX at various concentrations can cause apoptosis and necrosis in fibroblast cells, epidermal, dermal and subcutaneous tissues and can decrease the number of osteoblast cells (10,11). Based on the above, irrigation materials are still required that have a low risk of tissue toxicity.

Several previous studies have suggested that N-acetylcysteine (NAC) has an antibacterial effect against endodontic pathogenic bacteria. N-acetylcysteine is not an antibiotic compound but is an antioxidant containing thiol groups and effectively reduces extracellular

production of polysaccharides, destroying mature biofilms in the same way as when functioning as mucolytic agents, (12) and reducing bacterial adhesion. In this paper we will explain in more detail the characteristics of *E. faecalis* bacteria and irrigation materials that can be used as antibacterial ingredients including research on NAC which has the potential to be used as an antibacterial agent of root canal irrigation.

LITERATURE REVIEW

A. Root Canal Treatment

The success of root canal treatment depends on accurate diagnosis, appropriate treatment plan, anatomical knowledge and dental morphology, and good debridement, disinfection and obturation. Eliminating of infected microorganisms and infected pulp tissue or necrosis are the main goals of root canal treatment. (13)

B. Anatomy of the Root Canal

The persistence of a periapical infection of the root canal that has been well rooted can be caused by the complexity of the root canal system. The complexity of the main root canal and the accessory canal, the ramifications or anastomosis of the root can cause continued infection, (3) Even 70% of the causes of recurrence of apical periodontitis after root canal treatment are derived from apical ramifications. (14) The root canal also has an isthmus which is a form of communication between two narrow roots and is ribbon-shaped. All

isthmuses must be cleaned because it can become a gathering place of bacteria. (15)

The shape of the apical root canals are highly variable and unpredictable. The number of variations of the shape and diameter of the root canal complicates the cleaning and shaping procedure (15,16). According to a study by Wu MK et al, 75% of the observed cases indicate that the initial files used during the assessment only come into contact with one wall of the apical root canal, while 25% of other cases do not come into contact at all. (17) This may be due to the oval shape of the root canal apical and the delayed entry of files in the coronal and mid-third sections of the root canal (15-17) (Figures 1 and 2)

The shape of the accessory channel also varies. The channel can be found with a diameter of 67.0 μm , with a length of 786.6 μm , oval shaped and curved, making it difficult to debridement. (18)

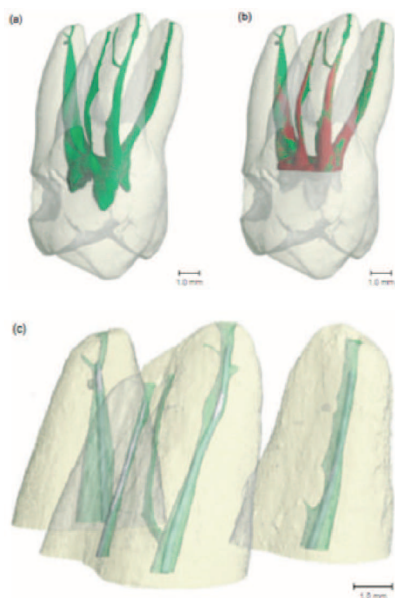


Figure 1. Three dimensional figure of (a) the tooth and root canal prior to treatment and (b) after crown down preparation. The change of root canal not subject to preparation is green, and those subject to preparation are red, and the red dot indicates the unchanged root canal wall. Figure (c) shows one-third of root canals with instrument and area not subject to preparation (16)

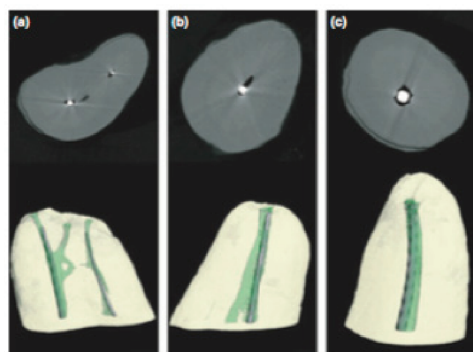


Figure 2. The cross section of a third of the apical tooth and instrument is evaluated in 2 dimension and 3 dimension at (a) mesio Buccal root 1 and 2, (b) distobuccal and (c) palatal (16)

C. Microorganism Root Canal Infection

Root canal disinfection may fail and leave resistant bacteria. Intraradicular infections occurring after treatment of the root canal are usually dominated by Gram-positive bacteria (19) These bacteria include Streptococci (*S. myitis*, *S. gordonii*, *S. anginosus*, and *Streptococcus Oralis*), *Lactobacillus paracasei* and *Lactobacillus acidophilus*, *Staphylococci*, *E faecalis*, *Olsenella uli*, *P. micra*, *Pseudoramibacter alactolyticus* and *Propionibacterium spp.* The prevalence of *E. faecalis* in the root

canals after root canal treatment can come to 90% of the cases (4), with the proportion in the root canals between 1% up to 39.26%. (20)

Bacteria in the root canal may be planktonic or in biofilms (6,21) Organized bacteria in biofilms are usually untouched by mechanical cleaning processes. (19) One of the bacteria that supports the formation of highly organized communities in biofilms is *E.faecalis*. (6)

C.1 *Enterococcus Faecalis*

The origin of *Enterococcus faecalis* found in root canals is still under discussion. Bacteria can come from blood, faeces and food. However, based on the virulence factor, *E. faecalis* bacteria found in root canals have more in common with strains of bacteria derived from food and faeces. These virulence factors include GelE, efaA (*E. faecalis* endocarditis antigen) and Ace. (22)

This bacterium is a Gram-positive bacterium spherical or ovoid in form with a size of 0.6-2.0 x 0.6-2.5 μm , it moves using a small flagella and has a capsule that is not too defined. Ninety percent of the bacterial cell wall is composed of peptidoglycan and anionic polymers (teichoic acid and polysaccharide cell wall), rounded off by 10% protein. (23) *Enterococcus faecalis* is able to penetrate into the dentine tubule as far as 100-400 μm , (24) and pass through minor constriction as far as 140-160 μm by cell division. (25) *Enterococcus faecalis* is commonly found as a single, paired, or

short-chain bacterium. (26)

The enterococcal bacteria are facultative anaerobic bacteria, that can live in an atmosphere of less oxygen, can produce energy by fermentation, and produce L(+)-lactic acid without gas with pH 4,2-4,6. (26) In addition, this bacteria can grow at a temperature of 10-45° (optimum temperature of 37°) and pH 4.0-11. *Enterococcus faecalis* is also able to survive at 60°C for 30 minutes, pH 9.6, 6.5% NaCl and 40% bile. (25,26)°.

Various factors of enterococcal virulence play a role in the process of attachment of the bacteria to the host tissue, the formation of abscesses, modulate the inflammatory response, and the secretion of products that can form biofilm. These substances include lipoteichoic acid, (27) Enterococcus surface protein (Esp), Adhesin to collagen of *E.faecalis* (Ace) or collagen binding protein, GelE, aggregate substance (AS), (20) proteases, toxins such as cytolysin and pheromones, (28) and also fli. (29)

Adhesion proteins belonging to *E. faecalis* include Esp and Ace, which can mediate the attachment of enterococcus to the host tissue. (29) The attachment to collagen is strengthened by the internal disulfide bond held by the Ace. (23) Enterococcus Surface Proteins located on the cell wall of bacteria also plays a role in the formation of biofilm. Meanwhile, GelE secreted by *E. faecalis* is a Zn-metalloprotease that plays a role together with Ace in the attachment of the bacteria

to dentine. (22)

The aggregate substance (AS) in *E. faecalis* is also a surface adhesion that mediates intercellular contact during plasmid transfer, facilitates translocation of intestinal epithelial cells, mediates adhesion to renal epithelial cells, and also increases the period of survival within PMN cells and macrophages. (22,29)

C.2 *Enterococcus Faecalis* Biofilm

The growth of pure planktonic bacteria is rare in the real environment. In fact, more bacteria are found in complex forms in biofilms, although they are not in contact. In this biofilm the bacteria are 1000 times more resistant to phagocytic processes, antibodies and various antibiotics. (20)

Biofilms are a form of microbial growth in which there is an immovable and interacting bacterial community on self-produced substance in the form of an extracellular polymer matrix. The extracellular matrix is 3-dimensional and serves as a cell attachment scaffold.³⁰ The extracellular matrix is a hydrated exopolysaccharide polyanion complex such as β -1,6-N-acetyl-D-glucosamine polymerized, cellulose, cholan acid polymer branch, protein, and DNA bacteria. (12) (Figure 3)

In addition to being resistant to antibacterial agents, the existence of biofilms gives the bacteria an additional advantage in that the nutrients are more concentrated, opening up opportunities

for genetic material exchange, facilitating communication between populations of bacteria in the same or different species, also called *quorum sensing* mechanisms that can produce inter-species growth factor.(28,31)

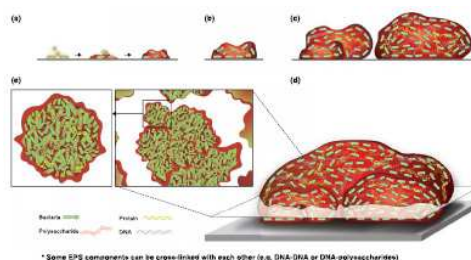


Figure 3 EPS matrix and biofilm formation.

(a-c) EPS are deposited on surfaces that initiate local adhesions and accumulations of microorganisms, to form building-like structures. Figure(d,e), shows the cross sections of the complex structure of the multi-microcolony biofilm. The diagram shows the matrix components such as polysaccharides, protein, and eDNA. This complexity is enhanced by the presence of polymers such as ionic or *nucleic acid-binding proteins*. (30)

The biofilms formed under different conditions affect the physico-chemical biofilms formed. Nutrient-rich environmental conditions, regardless of aerobic or anaerobic, produce a biofilm structure with bacterial aggregates located on the surface with a water channel. While in minimal nutrient conditions, biofilms are formed like irregular clumps of cells (28) (Figure 4) Nutrition and essential elements required by bacteria in metabolism are passed in by passively through water channels or by

electrostatic interactions and are trapped in them. In conditions of minimal glucose, exopolysaccharide produced by bacteria undergo changes. The production of water-soluble exopolysaccharide (WSE) declines and is replaced by the production of water-insoluble exopolysaccharide (WIE). (32)

While in a high pH environment, more biofilm is produced and may undergo maturation and calcification in order to maintain its stabilization in the root canal (19,32,33)




Figure 4 Biofilm morphology of *E. faecalis* formed in low nutritional conditions. (a) after 1 week with bacterial colonies above dentin and (b) 4 weeks in more irregular shape. (c) *E. faecalis* formed in rich nutrients, after 1 week. Polymer braid between the *E. faecalis* bacterial chain is visible. At week 4, the biofilm is seen more evenly covering the dentin with water channel between them (28)

D. Irrigation Material which is Effective against *E. faecalis*

Irrigation, which is one of the procedures in root canal treatment, is one of the keys to successful root canal treatment. The ideal conditions of the irrigation materials are: it being an

effective bactericidal and fungicidal, is non-irritating to the periapical tissue, stable, and has long-term antimicrobial effects. It also should remain active in the presence of blood, serum, and tissue-derived proteins. Irrigation materials are also expected to have low surface tension, do not cause intervention to healing of periapical tissue, do not cause staining, is capable of inactivation in culture medium, does not induce immune response, is capable of cleaning the smear layer and disinfect the underlying dentinal tubuli. In addition, irrigation materials should also be nonantigenic, non-toxic, noncarcinogenic to adjacent tissues, have no side effects on dentin physical properties, have no side effects on sealing ability, are easy to apply and relatively cheap.

D.1 Sodium Hypochlorite

Sodium hypochlorite when used in general, has a concentration ranging from 0.5-6% NaOCl, pH 11 and is hypertonic. Low NaOCl concentrations, say between 0.5-1% are able to dissolve most of the necrotic tissues. Higher concentrations have higher dissolving power.

When NaOCl is ionized in water it will form Na^+ ions and hypochlorite ions (OCl^-), and will survive in equilibrium to form hypochlorous acid (HOCl). At acidic and neutral pH, the chlorine formed is HOCl , while at pH 9 or more, the OCl^- ions dominate. Chlorine is an unstable material and is easily lost in the first phase of tissue dissolution or within 2 minutes. Therefore

irrigation must be done continuously with new material (8.34)

The effectiveness of the antibacterial NaOCl against *E. faecalis* according to a study by Radcliffe CE et al (2003) is that *E. faecalis* is more resistant to NaOCl than with *Actinomyces* and *C. albicans*, so that when eliminating *Actinomyces* and *C. albicans* requires only 0.5% NaOCl in 10 second, but to eliminate *E. faecalis* it takes 2.5% NaOCl more than 2 minutes and it takes 5.25% NaOCl more than 1 minute to get the same result.(35) Different results are shown by research conducted by Retamozo et al (2010), which states that to eliminate bacteria and biofilms of *E. faecalis* inoculated for 3 weeks requires NaOCl with a concentration of 5.25% for 40 min. (36)

The ability of this material to dissolve vital tissue is an unfavorable side effect of NaOCl. (37) Another possible side effect when NaOCl is pushed through the apical foramen is severe and prolonged pain, and may lead to hypersensitivity and contact dermatitis reactions.(38) Furthermore, at very low concentrations of 0.05% NaOCl showed a toxic reaction to fibroblast cells (39.40)

Combination of NaOCl with EDTA will eliminate the antibacterial effect of NaOCl. Even the EDTA-exposed tissue can no longer be effectively dissolved by NaOCl. (38) If EDTA or citric acid is used to remove the smear layer on dentine then NaOCl should not be reapplied as it may cause erosion of the dentine. (38)

Also, Sodium hypochlorite may not be combined directly with Chlorhexidine (CHX) because the contact of NaOCl with Chlorhexidine will form a carcinogenic para-chloroaniline (PCA) precipitate. (41,42)

D.2 Chlorhexidine

Chlorhexidine is a polybiguanide class antibacterial agent consisting of 2 symmetric rings of 4 chlorophenyl groups and 2 bis-guanides incorporated with hexamethylene chains [1,6,6-di (4-chlorophenyl-diguanido) hexane]. (43) Chlorhexidine is a strong and stable basic molecule like salt. (37,43)

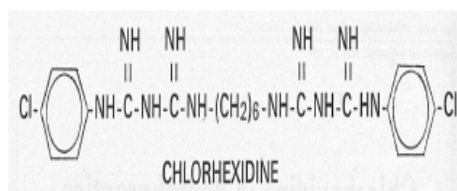


Figure 5.Chlorhexidine molecule (43)

Chlorhexidine is effective against gram-positive bacteria and gram-negative bacteria, as well as fungi. Chlorhexidine has 2 positive charges distributed around the nitrogen atoms that are bridged by the hexamethylene chain. Its positive charge allows the CHX to bind to the negative surface of the bacterial cell wall. And because most of the intraoral surfaces are negatively charged these molecules are easily distributed and not easily released. (43) Chlorhexidine is able to bond electrostatically with the negative surface of the bacteria, damaging the outer wall

of the cell, making it more permeable, and disturbing the balance of bacterial cell osmosis.(8)

At different concentrations CHX can be bacteriostatic and bactericidal. At high concentrations CHX acts as a detergent as it may cause cytoplasmic precipitation. At low concentrations CHX can cause leakage of small molecular substances such as potassium and phosphorus in cells without causing irreversible damage. Chlorhexidine may also affect bacterial metabolism by blocking transport activity of the sugar phosphotransferase system (PTS) and inhibiting acid production in some bacteria. (38)

Chlorhexidine can be absorbed into the walls of dentin or has substantivity properties and causing antimicrobial effects. However, CHX does not have the ability to dissolve tissue, so NaOCl is still used as the main irrigation agent in root canal treatment. (37)

According to Ma J et al (2015) CHX 0.2-2% effectively eliminate *E. faecalis* bacteria in both planktonic and biofilm forms. A significant and constant decrease in the biofilm of *E. faecalis* from the first 2 hours to 24 hours may then be due to CHX's substantivity ability. (44)

Also, according to Bottcher et al (2015), the ability of substantivity of CHX with a concentration of 2% can be observed up to 7 days. This is supported by the low number of *E. faecalis* bacteria that can survive at 48 hours and 7 days. But after

30 days, using confocal laser scanning microscopy, the number of *E. faecalis* bacteria will increase again. This result is inversely proportional to decreasing CHX levels. (45)

The toxicity reaction of CHX is lower than that of NaOCl, however CHX at various concentrations can cause apoptosis and necrosis of fibroblast cells and epidermal, dermal and subcutaneous tissue, and decrease the number of osteoblast cells. (10,11) In addition, CHX applications affects the life of STRO-1-enriched stem cells from the apical papilla (SCAP) within the root canal, therefore it does not support the endodontic regenerative procedures. (46) As mentioned earlier, the combination of CHX medication with NaOCl may also lead to the formation of toxic products, e.g. parachloroaniline (PCA). Exposure of tissue by PCA can lead to methemogloblins, followed by haemolytic anemia, extra medullary haematopoiesis and splenomegaly due to erythrocyte toxicity and regenerative anemia. (42)

D.3 MTAD, Tetraclean and QMix

To improve the effectiveness of existing irrigation material, currently mixed irrigation material have been produced using antibiotics or chlorhexidine mixed with detergent. Irrigating materials containing antibiotics include MTAD. BioPureMTAD (Dentsply, Tulsa, OK) and Tetraclean, while material containing chlorhexidine mixture is called QMiX.

MTAD. BioPureMTAD (Dentsply,

Tulsa, OK) is a mixture of isomers of tetracycline, acetic acid, and Tween 80 detergents (MTAD). Tetraclean is also a mixture of doxycycline antibiotics (50 mg / ml), acid and polypropylene glycol detergent. QMiX is an irrigant material for removal of smear layers added by antimicrobial agents. This material contains EDTA, CHX, and detergents. The mixing of EDTA and CHX is known to produce a white precipitate, but in Qmix this precipitate is not formed due to its chemical design. (5)

According to Prabhakar (2010), MTAD is said to be effective against *E. faecalis*, able to inhibit bacterial growth in biofilms and less cytotoxic. (47,48) However, research by Giardino et al (2007) suggests that the ability of Biopure MTAD to remove biofilms is lower than with Tetraclean and NaOCl 5.25%. In this study NaOCl 5.25% was able to remove biofilms in 5 min, while Tetraclean was able to reduce the biofilm count by 90% after 5 min, and to remove all biofilms produced by *E. faecalis* a period of 60 min is required, which is well below the ability of 5.25 % NaOCl. Meanwhile, MTAD is only able to remove some biofilms in the 30th minute and the biofilm will rise again afterwards. (49)

Although the use of antibiotics in these antibacterial agents provides advantages in disinfection, but antibiotics can cause resistance, allergies, angiogenesis inhibition and dye staining. Therefore its use should be seriously considered and

it should only be administered when it is really needed. (50)

D.4 N-acetylsysteine

N-acetylcystein(NAC)[C₅H₉NO₃S], is a derivative of the L-cysteine amino acid, which is a widely used antioxidant in the medical world which is administered by inhaling, orally or intravenously in cases of chronic bronchitis or acetaminophen overdose and is very safe. N-acetylcysteine is an antioxidant because it plays a role in the donor L-cysteine needed in the synthesis of glutathione (GSH). Glutathione itself is an intracellular tripeptide antioxidant that effectively reduces the lipid, protein and nucleic acid oxidation effects. (51) N-acetylcysteine is also said to be a molecule that can increase osteogenesis in bone regeneration.(52) N-acetylcysteine is available in the form of a 200-mg capsule with a pH of 2.5 and an injection / inhalation drug of 100 mg / ml with a pH of 7 (53).

Other than that, the addition of NAC to bonding agents can increase the activity of alkaline phosphatase (ALP) or enzymes that play a role in mineralization. In contrast, the bonding agent extract alone inhibits ALP activity, so that NAC is inferred to reduce the cytotoxicity effect of the resin contained in the bonding agent. (54)

N-acetylcysteine has anti-inflammatory activity because it blocks the expression and release of various proinflammatory cytokines, such as NF-KB activation and TNF- α release

on Kupffer cells, it also impedes the matrix metalloproteinase-9, IL-8, IL-6, NF-kB and TNF - α in the human fetus membrane. N-acetylcysteine also reduces the expression of IL-1 β and the production of eotaxin and monocyte chemotactic protein-1 in the respiratory muscle cells, and IL-8 that regulates blood CD11b. (55)

In addition NAC is a non-antibiotic compound that has antimicrobial effects by reducing the formation of biofilm produced by various bacteria, among others *Pseudomonas aeruginosa*, *Escheria coli*, *Staphylococcus epidermis*, *Streptococcus pneumonia*, *Staphylococcus aureus*, *Klebsiella pneumonia*, *Prevotella intermedia*, and biofilm produced by the combination of several bacteria as for instance *Actinomyces naeslundii*, *Lactobacillus salivarius*, *Streptococcus mutans*, and *Enterococcus faecalis*.(55)

The active part of NAC is the thiol (-SH) group which acts as a free-radical scavenger and can cause intermolecular or intramolecular destruction of disulfide bonds in proteins. The reaction of the -SH group to the disulfide bond of this bacterial protein causes irreversible damage to bacterial proteins that are essential for bacterial growth and metabolism. This mechanism is also the way NAC works to destroy the 3-dimensional structure of the biofilm and dilute the mucus. (12,56,57)

N-acetylcysteine may also inhibit the formation of biofilms in the presence of sulfhydryl groups that release the disulfide bonds of bacterial enzymes involved in

the production or excretion of EPS during thiol-disulfide group exchange. The antioxidant effects of NAC are also said to have an indirect impact on cell metabolism and EPS production. (58)

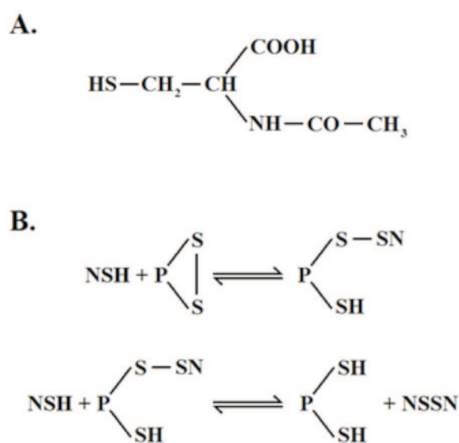


Figure 6A)Chemical formula of N-acetylcysteine (NAC); Disulfide bonds of proteins, both proteins present in biofilms and in bacteria, can be damaged by NAC with B)the two step exchange reactions of the thiol-disulfidegroup

According to Quah SY et al (2012), the efficiency of the thiol-disulfide group exchange may be affected by the protonation of thiol groups derived from the sodium hydroxide (NaOH) hydroxyl group, which causes the formation of thiolate anions (-S-). Therefore, pharmacokinetics and effectiveness of NAC will give different results at different pH conditions. Still according to this study, NAC will more effectively kill planktonic and biofilm forms of *E. faecalis* ATCC 29212 at pH 11, and its antibacterial effect is also unaffected by dentin powder. This is in contrast to Ca(OH)₂ which loses its

antibacterial power after dentine powder is added as an analogy of the buffering effect of dentine in the root canal. (58)

Table1 Minimum Inhibition Concentration (MIC) and Minimum Bactericidal Concentration (MBC) of NAC at pH 7,9and 11(Quah, 2012)(58)

	pH 7	pH 9	pH 11
MIC of NAC (mg/mL)	>200	200	1,56*
MBC of NAC (mg/mL)	>200	>200	12,5*

*Thiol-disulfide Group Exchange, more likely at pH 11

Meanwhile, Darrag AM (2013) states that NAC 200mg / ml without changes in pH used as irrigation material for 5 minutes can kill *E. faecalis* ATCC 29212 and *S. mutans* ATCC 25175 both in planktonic and in biofilm form. Both bacteria experienced significant decrease after being irrigated with NAC compared to CHX 2% and NaOCl 5.25%.(6) This study used concentrations which issimilar to the study of Cindy HR et al (2013), which states that NAC 200 mg / ml provides a good antibiofilm effect against bacteria in the oral cavity.(59)

DISCUSSION

The complexity of the main root canals and the accessory channels, also the ramifications or anastomosis of the channel will make it difficult to maximize the cleaning using mechanical

instruments and eventually the bacteria will be well organized in the biofilms produced by *E.faecalis*. The structural change of biofilms when it is in a difficult environment accompanied by density of the biofilms makes it increasingly difficult forthe antibacterial ingredients to penetrate into it.

Although the study of antibacterial agents currently available still exhibit different results but irrigation materials that have good effectiveness on *E.faecalis* are Sodium hypochlorite with a concentration of 5.25% and Chlorhexidine 2%. Sodium hypochlorite has been shown to eliminate *E.faecalis* bacteria in both planktonic and biofilm forms. Another advantage of this material is its ability to dissolve necrotic tissue. However, the toxicity of this material is still feared for use in high concentrations.

Chlorhexidine is also a potent antibacterial agent against *E.faecalis* bacteria, although the results of existing studies still show contradictions. The beneficial potential of this material may be present in its cationic properties enabling it to survive in anionic tissues and continue to have an antibacterial effect. However, additional research is needed to observe the long term effectiveness of this material. The effect of these antibacterial agents on the viability of fibroblast cells, osteoblast cells and STRO-1-enriched stem cells from the apical papilla (SCAP) in root canals, and PCA that may be formed when combined with NaOCl should be considered in its use

as a supportive irrigation agent to heal the periapical tissue.

Other studies have also shown that chlorhexidine, MTAD, QMix are highly potent against planktonic bacteria but are less effective at eliminating *E. faecalis* bacteria in biofilms. Meanwhile, the irrigation material capable of removing *E. faecalis* biofilm is Tetraclean, although the antibiotic content in it should be given serious consideration because of the risk of resistance.

It can be observed that irrigation materials that are currently in use have not been able to meet all the requirements of the ideal irrigation materials. As for now, to achieve results that are close to optimal, these materials must still be combined in a specific way and mixture to achieve a good root canal treatment result.

N-acetylcysteine, which has been used in the medical profession for bronchitis and as a relieve for overdose in acetaminophen treatment, should be considered for use in root canal irrigation. The antimicrobial effects of this material against planktonic bacteria and the ability of these substances in proteins can inhibit biofilm formation and destroy the 3-dimensional structure of the biofilm. In addition NAC is also an antioxidant molecule that can increase osteogenesis in bone regeneration.

The thiol (-SH) group of NAC is a sulfur and hydrogen atom attached by a strong covalent bond. The reaction of the -SH group to the disulfide bond of the

bacterial protein causes irreversible damage to bacterial proteins that are essential for bacterial growth and metabolism. One of the proteins produced by *E. faecalis* that has a disulfide bond is Ace and a bacterial enzyme involved in the production or excretion of EPS. The antioxidant effects of NAC are also said to have an indirect impact on cell metabolism and EPS production.

When the NAC pH is increased by the addition of sodium hydroxide (NaOH), the hydroxyl group (-OH) derived from NaOH releases the covalent bond and produces a reactive thiolate anion (-S⁻). Thiolate anion is more effective in breaking the protein disulfide bonds in biofilms. Because of the broken disulfide bonds on the 3-dimensional structure of the *E. faecalis* biofilm, it becomes easier for the NAC active agent to make an exchange in the thiol-disulfide groups of the bacteria in the biofilm. This can lead to intermolecular and intramolecular destruction of proteins at the bacterial wall as well as destruction of the molecules produced by the bacteria and decreasing the virulence factors of *E. faecalis* bacteria.

CONCLUSION

E. faecalis biofilms in complex root canals are difficult to clean and cause bacteria to become more resistant to antibacterial agents. Most current root canal irrigation materials have been able to kill *E. faecalis* bacteria, but the toxicity and resistance risk of these ingredients is still high.

N-acetylcysteine which is a non-antibiotic compound can be used as a root canal irrigation material due to its ability to break the disulfide bond of the bacterial protein, thus causing irreversible damage to bacterial proteins that are essential for bacterial growth and metabolism. The destruction of proteins can inhibit biofilm formation and destroy the 3-dimensional structure of biofilms. In addition NAC is also an antioxidant molecule that can increase osteogenesis in bone regeneration.

SUGGESTIONS

Given the differences in methods in previous studies, further research should be carried out to determine the appropriate concentrations and pH values in order to obtain the ideal or optimal root canal irrigation material. Also a research should be undertaken to study the basic properties of NAC in liquid form that can meet the requirements of an ideal irrigation material.

REFERENCE

1. Ng YL, Mann V, Rahbaran S, Lewsey J, Gulabivala K. Outcome of primary root canal treatment: Systematic review of the literature - Part 1. Effects of study characteristics on probability of success. *Int Endod J*. 2007;40(12):921–39.
2. Elemam RF, Pretty I. Comparison of the success rate of endodontic treatment and implant treatment. *ISRN Dent* [Internet]. 2011;2011:640509. Available from:
3. Nair PNR. On the causes of persistent apical periodontitis: A review. *Int Endod J*. 2006;39(4):249–81.
4. Teles AM, Manso MC, Loureiro S, Pina C, Cabeda J. Microorganisms: the reason to perform Endodontics. *Microb Pathog Strateg Combat them Sci Technol Educ*. 2013;1778–86.
5. John G, Kumar KP, Gopal SS, Kumari S, Reddy BK. *Enterococcus faecalis*, a nightmare to endodontist: A systematic review. 2015;9(13):898–908.
6. Darrag AM. Antimicrobial efficacy of endodontic irrigation solutions against planktonic microorganisms and dual-species biofilm. *Tanta Dent J* [Internet]. 2013;10(3):129–37. Available from: <http://www.sciencedirect.com/science/article/pii/S1687857413000243>
7. Madhav VN. of Dental Sciences. *Indian J Dent Sci*. 2012;4(4):123–6.
8. Haapasalo M, Shen Y, Qian W, Gao Y. Irrigation in Endodontics. *Dent Clin North Am*. 2010;54(2):291–312.
9. Chandrappa PM, Dupper A, Tripathi P, Arroju R, Sharma P, Sulochana K. Antimicrobial activity of herbal medicines (tulsi extract, neem extract) and chlorhexidine against *Enterococcus faecalis* in Endodontics: An in vitro study. *J Int Soc Prev Community Dent* [Internet]. 2015;5(Suppl 2):S89-92. Available from: <http://www.ncbi.nlm.nih.gov/pubmed/26942123>

10. Faria G, Cardoso CRB, Larson RE, Silva JS, Rossi MA. Chlorhexidine-induced apoptosis or necrosis in L929 fibroblasts : A role for endoplasmic reticulum stress. *Toxicol Appl Pharmacol* [Internet]. Elsevier Inc.; 2009;234(2):256–65. Available from: <http://dx.doi.org/10.1016/j.taap.2008.10.012>
11. Vörös P, Dobrindt O, Perka C, Windisch C, Matziolis G, Röhner E. Human osteoblast damage after antiseptic treatment. 2014;177–82.
12. Makipour K, Friedenber FK. The Potential Role of N-Acetylcysteine for the Treatment of Helicobacter pylori. *J Clin Gastroenterol* [Internet]. 2011;45(10):841–3. Available from: <http://www.ncbi.nlm.nih.gov/pubmed/22414444>
13. Peters OA, Noblett WC. Cleaning and Shaping. In: Torabinejad M, Walton RE, Fouad AF, editors. *Endodontics: Principles and Practice*. 5th ed. St. Louis; 2015. p. 273–300.
14. M. WADA, T. TAKASE, K. NAKANUMA, K. ARISUE, F. NAGAHAMA & MY. Clinical study of refractory apical periodontitis treated by apicectomy Part 1 . Root canal morphology of resected apex. *Int Endod J*. 1998;31:53–6.
15. Vertucci FJ, Haddix JE. Tooth Morphology and Access Cavity. In: Hargreaves KM, Cohen S, editors. *Cohen's Pathway of the Pulp*. 10th ed. St. Louis; 2011. p. 136–222.
16. Paqu?? F, Zehnder M, Marending M. Apical fit of initial K-files in maxillary molars assessed by micro-computed tomography. *Int Endod J*. 2010;43(4):328–35.
17. Wu MK, Barkis D, Roris A, Wesselink PR. Does the first file to bind correspond to the diameter of the canal in the apical region? *Int Endod J*. 2002;35(3):264–7.
18. Xu T, Tay FR, Gutmann JL, Fan B, Fan W, Huang Z, et al. Micro-Computed Tomography Assessment of Apical Accessory Canal Morphologies. *J Endod* [Internet]. Elsevier Ltd; 2016;42(5):798–802. Available from: <http://dx.doi.org/10.1016/j.joen.2016.02.006>
19. Di Filippo G, Sidhu SK, San Chong B. The role of biofilms in endodontic treatment failure. *Endod Pract Today*. 2014;8(Table 1):87–103.
20. Wang L, Dong M, Zheng J, Song Q, Yin W, Li J, et al. Relationship of biofilm formation and gelE gene expression in enterococcus faecalis recovered from root canals in patients requiring endodontic retreatment. *J Endod* [Internet]. Elsevier Ltd; 2011;37(5):631–6. Available from: <http://dx.doi.org/10.1016/j.joen.2011.02.006>
21. Jiang C, Schaudinn C, Jaramillo DE, Webster P, Costerton JW. In Vitro Antimicrobial Effect of a Cold Plasma Jet against Enterococcus faecalis

- Biofilms. ISRN Dent [Internet]. 2012;2012:295736. Available from: <http://www.pubmedcentral.nih.gov/articlerender.fcgi?artid=3302053&tool=pmcentrez&rendertype=abstract>
22. Vidana R, Sullivan A, Billström H, Ahlquist M, Lund B. Enterococcus faecalis infection in root canals - host-derived or exogenous source? Lett Appl Microbiol. 2011;52(2):109–15.
 23. Hancock LE, Murray BE, Sillanpää J. Enterococcal Cell Wall Components and Structures. Enterococci From Commensals to Lead Causes Drug Resist Infect [Internet]. 2014;1–35. Available from: <http://www.ncbi.nlm.nih.gov/pubmed/24649506>
 24. Zapata RO, Bramante CM, de Moraes IG, Bernardineli N, Gasparoto TH, Graeff MSZ, et al. Confocal Laser Scanning Microscopy Is Appropriate to Detect Viability of Enterococcus faecalis in Infected Dentin. J Endod. 2008;34(10):1198–201.
 25. Rahul H, Mithra HN, Kiran H. Penetration of E . faecalis into Root Cementum Cause for Reinfection. 2014;4(24):4115–22.
 26. Staley JT, Williams ST. Gram-Positive Cocci. In: Holt JG, Krieg NR, HA SP, Staley JaT, Williams ST, editors. Bergey's Manual of Determinative Bacteriology. 9th ed. Baltimore: Lippincott Williams & Wilkins; 1994. p. 528–38.
 27. Elsner H a, Sobottka I, Mack D, Claussen M, Laufs R, Wirth R. Virulence factors of Enterococcus faecalis and Enterococcus faecium blood culture isolates. Eur J Clin Microbiol Infect Dis. 2000;19(1):39–42.
 28. Baumgartner JC, Siqueira JF, Sedgley christine M, Kishen A. Microbiology of Endodontic Disease. In: Ingle JI, Bakland LK, Baumgartner JC, editors. Ingle's Endodontics. 6th ed. Shelton: People's Medical Publishing House; 2008. p. 221–308.
 29. Budzik JM, Schneewind O. Pili prove pertinent to enterococcal endocarditis. J Clin Invest. 2006;116(10):2582–4.
 30. Koo H, Yamada KM. Dynamic cell-matrix interactions modulate microbial biofilm and tissue 3D microenvironments. Curr Opin Cell Biol [Internet]. Elsevier Ltd; 2016;42(1):102–12. Available from: <http://dx.doi.org/10.1016/j.ceb.2016.05.005>
 31. Li YH, Tian X. Quorum sensing and bacterial social interactions in biofilms. Sensors. 2012;12(3):2519–38.
 32. Ran S, Gu S, Wang J, Zhu C, Liang J. Dentin tubule invasion by Enterococcus faecalis under stress condition ex vivo. Eur J Oral Sci. 2015;123(5):362–8.
 33. Kishen A, George S, Kumar R. Enterococcus faecalis-mediated biomineralized biofilm formation on root canal dentine in vitro. J Biomed Mater Res - Part A. 2006;77(2):406–

- 15.
34. Berman LH, Hargreaves KM, Cohen SR. Cohen's Pathways of the Pulp Expert Consult [Internet]. Elsevier Health Sciences; 2010. Available from: <https://books.google.co.id/books?id=Jl7gSo5zcWEC>
35. Radcliffe CE, Potouridou L, Qureshi R, Hababbeh N, Qualtrough A, Worthington H, et al. Antimicrobial activity of varying concentrations of sodium hypochlorite on the endodontic microorganisms *Actinomyces israelii*, *A. naeslundii*, *Candida albicans* and *Enterococcus faecalis*. *Int Endod J*. 2004;37(7):438–46.
36. Retamozo B, Shabahang S, Johnson N, Aprecio RM, Torabinejad M. Minimum Contact Time and Concentration of Sodium Hypochlorite Required to Eliminate *Enterococcus faecalis*. *J Endod* [Internet]. Elsevier Ltd; 2010;36(3):520–3. Available from: <http://dx.doi.org/10.1016/j.joen.2009.12.005>
37. Metzger Z, Basrani BR, Goodis HR. instrument, materials, and devices. In: Hargreaves KM, Cohen SR, Berman LH, editors. *Cohen's Pathway of the Pulp*. 10th ed. St. Louis: Mosby Elsevier; 2011. p. 223–82.
38. Basrani B, Haapasalo M. Update on endodontic irrigating solutions. *Endod Top*. 2012;27:74–102.
39. Simbula G, Dettori C, Camboni T, Cotti E. Comparison of tetraacetylenediamine + sodium perborate and sodium hypochlorite cytotoxicity on L929 fibroblasts. *J Endod* [Internet]. Elsevier Ltd; 2010;36(9):1516–20. Available from: <http://dx.doi.org/10.1016/j.joen.2010.05.010>
40. Hidalgo E, Bartolome R, Dominguez C. Cytotoxicity mechanisms of sodium hypochlorite in cultured human dermal fibroblasts and its bactericidal effectiveness. *Chem Biol Interact*. 2002;139(3):265–82.
41. Cintra LTA, Watanabe S, Samuel RO, da Silva Facundo AC, de Azevedo Queiroz ÍO, Dezan-Júnior E, et al. The use of NaOCl in combination with CHX produces cytotoxic product. *Clin Oral Investig*. 2014;18(3):935–40.
42. Basrani BR, Manek S, Sodhi RNS, Fillery E, Manzur A. Interaction between Sodium Hypochlorite and Chlorhexidine Gluconate. *J Endod*. 2007;33(8):966–9.
43. Journal W, Sciences P, Kaur G, Singh A, Patil KP, Nayyar AS, et al. Chlorhexidine : a Cationic Bisbiguanide, Membrane Active Drug in Periodontal Medicine , Structure-Advantages and Associated Adverse Effects , a Brief. 2015;4(7):370–92.
44. Ma J, Tong Z, Ling J, Liu H, Wei X. The effects of sodium hypochlorite and chlorhexidine irrigants on the antibacterial activities of alkaline media against *Enterococcus faecalis*. *Arch Oral Biol* [Internet]. Elsevier

- Ltd; 2015;60(7):1075–81. Available from: <http://dx.doi.org/10.1016/j.archoralbio.2015.04.008>
45. B??tcher DE, Sehnem NT, Montagner F, Fatturi Parolo CC, Grecca FS. Evaluation of the Effect of Enterococcus faecalis Biofilm on the 2% Chlorhexidine Substantivity: An InVitro Study. J Endod. 2015;41(8):1364–70.
 46. Trevino EG, Patwardhan AN, Henry MA, Perry G, Dybdal-Hargreaves N, Hargreaves KM, et al. Effect of irrigants on the survival of human stem cells of the apical papilla in a platelet-rich plasma scaffold in human root tips. J Endod [Internet]. Elsevier Ltd; 2011;37(8):1109–15. Available from: <http://dx.doi.org/10.1016/j.joen.2011.05.013>
 47. Prabhakar A, Basappa N, Basavraj P. Comparative evaluation of Morinda citrifolia with chlorhexidine as antimicrobial endodontic irrigants and their effect on micro-hardness of root canal dentin: An in vitro study. Int J Oral Heal Sci [Internet]. 2013;3(1):5. Available from: <http://www.ijohsjournal.org/text.asp?2013/3/1/5/122086>
 48. Newberry BM, Shabahang S, Johnson N, Aprecio RM, Torabinejad M. The Antimicrobial Effect of Biopure MTAD on Eight Strains of Enterococcus faecalis: An In Vitro Investigation. J Endod. 2007;33(11):1352–4.
 49. Giardino L, Ambu E, Savoldi E, Rimondini R, Cassanelli C, Debbia EA. Comparative Evaluation of Antimicrobial Efficacy of Sodium Hypochlorite, MTAD, and Tetraclean Against Enterococcus faecalis Biofilm. J Endod. 2007;33(7):852–5.
 50. Bansal R, Jain A. Overview on the Current Antibiotic Containing Agents Used in Endodontics. N Am J Med Sci [Internet]. India: Medknow Publications & Media Pvt Ltd; 2014 Aug;6(8):351–8. Available from: <http://www.ncbi.nlm.nih.gov/pmc/articles/PMC4158642/>
 51. Casanova T, Garigliany M. N-acetylcysteine: An Old Drug With Variable Anti-Influenza Properties. J Controv Biomed Res. 2016;2(1):1–8.
 52. Yamada M, Tsukimura N, Ikeda T, Sugita Y, Att W, Kojima N, et al. N-acetyl cysteine as an osteogenesis-enhancing molecule for bone regeneration. Biomaterials [Internet]. Elsevier Ltd; 2013;34(26):6147–56. Available from: <http://dx.doi.org/10.1016/j.biomaterials.2013.04.064>
 53. POM D. Farmakope Indonesia. IV. Jakarta: Departemen Kesehatan R.I; 1995. 1124 p.
 54. Kim NR, Park HC, Kim I, Lim BS, Yang HC. In vitro cytocompatibility of n-acetylcysteine-supplemented dentin bonding agents. J Endod [Internet]. Elsevier Ltd; 2010;36(11):1844–50. Available from: <http://dx.doi.org/10.1016/j.jend.2010.08.008>

org/10.1016/j.joen.2010.08.005

55. Moon J-H, Choi Y-S, Lee H-W, Heo JS, Chang SW, Lee J-Y. Antibacterial effects of N-acetylcysteine against endodontic pathogens. *J Microbiol* [Internet]. 2016;54(4):322–9. Available from: <http://www.ncbi.nlm.nih.gov/pubmed/27033208>
56. Dinicola S, De Grazia S, Carlomagno G, Pintucci JP. N-acetylcysteine as powerful molecule to destroy bacterial biofilms. A systematic review. *Eur Rev Med Pharmacol Sci*. 2014;18(19):2942–8.
57. Poole PJ. Role of mucolytics in the management of COPD. *Int J Chron Obstruct Pulmon Dis*. 2006;1(2):123–8.
58. Quah SY, Wu S, Lui JN, Sum CP, Tan KS. N-acetylcysteine inhibits growth and eradicates biofilm of enterococcus faecalis. *J Endod* [Internet]. Elsevier Ltd; 2012;38(1):81–5. Available from: <http://dx.doi.org/10.1016/j.joen.2011.10.004>
59. Cindy H, Rene H, Sergio G, Diana R. Rifampicin and N-acetylcysteine Inhibit Oral Bacterial Growth and Biofilm Formation. *Pharma Innov - J*. 2013;2(Mic):16–23.

BLEACHING TECHNIQUE FOR DISCOLORATION IN POST ENDODONTIC TREATMENT TOOTH : A CASE REPORT

Makkunrai Eka Kramatawati Elizabeth¹, Karlina Samadi, drg., MS, SpKG(K)²

¹Resident of Conservative Dentistry

²Staff of Conservative Dentistry

Faculty of Dental Medicine, Universitas Airlangga
Surabaya, Indonesia

ABSTRACT

Background :Nowadays, there are variety treatment options for discoloration in post endodontic treatment tooth, from invasive methods to least invasive and asthetic procedure like bleaching. Bleaching of nonvital discolored teeth is a low risk routine treatment for improving esthetic. Discoloration of nonvital tooth can caused by trauma or endodontic procedure. Walking bleach technique is one of bleaching technique for nonvital tooth. The walking bleach technique is a relatively reliable, fairly simple technique for dentists and patients. Material that used for this technique is 35% hydrogen peroxide gel. In walking bleach technique, the root filling should be completed first and the bleaching agent should be changed every 3-7 days until desired result was obtained. In this case report, the tooth color was accomplished in third visit. **Conclusion**, walking bleach technique as treatment of tooth discoloration can provide a good result with good endodontic treatment.

Key words: tooth discoloration, non vital tooth, walking bleach, hydrogen peroxide

INTRODUCTION

Tooth discoloration varies in etiology, appearance, location, and severity. It could be classified as intrinsic, extrinsic, or both according to its location and etiology. Extrinsic discoloration is caused by chromogens derived from habitual intake of dietary sources such as wine, coffee, tea, carrots, oranges, chocolate, tobacco, mouth rinses, or plaque on the tooth surface, while intrinsic discoloration typically results from systemic or local causes. Systemic causes include drug-related

(tetracycline), metabolic, fluorosis, and genetic (hyperbilirubinemia, amelogenesis imperfecta, and dentinogenesis imperfecta).¹ Local causes include pulp necrosis, intrapulpal hemorrhage, pulp tissue remnants after endodontic therapy, endodontic materials, coronal filling materials, root resorption, and aging.² Over the years, many bleaching agents have been used with varying results. Among them are oxalic acid, calcium hypochlorite, hydrogen peroxide, carbamide peroxide, and sodium perborate.³ The most commonly used

agents for bleaching endodontically treated teeth are 30%–35% hydrogen peroxide and sodium perborate either in combination or separately.⁴ Two basic techniques have been used to bleach discolored nonvital teeth: thermocatalytic and walking bleach.

The walking bleach technique that was introduced in 1961 involved placement of a mixture of sodium perborate and water into the pulp chamber, which was sealed into place between dental visits. This method was later modified by 30-35% hydrogen peroxide to improve the whitening effect. A sealed root-canal filling is an important requirement for allowing an endodontically treated tooth to be bleached. The tooth must be symptom-free, but a waiting period is called for in the case of a radiologically detectable periapical radiolucency. Such lesions should be observed to determine whether the alteration is increasing or if a healing process is apparent. In every case, the root-canal filling material should be sealed with a base material, in order to prevent penetration of the bleaching agent into the periodontal space or root canal. In the walking bleach technique, a thick paste of sodium perborate mixed with water or hydrogen peroxide is placed in the pulp chamber and sealed for periods of 3 to 7 days. When the bleaching agent is applied inside the pulp chamber and sealed, the bleaching occurs between dental appointments via the walking bleach technique.⁵

After the desired bleaching result has been obtained or slightly surpassed,

sometimes an application of calcium hydroxide is recommended in order to diminish oxygen inhibition of the polymerization of the definitive composite filling, and to counteract the increased permeability of the dentin caused by the bleaching agent.⁶

This technique traditionally has been used to treat discoloured non-vital teeth. According to Howell, walking bleach technique have an immediate success rate of 89.5%. However, there is a possibility of recurring discoloration, which means that the initial results cannot be considered permanent.⁵

CASE REPORT

A 20 year old female patient reported to the Department of Conservative dentistry and Endodontics RSGM-P Airlangga University with discolored of her upper left central incisor for an improvement in esthetic appearance.

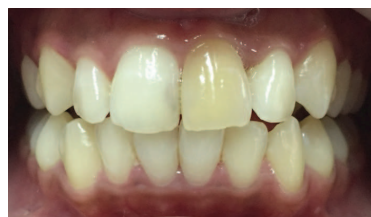

Figure 1. Clinical appearance of discolored tooth 21

The patient presented a history of trauma 4 years ago and had undergone root canal treatment approximately 3 months ago. Radiographs were taken to verify the adequacy of root canal treatment.

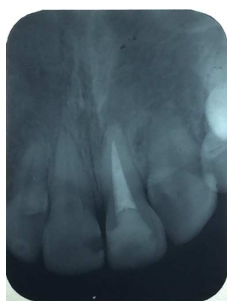

Figure 2. Initial radiographic photo of tooth 21, post endodontic treatment

The shade guide of the discolored tooth was assessed under normal daylight with a Vita Classic shade guide. Pre- and post-bleaching photographs were taken.

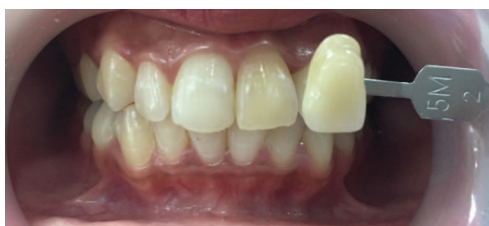

Figure 3. Shade guide before internal bleaching

Using rubber dam, the tooth to be bleached was isolated.

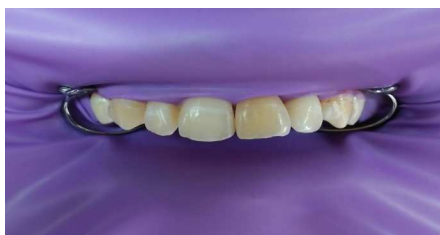

Figure 4. Rubber dam isolation

Before applying the bleaching agent, 1–2 mm of the gutta-percha was removed in an apical direction beyond the cemento-enamel junction.

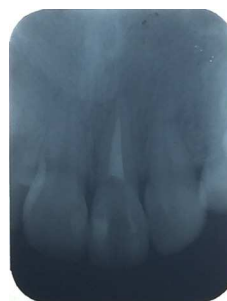

Figure 5. 1-2 mm of gutta-percha was removed in an apical direction

A base of 1–2 mm glass ionomer cement was placed over the root filling material to assure a mechanical barrier between the sealed root canal and the bleaching agent 35% hydrogen peroxide gel (Opalescence Endo) was applied into pulp chamber and sealed with glass ionomer cement. Procedure was repeated two times every 7 days until desired results were obtained.

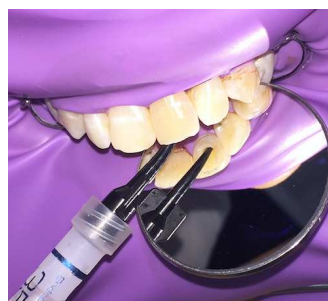

Figure 7. Application 35% hydrogen peroxide into pulp chamber

After the procedure, the gel was completely removed then the pulp chamber was rinsed, dried obturated with calcium hydroxide and closed with a cotton pellet and provisional cement for one week before the final or permanent filling material with light cure composite resin. This was necessary to allow for elimination

of residual oxygen, which interferes with polymerization of the filling material and to neutralize and render the medium alkaline that reduces the risk of cervical resorption.⁶

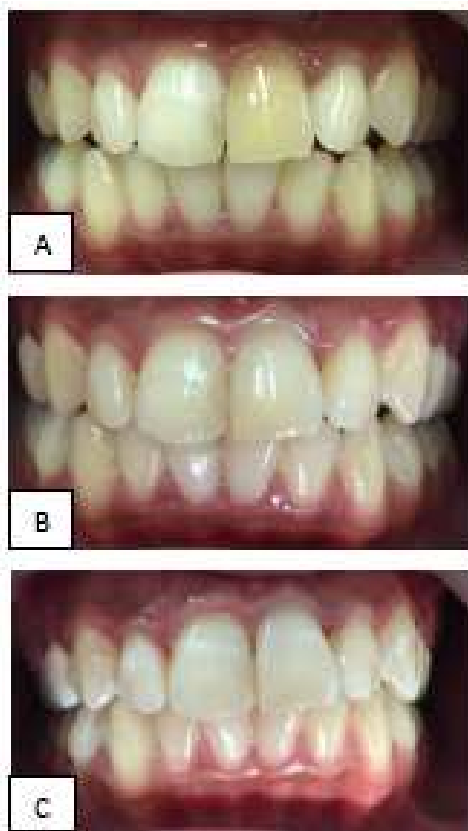


Figure 8. Tooth at first visit (A), second visit (B), and third visit of internal bleaching

DISCUSSION

Discolorations can be of extrinsic or intrinsic origin. An intrinsic discoloration is defined as one with its origin within the pulp chamber. This includes hemorrhage, necrosis, calcification, and iatrogenic discoloration due to dental treatment. Hemorrhage of the pulp is the most common cause of discoloration after

trauma. Blood enters the dentinal tubules and then decomposes. This leads to a deposit of chromogenic blood degradation products, such as hemosiderin, hemine, hematin, and hematoidin.⁷ Discolorations arise due to the formation of chemically stable, chromogenic products. Pigments consist of long-chain organic molecules. In bleaching, these compounds are oxidized: they are split into smaller molecules which are usually lighter. During bleaching, the long-chain organic molecules are transformed into carbon and water, and together with nascent oxygen are released.⁸

Hydrogen peroxide bleaching generally proceeds via the perhydroxyl anion (HO_2^-). Hydrogen peroxide is an oxidizing agent that, as it diffuses into the tooth, dissociates to produce unstable free radicals which are hydroxyl radicals (HO^\bullet), perhydroxyl radicals (HOO^\bullet), perhydroxyl anions (HOO^-), and superoxide anions ($\text{OO}^{\bullet-}$), which will attack organic pigmented molecules in the spaces between the inorganic salts in tooth enamel by attacking double bonds of chromophore molecules within tooth tissues. The change in double-bond conjugation results in smaller, less heavily pigmented constituents, and there will be a shift in the absorption spectrum of chromophore molecules; thus, bleaching of tooth tissues occurs.^{1,9,10}

CONCLUSION

This case report demonstrates the successful management of a discolored post endodontic treatment tooth using

35% hydrogen peroxide gel (Opalescence Endo) as bleaching material, effectively and safely.

REFERENCES

1. Dahl JE, Pallesen U. Tooth bleaching-a critical review of the biological aspects. *Crit Rev Oral Biol Med* 2003;14:292-304.
2. Watts A, Addy M. Tooth discoloration and staining: a review of the literature. *Br Dent J* 2001;190:309–16.
3. Rostein I. Tooth discoloration and bleaching. In: Ingle JI, Bakland LK, editors. *Endodontics*. 5th ed. Hamilton, Ontario, Canada: BC Decker Inc, 2002:845-60.
4. Attin T, Paque F, Ajam F, Lennon AM. Review of the current status of tooth whitening with the walking bleach technique. *Int Endod J* 2003;36:313–29.
5. Archana KS, Ajay KS. Walking bleach: a case report. *IJO CR Oct-Des* 2013. Volume I Issue 2. pp 55-58.
6. De Oliveira L D, Carvalho C A, Hilgert E, Bondioli I R, De Araújo M A, Valera M C: Sealing evaluation of the cervical base in intracoronal bleaching. *Dent Traumatol* 19: 309–313 (2003)
7. Demarco F F, Freitas J M, Silva M P, Justino L M: Microleakage in endodontically treated teeth: influence of calcium hydroxide dressing following bleaching. *Int Endod J* 34: 495–500 (2001)
8. Zimmerli B, Jeger F, Lussi A. Bleaching of Nonvital Teeth : A Clinically Relevant Literature Review. *Schweiz Monatsschr Zahnmed* Vol. 120 4/2010:306-313
9. Joiner, A. The bleaching of teeth: a review of the literature. *J. Dent.*, 34 (2006), pp. 412-419
10. Minoux M and Serfaty R. Vital tooth bleaching: biologic adverse effects—a review. *Quintessence Int.*, 39 (2008), pp. 645-659

THE USE OF PREFABRICATED FIBER POST COMBINED WITH POLYETHYLENE RIBBON AS CUSTOMIZED POST IN WIDE ROOT CANAL FOLLOWING ENDODONTIC RETREATMENT

A CASE REPORT

Marsintha L.M.T*, Dennis, Trimurni Abidin****

*Resident of Specialist Program of Conservative Dentistry

** Lecturer of Department of Conservative Dentistry

University of Sumatera Utara

Jl. Alumni No. 2 Kampus USU Medan 20155

ABSTRACT

The use of post in the case of tooth with wide canal should consider the adaptation and the retention factors in order to evenly distribute the load received. When endodontic retreatment leaves a wide canal, meanwhile the largest size of prefabricated fiber post does not fit properly into the available space. The resin cement layer will be too thick, as a consequence, polymerization shrinkage can arise and affected adaption and retention. Combining prefabricated fiber post with polyethylene fiber-reinforced ribbon creates an anatomic and custom post, will ensure good adaptation and improving retention. A 20 year old female patient came to Dental clinic at Department of Conservative Dentistry, University of Sumatera Utara with chief complaint that the crown of maxillary left central incisor came off 2 years ago which disturbs the patient's esthetic. This case report aims to describe the use of prefabricated fiber post combined with polyethylene fiber-reinforced ribbon in endodontic retreatment with wide canal.

Keywords : Endodontic retreatment, polyethylene fiber-reinforced ribbon, prefabricated fiber post.

INTRODUCTION

In permanent dentition, the most common types of trauma occur in the maxillary incisor region and could cause crown fractures. Also endodontically treated teeth, caries lesions and large and fragile restorations could be predisposing factors for coronal fractures. Restorations of endodontically treated teeth are often achieved by using a post and core. Teeth that have been endodontically treated often

have little coronal tooth tissue remaining and, as such, require a post to retain the core and restoration, and need to be restored by crowns.¹

The use of post in the case of tooth with wide canal on teeth should consider the adaptation and retention factors in order to evenly distribute the load received. When endodontic retreatment leaves a wide canal, it will cause the largest size of prefabricated fiber post does not fit

properly into the available space. The resin cement layer will be too thick, as a consequence, polymerization shrinkage can arise and affect its adaptation and retention. Combining prefabricated fiber post with polyethylene fiber-reinforced ribbon creates a custom post, ensuring good adaptation and improving retention.² This case report aims to describe the use of prefabricated fiber post combined with polyethylene fiber-reinforced ribbon in endodontically treated tooth with wide canal.

CASE REPORT

A 20 year old female patient came to RSGM FKG USU with chief complaint that the crown of left maxillary central incisor came off 2 years ago which disturbs the patient's esthetic. Previously these teeth have been done root canal treatment and wearing a crown. After clinical and radiographic examinations, it was diagnosed a non vital teeth post endodontic treatment with complex crown fracture incisor. (Figures 1a-c)

In this clinical case, we used a technique combining a fiber post, a polyethylene fiber and composite resin for esthetic and durable restoration, which could be an alternative to the prosthetic approach.

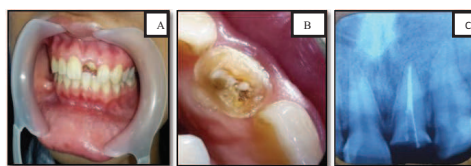


FIGURE 1.(A) Clinical aspect of fractured left maxillary central incisor (B) Occlusal view of the crown fracture (C) Initial radiographic

CASE MANAGEMENT

First visit:

After thoroughly explained about the suggested treatment, the patient accepted and signed the informed consent. Tooth #21 was isolated with rubber dam and then access opening was made into the root canal. There were composite and base cement remainders that covered the orifices. A bur pesso reamer was used to remove the sealer and guttapercha inside the root canal. Re-wallling was done afterward to restore the shape of the tooth while maintaining access cavity by inserting guttapercha. Palatal access was re-opened and the canal was irrigated with NaOCl 2,5%. The canal was negotiated with K-file #20 and the glide path was managed with K-file #40. Working length was initially measured with apex locator (*Raypex 6, VDW*) and then confirmed radiographically with Initial Apical File (IAF) ISO #40 to 22 mm. Cleaning and shaping were done in Single Length technique (*Mtwo Rotary Files*) and canal was irrigated with NaOCl 2,5% after using each file. After drying the root canal, intracanal dressing Ca(OH)_2 (*VioPaste™*—

DiaDent) was placed and the access was covered with GIC. (Figure 2A-E)

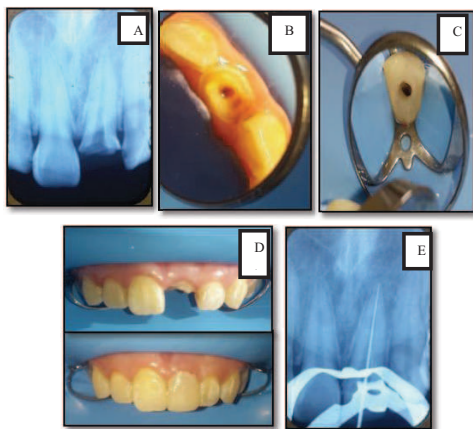


Figure 2A-E. (A) Radiographic retreatment (B) Occlusal view of retreatment (C) Rewalling (D) Access opening (E) Initial Apical File

Second visit:

After two weeks without any complaints, the temporary filling was removed and the canal was irrigated with NaOCL 2,5%, EDTA 17% and Chlorhexidine 2%, and subsequently dried. Master Apical Cone (MAC) was inserted up to the working length and confirmed radiographically. Obturation was done using ISO Guttapercha and AH26 sealer (Dentsply, Switzerland) with lateral condensation technique. Orifice barrier was formed afterwards using Fuji I GIC, followed by temporary filling (*Cavit*) and radiograph was taken for confirmation (Figure 3A-B)

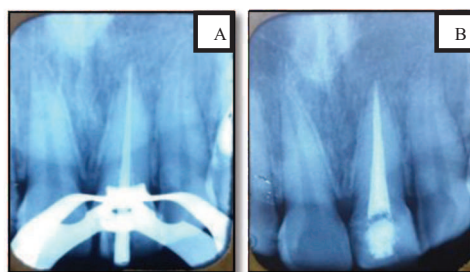


Figure 3A-B. (A) Radiographic MAC (B) Radiographic obturation

Third visit:

A day after obturation, prefabricated fiber post (Parkell Inc, Switzerland) was placed following post length determination and post channel preparation using peeso reamer Largo® ISO#3 (Dentsply, Switzerland).

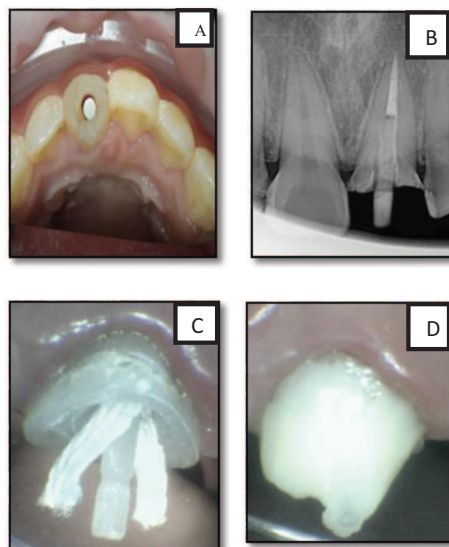


Figure 4A-D. (A) Prefabricated post placement (B) Radiography of prefabricated post placement (C) Prefabricated fiber post and Polyethylene ribbond seated into wide canal (D) custom post and core

A bur pesso reamer was used to remove gutta-percha for creating a post space (Figure 4A) which is radiographically confirmed (Figure 4B). There was no prefabricated post could fit properly in the canal because it was too wide, and the decision was made to use a custom post. Single layer of silane coupling agent was applied to the prefabricated post surfaces and gently air dried after 60's as a surface treatment. Then, polyethylene ribbon (*Ribbon®*, Scottle, WA, USA) was conditioned by wetting unfilled resin. The combination of fiber prefabricated post (*Parkell Inc*, Switzerland) with polyethylene fiber-reinforced ribbon was inserted concomitantly into the canal (Figure 4C) creating a custom post and core (Figure 4D) with self-adhesive resin luting cement (*RelyXTM U200*, 3M ESPE). Exposed ribbon was then filled and covered with composite resin (*3M ESPE Filtek Z350 XT*) incrementally for fabricating core, and light cured for 40 sec from one surface, which is radiographically confirmed (Figure 5).

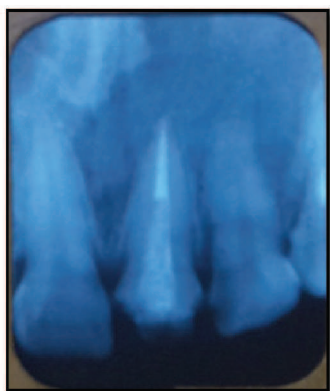

Figure 5. Radiography of custom post and core

The core preparation was completed with circumferential deep chamfer finish line. Fissure diamond bur were used for tooth preparations. The width of the shoulder was kept 1 ~ 1.2 mm. Cervical margin was placed 0.5 mm sub-gingivally to increase the length of preparation as well as aesthetic improvement of the final restoration. Sharp edges or irregularities were corrected to minimize stress concentration. (Figure 6A-B). Complete arch impression was made with a silicon impression material and chair side provisional crown (*Revotek LC*, GC), and cementation with (*Freegenol Temporary Pack*, GC) (Figure 6C).

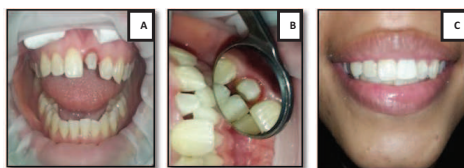


Figure 6A-B. Final preparation for full ceramic restoration, 6C. Provisionary crown

Full ceramic crown was fabricated. The complete seating, marginal adaptation, aesthetic appearance of crown and occlusion was checked at the first try-in. Any premature contacts of centric occlusion position and /or the lateral and anterior movements were eliminated.

The internal surface of the crown was etched with 5% hydrofluoric acid gel (*IPS ceramic etching gel*; Ivoclar, Vivadent) for 20 sec. A silane coupling agent (*Monobond-S*; Ivoclar, Vivadent) was applied for 60 sec. The preparation was

cleaned with *pumice slurry* and *retraction cord* was applied. The core surfaces and remaining tooth surfaces were etched with 37%phosphoric acid for 60 seconds. Tooth was rinsed with water and dried. Syntac Primer and Syntac Adhesive were applied. The bonding agent was brushed on both preparation surfaces and internal surface of the restoration, thinned with air, and cementation was performed immediately by using *Variolink II* high viscosity resin cement. Excess cement was removed and the restoration was photo-polymerized for 40 sec. from all surfaces. The occlusion was controlled to preclude premature contacts (Fig. 8).

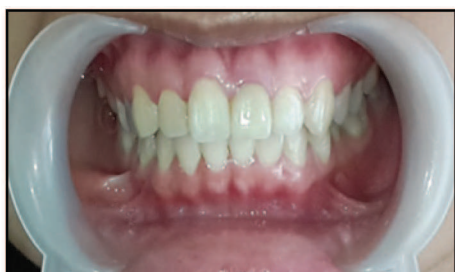

Figure 7. Full ceramic crown

DISCUSSION

The goal of endodontics and restorative dentistry is to maintain natural teeth with maximum function and good aesthetics. It is generally evident that successful treatment of damaged tooth with pulp disease depends not only on good endodontic treatment but also on good final restoration reconstruction after endodontic treatment is complete.³

Failure of root canal treatment is influenced by various factors. The quality of coronal restorations has a significantly greater effect on periapical health than on the quality of obturation. Research Hommez et al (2002) suggests that failure to adequately position coronal restorations may lead to root canal failure while Gautam et al. (2012) suggests that inadequate obturation is a major cause of root canal failure due to micro leakage via fillers contaminated by bacteria.^{4,5}

Post customized polyethylene fiber is one type of post that is restored by the operator itself. The use of Fiber Reinforced Composite polyethylene tape as post customized requires cement luting resin and composite resin. The modern adhesive system strongly supports to protect and strengthen the tooth structure left behind because adhesive restoration creates minimal preparation so as to maintain healthy tooth structure. For this reason the use of polyethylene fiber is growing to increase resistance to resin and composite bonding.⁶

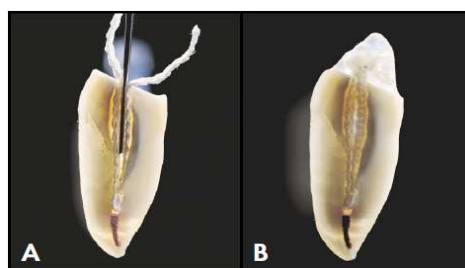


Figure 8. The post system is customized using reinforced resin fiber ribbons
A. Composite resins and polyethylene fibers condensed into the root canal; B. Restoration after build-up⁸

The use of Ultra High Molecular Weight Polyethylene (UHMWP) is increasingly popular. UHMWP can be used for build-up pegs and the endodontic core can even adapt to root canal walls without the need for additional root canal expansion after endodontic treatment.⁷ The woven fiber has a similar elastic modulus to dentin and creates a dentin-post-core monoblock system that can distribute the pressure along the roots well.⁸ Starting from the stake material, sealer, adhesive system, cement luting and restoration of cores and crowns have the same resin-based properties. The elastic modulus of all components approaches the modulus of dentine elasticity so that the pressure is well distributed. Fiber polyethylene has many clinical uses such as periodontal splints, bridges for anterior teeth, orthodontic retainers, and can also be used as preparation for porcelain crown restoration in both the anterior and posterior teeth.^{6,7,8}

Polyethylene fiber was introduced in the market in 1992. This material is a bonding fiber and has the strengthening properties of the remaining dentin structure comprising glass fibers or polyethylene fibers.^{7,9} Tooth fracture is one of the causes of post and core restoration failures. Core stability and post retention are essential in preventing the failure of endodontic treated restorations. The ideal post system should replace the loss of tooth structure and provide adequate retention and support of the core so as to properly distribute the occlusal pressure while performing

functional and parafunctional activities to prevent fractures at the root. The post-polyethylene fiber reinforced system uses internal anatomy, surface area and root canal irregularities to enhance the bonding with dentine, to improve the integrity of remaining radical structures of dentin and increase retention and movement resistance.⁸

Fractured tooth is one of the cause of failure in fiber post and core restoration. Core stabilization and fiber post retention is very important in prevention the failure of tooth restoration with an endodontic treatment. An ideal fiber post should be able to replace a tooth structure and providing adequate retention supporting its core in distributing a good occlusal force during functional and parafunctional activity to avoid root fracture. *Polyethylene fiber reinforce* fiber post system uses internal anatomy, surface area and irregular shape of root for increasing its attachment with dentin, to correct the integrity of radicular dentin structure left and increasing its retention and resistance towards the movement.⁷ In this case, the patient's chief complaint was its maxillary left central incisor crown came off, which disturb the patient's esthetic. Endodontic retreatment was done and 1/3 of the coronal wide root canal, it was planned to do a combination of prefabricated post and polyethylene ribbon.

If the post does not fit well, especially at the coronal level, the resin cement layer is excessively thick and the bubbles are

likely to form, thus predisposing adhesive failure and debonding. The solution to overcome this problem is to create custom post that closely match the diameter of the canal and it will be surrounded by a thin and uniform film cement, which represents ideal condition for retention. Several technique was introduced to create a custom post or anatomic post. In this case, combining prefabricated fiber post with ribbon is relatively easy and it is possible to achieve better fitting quality . Ferreira et al (2014) describe an anatomic post by reshaping fiber post to fit the root canal using composite resin.¹⁰Boksman et al (2011) describe using prefabricated post combined with polyethylene ribbon in the case where the coronal circumference has a wide flare 25% greater than the size of fiber post available in order to reduce the thickness of cement and increase fracture resistance. In this case, a self-adhesive resin cement was used without having to pre-condition the tooth structure before luting procedure.²

Dental cement lute the post to radicular dentin and some properties of cements, such as compressive strength, tensile strength and adhesion, are commonly described as predictors for success of a cemented post. Cement provides important retention to the post and core; however, no cement can compensate for a poorly designed post.¹⁰In this case report, before the cementation procedure, the canal was washed off and dried after the etching procedure, ensuring that the post space was free of any residue.

The root canal was filled with resin cement by using lentulospiral and polyethylene fiber ribbon embedded to the resin cement was placed to the prepared root canal.

In this case, crown lengthening cannot be done on the patient for the improvement of the cervical line due to shortage of time. Risk of root perforation can be eliminated and the remaining root dentin to resist fracture is optimized. However, a significant challenge with this technique is the handling of the polyethylene ribbon during embedment of the resin cement.

CONCLUSION

The use of fiber-reinforced post combined with polyethylene fiber-reinforced ribbon might be an option in wide canals as it improves the adaptation and retention.

REFERENCES

1. Barutçigila C, Harorlia OT, Yildiz M,. Restoration of crown fractures with a fiber post, polyethylene fiber and composite resin : a combined restorative technique with two casereports. *Rev ClínPesqOdontoljan/abr2009;5(1):73-77*
2. Boksman L, Hepburn AB, Kogan E, Friedman M, deRijk W. Fiber post techniques for anatomical root variations. 2011. *Dent Today May 30(5): 104 106-11*
3. Gogna R, Jagadish S, Shashikala K, Keshava BS., Restoration of badly broken, endodontically treated

- posterior teeth. *J Conserv Dent* 2009; 12(3): 123-128.
4. Gautam, S, Thapa, A, Rajkumar, B. Reason for failure of non surgical root canal treatment in Nepali population. *Nepal Med Coll J* 2012; 14(2): 142-145.
 5. Hommez, G,M, Coppens, C,R, De Moor, R,J. Periapical health related to the quality of coronal restorations and root fillings. *International Endodontic Journal* 2002; 35: 680-689.
 6. Ayna B, Celenk S, Atakul F, Uysal E,. Three-year clinical evaluation of endodontically treated anterior teeth restored with polyethylene fibre reinforced composit. *Aust Dent J* 2009;54:136-40
 7. Gluskin Ah, Ahmad I, Harrera DB,. The aesthetic post and core;unifying radicular form and structure. *PractProcedAesrheth Dent*;2002:14(4):313-21
 8. Terry DA,.Design principles for the direct fiber-reinforced composite resin post and core system. *Contemporary Esthetic and Restorative Practice*.2003:22-31.
 9. Ferreira MG, Camapum MCN, Ferreira GC,Perillo MV, Cardoso PC, Silva JA. Restorative perspective for endodontically treated teeth: *Anatomic Post.Dental Press Endod*; 2014:Jan-Apr 4(1):34-45
 10. H.N. Alkumru *et al*.,Use of Polyethylene Fibre Ribbon Reinforced Composite Resin as Post-Core Build-Up: A Technical Report, *Balk J Stom*, 2008; 12:174-177

RESTORATION OF ENDODONTICALLY TREATED TEETH WITH SEVERE LOSS OF TOOTH STRUCTURE – CASE REPORT

Mike Wijaya* Dennis**Trimurni Abidin **

* *Resident of Specialist Program of Conservative Dentistry*

***Lecturer of Specialist of Conservative Dentistry*

Faculty of Dentistry, University of Sumatra Utara

Jln. Alumni No.2 Kampus USU Medan 20155

ABSTRACT

It is generally agreed that the successful treatment of a badly broken tooth with pulpal disease depends not only on good endodontic therapy, but also on good prosthetic reconstruction of the tooth after endodontic therapy. Often, we come across endodontically treated teeth with little or no clinical crown in clinical cases. In such cases, additional retention and support of the restoration are difficult to achieve. Case reports of patients with loss of dental structural tissue and patients still want to retain their teeth due to aesthetic factors. Case reports are discussed here where structurally compromised, endodontically treated. A 45 years old female patient came to the clinic of RSGM FKG USU with chief complaint on tooth #14 and #15 which was painful since 1 month ago. The patient took analgesic to relieve the pain. Tooth #14 clinical examination loss of tooth structure palatal cup and pulp exposure. Vitality test using Electric Pulp Tester (EPT) showed response positive. Tooth #15 was endodontically treated 6 years ago. Clinical examination failure restoration. Radiological examination under filling of root canal obturation. The purpose of this article of a post is to retain a core in a tooth that has lost its coronal structure extensively.

Keywords: Post Fiber, Retreatment, Underfilling, Restoration.

Introduction.

The goal of endodontics and restorative dentistry is to retain the natural teeth with maximal function and pleasing aesthetics. It is generally agreed that the successful treatment of a badly broken tooth with pulpal disease depends not only on good endodontic therapy, but also on good prosthetic reconstruction of the tooth after the endodontic therapy is complete.¹ Resistance loss and fracture risk. It is well established that teeth undergoing endodontic treatment have smaller

resistance and higher fracture risk. These tooth fractures are relatively frequent in daily clinical practice.²

To plan and perform the restorative treatment of endodontically treated teeth, properly, it is important that the dentist know these alterations and their effects, predicting possible interurrences and planning the most correct approach for each case treatment.² Frequently, teeth not only require prosthetic rehabilitation by means of a full coverage prosthesis, they often also need restoration of teeth

by retention acquired from within the root canal space, particularly when large amounts of dental tissue have been lost because of destructive caries, superadded by endodontic treatment. Because badly mutilated teeth or the grossly decayed teeth pose problems to the restorative dentist during their treatment due to unavailability of sufficient clinical crowns, hence a crown lengthening procedure prior to restorative treatment is necessary during management of such teeth.³

This case report aims to describe the successful endodontic treatment with loss of dental structural tissue and structurally compromised, and patients still want to retain their teeth due to aesthetic factors. A post is to retain a core in a tooth that has lost its coronal structure extensively and crown lengthening need to restoration.

Case

A 45-year-old female patient presented to RSGM FKG USU tooth #15 which has been painful since 1 month ago. The tooth was endodontically treated 6 years ago. Clinically examination showed open obturation cause failure restoration. Radiological examination under filling of root canal obturation. The tooth diagnosed was non vital pasca endodontic treatment. Treatment planning for this situation was retreatment endodontic. Final restoration was complicated by fiber post + build upresin composite.

Tooth #14 with a pain for past few weeks. Clinical examination loss of tooth

structure cups palatal and pulp exposure. Vitality test using Electric Pulp Tester (EPT) was positive. A diagnosed was of Asymptomatic irreversible pulpitis and there was no sign of periapical lesion. Treatment planning for this situation was crown lengthening in palatal for the need restoration. Final restoration was complicated by fiber post+ build up resin composite.(figure 1a dan 1b).

The patient was given some informations on the procedure to be performed and she signed the informed consent.

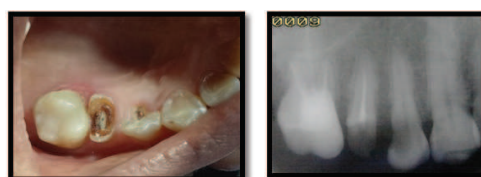

Figure 1. Pre-Operative Pre-Operative Radiography

Case Management

First visit opening access to the root canal orifice used endoaccess diamond bur. Retreatment was performed on tooth 15 with rotary NiTi files and root canal filling preparation was done to remove obturation root canal filling, 0.1 ml of chloroform was applied to the root canal to soften gutta-percha for 30 seconds then Drice retreatment files (IRace, FKG) were used to obturation material. Treatment phase was rewalling followed by measuring the working length with apex locator and radiography was taken. Tooth #15 with K-file No. 20 Initial apical File bukal and palatal 20 #17ml. Tooth #14 with K-file

No. 20 Initial apical File 20 #20ml. Before Akses kavitas isolation with rubber dam (Figure 2a, 2b.)

Tooth #14 Before rewalling is done crown lengthening on the palatal part to get clear teeth limit. Bleeding stopped using hemostat. After that done the installation of circumferential matrix and made the wall using composite to reshape the missing wall. A crown-lengthening procedure was carried out using the tissue recontouring system to expose 2 mm of the tooth structure and to have the crown ferrule effect for better retention.¹

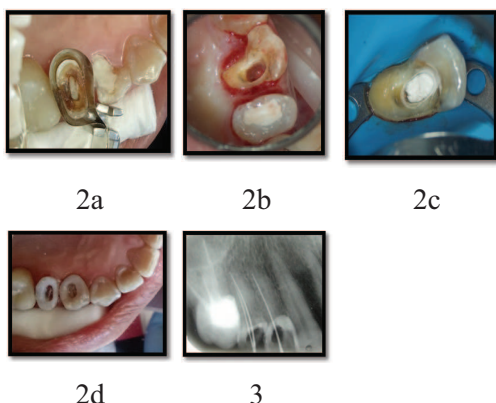


Figure 2a, 2b, 2c, 2d Rewalling & crown lengthening tooth 14

Figure 3. Access cavity and working length confirmation

The root canal was chemomechanically prepared with a rotary NiTi instrument (IRace, FKG). Cleaning and Shaping were completed using rotary IRace instruments with crown-down technique R1 (15/.06), R2 (25/.04), R3 (30/.04). Irrigated with copious 2.5% sodium hypochlorite, and 17% EDTA were used as

irrigants alternatively. Final irrigation was 2% Chlorhexidine.

The master cone was selected and the root canals dried with absorbing paper points. MAC tooth #14 30/.04 #20ml. And MAC tooth #15 Bucal and palatal 30/.04 #17ml. (Figure 3a). Root canals were obturated then obturated with a resin-based sealer (AH Plus, Dentsply) and using single cone and lateral condensation technique. RM GIC was used to seal coronal portion and temporized restoration with GIC. A periapical radiograph was taken immediately after the obturation. (Figure 3b)

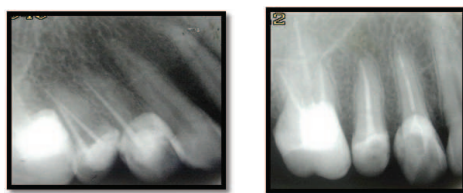


Fig. 3a Fitting of master cone Fig. 3b. Obturation of the root canal,.

On the next visit after 1 week for control, clinical examination showed that patient was no complaint, post space preparation was done by removing gutta-percha in the largest root is the root of two thirds the length of work or leave gutta-percha at about 4 mm apical to PEEK reamer (Mani, Japan), cementation of fiber post was performed with self adhesive resin cement Rely X U200 (3M ESPE, Germany). (Figure 4a, 4b). final restoration was complicated by resin composite build up (figure 5). 1 month later the patient was recalled for a follow-up. At the clinical examination the tooth was asymptomatic

and the radiographic examination revealed normal periapical tissue. (figure 5a, 5b)

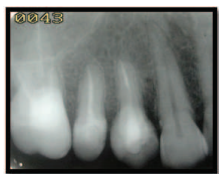
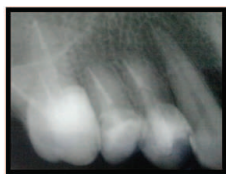
Fig. 4a. Inset post fiber tooth# 14



4b. Inset post fiber tooth # 15

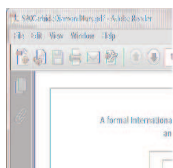
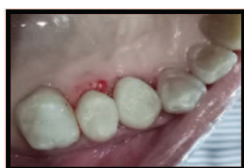
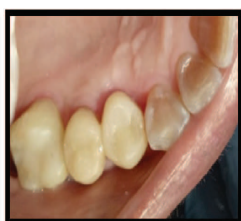
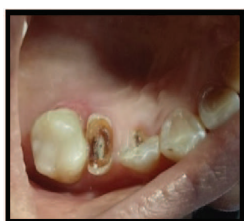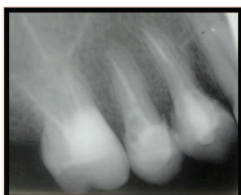
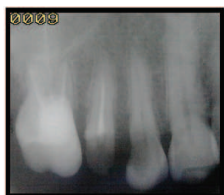Fig. 5a. Matrix Sectional



5b. Final Restoration



Pre operative Post Operative



Pre operative radiografi Post operative radiografi

Discussion

Endodontic treatment is an attempt at preserving a tooth with damaged pulp in function. The treatment success depends on numerous factors such as: variability of endodontic space morphology, available endodontic instruments, therapist's

knowledge and clinical experience, patient's health and patience, time available for the treatment.⁴ Provided that the endodontic treatment was successful, confirmed radiographically and clinically, the task of the dental practitioner is to restore the tooth's function by supplying the crown and bringing it into correct relationship with adjacent teeth and antagonists. Postendodontic restoration today is considered equally important as the instrumentation and obturation of the root canal.⁴

Long term success of endodontic treatment also depends on restoration of the endodontically treated tooth, which is supported by the fact that more problems and/or tooth losses in endodontically treated teeth are caused by inadequate restoration than by failure of the endodontic procedure itself.^{3,6}

In the case of wider tooth decay, the restoration procedure becomes more complicated. The posterior tooth always requires coronal protection, because the pressure on the occlusion is greater, regardless of the loss of hard tissue of the teeth. The preparation of coronal apparatus depends on the proximal surface conditions.⁵

In the case of wider tooth decay, the restoration procedure becomes more complicated. The posterior tooth always requires coronal protection, because the pressure on the occlusion is greater, regardless of the loss of hard tissue of the teeth. Coronal surface preparation depends

on the proximal surface conditions.^{3,5}

In this case report, successful non-surgical treatment depends on adequate shaping and cleaning, obturation and final restoration. Factors affecting the final restoration options are the number of coronal tooth structures remaining, the aesthetic needs of the patient, the periodontal tissue status that supports the teeth. Other factors of restoration prognosis after endodontic treatment are type of occlusion, tooth type, position in the dental arch, type of final restoration, abutment type and proximal contact.^{6,7}

The ultimate restoration of endodontic treatment varies from direct restoration and indirect restorations involving post and core placement. Restoration of endodontically treated teeth requires strength from restorative materials and remaining tooth tissue so as to have resilience to occlusal pressure and have good aesthetics. Adequate restoration should be done as soon as possible after endodontic treatment to prevent salivary and microbial contamination to periradicular areas.^{1,2,7}

This case report presents the final restoration of the first and second cases with composite resin material. Composite resins in addition to their more affordable prices also have advantages such as: low polymerization Shrinkage, low water absorption, high fracture resistance, good bonding to enamel or dentine, dye with teeth, easy manipulation, finishing and polishing easy. Because it has more extensive coronal tooth decay damage,

post and core placement can be performed so as to obtain good retention.⁷

Post prefabricated fibers are one of many types of post and can bind to resin cement and resin-based composite cores resulting in an excellent adhesive bond within the root canal. This technique creates a monoblock system in the root canal that is a term that means a unity. The monoblock system is expected to improve seal quality in the root canal so as to strengthen the roots and help to distribute homogenous mastication and reduce the pressure on the mastication function.^{3,7}

Conclusion

Postendodontic restoration is as important as endodontic treatment itself, as successful endodontic treatment can not be achieved without postendodontic restoration

Reference

1. Gogna, R, Jagadish, S, Shashikala, K, Keshava, B,S. Restoration of badly broken, endodontically treated posterior teeth. J Conserv Dent 2009; 12(3): 123-128.
2. Gonzaga, C, C, Campos, E, A, Filho, F, B. Restoration of endodontically treated teeth. RSBO 2011; 8(3): e33-46.
3. Segovic SS, Galic N, Davanzo A. Post endodontic tooth restoration part I : The aim and the plan of the procedur. Acta stomat Croat : 2004(38): 81-86

4. Daokar, S, Kalekar, A. Endodontic failures- a review. IOSR Journal 2013; 4(5): 5-10
5. Raj, N, Kumar, S, Raju, V, Darshan, V. Need for prosthodontic management of the endodontically treated teeth. URJDS 2015; 02(1): 1-2.
6. J. F. Siqueira. Aetiology of root canal treatment failure: why well-treated teeth can fail. Int endod J 2001; 34 : 1-10.
7. Raj, N, Kumar, S, Raju, V, Darshan, V. Need for prosthodontic management of the endodontically treated teeth. URJDS 2015; 02(1): 1-2.

TREATMENT OF DISCOLORATION ON THE MAXILLARY CENTRAL INCISOR WITH WALKING BLEACH TECHNIQUE

(A CASE REPORT)

Muh. Yusri*, Rahmi Alma Farah **

*Postgraduate Student, Departement of Conservative Dentistry, Faculty of Dentistry,
Universitas Padjadjaran, Bandung, Indonesia

** Departement of Conservative Dentistry, Faculty of Dentistry,
Universitas Padjadjaran, Bandung , Indonesia

ABSTRACT

Introduction: Discoloration of anterior teeth are often causing problems in an overall patient's appearance that lead to a professional dental treatment. Bleaching procedures are more conservative than restorative methods such as crown and veneer. The methods most commonly used to bleach in conjunction with root canal treatment is the walking bleach technique. **Case report:** A 21-year-old female patient came to the clinic with pain and swelling on her upper anterior tooth, and disturbed by its discoloration which due to an accidental trauma when she was 10 years old. Her tooth had been darkened in the past 8 years. Patient was then proceeded with an endodontic treatment and the pain and swelling were gone. For aesthetic consideration, a non-vital tooth bleaching procedure was chosen. After recorded the initial color of tooth, approximately 2mm gutta-percha filling was removed below the cervical and performed cervical seal. H_2O_2 (opalescence endo 35%) bleaching material was applied to in the pulp cavity with the walking bleach technique. Tooth color progression was checked weekly until the desired color achieved. Direct composite restoration was done following bleaching procedure. **Discussion:** Walking bleach was considered for this case as it gave least chair time, more comfort, and relatively safe technique. **Summary:** Tooth discoloration caused by dental trauma may be corrected through an internal bleaching procedure using a walking bleach technique following a root canal treatment

Keywords: Non-vital tooth, trauma, discoloration, walking bleach

Introduction

Discoloration of anterior teeth are a cosmetic problem that are often significant enough to induce patients to seek corrective

measures.¹ Tooth discoloration varies with etiology, appearance, localization, severity and adherence to the tooth structure. It may be classified as extrinsic or intrinsic discoloration or combination of both.²

Tabel 1. Etiology of tooth discoloration.^{2,3}

Intrinsic discoloration	Extrinsic discoloration	
	Pre-eruptive	Post-eruptive
a. Daily acquired stains	a. Disease	- Pulpal changes
- Plaque	- Alkaptonuria	- Trauma
- food and beverages	- Hematological	- Dentin hypercalcification
- tobacco use	disorder	- Dental caries
- Poor oral hygiene	- Disease of enamel and dentin	- Restorative materials and operative procedures
- Swimmer's calculus	- Liver diseases	- Aging
- Gingival hemorrhage	b. Medications	- Functional and parafunctional changes
b. Chemicals	- Tetracyclin stains and other antibiotic use	
- Chlorhexidine	- Fluorosis stain	
- Metallic stains		

Bleaching procedures are more conservative than restorative methods, relatively simple to perform, and less expensive.¹Dental bleaching offers a solution for conservative and aesthetic problem instead of invasive repair options, such as crown or porcelain veneers.⁴. The procedures may be internal bleaching (within the pulp chamber) or external bleaching (on the enamel surface). The Indication for internal bleaching technique are 1. Discoloration of pulp chamber origin, 2.Dentin discoloration, 3. Discoloration that are not amenable to external bleaching. Contraindication are: 1. Superficial enamel discolorations, 2. Defective enamel formation 3. Severe dentin loss 4.Presence of caries, 5. Discolored proximal composites (unless they are replaced after bleaching).¹

Various of techniques and procedures have been introduced for intracoronal bleaching. where is the most commonly used after a root canal treatment is a technique of thermocatalytic and walking bleach. The walking bleach technique is

prefer because it requires the least chair time and is more comfortable and safer for the patient.^{1,5}The successful bleaching of discolored non-vital using walking bleach technique have been evaluated with a good prognosis and no side effects even 6 years after bleaching.⁵

Case Report

A 21-year-old female patient came to the clinic with pain and swelling on her upper anterior tooth, and disturbed by its discoloration which due to an accidental trauma when she was 10 years old. Her tooth had been darkened in the past 8 years. Patient was then proceeded with an endodontic treatment and the pain and swelling were gone.

Extra oral examination showed symmetrical face, lips and temporomandibular joints no abnormalities, as well as lymph glands submandibularis left and right were not palpable and painless. The oral health examination resulted look good. The color of the tooth 21 looked darker than adjacent teeth. The examination of vitality, percussion, palpation, press and mobility showed negative results (Figure 1).

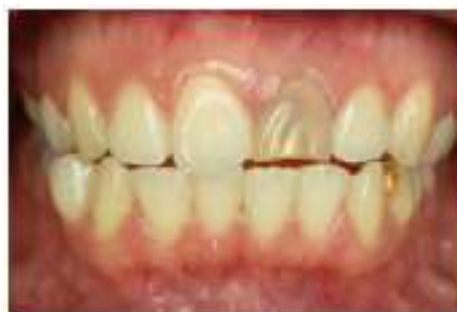

Figure 1.Initial Clinical Image of Tooth 21

Radiological examination result after endodontic treatment showed radiopaque image of the filler material from the crown to the root of the tooth 21 and filler material looked hermetic apical tip. There was a diffuse radiolucent image in the apical region of 2 mm diameters, which showed the healing process occurs in the area of apical tooth 21. Periodontal membrane widened and laminadura was disconnected at the apical tooth 21. Dental alveolar bone crest 21 in normal range (Figure 2b).

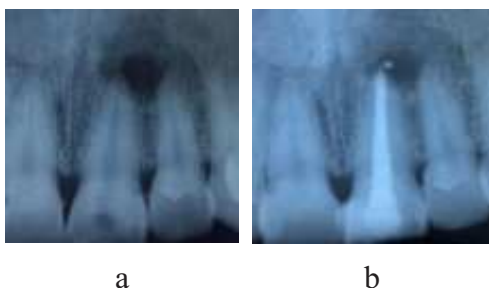


Figure 2. Radiography Image of The Tooth 21: (a). Before Treatment, (b). After Endodontic Treatment

The tooth of 21 was diagnosed Previously treated (AAE 2013) and intrinsic discoloration. The treatment plan will be performed on tooth 21 is internal bleaching treatments with walking bleach technique. Prognosis of the tooth 21 was good, because the patient was cooperative, the age of the patient was relatively young, the root canal was straight from the coronal access, easy coronal access, and good oral hygiene.

Case Management

Visit I

Patient was given an explanation of the treatment plan will be undertaken, the results of which will be achieved, the possibility of failure and complications of the use of bleaching material then the patient signed an informed consent. The entire surface of the tooth was cleaned first using a brush and powdered stones to get the actual color. The color registration was done using the Vitapan Classical shade guide with color early on the tooth 21 was C4 (figure 3). The color of the tooth to be achieved was A1, match the colour of teeth 11 and 22.

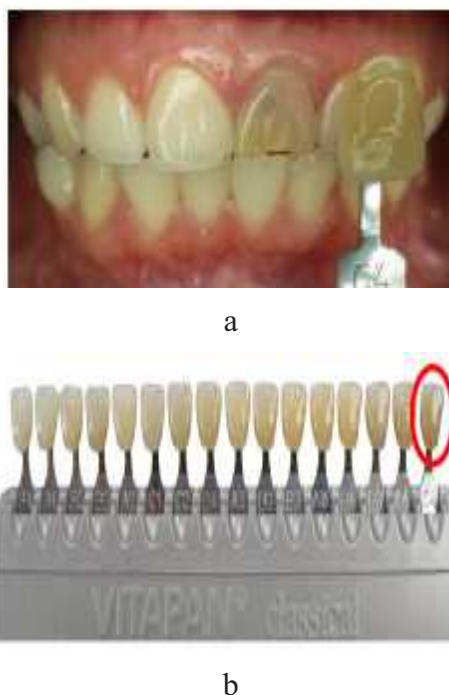


Figure 3. a. The Initial Color Before Treatment, b. Vitapan Classical Shade Guide With Early Tooth Color 21 Was C4

Measurement of clinical crown height was performed using a periodontal probe. In the labial section has a clinical crown height of 9 mm (Figure 4).

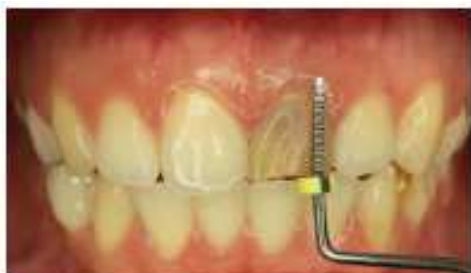

Figure 4. Measurement of Clinical Crown Height Was Performed Using A Periodontal Probe

The setting up of rubber dam was done and the opening of the coronal access on the tooth 21 done from palatal with a round bur until gutta-percha orifice has been looked. The depth of the removal of filler material confirmed again using a periodontal probe. (Figure 5).

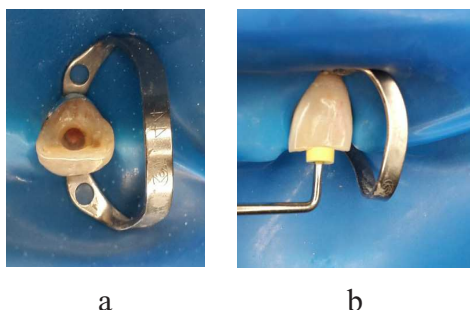


Figure 5. a. Opening of the Coronal Access To Look Under Orifice Gutta-percha, b. Confirmation of Depth Limit Cervical

Root canal filling material was removed until a depth of 2 mm below the cervical tooth with peeso reamer to provide a place for cervical seal material (Fig. 6)



Figure 6. Removal Of The Filler material With A Peeso Reamer

The cavity of the tooth 21 was irrigated with distilled water to clean and dried. Making cervical seal was done by applied Resin Modified Glass Ionomer Cement (Ionoseal, Voco, Germany) as thick as 2 mm above the gutta-percha to cervical line followed the shape of the “bobsled tunnel” from the facial view and shaped “ski slope” of proximal view which base sloped towards the labial.

After the cervical seal hardened, the cavity was cleaned again and certainly no excess cement that covered the wall of the labial. Furthermore applied bleaching material like gel in the form of hydrogen peroxide 35% (Opalescent Endo, Ultradent Products Inc., USA) with cotton pellets on the cavity and covered with temporary filling material (Cavit, 3 m) (Figure 7). The patient was instructed to control one week later.

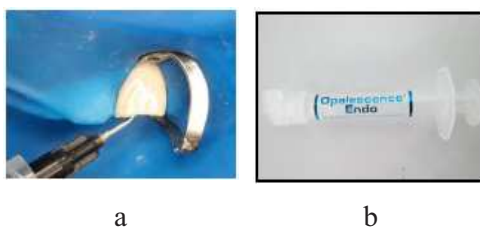

Figure 7. a) Application With Hydrogen Peroxide 35%, b) Bleaching Material Preparation (Opalescence Endo, Ultradent Products Inc., USA)

Visit II

The patient came one week after the first application. On the subjective examination there was no complaint of patient. Color examination of the tooth 21 showed to change brighter into B3 color (Vitapan Classical) (Figure 8). After was isolated, temporary filling was removed, and cavity was cleaned with distilled water and dried. Then bleaching material was applied again and covered with temporary filling. The patient was instructed to control of at least one week later.

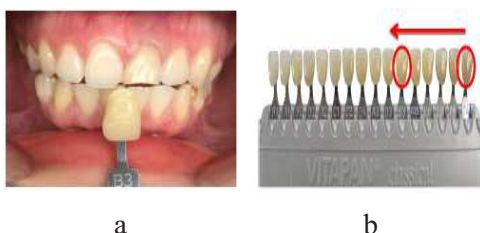

Figure 8. a. The Color of The tooth 21 changed to become B3, b. Change Color on Shade Guide From C4 to B3

Visit III

The patient came one week after the second application. The subjective examination showed no complaint. The

color of the tooth 21 changed brighter into D4 color (Vitapan classical) (Figure 9). After was isolated, temporary filling was removed, and cavity was cleaned with distilled water and dried. Then bleaching material was applied again and covered with temporary filling. The patient was instructed to control of at least one week later.

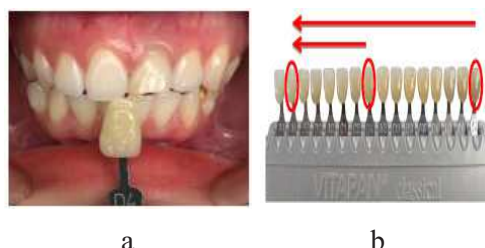


Figure 9. a. The Color of The tooth 21 Change to Become D4, b. Change Color on Shade Guide From B3 to D4

Visite IV

The patient came one week after the second application. The subjective examination showed no complaint. The tooth 21 color changed brighter into A1 color (Vitapan classical), according to the desired color (Figure 10). After was isolated, temporary filling was removed, and cavity was cleaned with distilled water and dried. Then pasta calcium hydroxide (Ultracal, Ultradent, USA) was applied to the inside of the cavity and covered with temporary filling. The patient was instructed to control of at least one week later.

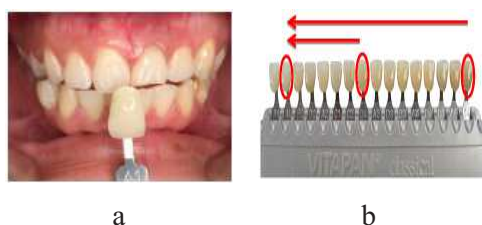


Figure 10 The Color of The tooth 21 Changed to Become A1, b. Change Color on Shade Guide From D4 to A1

Visite V

The patient came to control. Subjective examination showed no patient complaint, and objective examination showed a negative response on percussion, press and palpation test. Patient was satisfied with the results achieved. Temporary fillings on tooth 21 removed, cavity was cleaned with distilled water and dried. Then the final restoration was done with direct composite (Figure 11). The final result showed the color of tooth 21 became the A1 color after treatment was completed.

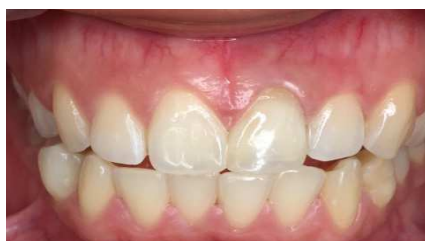

Figure 11. Final Restoration of The Tooth 21

Visite VI

The patient came to control. Subjective examination showed no patient complaint, and objective examination showed the composite restoration color was stable, did

not change or damage, negative response on percussion, palpation and press, and tissue around in the normal range. The patient was instructed after internal bleaching treatment and was showed clinical image of her tooth 21 before and after treatment.

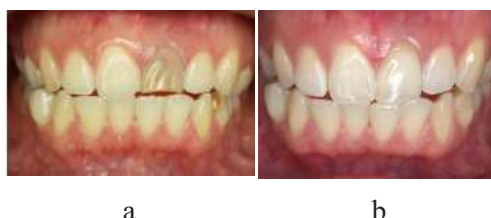

Figure 12. Clinical Image of The Tooth 21a. Before Treatment, b. After Treatment

Discussion

Tooth discoloration can be classified as extrinsic or intrinsic discoloration or combination of both.² In this case, the discoloration of the tooth caused by intrinsic factor which caused by necrosis after trauma a few years ago. Pulpal hemorrhage may occur giving the tooth a grey, non vital appearance. The discoloration is due to the hemorrhage, which causes lysis of red blood cells. Blood disintegration products such as iron sulphides enter the dentine tubules and discolor the surrounding dentine, which caused discoloration of the tooth. Sometimes the tooth can recover from such an episode and the discoloration can reverse naturally without bleaching. These discolored teeth should be vitality tested, because those that was still vital.³

Despite of restorative methods, such as crown and veneers are available, discoloration can often be corrected

totally or partially by bleaching. bleaching procedures are more conservative than restorative methods, relatively simple to perform, and less expensive.¹ Dental bleaching offers a solution for conservative and aesthetic problems instead of invasive repair options, such as crowns or porcelain veneers.⁴

The methods most commonly used to bleach teeth in conjunction with root canal treatment are the thermocatalytic technique and walking bleach technique. These techniques are quite different but procedure similar results. The walking bleach technique is preferred because it requires the least chair time and is more comfortable and safer for the patient.¹ In this case, walking bleach technique was done by applying hydrogen peroxide gel (H₂O₂) (opaescence endo 35%) to the pulp chamber and the cavity was filled temporarily.

Walking bleaching technique was first described by Spasser (1961). Sodium perborate was mixed with water into a paste and then inserted into the access cavity. Later, the technique was modified by mixing sodium perborate with hydrogen peroxide and inserting this into the access cavity (Nutting & Poe 1967). Instead of sodium perborate, carbamide peroxide or hydrogen peroxide can also be used for the walking bleach technique, using the same procedure described above (Vachon et al. 1998).⁶

The bleaching mechanism with hydrogen peroxide occurs through the

oxidation-reduction reaction known as the redox reaction. Hydrogen peroxide is an oxidizing agent that is able to produce free radicals (H₂O + O₂), which are very reactive; in a purely aqueous state, the hydrogen peroxide is slightly acidic. The result is the perhydroxyl (HO₂) that is the most potent free radical. To be able to promote the formation of the ion perhydroxyl, hydrogen peroxide needs to become alkaline; the optimum pH for this to occur is of 9.5 to 10. After forming HO₂ in large amounts then these free radicals will react with unsaturated bonds. This leads to interference in electron conjugation and changes in energy absorption in enamel energy molecule. In addition to changes in molecular weight of dental organic material that reflects the specific light waves that cause discoloration in materials with lower molecular weight and reduced molecules reflecting light. Thereby forming smaller organic molecules with light colors. (figure 1).^{7,8,9}

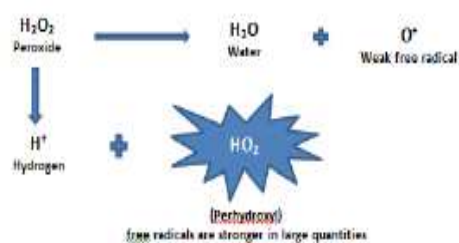


Figure 1. The buffer process results in much more powerful free radicals (Perhydroxyl)⁷

Complications and Adverse Effects to bleaching can be classified:

1. External Root Resorption. Clinical reports and histological studies have

shown that intracoronaleaching may induce external root resorption. The irritating chemical diffuses through the dentinal tubules and reaches the periodontium defects in the cement-enamel junction. To avoid root resorption, the cervical seal should protect the dentin tubules and conform to the external epithelial attachment. Some materials can be used as cervical seal such as: polycarboxylate, Zn-phosphate, glass ionomer, resin modified glass ionomer cement (RMGIC), intermediate restorative material (IRM) or cavity, calcium hydroxide, and MTA.^{1,6,10,11,12,13}

2. Coronal fracture. Slightly increased brittleness of the coronal tooth structure, particularly when heat is applied.¹
3. Chemical Burns. Thirty percent hydrogen peroxide is caustic and causes chemical burns and sloughing of the gingiva.^{1,10}
4. Damage to restorations. The residual peroxide causes inhibition of polymerization of composite resin and increases resin porosity.¹⁴

Suggestions for safer bleaching of endodontically treated teeth are: 1. Isolate the tooth effectively, 2. Protect the oral mucosa, 3. Verify adequate endodontic obturation, 4. Use protective barriers 5. Avoid acid etching, 6. Avoid strong oxidizers, 7. Avoid using heat, and 8. Recall periodically.¹⁰

In this case, after bleaching treatment, Packing calcium hydroxide paste in the

pulp chamber for a few weeks prior to placement of the final restoration, to counteract acidity caused by bleaching agents and to prevent root resorption.^{10,15}

The final restoration in this case was composite restoration, where the resin composite was an adequate material for the reconstruction of weakened teeth due to their inherent characteristic, such as lower degree of polymerization shrinkage, higher hardness, greater resistance to wear and compression. According to Pontius and Hutter, endodontically treated teeth with adequate dentin thickness can be restored only with composite resin.¹⁶

Conclusion

Discoloration that caused by intrinsic factors such as trauma that cause necrosis of the teeth can be treated with internal bleaching, where bleaching is a more conservative procedure, simple, and inexpensive as well as a solution to aesthetic problems.

REFERENCES

1. Rotstein I, Walton RE. Bleaching discolored teeth. Dalam: torabinejad M, Walton R, Fuad AF, editor. Endodontics principles and practice. Edisi ke-5. Lois missauri: Elsevier; 2015. hlm. 428-36.
2. Garg N, Garg A. Textbook of endodontics. 3th ed. New Delhi. Jaypee Brothers Medical Publishers. 2014. p. 492-7.

3. Greenwall L. Bleaching techniques in restorative dentistry. An illustrated guide. 2001.p.5.
4. Izidoro ACS, Martins GC, Higashi C, Grande CZ, Tay LY, Gomes JC et al. Combine technique for bleaching nonvital teeth with 6-Month Clinical Follow-Up: Case Report. *Int J Oral Dent Health*. 2015;1:2
5. Garg N, Garg A. Textbook operative dentistry. . 3th ed. New Delhi. Jaypee Brothers Medical Publishers. 2015. p. 453.
6. Zimmerli B, Jeger F, Lussi A. Bleaching of nonvital teeth. a clinically relevant literature review. 2010;120:306-313.
7. Adang RAF, Suprastiwi A, Usman M. pemutihan gigi teknik homebleaching dengan menggunakan karbamid peroksida. Dep Ilmu Konservasi Gigi Fakultas Kedokteran Gigi Universitas Indonesia.
8. Matos LF, Hernandez LM, Abreu N. Dental bleaching technique; Hydrogen-carbamide peroxide and light sources for activation, an update, mini review article. *The open dentistry journal*. 2014;(8):264-8.
9. Goldstein RE, Garber DA. Complete Dental Bleaching. Chicago. Quintessence Publ. 1995:1-100.
10. Ingle JJ, Heithersay GS, Hartwell GR, Goerig AC, Marshall FJ, Krasny RM, et al. Tooth discoloration and bleaching. Dalam: Rotstein I, Li Y, editor. Endodontics. 5th ed. London: BC Decker; 2002.p.845-854.
11. Neelakantan P, Jagannathan N. Non vital bleaching- A non invasive post endodontic treatment option: A case report. *Journal of Clinical and Dagnostic Research*. 2012;6(3);527-529.
12. Greenwall L. Clinical tooth bleaching: The inside/outside bleaching technique. Restorative and Aesthetic Practice. 2000.
13. Leith R, Moore A, O'Connell AC. An effective bleaching technique for non-vital, discoloured teeth in children and adolescents. *Journal of The Irish Dental Association*. 2009;55(4).
14. Kohli A. Textbook of Endodontics. Elsevier. 2010:336.
15. Sa P. Effect of calcium hydroxide on ph change of external medium after intra coronal bleaching. *J Contemp Dental Practice*. 2011;12(1):158-63.
16. Azevedo RA, Silva-Sousa YTC, Sousa-Gabriel AE, Messias DCF, Alfredo E, Silva RG. Fracture resistance of teeth subjected to internal bleaching and restored with different prosedures. *Braz Dent J*. 2011;22(2).

CASE REPORT

ROOT CANAL TREATMENT OF LOWER RIGHT MOLAR IN CHRONIC TERMINAL RENAL FAILURE.

Muhammad Zaal Haq¹, Anggraini Margono²

¹Post Graduate Student, Department of Conservative Dentistry, Faculty of Dentistry
Universitas Indonesia

²Lecturer, Department of Conservative Dentistry, Faculty of Dentistry,
Universitas Indonesia

ABSTRACT

Endodontic treatment in patients with a medical history of chronic terminal renal failure requires special consideration for endodontic treatment because of the tendency for increased bleeding, susceptibility to infection and interactions with drug use. Male patients, aged 67, came to UI dental conservation clinics with complaints of large right hollow lower right molars, patching and root canal treatment was never completed. Patients have a history of systemic Kidney Failure disease since 2009. Patients are taking Calcium Carbonate, Sodium Bicarbonate, Vitamin B12, folic acid, amlodipine, allopurinol and gliquidone. The dental diagnosis 46 is a chronic apical periodontitis et causa of incomplete root canal treatment. The treatment plan, in this case, is conventional endodontic treatment and dowel crown restoration plan. For prophylaxis, Dexyclav Antibiotics 1x daily for 5 days, Paracetamol when needed, mouthwash 4x daily and multivitamin. After the complaint is absent, root filling is done using F3 gutta protaper with AH Plus sealer and then given GIC LC base.

At the next visit, gutta is taken on the distal root canal along 2/3 root canals, then done fiber post printing. Subsequent visits were subjected to post-test and cementation was then performed by crown preparation. The next visit was to cement the Porcelain fused to Metal crown and control 3 months later. Conclusions: Patients diagnosed with Chronic Terminal Renal Failure have a tendency to bleed due to decreased production of von Willebrand factors, increased nitric oxide and prostacyclin production, platelet dysfunction, anemia and uremic toxins. Root canal treatment should start the day after the haemodialysis schedule, to prevent the spread of toxins. In these patients, radiography after 3 months of treatment showed a good healing.

Keywords : root canal treatment, chronic terminal renal failure, lower right molar.

INTRODUCTION

Chronic Terminal Renal Failure is a condition that indicates a decline in kidney function that lasts long, chronic and generally is not reversible, with progressive

damage of the nephron.^{1,2} The deterioration of bilateral, progressive and chronic nephrons causes uremia and can lead to death.³ The patient's defense depends on active action, either with long-term dialysis

or successful kidney transplantation.^{1,4} During the last decade, there has been a significant improvement in the prognosis of this disease because the development of dialysis and transplantation techniques has provided an opportunity for survivors to face the loss of overall kidney function.

Systemic diseases including chronic renal failure may provide some pathological manifestations in the oral cavity. From a study of chronic renal failure patients, more than 90% had symptoms of uremia in the oral cavity and surrounding areas such as parotitis, stomatitis, gingivitis, xerostomia, and the taste and smell of ammonia. In extraoral, increased incidence of asymptomatic enlargement of salivary glands (parotitis) is thought to be associated with episodic dehydration experienced by patients with chronic renal failure and from uremic toxins, but few data have been found on changes in salivary gland function in these conditions.^{2,3}

Complaints in the oral cavity commonly experienced by patients are dry mouth (xerostomia), halitosis, and metal taste.^{1,4,6,8,10} The taste and smell of metal (uremic foster) is a characteristic of uremic patients and is caused by the high concentration of urea in saliva which will be hydrolyzed to ammonia by urease enzyme produced by *Streptococcus mutans* bacteria.^{3,10,17} This will also cause an increase in salivary pH. While the increase in phosphate concentration in saliva contributes to an increase in salivary buffer capacity.⁸ Oral ulceration may be

due to the same factors as uremic stomatitis or wound healing in patients with chronic renal failure. This oral ulceration tendency is mainly on the inferior surface of the tongue and the floor of the mouth.²⁰ In the oral cavity, there is frequent bleeding of the gingiva, which is thought to be related to changes in platelet quality and quantity and use of anticoagulant drugs (heparin)^{8,20}

Patients with Chronic Terminal Renal Failure, have special needs to consider before starting dental treatment. Treatment in these patients should be related and tailored to the complications that occur.⁹ Patients with hypertension should be treated according to established procedures for hypertensive patients, patients with anemia should be treated according to the requirements established for anemic patients. Before starting treatment, the patient should have a medical evaluation for the last 3 months.

In patients receiving dialysis, the recommendation equals patients with conservative care with the following considerations:

- If there is potential for infection, care techniques should be done carefully by performing a maximum irrigation in the operative area and antibiotics.
- Use of preoperative mouth rinses with 0.12% chlorhexidine and optimal maintenance of oral hygiene.^{3,6,9}

CASE

Male patients, aged 67, came to UI dental conservation clinics with complaints of large right hollow lower right molars, patching and root canal treatment was never completed. Patients have a history of hypertension that induces systemic Kidney Failure disease since 2009. Patients are taking Calcium Carbonate, Sodium Bicarbonate, Vitamin B 12, folic acid, amlodipine 10 mg, allopurinol 100 mg and gliquidone 30 mg.

On an objective examination found discolored 46 teeth with inadequate old restorations, negative pulp sensitivity tests, and percussive sensitivity. Based on the X-ray seen a periapical lesion on the tooth 46.

The diagnosis 46 is a chronic apical periodontitis etcausa of incomplete root canal treatment. The treatment plan, in this case, is conventional endodontic treatment and dowel crown restoration plan.

CASE MANAGEMENT

Once the diagnosis is established, the operator dismantles the old restoration and opens access to the root canal. Afterwards, a root canal line with file # 10 for the mesiolingual root canal and # 15 for the distal root canal with the reference point of the mesiobuccal and distobuccal discs of the tooth 46 was taken taking the radiograph to determine the length of the work.

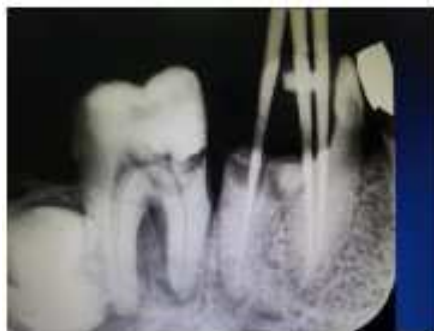

Figure 1.Initial file Radiograph

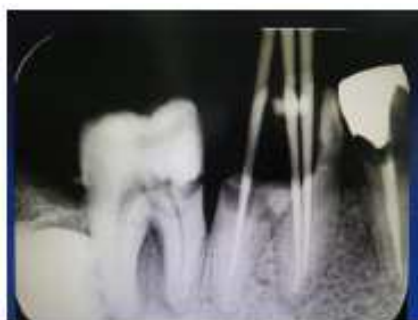

Figure 2.Master Apical Cone Radiograph

Based on X-ray images obtained the length of the work of the root channel of 20 mm mesiobuccal, the Bukit 20 mm root canal and the working length of the 20mm root canal tube. Furthermore, a root canal preparation was made using ProTaper Rotary (DentsplyMaillefer, Switzerland). Obtained Main file # F3 / 17 mm BukioBukal root, # F3 / 19 mm for Distobuccal rootcanal and # F3 / 20 mm for Palatal root canal. Every change of equipment is always interspersed with 2.5% NaOCl irrigation. After preparation is complete, irrigate again with 2.5% NaOCl and aquadest then dried with paper point and given medication Ca (OH) 2 then patched temporarily (GC Caviton).

For prophylaxis, Dextyclav 500 mg Antibiotics 1x daily for 5 days, Paracetamol 500 mg when needed, mouthwash 4x daily Mouthwash enzyme and multivitamin. After the complaint is absent, root filling is done using F3 gutta protaper with AH Plus sealer and then given GIC LC base. Charging is done in accordance with the length of work.

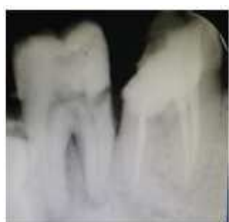

Figure 3.
Obturation
radiograph

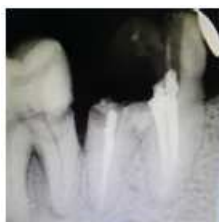
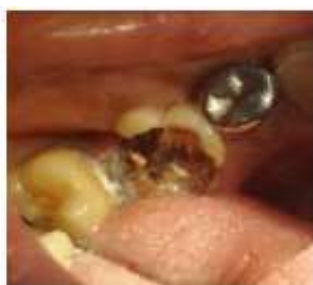
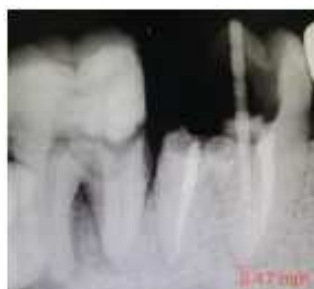Figure 4. Recall
2 weeks after
obturation

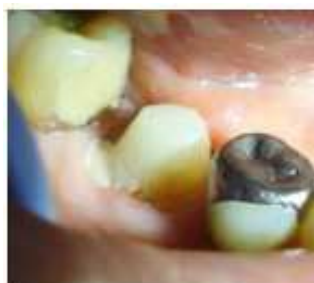At the next visit guttap was taken on the distal root canal along 2/3 root canals, then the root canal dowel preparation was done.



(a)



(b)

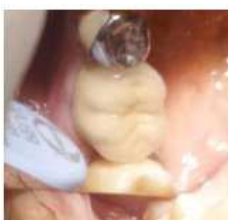

(c)

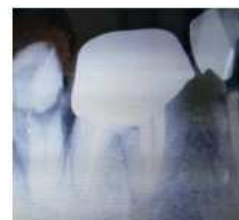Figure. 5 (a). 2 weeks post-treatment, the brittle dental crown condition, and fracture (b). guttap was taken on the distal root canal along 2/3 root canals and (c). Build Up Core

Subsequent visits were subjected to post-test and cementation was then performed by crown preparation but previously gingival electrocautery was performed around the tooth.

The next visit was to cementing the Porcelain fused to Metal crown and recall 3 months later.



(a)



(b)

Figure.6 (a).Insertion crown PF Mand (b). Periapical radiograph

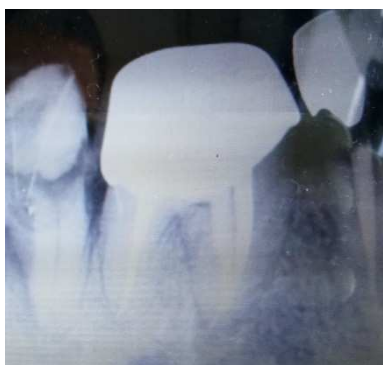

Figure.7 Recall 6 months

Recall 6 months post treatment taken at different angles, the radiolucent image appears to decrease more. But on the apical on the distal side still visible radiolucent residual. Indicates that the lesion is in the healing process.

DISCUSSION

The initial stage of treatment to be performed is an appropriate history and diagnosis. In this case, it was found that the patient had been diagnosed with Chronic Terminal Renal Failure since 2009 and was taking Calcium Carbonate, Sodium Bicarbonate, Vitamin B 12, folic acid, amlodipine 10 mg, allopurinol 100 mg and gliquidone 30 mg. Teeth have been done root treatment but not complete as well as from the pulmonary sensitivity test results obtained negative results. Then reinforced from radiographic photographs, it was found that there was radioopaque in the area of 1/3 tooth corona 46. From the examination, we found a diagnosis of chronic apical periodontitis with the odontogenic source, necrosis of dental pulp 46.

The principle of treatment is to eliminate the infection, the necrotic pulp tissue and the elimination of pathogenic microorganisms to the maximum extent possible by using appropriate irrigation and medication of root canals.^{6,7} Prophylactic antibiotics (Amoxicillin 250 mg) are also given for 5 days to avoid the occurrence of secondary infection.

NaOCl is an irrigation material widely used in endodontic treatment because it has many advantages, among others can dissolve organic tissue and high antibacterial properties. Use of this irrigation solution does not affect its systemic condition if used according to the procedure. The medicaments used are Ca (OH) 2 because it is the gold standard in dentistry and most biocompatible with body tissues compared to other medicaments.

In patients diagnosed with Chronic Terminal Renal Failure, the dentist should be aware of and pay special attention to the administration of drugs, especially those excreted through the kidney or nephrotoxic and should be administered in reduced or avoidable doses altogether. Patients with renal impairment often react abnormally to certain drugs and the usual doses can cause serious toxic effects. Drugs that are often used in dentistry such as tetracycline, aspirin, NSAIDs, acyclovir, meperidine, and acetaminophen should be avoided since the administration of nephrotoxic drugs has the potential for further kidney damage. Although there are already available and known lists of hazardous medicines

for people with Chronic Terminal Renal Failure, it is best to consult a doctor to treat them. In general, a full dose of most drugs may be given if the patient's GFR is greater than 20-30% of normal (GFR > 20-30 cc/min).⁶ Patients with lower GFR and patients with end-stage renal failure usually require dose adjustment.⁶

The main purpose of a treatment is healing, therefore we must know the mechanism. So we can design a treatment approach that maximizes conditions that support wound healing, such as effective disinfection of the root canal system, bleeding control, and medication.⁷

Oral problems that can be found in Chronic Terminal Renal Failure patients such as Xerostomia, due to fluid intake restriction or the effect of antihypertensive drugs, the patient needs to be prescribed a mouthwash that can increase salivary stimulation.

Patients diagnosed with Chronic Terminal Renal Failure have a tendency to bleed due to decreased production of von Willebrand factor, increased nitric oxide and prostacyclin production, platelet dysfunction, anemia and uremic toxins. Root canal treatment should start the day after the haemodialysis schedule, to prevent the spread of toxins.

To control the occurrence of bleeding during root canal treatment can be prescribed Tranexamic Acid 500 mg 2x daily in these patients. The use of local anesthesia such as Lidocaine, is generally

safe in these patients by infiltration, whereas for nerve blocks should be avoided as they tend to cause bleeding.

Healing process begins when inflammation occurs. When irritants in the root canal or in periapical tissue are eliminated by endodontic treatment, inflammatory mediators are no longer produced in periapical tissue due to reduced immunoinflammatory cells. Inflammatory mediators are disabled by the body's mechanisms to prevent inflammatory reactions.⁷

In these patients, radiography after 3 months of treatment showed a good healing. However, at 6 months after treatment, bone density on the distal periapical roots of the mesial tooth is not perfect. When compared with healing in normal patients, the healing of periapical lesions in these patients is slower. Because Autoantibodies can affect protein in the process of bone cell differentiation. Autoantibodies can affect the process of formation and inhibit healing.¹³

Loss of clinical symptoms and periapical lesions is a leading indicator of root canal treatment is said to be successful. For treated teeth with vital pulp status and no periapical lesions found before treatment, efficacy is characterized by a tooth that remains asymptomatic, and no new apical lesion is formed. The emergence of new apical lesions signifies the failure of root canal treatment. As for teeth with necrotic pulp status before treatment, it is said to succeed if the tooth

remains asymptomatic, apical lesions heal and no new apical lesions appear. If new symptoms or dilated lesions in the apical tooth indicate root canal treatment fails.⁸

CONCLUSION

The success of 46 dental endodontic treatments in patients with systemic diseases of chronic renal failure is influenced by several factors, including: Use of preoperative mouth rinses with 0.12% chlorhexidine and optimal maintenance of oral hygiene.- If there is potential for infection, care techniques should be done carefully by performing a maximum irrigation in the operative area and antibiotics.

Use of prophylactic antibiotic drugs Amoxicillin and Penicillin require dose adjustment as well as supplemental supplementation after hemodialysis and treatment of these patients, should endodontic treatment be scheduled on the day after hemodialysis. Before and on the day of hemodialysis, patients are generally tired and may have a tendency to bleed.

References

1. Olga A.C. Ibsen, RDH, MS, Joan Andersen Phelan, DDS, Oral Pathology for the Dental Hygienist 4th ed. Saunders, an imprint of Elsevier, 2004:109-111
2. Cawson's essentials of Oral Pathology and Oral Medicine, 8th ed. Elsevier, 2002:365-366
3. Von Feldt JM. Systemic lupus erythematosus. Recognizing its various presentations. *Postgrad Med* 1995; 97(4):79, 83, 86 passim.
4. Estes D, Christian CL. The natural history of systemic lupus erythematosus by prospective analysis. *Medicine (Baltimore)* 1971; 50(2):85-95.
5. Jonathan B. Albilis, DMD; David K. Lam, DDS; Cameron M.L. Clokie, DDS, PhD, FRCD(C); George K.B. Sándor, MD, DDS, PhD, FRCD(C), FRCSC, FACS, Clinical Practice Systemic Lupus Erythematosus: A Review for Dentalis, 2007.
6. Valois CRA, Costa-júnior ED. Periapical Cyst Repair After Nonsurgical Endodontic Therapy - Case Report. *Braz Dent J*. 2005;16(3):254-8.
7. Metzger Z, Basrani B, E. Good H. Cohen's Pathway of the Pulp 10th Edition. Instruments, Materials, and Devices. Elsevier Mosby; 2011. p. 253-4.
8. Torabinejad M, Walton R E, Endodontic Principles and Practise, 5th ed. Elsevier, 2009
9. Fessler BJ, Alarcon GS, McGwin G Jr, Roseman J, Bastian HM, Friedman AW, and others. Systemic lupus erythematosus in three ethnic groups: XVI. Association of hydroxychloroquine use with reduced risk of damage accrual. *Arthritis Rheum* 2005; 52(5):1473-80.

10. Ozcelik O, Haytac MC, Seydaoglu G. The effects of anabolic androgenic steroid abuse on gingival tissues. *J Periodontol* 2006; 77(7):1104–9
11. Zvi Metzger, DMD, Ronen Huber, DMD, Dragos Slavescu, DMD, Dan Dragomirescu, DMD, Idan Tobis, BSc Eng, and Hadar Better, MD, DMD. Healing Kinetics of Periapical Lesions Enhanced by the Apexum Procedure: A Clinical Trial, 2009
12. Giorgio Pagni, Gaia Pellegrini, William V. Giannobile, and Giulio Rasperini, International Journal of Dentistry, Review Article, Postextraction Alveolar Ridge Preservation: Biological Basis and Treatments, 2012
13. Barbara William Patrick, Department University Downstate, Study on a Nonhealing Fracture from a Patient with Systemic Lupus Erythematosus, 2005.

CASE REPORT

RETRIEVAL OF SEPARATED INSTRUMENT FROM THE CURVED CANAL USING ULTRASONIC TIP INSTRUMENT : A CASE REPORT

Natalia Iskandar Setiawan¹, Bernard O Iskandar², Aryadi Subrata²

¹ Resident at Department of Conservative Dentistry,
Trisakti University, Jakarta- Indonesia

² Staff of Department of Conservative Dentistry, Trisakti University, Jakarta- Indonesia

ABSTRACT

Background: One of the greatest challenge for dentist in performing endodontic treatment is extracting broken instrument during endodontic treatment on curved canal. The broken instrument may cause canal blockage which hinders cleaning and shaping procedures, irrigation of apical proportion, and influence the final outcome and prognosis of the root canal therapy. To retrieve the instrument is difficult especially due to the shape of the canal. In this paper, a more effective retrieval method using ultrasonic will be discussed.

Objective: The aim is to present the success of retrieval separated instrument in curved canal using ultrasonic tip instrument. **Case:** A 25 years old female patient came to restore the right mandibular first molar to co-ass in RSGM(P) Trisakti University, but after making the radiograph and found separated instrument in mesial canal, the patient was referred to post graduate clinic of Department Conservative Dentistry and Endodontics RSGM(P) Trisakti University. Patient gave history of root canal treatment in right mandibular first molar 2 years ago. Objective assessment showed temporary restoration in mesio-occlusal side with positive percussion test and found a sinus tract in buccal mucosa 46 tooth. Radiographic examination showed that there was separated instrument in mesial canal and apical lesion on her right mandibular first molar. Diagnostic for 46 tooth was chronic apical periodontitis et causa pulp necrotic and separated instrument. Retrieval of separated instrument with ultrasonic tip instrument combined with irrigation and dental operating microscopes was chosen and root canal treatment was performed. **Conclusion :** Retrieval of separated instrument with ultrasonic tip instrument in curved canal for 46 tooth was success and root canal treatment showed a successful treatment outcome.

Keywords : Instrument retrieval, instrument separation, ultrasonic tip instrument, root canal treatment

Introduction

The fracture of endodontic instrument within the root canal is one of the most undesirable events during endodontic procedure, because the removal becomes time-consuming, risky and limited success. But this accident has become a common error in endodontics, and when occurs, it immediately provokes anxiety, frustration and despair. The broken instrument may cause canal blockage which hinders cleaning and shaping procedures, irrigation of apical proportion, and influence the final outcome and prognosis of the root canal therapy. Patients can feel continuous pain or discomfort in the involved tooth if the broken instrument is not removed or bypassed.

There are various reasons for instrument separation inside the canal, such as over-instrumentation, increased speed with rotary instrument, loss of tactile sensation, anatomical variations like curved canals, and accessory canals. But the most common reasons of broken instrument are cyclic fatigue and torsional stress. Cyclic fatigue is caused by repetitive compressive and tensile stresses acting on the outer portion of a file rotating in a curved canal.¹ Torsional stress occurs when the tip of the instrument binds but the shank of the file (driven by the handpiece) continues to rotate.¹ Cyclic fatigue seems to be more prevalent in curved canals, while torsional stress might happen even in a straight canal.¹

The possible outcomes that may be

encountered when treating the broken instrument are nonsurgical orthograde (mechanical or chemical) or surgical approach. The nonsurgical technique such as (i) Retrieval the broken instruments, (ii) Bypass and sealing the fragment within the root canal space, (iii) True blockage and leaving the instrument. The mechanical removal involves the use of tools like extractors, wire loops, ultrasonic, and laser irradiation. The chemical removal involves the use of chemical solvents for instrument corrosion and electrochemical process for instrument dissolution. Surgical approaches include radicular surgery, intentional replantation, root amputation, or hemisection.¹

The ability to nonsurgically access and remove broken instrument will be influenced by the diameter, length, and position of the obstruction within a canal. In general, if happens in one-third of the overall length of an obstruction can be exposed, it can usually be removed. Broken instrument that lie in the straightaway portions of the canal can typically be removed. Instruments that lie partially around canal curvatures, although more difficult, can oftentimes be removed if straightline access can be established to their most coronal extents. But when the fragment is in one-third apical to the curvature of the canal and safe access cannot be accomplished, then removal is usually not possible, and in the presence of signs and symptoms, the final choice is surgery or an extraction.²

The type of material is another important factor to be considered. Stainless steel files tend to be easier to remove than nickel-titanium, because they do not further fracture during removal process, but in nickel-titanium may break again, albeit deeper within the canal, during ultrasonic efforts presumably due to heat buildup.²

In this case report, a more effective retrieval method using ultrasonic will be discussed when there was file separation inside the canal.

Case Report

A 25 years old female patient came to restore the right mandibular first molar to co-ass in RSGM(P) Trisakti University, but after making the radiograph and found separated instrument in mesial canal, the patient was referred to post graduate clinic of Department Conservative Dentistry and Endodontics RSGM(P) Trisakti University. The patient gave a history of root canal treatment in the mandibular back teeth 2 years ago. She felt uncomfortable when eating.

Clinical examination revealed that there was sinus tract in buccal mucosa 46 tooth. The teeth was tender on percussion, palpation and when had a bite test. The surrounding gingival tissue and the pocked depths was within the normal limits. Sensibility tests (cold test) performed on 46 tooth and revealed the nonvitality of both teeth. Objective assessment showed temporary

restoration in mesio-occlusal side (Fig 1). Radiographic examination showed that there was separated instrument in mesial canal that and apical lesion on her right mandibular first molar (Fig 2). The mesial canals were curved based on radiograph and the broken instrument was in there.

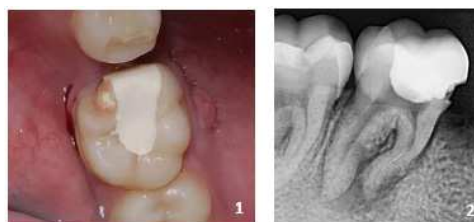

Fig. 1. Preoperative Photo and sinus tract in buccal mucosa #46.

Fig. 2. Preoperative radiograph #46.

Diagnostic for 46 tooth was chronic apicalis periodontitis etcausa pulp necrotic and separated instrument. Non-surgical root canal treatment was planned and the patient was informed about the treatment plan. After patient agree with the treatment plan, she signed the informed consent. Root canal retreatment was initiated in 46 tooth under the rubber dam isolation. The previous restoration was removed and the access opening was enlarged, then rewalling was made (Fig 3).

Retrieval of separated instrument with ultrasonic tip instrument combined with irrigation and dental operating microscopes was chosen with this following procedure : (i) First step in the removal of broken instruments is make a straight coronal access with tapered fissure highspeed bur to have a straight access to orifice. (ii)

Based on radiographic examination, the broken instrument lied in middle-third mesiobuccalcurved root. So the second step is radicular access, the root canal is enlarged to make staging platform around the head of broken instruments with ultrasonic tip ET25 (*EndoSuccess™*) and activated with ultrasonic device (*P5 Newtron Ultrasonic Device*) (Fig 4a and 4b) and helped with Dental Operating Microscope (*Zeiss*).

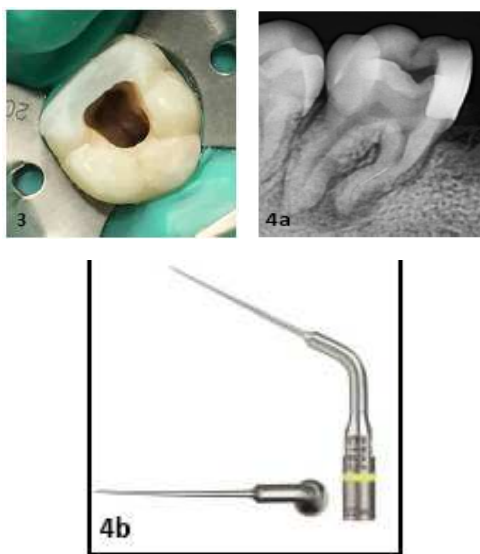


Fig. 3. Rewalling in mesial side of #46. Fig. 4a. Radiograph of #46 after rewalling and making straight opening access. Fig. 4b. ET25 (*EndoSuccess™*)

Root canal was irrigated with sodium hypochlorite (NaOCl) 2.5% to assist the broken instrument movement and lower the heat of the ultrasonic tip. After a while, the broken instrument was removed from the root canal (Fig 5a and 5b). A radiograph was then taken to confirm the retrieval of the broken instrument from 46 tooth (Fig 6).

Then the root canal was irrigated with the protocol NaOCl 2.5% (5mL), saline sterile (3mL), EDTA 17% (2 mL), and saline sterile (2mL), then all canals were dried with paper point sterile.

Calcium hydroxide (*Ultracal XS, UltraDent*) was used as an intracanal medicament and closed dressing was given for two weeks.

In the next visit, after flushing the canals with NaOCl 2.5%, biomechanical preparation was completed by crown down technique using *Mtwo Rotary (VDW)*. First, working lengths were estimated in 46 tooth using K-file #10 and confirmed by electric apex locator (*Root ZX II, Morita*) and radiograph (Fig 7). The working length of distal (19 mm), mesiobuccal (16mm), and mesiolingual (17mm). Then, all canals were shaped (with 10/.04 (*MTwo, VDW*), 15/.05 (*MTwo, VDW*), 20/.06 (*MTwo, VDW*), for mesiobuccal and mesiolingual used 25/.06 (*MTwo, VDW*) as a final file. For distal after 25/.06 (*MTwo, VDW*), the final file was 30/.05 (*MTwo, VDW*). In between the instrumentation, the canals were irrigated with NaOCl 2.5% and did apical patency with #08 one mm longer than working length.

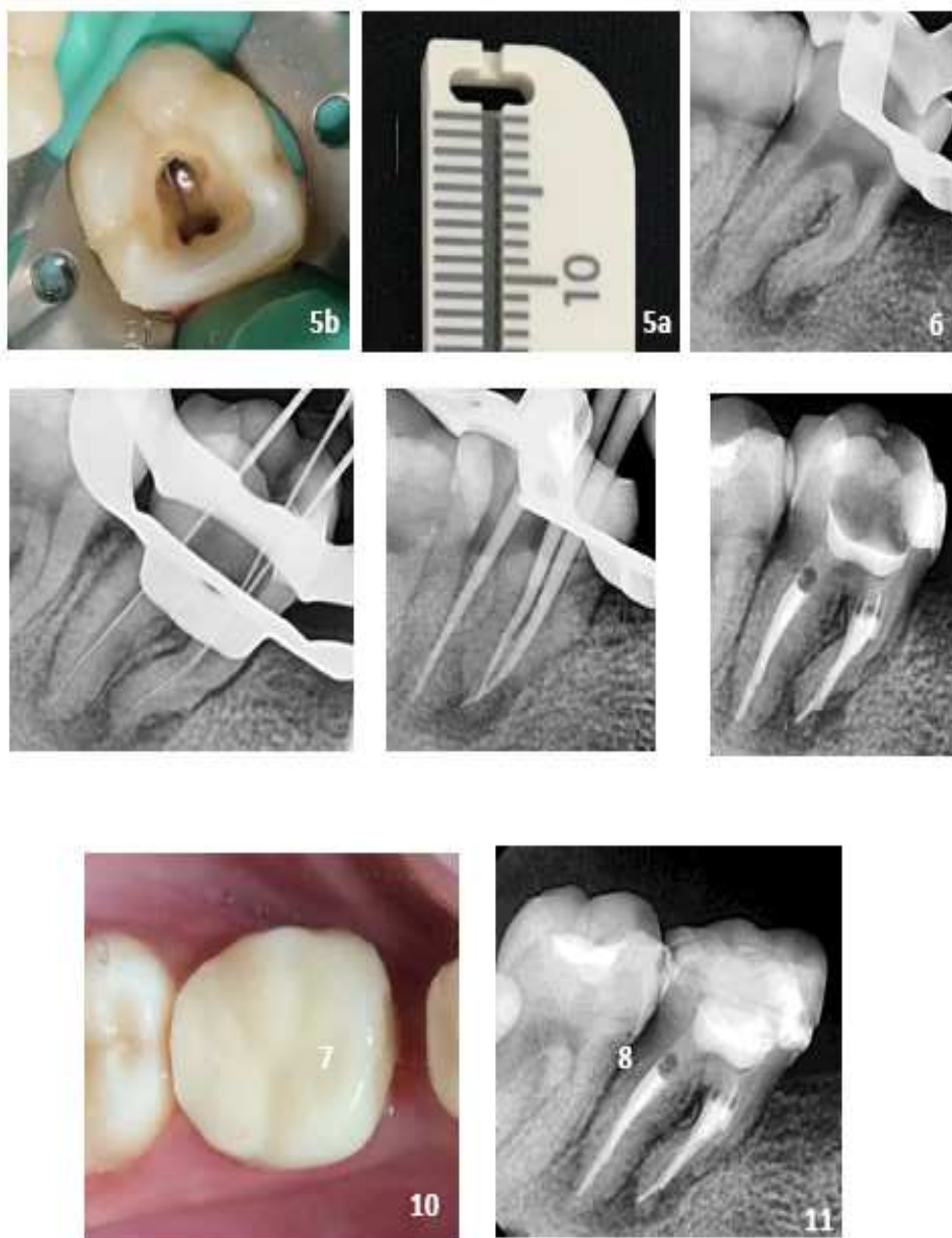

Fig.5a. Broken instruments successfully retrieved from the mesiobuccal canal. Fig.5b. The measurement of broken instruments (4mm). Fig.6. The radiograph showing the teeth after retrieval of instrument. Fig.7. The radiograph of working length (MB = 16 mm, ML = (17mm), Distal = 19 mm). Fig.8. Confirmation of Master Cone Radiograph (MB&ML = 25/.06 and Distal = 30/.05). Fig.9. Photograph after obturation. Fig.10. After sementation of endocrown in #46. Fig 11. Photograph of final restoration after sementation in #46.

Before obturation, all canals were irrigated with NaOCl 5.25% (3 ml), saline sterile (3 ml), EDTA 17% (3 ml), saline sterile (3 ml) and final rinse with Chlorhexidine 2% (3 ml) and saline sterile (3 ml). Then, dried all canals and a master cone radiograph was taken (25/.06 for mesiobuccal and mesiolingual canal and 30/.05 for distal canal) (Fig 8). Vertical condensation technique method of obturation was performed using Calcium Hydroxide sealer (Sealapex, SybronEndo) and confirmed with radiograph (Fig 9). The tooth was restored with endocrown as a final restoration (Fig 10 and 11).

Discussion

Retrieval of broken instruments has become a challenging part of root canal therapy. Various attempts can be made to remove the broken file to increase the longevity of the treatment option. Several methods are described to remove broken instruments or objects within root canals. The evaluation of fractured instrument removal system and techniques, such as the Masserann Kit, Endo Extractor (Brasseler USA Inc.), wire loop technique, the Canal Finder System, and ultrasonic devices.³ The limitations of these devices include excessive removal of root canal dentin, ledge formation, perforation, limited application in narrow and curved roots, and extrusion of the fractured portion through the apex.

One of the most important factors to be considered prior to instrument retrieval

is to obtain a straight line access to the coronal end of the separated instrument. The loss of dentine increases the chances of teeth to fracture. Excessive instrumentation of the root canal and dehydration of dentine may lead to fracture of the teeth. Hence, it is advisable to do under dental operating microscope and use irrigation during the procedure. Successful removal of such obstructions relies on factors such as the position of the instrument in relation to the canal curvature, depth within the canal, and the type of fractured instrument. The more apical the location of the broken instrument, the greater the potential for root perforation and the lower the fracture resistance of the root after removal the instrument.

In straight canals, the broken instruments were removed by a conventional method or Masserann Kit. The removal of the broken instruments using traditional methods is time-consuming, risky and has limited success. However, in curved canals, like in this case report, broken instruments were removed with ultrasonic devices.⁴ The use of ultrasonic devices for the management of broken instrument has shown successful results avoiding further canal obstructions and is advantageous over conventional methods for retrieval of broken instruments as it is able to set separated instruments free from canals without sacrificing the dentin.

Ultrasonic tips mounted on an ultrasonic hand piece are used with dental loupes or under a dental operating

microscope. A long thin titanium ultrasonic tip is selected, used at lowest power. The tip is applied circumferentially to the smaller number file placed inside the canal to remove dentin around head of the file. This procedure is carried out slowly with intermittent usage of water and air coolant. Continue the process until some length of the file stands free within the canal space and some movement of the fragment is noticed.⁵ Once some movement is seen, then ultrasonic vibration with NiTi ultrasonic tip is applied to remove the fragment and the irrigation is helpful to move the fragment.⁶

Conclusion

Retrieval of separated instrument with ultrasonic tip instrument in curved canal was success and root canal treatment showed a successful treatment outcome. Among the various techniques for retrieval, ultrasonic is one of the most effective if used with dental magnification. Successful management of broken instrument is thus defined as removal or complete bypassing the fragment without creating a perforation. The best preventive technique to avoid broken instrument which can be done by constant monitoring the usage of file. Prevention of file separation is always more desirable than attempted removal. Adhering to proven concepts, integrating best strategies, and utilizing safe techniques during root canal preparation procedure will virtually eliminate the broken instrument procedural accident.

References :

1. Terauchi, Y. Managing Iatrogenic Endodontic Events. Dalam : Cohen S Pathway of the pulp. Ed 11. St.Louis : Mosby; 2016. Hal 725-726
2. Ruddle, C.J. Nonsurgical Retreatment : Post & Broken Instrument Removal. J Endod. 2004. Hal 13-18.
3. Chauhan, R., Chandra, A., dan Singh, S. Retrieval of a separated instrument from the root canal followed by non-surgical healing of a large periapical lesion in maxillary incisors – a case report. Endodontology. 2013; 25(2) : 68-73.
4. Gencoglu, N. dan Helvacioğlu, D. Comparison of the different techniques to remove fractured endodontic instruments from root canal system. Eur J Dent. 2009; 3: 90-5
5. Sokhi, R., Sumanthini, MN., Shenoy, V. Retrieval of separated instrument using ultrasonic in a permanent mandibular second molar: A case report. J Contemp Dent. 2014; 4: 41-5
6. Terauchi, Y., O'Leary, L., Suda, H. Removal of separated files from root canals with a new file-removal system : Case reports. J Endod. 2006; 32:789-97.

CASE REPORT

RETAINING EXTENSIVE CAVITY HYPERPLASTIC PULPITIS MANDIBULAR FIRST MOLAR WITH PULPECTOMY AND ENDOCROWN : A CASE REPORT

Paulus Alexander¹, Eko Fibryanto², Taufiq Ariwibowo²

¹ Resident at Department of Conservative Dentistry Trisakti University, Jakarta-Indonesia

² Staff at Department of Conservative Dentistry Trisakti University, Jakarta-Indonesia

Background :Hyperplastic pulpitis (pulp polyp) is common occur in children and young adult permanent molar.This condition usually characterized by a reddish, cauliflower-like outgrowth of connective tissue into caries lesion. Since it contains few nerve fibers, it is non-painful but bleeds easily due to rich networkof blood vessels.Extraction of permanent molar can lead to malocclusion, aesthetic and functional problems. **Objective :** the aim of this case report is to present a successful treatment outcome of retaining extensive cavity hyperplastic pulpitis mandibular first molar with pulpectomy and endocrown.**Case :** 21 years old female was referred for root canal treatment on the mandibular right first molar with hyperplastic pulpitis. Clinical assessment showed extensive loss of tooth structure. Radiographic examination showed cavity extended to the pulp horn with small periapical radiolucency around the mesial root. Root canal treatment was performed with Protaper Next systemand calcium hydroxide as medicament. One week later the tooth was obturated with gutta-percha and followed by composite endocrown for final restoration. **Conclusion :** retaining extensive cavity hyperplastic pulpitis mandibular first molar with pulpectomy and endocrown showed a successful treatment outcome.

Keyword : Hyperplastic pulpitis, root canal treatment, endocrown

Introduction

Hyperplastic pulpitis is a type of irreversible chronic pulpitis.¹ It is common occur in children and young adult teethwhere the pulp has been exposed by caries or trauma, usually in permanent molar.^{1,2}Mechanical irritation and bacterial invasion result in a level of chronic inflammation that produces hyperplastic granulation tissue extrudes from the chamber and often fills the associated dentinal defect.¹This condition usually

characterized by a reddish, cauliflower-like outgrowth of connective tissue into caries lesion.² Since it contains few nerve fibers, it is non-painful but bleeds easily due to rich network of blood vessels.

Rehabilitation of endodontically treated teeth with large coronal destruction is still a clinical challenge, especially due to the loss of strength characteristics associated to the removal of pulp and surrounding dentin tissues. Coronal retention of the

restoration is usually compromised, thus intraradicular posts combined or not with core materials may be required. Despite all clinical success achieved with the use of intraradicular posts, one disadvantage of this system is the additional removal of sound tissue needed for fitting the post into the root canal. Alternatively, other restorative approaches have been suggested, including but not limited to the well-known endocrown restorations. Endocrowns assemble the intraradicular post, the core, and the crown in one component, thus representing monoblock restorations. Different from conventional approaches using intraradicular posts, endocrown restorations are anchored to the internal portion of the pulp chamber and on the cavity margins, thereby resulting in both macro- and micro-mechanical retention, provided by the pulpal walls and adhesive cementation, respectively.³

Case Report

Twenty one years old female was referred to department of conservative dentistry Trisakti University with the chief complaint of felt uncomfortable while chewing food. She told that there was a big cavity in the mandibular right first molar, and it had been happen since long time ago but she never felt any pain. Clinical assessment showed extensive loss of tooth structure on the occlusal (Fig.1). Red granulation tissue were seen in the center cavity with the gingival extension on the mesial side. Vitality test showed the tooth response to cold test. The tooth had

no tenderness on palpation, percussion, and no mobility. No fistulae and edema was observed. Radiographic examination showed cavity extended to the pulp horn with small periapical radiolucency around the mesial root (Fig.2). The clinical and radiographic examination led to a diagnosis of chronic hyperplastic irreversible pulpitis and requiring root canal treatment.

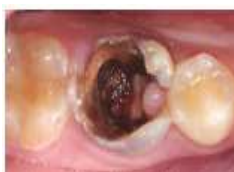

Figure 1.
Preoperative

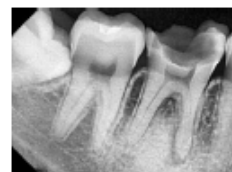

Figure 2. Initial
radiograph

On the first visit, caries and granulation tissue was remove with a round diamond bur in a high speed hand piece. This step was done under anesthesia. Artificial wall was made aroundtooth wall with composite resin (Fig.3) and followed by isolation of the tooth using rubber dam. After pulp extirpation and obtaining the canal patency, C+file (Denstply, Maillefer) size #10 was inserted and working length was determined using Root ZX II apex locator (Morita) and confirmed with radiograph (Fig.4). Root canal treatment was performed with Protaper Next systemand calcium hydroxide as medicament.

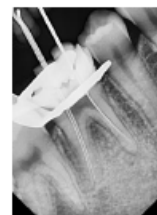
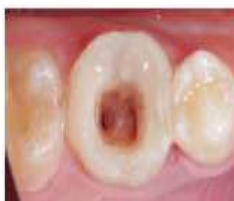
Figure 3. Artificial wall was made from composit resin prior to treatment.

Figure 4. Radiograph of working length determination

in hyperplastic changes. A tooth with a hyperplastic pulpitis and periapical involvement presents many difficulties in diagnosis and treatment. It is believed that radiographically, the pulpal lesion does not show any periapical changes. In this case, there was periapical lesion. It could happened because of delay in treatment. The inflammation were spread into the periodontal ligament space through the apical foramen.⁴ Periapical lesion occurs due to the extension of micro-organisms, and their metabolic products, toxins, enzymes from pulpal tissue into the periapical space.⁴

Second visit was seven days later, patient was clinically evaluated and the tooth remained asymptomatic. Master cones gutta-percha inserted to the canals and confirmed with radiograph. Obturation was performed with gutta-percha Protaper Next X2 (Densply, Maillefer) and root canal sealer (Saelapex, SybronEndo) using vertical condensation technique (Fig.5). The tooth was then restored with composite endocrown (Fig.6 and Fig.7).

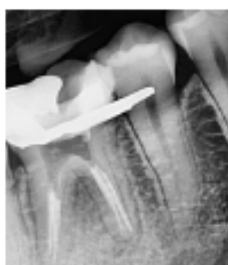

Figure 5. Obturation result.

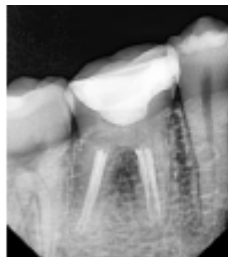

Figure 6. Radiograph of final restoration.

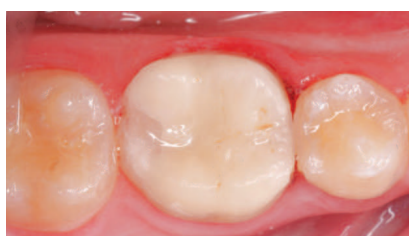

Figure 7. Composite endocrown as a final restoration.

Discussion

Chronic hyperplastic pulpitis or proliferative pulpitis is also known as pulp polyp. It is the protective response against the tissue inflammation resulting

Management of the tooth with chronic hyperplastic pulpitis includes extraction when minimal amount tooth structure remains which is unfavourable for restoration and conservatory approach requires a multidisciplinary approach including endodontic management, surgical crown lengthening and prosthodontic management. In cases of pulp polyp in young adults where there is only coronal pulpal tissue involvement pulpotomy has also been suggested as a treatment option.² Extraction of permanent molar can lead to malocclusion, aesthetic and functional problems.

The remainin tooth structure in this case was not enough to give ferrule for crown restoration, and had to be done by surgical crown lengthening. In the other way, endocrown can be the option for restoring the tooth with extensive loss of tooth structure. Endocrowns assemble

the intraradicular post, the core, and the crown in one component, thus representing monoblock restorations.³ The available literature found suggests that endocrowns may perform similarly or better than the conventional treatments using intraradicular posts, direct composite resin or inlay/onlay restorations.³

Conclusion

The success of endodontic treatment are depening on good root canal treatment and good restoration. Retaining extensive cavity hyperplastic pulpitis mandibular first molar with pulpectomy and endocrown showed a successful treatment outcome.

References

1. Faryabi J, Adhami S. Unusual Presentation of Chronic Hyperplatic Pulpitis: A Case Report. *Iran Endod J*. 2008; 2(4): 156–158.
2. Anilkumar K, Lingeswaran S, Ari G, Thyagarajan R, Logaranjani A. Management of Chronic Hyperplastic Pulpitis in Mandibular Molars of Middle Aged Adults- A Multidisciplinary Approach. *Journal of Clinical and Diagnostic Research*. 2016;10(1): ZD23-ZD25.
3. Sedrez-Porto JA, et al. Endocrown restorations: A systematic review and meta-analysis. *Journal of Dentistry*. 2016;52:8–14
4. Suresh KV, Bajaj N, Nayak AG, Chapi DMK, Patil S, Rani A. Pulp polyp – A Periapical Lesion: Radiographic observational study. *J Indian Acad Oral Med Radiol*. 2015;27:68-71.

CASE REPORT

COMPREHENSIVE TREATMENT OF MAXILLARY ANTERIOR TEETH : A CASE REPORT

Priska Lasari¹, Tien Suwartini², Wiena Widyastuti²

¹ Resident at Department of Conservative Dentistry, Trisakti University,
Jakarta- Indonesia

² Staff of Department of Conservative Dentistry, Trisakti University, Jakarta- Indonesia

ABSTRACT

Background : Restoration of teeth becomes more complex when the involved teeth have a large cavity, endodontic and aesthetic requirements. Modern dentistry aims at conservation of remaining tooth structure with minimally invasive treatment in restoring the function and aesthetic aspect. Anterior teeth with minimal loss of tooth structure can be restored conservatively with composite restorations. **Objective :** the aim of this case report is to present a successful treatment of maxillary anterior teeth with endodontic treatment and composite restoration. **Case :** A 16th years old female patient desire esthetic smile with affordable restoration. Patient felt dull pain in her anterior maxilla since 1 month ago. Clinical examination showed cavities and demineralization on her lateral and central upper incisor. Radiographic examination showed cavity extended to the pulp and periodontal ligament widening on her left second incisor tooth and right central incisor tooth. Examination, diagnosis and treatment planning was made for maxillary anterior teeth. CPP-ACP was given to suppressed demineralization and enhanced remineralization. One visit endodontic treatment was performed on her left second incisor tooth and right central incisor tooth, followed by composite restoration as the final restoration. **Conclusion :** This article describes a comprehensive treatment to restore function and aesthetics of maxillary anterior teeth with a successful endodontic treatment and composite restoration as the final restoration.

Keyword : endodontic treatment, anterior teeth, aesthetic restoration

INTRODUCTION

The important role of anterior teeth in esthetics and function makes these teeth a significant component in dentition.¹ Restoration of teeth becomes more complex when the involved teeth have a large cavity, endodontic and aesthetic requirements. The primary aim of endodontic treatment is to reduce

or eliminate micro-organisms and their by-products from the root canal system.² The aims of coronal restoration of endodontically treated teeth are generally considered to be the following ones: to prevent recontamination of the root canal system and / or periapical space, to replace missing hard dental tissues and to restore coronal morphology and functions, to

provide the necessary strength for the restoration/tooth complex in order to withstand functional stress and prevent crown and/or root fracture.⁵Endodontically treated teeth are weaker than intact teeth due to loss of tooth structure, reduction in tooth flexural strength, change in the collagen cross-links and moisture content reduction and tooth dehydration.³ Canal enlargement and cavity preparation can reduce the stiffness of the teeth and brittleness could be a final result of a root canal treatment. Placement of a crown is not necessary just because an anterior tooth is endodontically treated. It becomes a matter of clinical judgment depending on whether the tooth can be adequately restored to form and function with direct restorative materials.⁴ Now modern dentistry aims at conservation of remaining tooth structure with minimally invasive treatment in restoring the function and aesthetic aspect. Anterior teeth with minimal loss of tooth structure can be restored conservatively with composite restorations. Composite resin is a material that has a good performance and increases the longevity of treatment. The restorative material should have physical and mechanical properties similar to tooth structure for achieving clinical success. The aim of this case report is to present a successful treatment of maxillary anterior teeth with endodontic treatment and composite restoration.

CASE

A 16th years old female patient desire esthetic smile with affordable restoration.

Patient felt dull pain in her anterior maxilla since 1 month ago. Clinical examination showed cavities and demineralization on her lateral and central upper incisor. The patient has never had a dental check up to treat the pain. The patient's medical history has no systemic findings.

Extraoral evaluation revealed normal soft tissue structures with no apparent pathosis. Intraoral examination showed all the incisor maxillary teeth with cavities and were discolored with white-brownish bands of discoloration on the middle third and cervical third without any pitting or grooves.

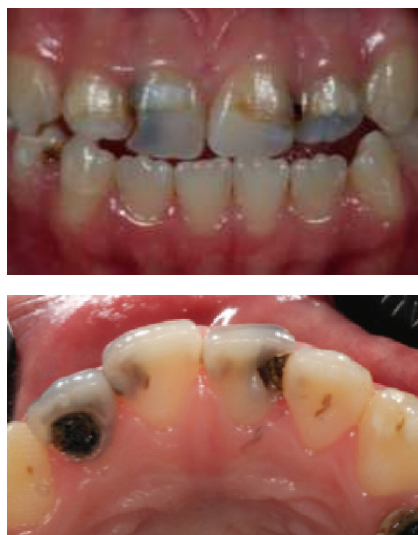

Fig. 1(A). Labial view: Discolored maxillary anterior teeth with cavity on mesial right lateral incisor #12, distal and mesial central incisor #11 and distal central incisor #21, and mesio-palatal lateral incisor #22; (B) Palatal view : large cavity on the palatal #22

Radiographic examination showed cavity extended to the pulp and periodontal ligament widening on her left second

incisor tooth and right central incisor tooth. There was no periapical lesion visible on the radiograph.

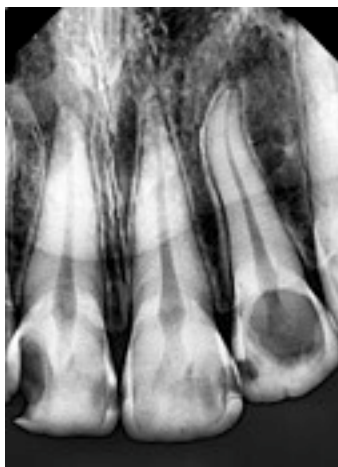

Fig. 2. Initial radiograph showed cavity extended to the pulp on #11 and #22

Diagnostic tests revealed lingering pain to cold tests. Electric pulp testing (EPT) results showed a more intense response in the involved tooth as compared to the contralateral healthy mature permanent tooth. After complete clinical and radiographic examination, a diagnosis of irreversible pulpitis for #11 and #22 were made and the tooth requires endodontic treatment. The diagnosis for #12 and #21 were reversible pulpitis and the tooth requires restorative treatment.

CPP-ACP was given to suppressed demineralization and enhanced remineralization. One visit endodontic treatment was performed on her left second incisor tooth and right central incisor tooth, followed by composite restoration as the final restoration.

CASE MANAGEMENT

The tooth #22 and #11 was anaesthetized with 2% lidocaine with 1:100,000 epinephrine. Carious lesion was removed with carbide bur and round diamond bur. Access cavity was prepared using endo access diamond bur no. 2 and high speed hand piece. The pulp was extirpated with nerve broach (Spiro Colorinox, Dentsply). The artificial wall was made on palatal wall with composite resin and rubber dam isolation was performed. Initial exploration of the canal using #8 K-File and #10 K-File. Working length was determined using Root ZX II apex locator (Morita) and confirm with radiograph. After establishing glide path with Proglider (Dentstply, Maillefer) size #16.02, the canal were shaped with Protaper Next (Dentstply, Maillefer) file X1 #17.04, X2 #25.06, and X3 #30.07 sequentially. Apical gauging with #30 K-File. In between instrumentation, copious irrigation was done with 5.25% NaOCl (Chloraxid, Cerkamed), saline and 17% EDTA Solution (MD Cleanser, META BIOMED). Obturation was performed with gutta-percha Protaper Next X3 (Dentstply, Maillefer) and root canal sealer (Saelapex, SybronEndo) using vertical condensation technique. The tooth was then restored with composite resin (Palfique, Tokuyama).

Patient was followed up 6 month later, the subjective and objective examination showed asymptomatic throughout.

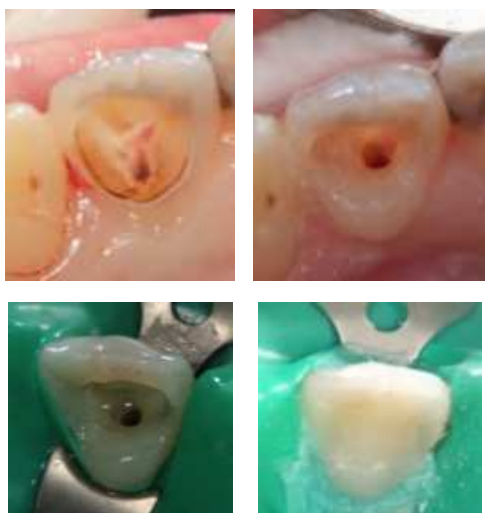

fig. 3. Treatment of tooth #22.(A) removal of the carious lesion; (B) artificial wall was made with composite resin; (C) rubber dam isolation was performed (D) composite resin restoration

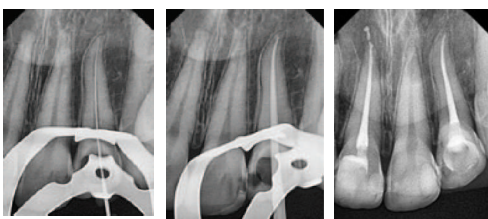


fig. 4 . Radiograph of tooth #22 (A) Working length was confirmed by radiograph; (B) Mastercone radiograph (C) Post-obturation radiograph

The same procedure was applied to the tooth #11

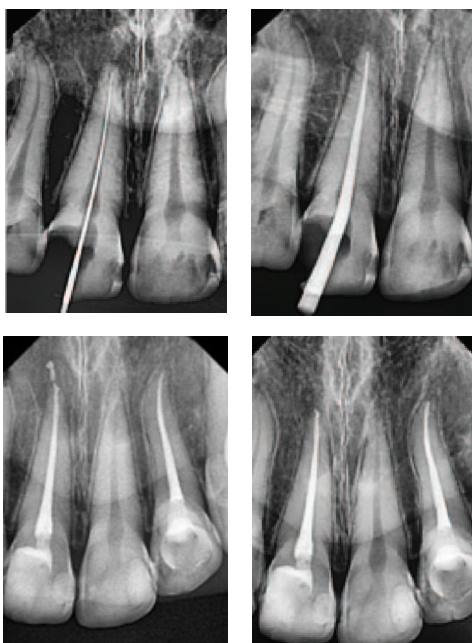


fig. 5 . radiograph of tooth #11 (A) Working length was confirmed by radiograph; (B) Mastercone radiograph (C) Post-obturation radiograph showed sealer extruded to the apical. (D) Follow up 6 month post-obturation

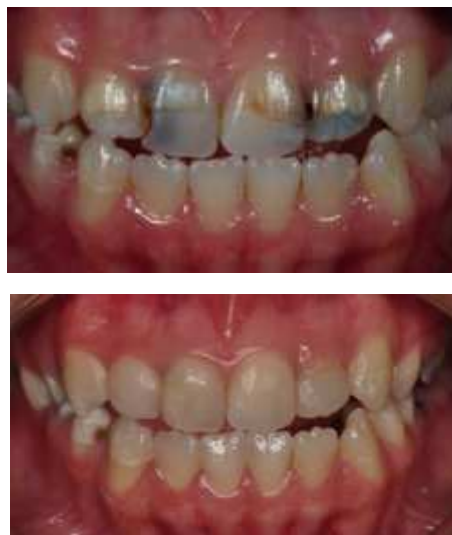

fig. 6. (A) Labial view pre-operative treatment; (B) Post-operative endodontic treatment and composite resin restoration

DISCUSSION

Coronal restoration for endodontically treated teeth needs taking into consideration that reduced tooth structure resulting from caries or trauma and from cavity preparations has a negative influence on the fracture resistance of teeth.⁵ Physical maneuvering during endodontic procedures in the form of access cavity and canal preparations and obturation may also introduce micro-cracks and fatigue that could further weaken the tooth. All those possibilities together with well established fact of reduced moisture content will make intact endodontically treated teeth generally weaker or more brittle than their vital counterparts. Study by Michael et al showed adequate result to restore intact endodontically treated anterior teeth with just composite resin in patients with normal biting force.³ Full coverage restoration is not always necessary to restore those teeth. Restoration with full coverage restoration will add other disadvantages such extra clinical procedures and time, unnecessary removal of tooth structure and extra cost. The restoration will not add extra strength to those teeth.³

The restorative material should have physical and mechanical properties similar to tooth structure for achieving clinical success. Nanocomposites have a high mechanical resistance to fracture and wear, lower polymerization shrinkage, excellent polishing, color stability, and good optical properties such as fluorescence and translucency, and are safely indicated for

restorations of anterior and posterior teeth.⁶

The advances in dental materials in recent years have revolutionized the concepts applied to restorative dentistry, making it basically an adhesive dentistry. The development of resinous materials and adhesive systems allows minimally invasive procedures and highly esthetic restorations, preserving a greater amount of dental tissue, which is highly advantageous.⁶

CPP-ACP (Casein phosphopeptide–amorphous calcium phosphate) was given to the patient to reduced the demineralization. Wu et al studied result CPP-ACP tooth mousse can reduce the size and mean grey level of demineralized areas and promote the remineralization of bovine enamel, and combined application with fluoride toothpaste strengthens the effect.⁷ Ranjitkar *et al.*, stated that this may be due to both lubricating and remineralizing effects of CPP-ACP.⁸ Previous studies have shown that the anticariogenic effect of CPP-ACP may be responsible for the prevention of enamel erosion.⁹ Moreover, it is well documented that CPP-ACP can increase microhardness of enamel and reduce erosion caused by cola drinks.¹⁰

CONCLUSION

Maximum preservation of healthy tooth structure and use of restorative materials with mechanical properties similar to dental structure favor greater longevity of the tooth–restoration complex. Composite resin is a material that has a good

performance and increases the longevity of treatment. Therefore, it is possible to conclude that nanocomposite resins can be indicated for anterior teeth restorations, as they demonstrate good optical and mechanical properties. Furthermore, the resin composite restorations promote an effective long-term performance.

REFERENCES

1. Singh S, et all. Esthetic and Functional Rehabilitation of Maxillary Anterior Tooth by Polyethylene Fibre Post. *Austin J Clin Case Rep*. 2016; 3(3) 1094.
2. Sardhara Y, Dhanak M, and Parmar. Management of Maxillary Central Incisor with Calcified Canal : Case Report. *IOSR*. 2016;24-27
3. Michael, et all. Fracture resistance of the endodontically treated teeth: an in vitro study. *Orofacial Sciences* (2010), **5**(2): 36-41
4. McComb D. Restoration of the Endodontically Treated Tooth. *PEAK Ontario*. 2008
5. VĂrlan C, Dimitriu B, VĂrlan V, Bodnar D, Suciu I. Current opinions concerning the restoration of endodontically treated teeth: basic principles. *Journal of Medicine and Life*. 2009;2(2):165-172.
6. Gouveia, et all. Esthetic smile rehabilitation of anterior teeth by treatment with biomimetic restorative materials: a case report. *Clinical, Cosmetic and Investigational Dentistry*. 2017;9 27–3
7. Wu G, Liu X, and Hou Y. Analysis of the effect of CPP-ACP tooth mousse on enamel remineralization by circularly polarized images. *The Angle Orthodontist*. 2010 (80): 933-938.
8. Ranjitkar S, Rodriguez JM, Kadionis JA. The effect of casein phosphopeptide amorphous calcium phosphate on erosive enamel and dentine wear by toothbrush abrasion. *J Dent*. 2009;37:250–4.
9. Manton DJ, Cai F, Yuan Y, Walker GD, Cochrane NJ, Reynolds C, et al. Effect of casein phosphopeptide-amorphous calcium phosphate added to acidic beverages on enamel erosion *in vitro*. *Aust Dent J*. 2010;55:275–79.
10. Tantbirojn D, Huang A, Ericson MD, Poolthong S. Change in surface hardness of enamel by cola drink and a CPP-ACP paste. *J Dent*. 2008;36:74–9

DISCOLORATION TREATMENT WITH IN OFFICE BLEACHING : A CASE REPORT

Rike Kapriani

¹ Resident at Department of Conservative Dentistry, Padjajaran University,
Bandung- Indonesia

² Staff of Department of Conservative Dentistry, Padjajaran University,
Bandung- Indonesia

ABSTRACT

Tooth discoloration can impact on a persons physical attractiveness and self-confidence. External bleaching considered as a conservative treatment for discolored teeth. The aim of this study was to showed successful treatment in office bleaching technique. A 37 years old woman came to RSGM UNPAD with chief complaint in yellowish teeth since 5 years ago. She drinks three cups of tea per day. In-office bleaching was done by using hydrogen peroxide 40%, followed by Potasium Nitrate 3% and CPP-ACP application. The patient was satisfied with the result, teeth become whiter and brighter. Discoloration treatment by using in-office bleaching technique according to the protocol , will give significant outcome without adverse side effect.

Keyword : discoloration in office bleaching hydrogen peroxide 40%

INTRODUCTION

Tooth discoloration can impact on a persons physical attractiveness and self-confidence. The causes of tooth discoloration are divided into those caused by extrinsic factor and those caused by intrinsic factor. Intrinsic factor due to chromatogenic agents during odontogenic process dan eruption, aging processs, tetracycline consumption, highly flouridated exposure,growth and developmental abnormalities, caries, restoration, trauma during tooth germ development. Extrinsic factor due to colourful food and beverages, smoking, poor oral hygiene.¹⁻⁴

External bleaching is the treatment of choice in treating patients with dental discoloration rather than restorative procedures and veneer preparation. Professional bleaching can be done in dental clinic (in office bleaching) and can be done at home with supervision by dentist (home bleaching) or a combination of both.

CASE

A 37-year-old female patient came to RSGM FKG UNPAD with a complaint to improve her yellowish teeth. Patients drinking three cups of tea per day that lasts from young age. She wants to bleach her teeth to boost his confidence. A history of

systemic disease in the form of chronic gastritis disease was revealed.

Based on an objective examination showing a neat arrangement of teeth, the color of yellowish-colored teeth C3 using Vitapan shade guide. There were several teeth was lost, 37 and 46, cervical abrasion 44,45. Extra oral examination shows symmetrical faces, lips and temporomandibular joints no abnormalities, as well as the left and right submandibular glands are not palpable and painless. Intra oral examination good oral hygiene, neat arrangement of teeth, vital teeth, color of C3 teeth based on shade guide vita classic. The diagnosis of this case is discoloration of the maxillary and mandibular teeth due to extrinsic factors. Treatment plan is in office bleaching with 40% hydrogen peroxide. The prognosis is good because the patient is cooperative, the clinical state is good, and the etiology of the discoloration is due to extrinsic factors.

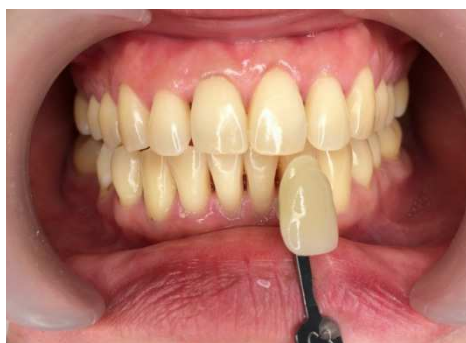

Figure 1. Initial color C3

The treatment procedure begins with the insertion of a cheek retractor and performing oral prophylaxis. The teeth are dried and isolated, then isoblocked

was put to hold the upper and lower teeth, avoid contact and prevent the tongue from moving towards the anterior and lateral (Figs. 2 and 3).

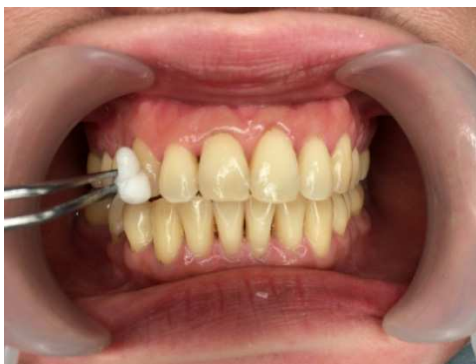

Figure 2. Topical flour polishing

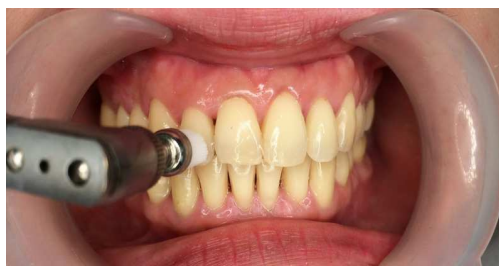

Figure 3. Cleaning with brush

Apply a softdam material (Figure 4) to the gingival region starting at the distal portion of the upper second premolar to the distal second left premolar subsequently distal portion of the lower right premolar to the left second premolars. The application of this soft dam to the formation of 4-6 mm height and 1-2 mm thickness, activated by using light curing unit 20 seconds with scanning motion (Figure 5).



Figure 4. Softdam Materials

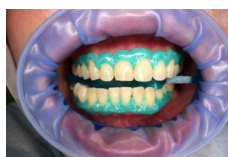

Figure 5. *Softdam* application



Figure 6. Stirring bleaching materials

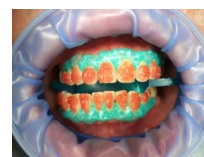


Figure 7. Application of bleaching materials

The next step is to prepare the bleaching material by mixing 40% hydrogen peroxide in red syringe and sodium fluoride and potassium nitrate on a transparent syringe (Opalescence Boost, Ultradent). Mixed with strong and fast pressure at least 25 times (12-13 times each side). Then the whole mixture of bleaching material is placed in a red syringe, and paired the applicator tip on the red syringe (Figure 6). The bleaching material is applied to the labial surfaces 0.5-5mm by thickness. The bleaching material is checked periodically whether there is a thin region and requires addition of the material. The bleaching material is cleaned by using waterfree suction after 20 minutes and the gingival barrier is maintained. Color change evaluation after the first application, obtained D4 color so that the application procedure is repeated again. After the application of both desired colors has been reached, the bleaching material is cleaned. Patients are instructed to avoid color foods and drinks during the first 2 weeks (Figure 7).

The next step is the application of Ultra Ez Desensitizing Gel and CPP-ACP (GC Tooth Mousse, GC for 5 minutes). The patient feel mild pain in her lower premolar. After application of Ultra Ez and CPP-ACP, the patient is asked to rinse again, the pain is felt much reduced. Patients went home with CPP-ACP, Ultra EZ Desensitizing Gel (Ultradent, Fondaco) and toothpaste sensitive toothpaste (opalescence whitening toothpaste) for home use.

After a week, the patient recalled for controlled and evaluated the stability of the color that has been achieved (measured with the vita shade guide classic, and obtained A2 color). The patient is satisfied, and advised to control in the next 6 months (Figures 8 and 9).

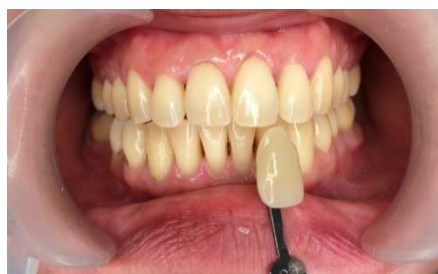

Figure 8. Before bleaching in office

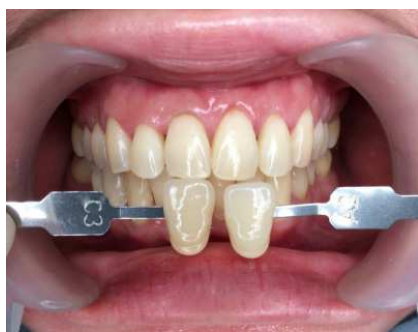

Figure 9. After bleaching

DISCUSSION

Increased public knowledge about dental care is so advanced, including the desire to improve performance. The desire to look attractive by having a beautiful smile and tooth color becomes one of the demands in society. This is in line with the development of aesthetic science and technology such as bleaching treatment.⁵

Bleaching is a treatment to remove tooth discoloration by using chemicals without removing the tooth tissue structure. It is the simplest treatment to improve tooth color, compared to other techniques such as direct veneer and indirect restoration.. Commonly used materials for external bleaching are 30-35% hydrogen peroxide and 3-15% carbamide peroxide. Small peroxide concentrations and alkaline pH require longer bleaching time. Hydrogen peroxide 35% produces a faster bleaching effect.^{2,6-8}

The discoloration in this case is due to long-term consumption of tea, so the tea (chromogen) dyestuff is attached to the tooth surface. Saliva proteins are attached to the teeth through a calcium bond

forming a pellicle, then chromogen binds to the pellicle through a hydrogen bond. Continuous exposure to chromogen will make hydrogen bonds stronger, resulting in difficult stains to clean. Color changes caused by food and drink can be removed by scaling and polishing. If dye penetration from food or beverage has entered into email, then bleaching action is required.

In this case, in-office bleaching treatment using 40% hydrogen peroxide gel due to: (1) Shorter treatment time and immediate results, improve patient satisfaction and motivation. (2) The effectiveness of care and protection from ingestion of the material and the protection of soft tissue is maximal because it is under supervision and (3) The storage is easier due to the preparation of materials in one package, thereby reducing the risk of damage. The advantage of using this material is the easy application because of its consistency of the gel, making it easier for the operator to maintain the fixed material⁶⁻¹⁰ Tooth whitening may occur due to the strong oxidizing properties of hydrogen peroxide. The breakdown of hydrogen peroxide into free radical penetrating into tooth structure can occur through photo dissociation, anionic dissociation or a combination of both. The free radicals produced by hydrogen peroxide are perhydroxyl and active oxygen. These free radicals have unpaired electrons (electrophilic). These electrons will be released and the enamel will receive the electron and oxidize. Hydrogen peroxide will produce HO₂

(perhydroxil) which are strong free radicals and O as free radicals that are weak.¹¹ Hydrogen peroxide at the optimum pH of the base will promote the formation of HO₂ (Figure 9). Free radicals HO₂. in this large percentage will react with the enamel unsaturated bonds of the enamel, causing a disturbance to the electron conjugation and the change in energy absorption in the enamel organic molecules to form a simpler organic molecule with lighter color (Figure 10).¹²




Figure 9. The breakdown of hydrogen peroxide becomes free radical
(a) photo dissociation (b) anion dissociation¹¹

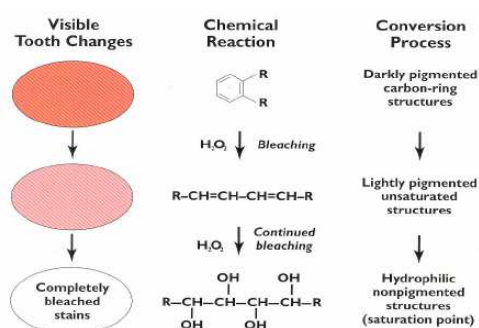


Figure 10. Bleaching mechanism¹²

In office bleaching technique using 40% hydrogen peroxide has a unique formula and is chemically activated so

it does not need to use light activation. Some researchers are still debating the use of light in bleaching procedures on vital teeth. The use of light and heating devices claimed to accelerate the working time of bleaching, controversy arose because according to other researchers the function of light as a heater or as a catalyst activator only. According to Ajaj, the bleaching in-office bleaching results with light and lasers did not prove to be better than chemical methods.¹³ Tredwin also stated that bleaching using hydrogen peroxide by light can cause the incidence of tooth sensitivity of 67 - 78%

Dental prophylaxis and polishing prior to bleaching using polishing sand is intended to clean the surface of teeth from deposits, stains and plaques. This is done because the bleaching material can react with many organic materials contained in the plaque, thereby reducing the effectiveness of bleaching materials.¹⁵ Topical flour is also performed before the bleaching procedure. Betke in Chen (2008) states that giving fluoride before bleaching procedures can reduce dehydration of dentine, because by maintaining dentin moisture will reduce hypersensitivity.¹⁶

Sensitivity is the most common side effect both during and after in-office bleaching treatment. The presence of sensitivity is associated with an increase in intrapulpal temperature, penetration of peroxide into the pulp through the dentin tubules, and dehydration process. Sensitivity is usually mild and temporary,

lasting for 24 hours. Patients reported sensitivity 2 hours after bleaching, for 3 minutes. Sensitivity is affected by the concentration of the material, the duration of exposure and the frequency application.¹⁵

The prevention of sensitivity after treatment was done with the application of Potassium Nitrate desensitizer (Ultra Ez) and the application of calcium phosphate cream. Potassium nitrate reduces the sensitivity effect by repolarization of the delta nerve so dentin decreases its sensitivity. The application of calcium-phosphate-amorphous (GC Tooth Mousse, GC Corp, Japan) cream containing casein phosphopeptide, amorphous calcium phosphate (CPP-ACP) can reduce tooth surface sensitivity by forming protective barrier against acid attack and increasing enamel structure mineralization.^{17,18}

The degree of discoloration of teeth obtained is one of the important factors determining the success of bleaching treatment. Clinical parameters that can be used as a benchmark for the success of bleaching treatment is when there is a 5-12 shade color change from the previous color that is arranged based on the value. The color changes that occur in this case from C3 to A2, which is a change of 9 shades. The long-term stability of the bleaching procedure is influenced by the etiology and early degree of discoloration, dietary factors, patient habits, and patient age. Tam et al.in Fearon (1999) conducted a study of 23 patients 1.5-3 years after external tooth whitening and reported that 72% of

them did not complain of discoloration or non-significant changes. Swift (1998) also stated that post-bleaching external color changes of as much as two shades.¹ Several ways that can be done to maintain the results of teeth whitening and minimize relapse that is using toothpaste containing bleach, mouthwash after consuming food, drinks that can cause stain. Touch ups can be done after 6 months, 1 or 2 years. If the patient smokes or has a habit of drinking coffee or tea on a regular basis, touch ups need to be more frequent.

CONCLUSION

Discoloration treatments using in-office bleaching techniques that are performed as indicated and appropriate work procedures provide satisfactory results. Teeth becomes whiter and brighter without any side effects.

REFERENCES

1. Fearon, Johny. Tooth whitening : concepts and controversies. International Dentistry. Vol 11 no.2
2. Rotstein Ilan. Tooth Discoloration and Bleaching. Dalam: torabinejad M, Walton R, Fuad AF, editor. Endodontics principles and practice. Edisi ke-5. Lois missouri: Elsevier; 2015. hlm. 428.
3. Alqahtani, Mohammed. Tooth bleaching procedures and their controversial effects:A literature review. The Saudi Dental Journal.2014.26, 33-46.

4. Mahrorta, V .et.al. Tell Tale Shades of Ciscolored Teeth- A Review. Indian Journal of Dental Sciences. June 2014.Issue 2 Vol 6.
5. Cynthia, Kasis. Extrinsic tooth discoloration, an update review. Dental Tribune Middle East and Africa Edition. March-April 2015.
6. Heymann HO. Additional Conservative Esthetic Procedures. In: Sturdevant's. Art and Science of Operative Dentistry. 5 th ed. St. Louis: Mosby Elsevier. 2006. p.638-46.
7. Sikri VK. Textbook of Operative Dentistry. 2 nd ed. Chennai: CBS.2010. p.558-74.
8. Rismanto DY, Dewayani I, Dharma RH. Dental Whitening. Jakarta: Dental Lintas Mediatama. 2005. p. 9, 33-44.12
9. Luk K, Tam L, Hubert M. Effect of Light Energy on Peroxide Tooth Bleaching. Jada 2004; 135: 194-201.
10. Roberto AR et ala Evaluation of Tooth Color After Bleaching With and Without Light-Activation. Rev Odonto Cienc 2011; 26 (3): 247-252.
11. Sulieman, M. An Overview of Bleaching Techniques: I. History, Chemistry, Safety and Legal Aspects. Dent Update 2004;31:608-616
12. Goldstein,ER & Garber AD. Complete Dental Bleaching. Quintessence Publishing co,inc.1995. p 26-32.
13. Ajaj,Reem et.al. Evidence based of the efficacy and effectiveness of light/laser activation in on- office dntal bleaching. Dent Hpotheses . 2012. VI3. 2(55-66).
14. Tredwin,C.J et.al. Hydrogen peroxide tooth whitening (bleaching products): Review of adverse effects and safety tissues.British Dental Journal. 2006.371-76.
15. Freedman. Contemporary Esthetic Dentistry. 2012. Elseveir, Mosby.
16. Chen, Hui-Ping et.al. Effect of fluoride containing bleaching agents on enamel surface properties.Journal of Dentistry 36 (2008)718-25.
17. Gilbert D, DaCosta B. Considerations for Enhancing Efficacy and Comfort with In-Office Tooth Whitening: A Case Report. Inside Dentistry 2006;2 (3).
18. American Dental Association. Tooth whitening Bleaching: Treatment Considerations for Dentist and Their Patients. ADA council on Scientific Affairs 2009. Available at <www.ada.orgisections/about/pdfs/HDD_whitening_rpt.pdf>. Accessed August 12, 2013.

LITERATURE REVIEW

POTENCY OF CHITOSAN NANO GEL AS DESENSITIZING AGENTS

Rina Oktavia* Trimurni Abidin**

** Resident of Specialist Program of Conservative Dentistry*

***Lecturer of Specialist of Conservative Dentistry*

Faculty of Dentistry, University of Sumatera Utara

Jln. Alumni No.2 Kampus USU Medan 20155

ABSTRACT

An understanding of the importance role of the tubules physiological characteristics is a structural linked asset to dentine fluid flow and its permeability. According to hydrodynamic theory, once dentine is exposed, external stimuli causes movement of tubular fluid, which in turn activates mechanoreceptor nerves, eliciting pain. Currently, widely used desensitizing agents to decrease dentin permeability by covering the tubules. Dentine desensitizers have been developed in various forms, for sealing the dentin tubules by forming tubule occlusion. Some researchers began to develop natural materials for tubular closure. The use of natural product in dentistry such as chitosan has increased widely. Chitosan is one of the natural material that it has various medical benefits and is proven safe for humans. The purpose of this article is to explain whether chitosan nanogel can be developed for the desensitization in reducing dentin permeability.

Keywords : dentine permeability, desensitizing agents, chitosan nanogel, tubule occlusion

INTRODUCTION

Under normal conditions, dentin is covered by enamel or cement. However, the exposure of dentinal tubules due to enamel loss by abrasion, erosion, abfraction, or root surface exposure caused by gingival recession, periodontal treatment, or a combination of both may produce strong dentin sensitivity.^{1,2,3,4,5}

The mechanism of dentinal pain is still not quite understood and the signs and symptoms of hypersensitivity are subjective and non-specific. Previous studies have shown that hypersensitive

areas may present exposed dentinal tubules. Many theories have been introduced to characterize dentin hypersensitivity. Nevertheless, the hydro dynamic theory proposed by Brannstrom is the most widely accepted.⁶ The hydrodynamic theory assumes that a stimulus applied on the dentin surface causes movement of tubular fluid, which in turn activates mechanoreceptor nerves, eliciting pain and discomfort.^{2,5,7,8,9}

Sometimes, dentin desensitization may occur spontaneously as a natural decrease of dentin permeability. In most cases, however, treatment is still

necessary. Thus, a reasonable and logical treatment approach for hypersensitivity should occlude/sealing of peripheral dentinal tubules to reduce the hydraulic conductance of the dentin. This concept is widely used to treat DH with an array of different types of desensitizing agents.^{6,7,10} An ideal desensitizing agent should not irritate or endanger the integrity of the pulp, should be painless immediately upon application and thereafter, be easy to apply, display rapid effect, be long-lasting or permanent and should not damage the teeth or gums, such as by discoloration. Many treatments have been devised according to these criteria, but no gold standard has been established.¹¹

In responding to dentin hypersensitivity many ways have been done on therapies such as the use of toothpaste containing fluoride, strontium chloride, sodium nitrate, the use of varnish, or laser. Several agents have been proposed for the treatment of the hypersensitivity, but none of them has been proven completely efficient for such use, and the development of new desensitizing agents is needed.¹²

Some researchers began to develop natural materials. One of the natural ingredients that is currently being developed as a treatment is chitosan. According to Ponti et al. (2015) research, high molecular chitosan dentifrice nanoparticles show dense closure patterns of dentinal tubules due to the size of particles present in chitosan so that the amine group (NH_2) in chitosan can bind the silica elements

present in the toothpaste so that molecular deliveries occurring on the dentin tubule network are more optimal so that able to cover the pattern of the dentinal tubules.¹³

Looking at the above descriptions arises as to whether chitosan nanogel can be developed as a desensitizing material to decrease dentin permeability.

Morphology and dentine physiology

Dentine forms the bulk of the tooth and is perforated by tubules that extend from the pulp to the enamel-dentine or cement-dentine junction. Dentine is a permeable mineralised tissue, which often becomes exposed by disease or restorative procedures. Interest in the permeability of dentine arises partly from the hydrodynamic hypothesis of dentine sensitivity. This hypothesis states that fluid movement occurs within the tubules when dentine is stimulated. The movement is thought to be rapid enough to stimulate nerve endings of receptor A delta.¹⁴

The density and diameter of the dentinal tubules increases with dentine depth from the EDJ (Enamel dentine junction) to the pulp region. The permeability of dentine is lowest at the EDJ and highest at the pulpal ends. The permeability of dentine has been said to be related to the functional diameter of the dentinal tubules; the greater the functional diameter, the higher the flow rate and thus the rate of permeation.¹⁴ The number of tubules per area next to the pulpal surface in comparison to the outer areas is of 4:1.

So, the superficial dentin is less permeable than the deep dentin. The diameter of the tubules in the deep dentin region is 3 to 4 mm and in peripheral dentin is 1 mm.¹

The permeability increases (hydraulic conductivity increases) rapidly as the pulp chamber is approached as per meability of dentine is proportional to the product of tubule numbers and diameter both of which increase as the tubules converge on the pulp. Thus the lower permeability of central dentine compared with that over the pulp horn might be due to fewer tubules per unit of the cross sectional area and that central tubules may have smaller diameters because they are further away from the pulp.¹⁴

Factors that may reduce the permeability of dentine : a) normal appositional growth of intratubular dentine, b) deposition of calcium phosphate crystals e.g. whitlockite in the tubules in the translucent zone ahead of the demineralised areas of caries, sometimes referred to as caries crystals, c) the coagulation of plasma proteins (fibrin) from pulpal blood vessels in the tubules beneath a recently cut cavity, d) pathological precipitation of intratubular materials i.e. mineral deposits, collagen fibrils, proteoglycan linings and bacteria, e) the formation of a smear layer of dentine debris on its cut surface during cavity preparation. All these factors can contribute to intratubular occlusion that reduces permeability.¹⁴

Dentinal Hypersensitivity

Dentinal hypersensitivity is defined as an exaggerated response to a stimulus that usually causes no response in a healthy tooth, and also, an exaggerated response to a nonharmful stimulus. The nonharmful stimuli are the thermal, tactile or osmotic stimuli that when applied on the exposed dentin, evoke pain without causing pathologic alterations to the dentin-pulpal complex.¹

Dentine hypersensitivity (DH) has been defined as a short, sharp pain arising from exposed dentin in response to stimuli, typically thermal, evaporative, tactile, osmotic or chemical, which cannot be ascribed to any other form of dental pathology. Several reviews have been published on the etiology of DH. Chronic trauma from toothbrushing, acidic erosion from the environment, gastric regurgitation or dietary substances, anatomical factors, gingival recession caused by periodontitis or periodontal surgery are some of the etiological factors that have been implicated. The most accepted theory to explain DH was the hydrodynamic theory by Brannstrom, even though several hypotheses have been put forward to date. This theory claimed that stimulus to an exposed dentin surface increased fluid flow in the tubules, and this increased flow caused pressure changes across the dentin, which activated the pulp-dentin border within the dentin tubules.^{1,4,10}

Dentinal Hypersensitivity Treatment

There are different kinds of dentinal hypersensitivity treatment available, nevertheless, the ideal desensitizer agent, according to Grossman (1935), should be nonirritating to the pulp, be relatively painless, be easily applied, act quickly, be permanently effective and not discolor tooth structure. Such material will offer the intriguing prospect of strengthening dentin and rendering it less susceptible to predisposing factors, while concurrently reducing DH.^{1,15} Basically, two treatment options for DH can be designed. One is to seal and occlude the dentin tubules, thereby blocking the hydrodynamic mechanism; the other is to block neural transmission at the pulp level.^{3,4}

Effective dentin occlusion should provide the greatest clinical prospect for long-lasting relief of DH. Ideally, the desensitizing material by occluding the tubules should not only be able to coat the exposed dentin surfaces, but also be able to penetrate into the open tubules and form acid resistance plugs to seal these tubules.³

Desensitizing Agents Utilized in the Office

Calcium Hydroxide

The real calcium hydroxide action mechanism is unknown, but it is suggested that it may block dentinal tubules or promote peritubular dentin formation. It is believed that the high pH provokes the odontoblastic process protein coagulation,

leading to a closure of the tubules through precipitation of these proteins, decreasing the hydraulic conductance.^{1,15}

Fluoride Compounds

When in contact with the mineralized tooth structures, fluoride ions are claimed to cause a reduction in diameter of the dentinal tubules by precipitating CaF_2 crystals. The speculated mode of action is the formation of a calcified barrier blocking the tubule openings. Since calcium fluoride is an unstable compound, it provides a short period of desensitizing effect. This indicates the necessity of several applications to reduce the pain. Among the most used fluoride compounds are the 5% sodium fluoride varnish (Duraphat, Colgate-Palmolive Company), 2% neutral sodium fluoride and 1.23% acidulated fluoride phosphate gel. Fluoride compounds, such as amine fluoride, stannous fluoride and titanium tetrafluoride have also been employed in order to reduce dentinal sensitivity.^{1,5}

Strontium Chloride

Strontium ions penetrate dentin deeply and replace calcium, resulting in recrystallization in the form of a strontium apatite complex. Some strontium chloride-based formulations are found in the market as varnishes or dentifrices. Ross (1961) and Kishore et al. (2002) treated patients with 10% strontium chloride and observed that these desensitizing agents significantly reduced dentin hypersensitivity. However,

Zappa (1994) do not support the effectiveness of 10% strontium chloride hexahydrate toothpaste in relieving the pain of tooth hypersensitivity and in comparison with other agents, the efficacy of strontium chloride is uncertain.^{1,5}

Oxalate Desensitizers

Oxalate ions react with calcium to form insoluble calcium oxalate crystals that occlude the dentinal tubules, decreasing dentin permeability. Although oxalates appear to be one of the best topical treatment for blocking tubules, they have the same drawback as all topic treatments, as the eventual dissolution of the surface precipitate that forms the barrier by saliva.^{1,2,3}

Application of a Waterproof Film and Restorative Procedures

These desensitizing agents have a blocking action mechanism through the sealing of exposed dentinal tubules, decreasing dentin permeability and hydraulic conductance.

- **Varnishes** : Varnishes promote a waterproof film formation. The most common are the copal varnishes and varnishes with desensitizing agents like strontium chloride and sodium fluoride.^{1,2,4}

- **Adhesive systems** : The adhesive systems are indicated for dentine hypersensitivity treatment, since they have hydrophilic primers, allowing an efficient dentin bonding. The use of HEMA as a hydrophilic primer is common in many modern

dentin bonding systems. The Gluma Desensitizer (Heraeus Kulzer, GMBH) is an aqueous solution of 35% HEMA and 5% glutaraldehyde. Glutaraldehyde is an effective fixative of flocculating agent and have the capacity to form a coagulation 'plug' within the dentinal tubules. Some products replace the glutaraldehyde with benzalkonium chloride and include a small concentration of fluoride in the formulation. Benzalkonium chloride is a disinfectant. The main benefit of the nonglutaraldehyde agents is that they are kinder to the tissue. Glutaraldehyde eventually causes a transient tissue burn and allergies and must be carefully used. The new trend of treatment of the dentinal hypersensitivity is the use of the self-etching adhesive systems. According to Turkun (2003), treating the enamel and dentin with self-etching adhesive systems instead of employing a conventional total-etch procedure prevent the collapse of collagen network. Additionally, the self-etching primers need no etching, rinsing and drying, so that the risk of over-etching and over-drying of the dentin is eliminated. They are simple to apply in clinical situations, and reduce the technique sensitivity of the bonding procedure.^{1,2,4}

- **Restorative procedures** : These procedures commonly use composite resins and glass ionomer cements. They are usually applied when esthetic and functional reestablishment of deeper lesions are necessary, besides the dentinal hypersensitivity control.^{1,2,4}

Laser Light

- **Nd:YAG laser** : Previous scanning electron microscopic studies showed that Nd:YAG laser could cause melting of dentin and closure of exposed dentinal tubules without dentin surface cracking resulting in a reduction of permeability and hydraulic conductance. Hsu et al. (2006) evaluate the combined occluding effects of fluoride-containing dentin desensitizer and Nd:YAG laser irradiation on human dentinal tubules, and observed that the occluding agent was thus 'burned into' the dentinal tubules, reducing the hypersensitivity and increasing the duration of the desensitizing effect.^{1,2,15}

- **CO₂** : CO₂ applications rely on the ability to close the dentinal. Slutzky-Goldberg et al. (2008) tested CO₂ laser energy as a possible alternative treatment for prevention of dentin hypersensitivity in restorative dentistry.^{1,2,15}

Home-made Desensitizing Agents for Self-applied

Dentifrices

Long used to treat dentinal hypersensitivity, dentifrices are cost-effective, noninvasive, simple to use and can be applied at home. Dentifrices with formulations containing potassium salts (e.g. chloride, nitrate, citrate, oxalate) and the others with fluoride are the most used home-made agents.^{1,5}

Arginine is an amino acid naturally found in saliva composition. Recent

research suggests that the arginine and calcium carbonate present in the formula of a toothpaste provides significantly increased dentin hypersensitivity relief. Arginine has the characteristic of presenting its molecule, at physiological pH, positively charged. The desensitizing mechanism of action is due its molecule connect to the dentin surface, negatively charged, occluding the dentinal tubules.^{1,5}

The use of natural materials as desensitizing agent

Chitosan

Chitosan is the deacetylated derivative of chitin, which is chemically defined as a copolymer of α -(1,4) glucosamine ($C_6H_{11}O_4N$)_n, having different number of N-acetyl groups (Zvezdova 2010). It is white to light red solid powder, insoluble in water but soluble in organic acids (figure 1). Chitosan is a polysaccharide extracted from the shells of crustaceans, such as shrimp, crab and other sea crustaceans, including *Pandalus borealis* and cell walls of fungi.^{16,17,18}

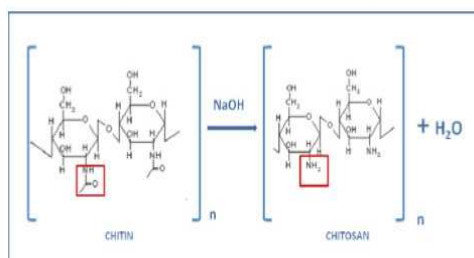


Fig. 1 Schematic representation for the conversion of chitin into chitosan

Derivatives from chitosan can be achieved through modification reactions like deacetylation, N-acetylation, acylation, O-acetylation, O-e N-ftalation, O-carboxymethylation, oxidation among others, to prepare several formulations (products), as tablets, micro-nanoparticles, microspheres, granules, liposomes, films, polymeric membranes, gels and hydrogels, with specific features for certain applications. However, due the strong intermolecular interactions and because it is a semi-crystalline structure, chitosan is less accessible to chemical reagents when compared to celluloses.¹⁸

Chitosan and its derivatives have excellent biocompatibility, non-toxicity to human beings, biodegradability, reactivity of the deacetylated amino groups, selective permeability, polyelectrolyte action, antimicrobial activity, ability to form gel, film and sponge, absorptive capacity, anti-inflammatory and wound healing. One of the most important properties of chitosan is high bioactivity, that makes this material very interesting to develop new biomaterials for application in dentistry.^{17,18,19}

Chitosan possesses positive ionic charges, which give it the ability to chemically bind with negatively charged fats, lipids, cholesterol, metal ions, proteins, and macromolecules (Li et al., 1992). In this respect, chitin and chitosan have attained increasing commercial interest as suitable resource materials due to their excellent properties including biocompatibility, biodegradability, adsorption, and ability to

form films, and to chelate metal ions (Rout, 2001).¹⁸

Applications of the chitosan as desensitizing agent

Chitosan in Dentifrices

Dentifrices are agents used along with a toothbrush to cleanse and polish natural teeth. Dentifrices should have maximum cleansing efficiency with minimum tooth abrasion. Dentifrices perform three important functions such as: 1. They assist the toothbrush to mechanically remove stains, debris, plaque and stained pellicle from the teeth. 2. They polish teeth to provide increased light reflectance and superior esthetic appearance. 3. They act as vehicles for the delivery of therapeutic agents that provide known benefits. Therapeutic agents include fluorides, tartar control agents, desensitizing agents, peroxides, and bicarbonates.¹⁹

Mohire et al. (2010) developed chitosan based polyherbal toothpastes with enhanced performance in oral care as chitosan inhibits the growth of *Streptococcus mutans* and *Porphyromonas gingivalis*; microorganisms responsible for caries and gingivitis, respectively. Chitosan based polyherbal tooth pastes proved to be a promising to be a potential oral hygiene product, which inhibited the growth of microorganisms responsible for caries and gingivitis and also potentiates the effectiveness of active ingredients of toothpaste for antimicrobial and anti-inflammatory activities.¹⁹

Ponti et al. (2015) developed high molecular chitosan nanoparticles added to toothpaste has the ability to close the dentinal tubules (in vitro). The SEM results show a close dentine tubular pattern with homogeneous crystallization, fine, with joining crystals such as a film layer continuous to the upper cross section and a smear plug present on the sagittal section and no visible crystalline crystallization.¹³

Enamel de-remineralization

Enamel demineralization is a major step for initiation of dental caries. The prevention of acid attack in the oral cavity is the most effective method in treating demineralization of teeth. Various treatment modalities and preventive methods have been explored to protect the tooth enamel from acid attack.¹⁵

Arnaud et al. (2010) used two demineralizing solutions and remineralizing solutions and found that enamel protected with acid soluble chitosan showed a higher surface microhardness with Vickers test than enamel which were not treated with any chitosan.¹⁵ Fitri et al. (2014) using a combination CPP-ACP gel and chitosan nanoparticles have the ability to improve the remineralization of tooth enamel.¹³

DISCUSSION

The patency and the number of dentinal tubules have direct effect on the permeability of dentin. The functional and anatomical occlusion of tubules reduces the flow of dentinal fluid. Consequently,

any substance that leads to a decrease in dentinal conductance (i.e. dentinal permeability) by reducing the diameter or closing the tubules and diminishing their number is able to reduce dentinal hypersensitivity and pain (Pashley; 1986, Sauro et al.; 2006).⁸

The treatments for dental sensitivity are varied. They can be more radicals such as restorations of sensitive teeth, until more conservative ones, like laser therapy, or professional desensitizing products. Numerous desensitizing agents have been clinically tested over several decades in an effort to alleviate DH. Several criteria are recognized as constituting an ideal desensitizing agent. These include not irritating the pulp, being relatively painless to apply, easily applied, rapid action, permanently effective and should not discolor the teeth.^{2,14}

Application of chitosan in dentistry is the subject of research for decades. Due to its characteristics of biodegradability, biocompatibility, hydrophilicity, antibacterial properties, bioactivity and to be processed in different forms (solutions, blends, sponges, membranes, gels, pastes, tablets, microspheres and micro granules, among others) chitosan is widely used. Also because it comes from natural and renewable resources.¹⁹

Chitosan is a fiber-like substance and a homopolymer of β -(1 \rightarrow 4)-linked N-acetyl-D-glucosamine. Chitin is made up of a linear chain of acetylglucosamine groups while chitosan is obtained by removing

enough acetyl groups (CH₃-CO) for the molecule to be soluble in most diluted acids. The actual difference between chitin and chitosan is the acetyl content of the polymer. Chitosan having a free amino group is the most useful derivative of chitin (No and Meyers, 1992).¹⁹

Nanoparticles are defined as particulate dispersions or solid particles with a size in the range of 1–1000 nm. Methods, such as the emulsion method, ionic gelation method (Ohya et al., 1994; Yokohama et al., 1998; Kataoka et al., 2000), reverse micellar method, self-assembling method (Liu et al., 2005; Chen et al., 2003), etc., have been used to prepare chitosan nanoparticles. The ionic gelation method and reverse micellar method are mainly considered. Chitosan nanoparticles in gel form have potential for the development of desensitization material.¹⁶

CONCLUSION

Based on the above discussion, it was possible to conclude that all the desensitizing agents were capable of reducing dentin hypersensitivity. The chitosan gel can be developed as a desensitizing agent in decreasing dentin permeability.

REFERENCES

1. Borges AB et al. Dentin Hypersensitivity—Etiology, Treatment Possibilities and Other Related Factors: A Literature Review. *World Journal of Dentistry* 2012; 3(1): 60-67.
2. Da Rosa WLO, Lund RG, Piva E, Da Silva AF. The effectiveness of current dentin desensitizing agents used to treat dental hypersensitivity: A systematic review. *Quintessence Int* 2013: 1-12.
3. Gu H, Zhou X, Ling J, Liu L, Zhao Z, et al. Comparative Efficacy of Experimental Solutions in Occluding Dentin Tubules: Calcium Phosphate Based and Oxalate-Based Solutions. *Dentistry* 2017; 7(2): 1-7.
4. Panir T, Dalgat H, Onal B. Clinical Evaluation of Three Desensitizing Agents in Relieving Dentin Hypersensitivity. *Operative Dentistry* 2007; 32(6): 544-548.
5. Rosing CK, Fiorini T, Liberman DN, Cavagni J. Dentine hypersensitivity: analysis of self-care products. *Braz Oral Res* 2009; 23(1): 56-63.
6. Pereira JC, Martineli ACBF, Santiago SL. Treating hypersensitive dentin with three different potassium oxalatebased gel formulations: a clinical study. *Rev. FOB* 2001; 9(3/4):123-130.
7. Arrais CAG, Chan DCN, Giannini M. Effects of desensitizing agents on

- dentinal tubule occlusion. *J Appl Oral Sci.* 2004; 12(2): 144-148.
8. Niazy MA, Jamil WE. The role of adhesive systems and dentin desensitizers in altering the permeability of human dentin. *Cairo Dental Journal* 2009; 25(3): 433-442.
 9. Nugrohowati. Iontophoresis untuk penanganan noninvasif dentin hipersensitif. *Indonesian Journal of Dentistry. Edisi Khusus KPPIKG XIV* 2006: 221-223.
 10. Hiroshi Ishihata H, et al. Effect of two desensitizing agents on dentin permeability in vitro. *J Appl Oral Sci.* 2017; 25(1): 34-41.
 11. Sadiasa A, Franco RA, Seo HS, Lee BT. Hydroxyapatite delivery to dentine tubules using carboxymethyl cellulose dental hydrogel for treatment of dentine hypersensitivity. *J. Biomedical Science and Engineering* 2013; 6: 987-995.
 12. Sales-Peres SHC, et al. Effect of propolis gel on the in vitro reduction of dentin permeability. *J Appl Oral Sci.* 2011; 19(4): 318-23.
 13. Batubara FY, Abidin T, Agusnar H. Effect of adding nanoparticle chitosan to casein phosphopeptid amorphous calcium phosphate (CPP-ACP) on tooth remineralization 2014; 18(1): 16-20.
 14. Ghazali FC. Permeability of dentine. *Malaysian Journal of Medical Sciences* 2003; 10(1): 27-36.
 15. Bartold PM. Dentinal hypersensitivity: A review. *Australian Dental Journal* 2006; 51(3): 212-218.
 16. Venghat S, Hegde MN. Application of chitosan in dental health sciences: A review *World Journal of Pharmaceutical Research* 2016; 5(5): 600-615.
 17. Tanikonda R, Ravi RK, Kantheti S, Divella S. Chitosan: Applications in Dentistry. *Trends Biomater. Artif. Organs* 2014; 28(2): 74-78.
 18. Hossain MS and Iqbal A. Production and characterization of chitosan from shrimp waste. *J. Bangladesh Agril. Univ.* 2014; 12(1): 153–160.
 19. Zhao LM, et al. Preparation and application of chitosan nanoparticles and nanofibers. *Brazilian Journal of Chemical Engineering* 2011; 28(3): 353-362.
 20. Kmiec M, Pighinelli L, Tedesco MF, Silva MM, and eis V. Chitosan – properties and applications in dentistry. *Advances in tissue engineering and regenerative medicine* 2017; 2(4): 1-7.

CONVENTIONAL ENDODONTIC RETREATMENT OF MANDIBULAR FIRST MOLAR WITH UNDERFILLING

(A CASE REPORT)

Riza Permitasari*

Kamizar**

*¹Resident, Department of Conservative Dentistry, Faculty of Dentistry,
Universitas Indonesia*

*² Lecturer, Department of Conservative Dentistry, Faculty of Dentistry,
Universitas Indonesia*

E-mail address: noe.avanti@gmail.com

ABSTRACT

Underfilling is one of the etiology factors of root canal failure. Less 1 mm of working length increase the probability of endodontic failure 14% in teeth with periodontitis.¹ Underfilling leaves an empty space in the root canal system resulting in the rest of the microorganisms to survive and multiply. When gaining access to periradicular tissues, these microorganisms can initiate or maintain periradicular inflammatory processes. If the foramen is not sealed properly, tissue fluid can provide nutrients to intracanal bacteria.² Case report will discuss conventional endodontic retreatment management of male patients aged 25 years with diagnosis chronic apical abscess in first mandibular molar et causa endodontic failure with underfilling. The procedure of the endodontics retreatment follows the triad endodontic rules. Combinations of adequate instrumentation with the addition of actual working length, use of 2.5% NaOCl irrigant, 17% EDTA and CHX 20% with ultrasonic vibration activation and saline rinse among irrigants, calcium hydroxide medicaments and AH Plus sealer with adequate obturation can be optimal in killing *E. faecalis* cause failure of root canal treatment. As the first control is conducted a week after the obturation, there are no subjective and objective complains found. The conditions are clinically well and restoration is conducted with fiber post and metal porcelain crown. In the second control after 1 month post-obturation, radiolucency in the periapex decreased. It is recommended to observe by the European Society of Endodontics, for 1-4 years to determine the success of treatment.

Keywords: Endodontic Failure, Underfilling, CHX 20%

* Graduate Student in Specialist Endodontics, Faculty of Dentistry, University of Indonesia, 2016.

** Lecturer in Department of Conservation and Endodontics, Faculty of Dentistry, University of Indonesia.

INTRODUCTION

The success of endodontics treatment is to eliminate bacteria from the root canal system as much as possible. If this is not achieved, persistent bacterial infections of the root canal can initiate periradicular inflammation after endodontic treatment.¹ According to the European Society of Endodontics, endodontic treatment called failure after root canal treatment, there are still persistent symptoms, pain, swelling, sensitive to percussion and palpation, mobility, periapical area unchanged or enlarged, and presence of new periapical or lateral radiolucencies of the region. Endodontic post-treatment teeth should be evaluated radiographically after 1 year to 4 years to determine treatment success.²

The main cause of root canal failure is due to microbes. There are three factors that cause failure, namely preoperative, during treatment, and post-treatment. Preoperative failures are caused by misdiagnosis, endo-perio lesion, trauma, and systemic. While the cause of failure during treatment are non-aseptic treatment procedures, inadequate irrigation materials, under preparations that cause underfilling obturation, missed canals, ledges, resistant bacteria, and failure obstruction of the root canal, and corona restoration failure.^{3,4,5,6} While the causes of post-treatment failure include corona restoration failure, persistent / reintroduced periradicular microorganisms, extraradicular infections, body reactions to foreign bodies, cysts, and fracture teeth.^{3,7}

There have been many clinical studies stating that underfilling teeth are often associated with periapical radiolucency. If the quality of obturation is not good, it can be said that the root canal system has not been through cleaning and shaping well.⁸

Underfilling is the obturation of root canals that incomplete or distant (≥ 2 mm) from the apex on radiograph. This occurs due to incomplete instrumentation through the working length or the formation of ledge on the root canal during mechanical instrumentation.¹ Under instrumentation results in cleaning and shaping not optimal, generally due to inaccurate measurement of working length, and the use of inappropriate size, taper and flexibility of instruments.⁹

Underfilling leaves the empty space inside the root canal system resulting in remaining microorganisms to survive and multiply. When gaining access to periradicular tissues, these microorganisms can initiate or maintain periradicular inflammatory processes. If the foramen is not closed properly, tissue fluid can provide nutrients to intracanal bacteria. *E.faecalis* is in a high frequency in the oral cavity of patients who have received failure root canal treatment. *E.faecalis* is associated with the onset of periradicular disease, primary endodontic infection and persistent infection. In the case of root canal failure, *E.faecalis* bacteria are 9 times higher in frequency than in primary endodontic infections. In a study by Sundqvist et al, *E. Faecalis* was isolated in 38% of failures. In addition to *E.faecalis*, fungal-like

microorganisms have also been isolated from teeth with failed root canal treatment, suggesting that these microorganisms are resistant to endodontic treatment.⁹

Several studies with radiographic observations concluded poor prognosis of teeth with underfilling. In the case of pulp necrosis and periradicular lesions, with obturation at 1 mm from apical foramen on radiograph having 94% success, 76% on overfilling while in the case of underfilling, success was only 68%. According to Chugal et al, 1 mm deficiency of working length increases the likelihood of treatment failure to reach 14% in teeth with periodontitis. According to Davis et al the underfilled root canal becomes filled with connective tissue and connected with the periodontium after 1 year of endodontic treatment.¹

Conventional endodontic retreatment is indicated when: (1) Conventional endodontic fails, (2) There are signs of inflammation or infection associated with the filled tooth, (3) There are persistent symptoms of a filled tooth, or existence of sinus tract, swelling or pain, (4) Root filling failure or technical risk, (5) Teeth can still be restored, (6) Teeth have periapical radiolucency and require new restoration, and (7) Previous root filling deficiencies and new restorations are required.²

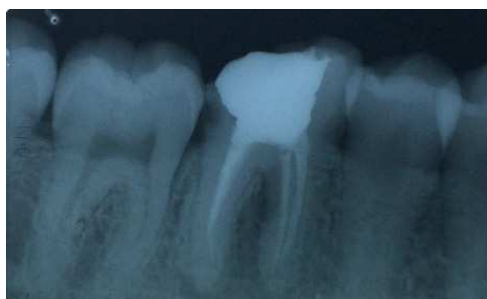This case report will discuss the management of conventional endodontic retreatment of mandibular molar root canal with underfilling. The purpose of writing this case report is to increase the

knowledge of dentist on performing the conventional endodontic retreatment by combining adequate instrumentation, the proper use of irrigation materials, medicaments, and sealers to optimally kill *E. Faecalis* during endodontic retreatment at cases of endodontic failure.

CASE

A 25-year-old male patient came with complaint of right lower posterior tooth pain when used to eat and often emerge swelling on his gums that intermittentsince 2 months ago. The tooth had previously been treated with root canal and was restored with amalgam about 5 years ago. Patients want these teeth to be treated so that they can be used again to eat.

On the objective examination, no extraoral abnormalities found. In intraoral, calculus found in region 3, 4; with Oral Hygiene Index 1. At dental examination, 46 post-endodontic treatment with amalgam restoration in occlusal found. Thermal test: (-), Percussion: (+), Palpation: (-), Gingiva: swollen. On radiographic examination there is restoration to the pulp chamber. There is underfilling on distal root canal 4 mm from the apical foramen and 3 mm in the mesio buccal and mesio lingual canal and radiolucency with ± 1 mm diameter at distal roots with irregular border.



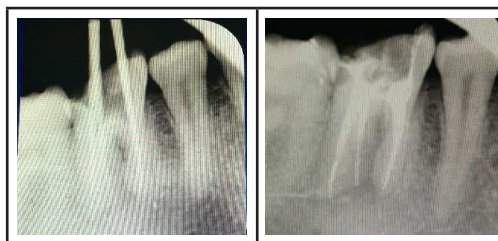
The diagnosis of right mandibular first molar in this case is chronic apical abscess caused by endodontic failure. The treatment plan in this case is a conventional endodontic retreatment with fiber post restoration and porcelain metal crown.

CASE MANAGEMENT

On the first visit, conventional endodontic retreatment were performed. First removal of the amalgam restoration and access preparation and removal of previous root canal material. The removal of root canal material is carried out with the help of solvent as eucalyptol oil placed in the pulp chamber until gutta percha softened and using Hedstrom (Dentsply Maillefer, Switzerland) instrument to remove the percha gutta from the root canal until clean. After the removal of the gutta percha is completed, a radiographic photograph is taken to ensure that no gutta percha remains in the root canal. At the end of the first visit, the appropriate working length has not been obtained yet. Then it was irrigated using 2.5% NaOCl, saline, EDTA 17%, saline and CHX 2% and activated using endoactivator. The root canal is dried using a paper point, and the teeth are given CHKM medicaments

and then covered with cavif, a temporary restoration.

At the second visit, it is continued by measuring the working length, working length of MB #20/24mm, ML #20/24mm, DB #20/23mm, DL #20/23mm obtained using radiographic images. Afterwards the teeth root canal prepared by using a crown down system using ProTaper For Hand Use (Dentsply Maillefer, Switzerland) to F3 with a chelator agent (RC-Prep) (Premier® Dental Products Company) 15% throughout the working length. Each replacement of the preparation tool was irrigated using NaOCl 2.5%, saline, EDTA 17%. Next, evaluate with periapical radiograph to see the gutaperchamaster cone. Then, it was irrigated using 2.5% NaOCl, saline, EDTA, saline and CHX 2% succesively and was activated using endoactivator. The root canal is dried using a paper point, and the tooth is given a calcium hydroxide medicament, then covered with a temporary cavif restoration.

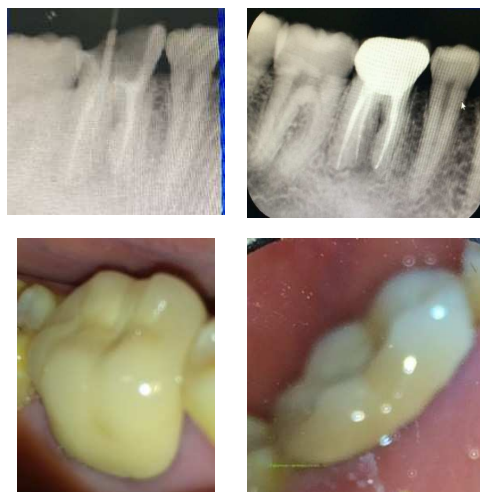

On the third visit, no abnormalities were found on either subjective or objective examination, no patient complaints and the teeth were insensitive to percussion and palpation. Temporary restoration was removed, then irrigated with 2.5% NaOCl, saline, final irrigation with CHX 2% and

activated using endoactivator, then dried with paper point. After the root canal dry, obturation was done with AH Plus sealer and master con guttapercha F3. Then dental radiograph was taken for obturation evaluation. From the radiographic image it appears that obturation reach the working length (1 mm from the apical foramen). After that, GIC (Glass Ionomer Cement) applied as base and temporary restoration with cavit.

On the fourth visit, obturation evaluation by subjective and objective examination, there were no toothache found, insensitive to percussion and palpation. Then temporary restoration and GIC base is removed and root canal preparation is done for fiber post placement. Then, followed by measuring the working length, working length of 16 mm obtained and from radiograph seen the post's diameter to be used is 1.5 mm. gutta percha removal and root canal preparation were done using Gates-Glidden Drill no. 6 followed by Fiber Clear Drill throughout the post working length to smooth the cannal wall. Then, fiber post try in into the root canal, then radiographic taken to determine the adaptation of post in the root canal. Before cemented into the root canal, root canal etched and rinsed, then bonding applied. The same thing also applied to the fiber post, etched with hydrofluoric acid 9.5% then rinsed and silane applied before cemented. cementation done by using Breeze (Pentron) dual cure resin cement, mix between base and catalyst. After that

the post is placed into the root canal for 1-1.5 minutes from the initial mixing. Light curing done at restoration margin for 1 minute for the cement to set and easy to clean. Excessive cement was disposed using sonde. The resin cement will be perfectly set within 1.5-4 minutes. After completion of cementation, the core is made by using Composite Resin. Then crown preparation is done by using rotary instrument with irrigation, the preparation should leave 2 mm ferrule and all the margins are placed at healthy tooth structure. Impression was made using heavy body and light body (Exaflex), then bite note were made and sent to dental lab for metal porcelain crown manufacture.



DISCUSSION

The diagnosis of right mandibular first molar in this case is chronic apical abscess caused by endodontic failure. Failure is characterized by complaints from patient of the pain on the tooth during eating, recurrent swelling of gingiva,

sensitivity on percussion and radiographic features of radiolucent image in periapical. The signs of failure are in accordance with the guidelines of The European Society of Endodontics, it is considered a failure if symptoms persist, swelling recurrence, sinus tract, pain, percussion (+), palpation (-), mobility and abnormal function, periapical area size unchanged or enlarged, presence of new periapical or lateral radiolucency areas. So, the root canal treatment is needed.²

In this case conventional endodontic retreatment are performed, as indications, such as: (1) Conventional endodontic fails, (2) There are signs of inflammation or infection associated with filled teeth, (3) Persistent symptoms of the filled teeth, or the presence of sinus tract, swelling or pain, (4) Failure of root canal obturation or technical risk, (5) There is a systemic risk if no intervention, (6) Teeth can still be restored, (7) tooth has periapical radiolucency (8) previous root filling deficiency and new restoration required, and (9) Patients wish to be retreated.²

In removing gutta percha there are three things to note, namely the quality of condensation, root canal form and obturation length. Straight root canal and under obturation make it easy to remove gutta percha manually. In this case, to remove gutta percha mechanically used Hedstrom file. In accordance with the results of study, Hedstrom significantly produced less residual obturation material than the rotary NiTi instruments, and there

was no significant difference between the two techniques for the removal of dentine tissue. In other studies, obturation materials cannot be completely removed during root canal retreatment, using either manual files or rotary files and that gutta percha is more effectively removed using manual files.¹⁰

Although some studies suggest that rotary instruments more rapidly remove obturation materials than manual instruments, but their usage should be careful as more dentin erodes, which may lead to weak roots and risk of root fracture or perforation.¹¹ The removal of gutta percha is done by using a Hedstrom file by engaging gutta percha with Hedstrom File, so that when drawn, guttapercha will come out along with the file. In addition, several other advantages of Hedstrom is that the tactical sensation is more easily obtained because it is a manual instrument, has spiral edge that gives the screw effect, has a positive rake angle so its effective to cut, easy to use and cheap.¹²

To facilitate the removal of the obturation material assisted by solvent in this case, eucalyptol oil is used to soften the root canal filler material. Based on the research, there is no significant difference between the solvent of the obturation material ie chloroform, citrus oil and eucalyptol in its effectiveness to clean the dentin tubule from obturation material. While chloroform, halothane, and turpentine oil are reported to have cytotoxic and carcinogenic properties.^{13,14} In addition, chloroform, xylene and

halothane have been shown to significantly weaken enamel and dentin.¹⁵

After removal of gutta percha, it is continued by calculating the working length by using radiographic photograph. The periapical radiographs proved to be accurate in measuring the length of root canals.¹⁶

Root canal preparation was done by crown down technique with protaper hand use instrument. The crown down technique is used by performing the preparation of the corona section, followed by the apical. The advantage of this technique is the removal of coronal tissue debris, which minimizes debris extrusion to the apical, reduces post-treatment pain that can occur due to apical extrusion of debris, increases penetration of irrigation materials resulting in better cleaning, smear removal is easier because it can contact preferably with root canal walls.¹⁷ Protaper hand use has advantages such as having a triangular cross-sectional design, resulting in increased efficiency on dentin removal, no screw effect to dentin, better tactile control thus maintaining the original form of the root canal with minimal risk of root canal transportation.¹⁸

Irrigation was performed with 2.5% sodium hypochlorite solution. This solution has antimicrobial activity and can dissolve organic tissue. Sodium hypochlorite acts as organic solvent and fat, degrades fatty acids and transforms them into fatty acid salts (soap) and glycerol (alcohols) which can reduce the surface tension of the residual solution. Sodium hypochlorite neutralizes

amino acids, forming water and salt. hydroxyl ions emerge will cause a decrease in pH. Hypochlorous acid, the substance contained in sodium hypochlorite solution, when in contact with organic tissue acts as a solvent and releases chlorine, which combines with amino group proteins to form chloramines. Chloramine reactions can interfere with cell metabolism. Chlorine has antimicrobial action, disrupts bacterial enzymes and causes irreversible oxidation of sulfidryl groups of important bacterial enzymes.¹⁹

In this case 2.5% sodium hypochlorite solution is used because it has antimicrobial effect and has been used extensively as an irrigation agent to resist pathogens both gram (-) and gram (+) bacteria, fungi, spores, viruses, easily obtained, relatively cheap and effectively eliminates debris and organic tissue from smear layer.²⁰

In addition, 17% EDTA irrigation material is important to used to remove smear layers and inorganic substances so as to support penetration of irrigants, medicaments and sealers to dentine tubules. In the retreatment of right posterior mandibular first molar, the operator uses an additional irrigation material in the form of chlorhexidine (CHX) 2%, because in the case of endodontic treatment failure there is more *E. faecalis* bacteria than primary endodontic treatment. The *E. faecalis* bacteria can penetrate deeper into the dentin tubule and have a mechanism of resistance to the canal medicament. Irrigation for 2 minutes using a 2% CHX

solution can remove *E.faecalis* from the superficial layer of dentin tubules up to 100 µm. Effective methods against *E.faecalis* infection during and after root canal treatment are good aseptic techniques, an increase in the size of apical preparation, irrigation with NaOCl 2.5% and CHX 2% are the most effective to eliminate *E. faecalis*.²¹

Root canal medicaments used in this case are calcium hydroxide. Calcium hydroxide has a low solubility rate in water, high pH (12.5-12.8), and insoluble in alcohol. Calcium hydroxide paste can kill bacteria by direct contact through the effects of pH, and its placement should include the apical region to provide biological effects on the tissues. The antimicrobial activity of calcium hydroxide occurs due to the release and diffusion of hydroxyl ions which create a high alkaline environment, which is not conducive to microorganisms.²² 2% CHX gel combined with calcium hydroxide can reach pH 12.8 and can thoroughly clean *E.faecalis* on dentinal tubules.²¹

The root canal is ready for filling when it has been prepared in accordance with the length of work, no exudate in the root canal, no odor, and no sensitivity or complaints from the periapical tissue.³ Teeth 46 is fitted with F3 cones, and the sealer used is sealer made from epoxy resin, that is AH plus. This sealer has good adhesive properties, good flow, antibacterial, low toxicity and can be tolerated by periapical tissue. AH Plus compared to other sealers

provides a more effective antibacterial effect against *E.faecalis* through infected dentine tubules.²¹ In addition, AH Plus is better than AH 26 because when polymerization process, AH Plus does not release formaldehyde that is toxic and also does not contain black silver sulphides that cause discoloration in teeth.²³

The selection of fiber post in the dental restorations is to support and strengthen the remaining tooth structure and fiber post have dentin-like flexural properties that reduce the risk of fracture. Selection of appropriate restorations is based on the number of remaining tooth structures, anatomical positions, occlusal loads, and restoration requirements of these teeth. Restoration will cause damage to the periodontium tissue if the occlusal surface does not have a good physiological shape and occlusion.²⁴ So, for this case the restoration used is a metal porcelain crown with a fiber post.

CONCLUSION AND RECOMMENDATIONS

The diagnosis of right mandibular first molar in this case is chronic apical abscess caused by endodontic failure. The treatment plan in this case is a conventional endodontic retreatment with fiber post restoration and porcelain metal crown. The combination of adequate instrumentation with the addition of actual working length, the use of 2.5% NaOCl, 17% EDTA and CHX 20% with saline rinsed between irrigants, as well as intracanal medicament

calcium hydroxide and AH Plus sealer with adequate obturation throughout the working length can be optimal in killing *E.faecalis* causes root canal treatment failure. After 3 weeks of control after obturations, no subjective complaints from the patient, and clinical examination no signs of inflammation, no swelling of the gingiva, neither percussion nor palpation sensitive, the tooth returns to function, and radiolucency in the radiograph periapex decreased. It is recommended to observe by The European Society of Endodontics, for 1 year to 4 years to determine the success of treatment.

REFERENCES

1. Louis, Rosenberg, Jarshen. Do Procedural Errors Cause Endodontic Treatment Failure ?. JADA Vol 136. 2005.
2. Decision making and treatment planning. In: Advanced Endodontics Clinical Retreatment and Surgery. Rhodes JS (ed). 2002. New York: Taylor and Francis. Pg. 23-45.
3. Walton RE, Torabinejad M. Principles and Practice of Endodontics. 3rd ed. 2003. Philadelphia: Saunders. Pg. 333-342.
4. Bruder III GA, White RR. Retreatment. In: Color Atlas of Endodontics. Johnson WT (Ed). 2002. Toronto: W. B. Saunders Company. Pg. 117.
5. Rationale for Endodontic Retreatment. In: Advanced Endodontics Clinical Retreatment and Surgery. Rhodes JS (ed). 2002. New York: Taylor and Francis. Pg. 1-22.
6. Siqueira. Aetiology of Root Canal Treatment Failure: Why Well-Treated Teeth Can Fail. International Endodontic Journal 2001; 34:1-10.
7. Cohen. Pathways of the Pulp. 11th ed. 2016. St. Louis, Missouri: Mosby Inc. Pg. 324-382.
8. Rationale for Endodontic Retreatment. In: Advanced Endodontics Clinical Retreatment and Surgery. Rhodes JS (ed). 2002. New York: Taylor and Francis. Pg. 1-22.
9. Hulsman, Michael. Prevention and management of problems during root canal treatment – a problem – based approach to root canal treatment. Part II. Endo (LondEngl). 2016; 10(3): 141-151.
10. Hammad, et al. Three-Dimensional Evaluation of Effectiveness of Hand and Rotary Instrumentation for Retreatment of Canals Filled with Different Materials. JOE. 2008.
11. Daniela et al. Penetrability of AH Plus dan MTA Fillapex After Endodontic Treatment and Retreatment: A Confocal Laser Scanning Microscopy Study. Microscopy Research and Technique. 2014.
12. Zivanovic et al. Quality of Root Canal Fillings in a Bosnian Adult Population Treated in Public and Private Dental Clinics. Ser J Exp Clin Res. 2016.
13. Virdee, Thomas. A Practitioner's

- Guide to Gutta-Percha Removal during Endodontic Retreatment. British Dental Journal. 2017
14. Scelza et al. Comparative SEM Evaluation of Three Solvents Used Endodontic Retreatment: An Ex Vivo Study. *J Appl Oral Sci.* 2008.
 15. Karatas et al. The Effect of Chloroform, orange oil and eucalyptol on Root Canal Transportation in Endodontic Retreatment. *AustEndod J.* 2016.
 16. Lucena et al. Accuracy of working length measurement: electronic apex locator versus cone-beam computed tomography. *International Endodontic Journal.* 2014;47,246-256.
 17. In: Cohen S, Hargreaves KM (Eds). *Pathways of the Pulp.* 8th ed. 2003. St. Louis, Missouri: Mosby Inc. Pg. 658-65.
 18. Shen Y, Zhou H, Zheng Y, Peng B. Current Challenges and Concepts of the Thermomechanical Treatment of Nickel-Titanium Instruments. *J Endod.* 2013;39(2):163-172.
 19. Mistry KS, Shah S. Review on Common root Canal Irrigants. *Journal of Dental Science.* 2(2): 27-31.
 20. Kandaswamy D, Venkateshbabu N. Root Canal Irrigant. *Journal of Conservative Dentistry.* Oct-Dec 2010; 3(4).
 21. Stuart, Schwartz, Beeson, Owatz. *Enterococcus faecalis: Its Role in Root Canal Treatment Failure and Current.* *J Endod.* 2006;32:93-98).
 22. Athanassiadis B, Abbott PV, Walsh LJ. The use of calcium hydroxide, antibiotics and biocides as antimicrobial medicaments in endodontics. *Australian Dental Journal Supplement.* 2007; 52(1 Suppl):S64-S82.
 23. Geurtsen W et al. Biological Aspect of Root Canal Filling Materials- Biocompatibility, Cytotoxicity, and Mutagenicity. *Clin Oral Investig.* 1997; 1 (1):5-11.
 24. Salameh et al. Effect of Different All Ceramic Crown System on Fracture Resistance and Failure Pattern of Endodontically Treated Maxillary Premolars Restored With and Without Glass Fiber Posts. *J Endod.* 2007;33:848-851).

CASE REPORT

DIRECT VENEER COMPOSITE FOR DIASTEMA AND PEG SHAPED ON ANTERIOR MAXILLARY TEETH

(CASE REPORT)

Rozyta K Hakim¹, Juanita A Gunawan², Selviana Wulansari²

Department of Conservative Dentistry Faculty of Dentistry Trisakti University

1 Resident in Department Conservative Dentistry and Endodontics Trisakti University

2 Lecturer in Department Conservative Dentistry and Endodontics Trisakti University

ABSTRACT

Background: Diastema is space between anterior teeth common in adult dentitions. Peg shaped teeth are type of microdontia which is teeth smaller than normal. Most of diastema and peg shaped feature in maxillary region and needing correction by practitioner to ensure patient's satisfaction with treatment outcomes. Direct composite veneer has been a treatment choice for diastema closure and peg shaped correction. **Objective:** The aim of this case report is to correction of dental anatomies such as diastema and peg shaped on anterior maxillary teeth with direct veneer composite. **Case:** A 24 years old male patient with complaint of space and small shaped on his front tooth. The patient had no history of trauma or extraction. Extra and intra oral examination showed no abnormalities. He feels not confident when communicated with people he met and he needs a treatment to fix shaped of his tooth. **Conclusion:** Direct veneer composite as a restoration for diastema and peg shaped showed a successful treatment outcome.

Keywords: diastema, peg shaped, direct veneer composite.

Introduction

Maxillary anterior spacing or diastema is a common aesthetic complaint of patients. Keene described midline diastema as anterior midline spacing greater than 0.5 mm between the proximal surfaces of adjacent teeth. It was reported that maxilla has a higher prevalence of midline diastema than mandible. The midline diastema has a multifactorial

etiology. In addition to the labial frenulum, microdontia, mesiodens, peg-shaped lateral incisors, lateral incisor agenesis, cysts in the midline region, habits such as finger sucking, tongue thrusting, and/or lip sucking, dental malformations, genetics, maxillary incisor proclination, dental-skeletal discrepancies, and imperfect coalescence of the interdental septum should be considered factors that can cause

diastema. The width to length ratio of the central incisors for aesthetic rehabilitation in complex midline diastema closure cases determines the treatment plan.¹

A peg lateral is defined as ‘an undersized, tapered, maxillary lateral incisor’ (Glossary of prosthodontic terms (1990) that may be associated with other dental anomalies, such as canine transposition and over retained deciduous teeth. Individuals with malformed lateral incisors often display a diastema in the midline region caused by the distal movement of the central incisor. There are many acquired and inherited developmental abnormalities that alter the size, shape and number of teeth peg-shaped laterals are also known as cone-shaped lateral incisor, which is a form of microdontia. There are many new conservative options that are possible using direct and indirect composite resin material. It is essential to discuss these options with patients, their parents and the interdisciplinary team that are involved in treatment.²

Objective

The aim of this case report is to correction of dental anatomies such as diastema and peg shaped on anterior maxillary teeth with direct veneer composite.

Case Report

A 24 year old male patient reported to the department of conservative dentistry Trisakti University with a chief complaint

of spacing and small shaped in the upper front tooth region. Patient’s medical history did not reveal any systemic diseases and intraoral examination revealed presence of midline spacing between maxillary central incisors (~2 mm). No dental caries were observed in both clinical and radiographical examinations. As a more conservative, economical, aesthetic, and quicker option is direct composite veneer. The patient showed normal overjet (2 mm) and overbite (2 mm). In order to convince the patient, virtual central and lateral incisors were build according to golden proportion and RED (RecurringEsthetic Dental) proportion from preoperative intra oral photograph (Fig 1A-1E) and diagnostic casts were prepared and mock up with wax was done (Fig 1F).

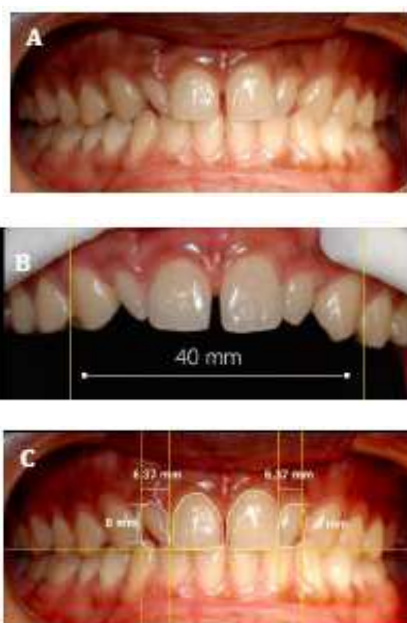

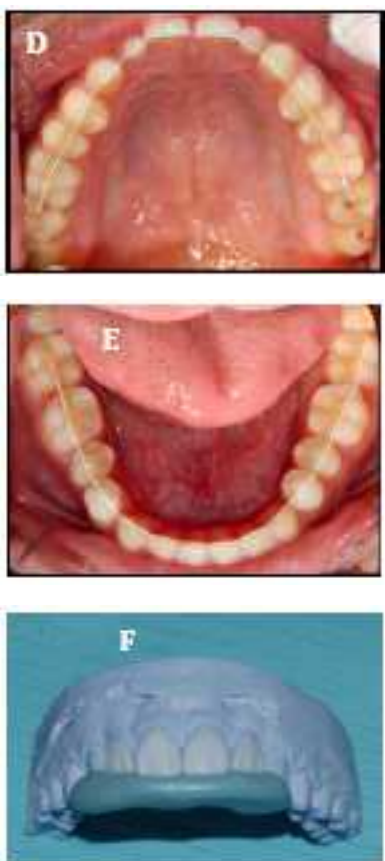


Figure 1. A) preoperative. B,C,D,E) golden proportion and RED (RecurringEsthetic Dental) proportion. F) diagnostic and mock up with wax.

Firstly, shade selection composite to simulate a natural outlook used shades OA3 for dentin and A2 for email(*Palfique LX5, Tokuyama*). No preparations were performed before the restoration procedure (Fig. 2A). Roughening of the enamel surface with pumice (Fig 2B). All maxillary incisors were isolated with rubber dam, the central and lateral incisors were retracted by using retraction cord cordsize 00 (Fig 2C). 37% phosphoric acid was applied for 15 seconds, rinsed for 20 seconds,

and dried with air slightly (Fig 2D-2E). Then bonding agent (*Optibond, Kerr*) was applied (Fig 2F-2G) and polymerized for 20 seconds with a LED light generator. Isolated proximal area with seluloid strip and thin layer composite was applied with mocked up as a guidance for palatal shell. A thin layer of OA3 shade composite resin was placed roughly as dentin layer. A2 shade composite resin was used as enamel layer(*Palfique LX5, Tokuyama*)(Fig 2).

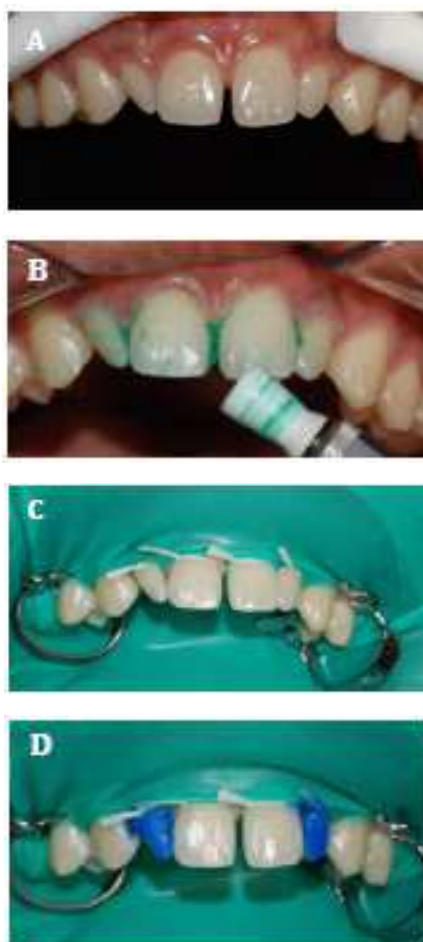

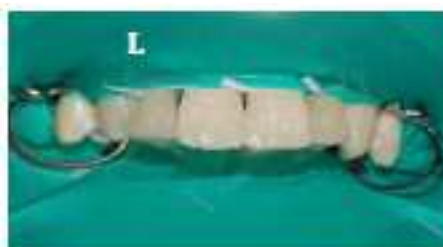
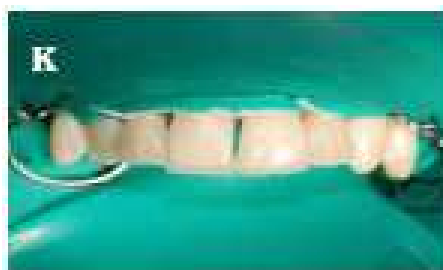
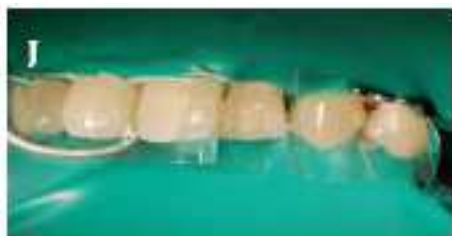
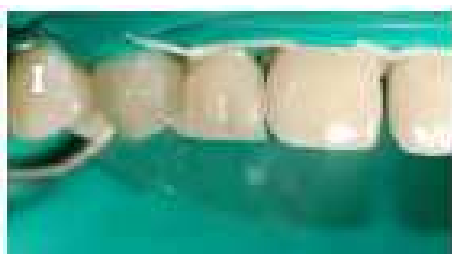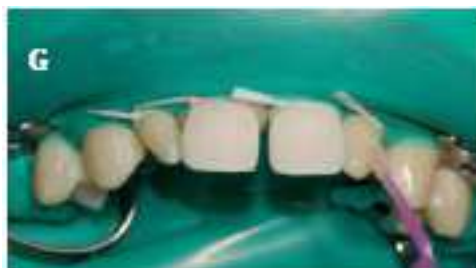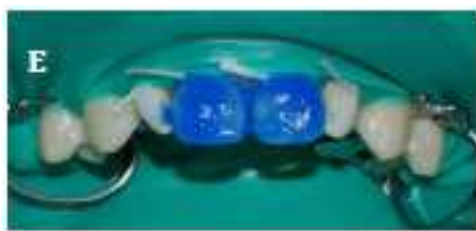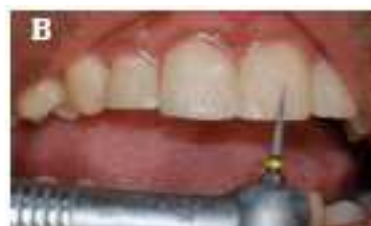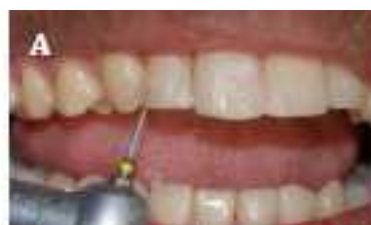Figure 1. A) shade selection composite simulated. B) roughening of the enamel surface with pumice C) isolated with rubber dam and retraction cord. D,E) Etching with 37% phosphoric acid. F,G) Bonding H) Palatal shell. I,J,K,L) Resin composite applied for dentin and email layer with seluloid strip.

Finishing contouring and polishing were accomplished with fissure superfine polishing bur and Sof-Lex disc (3M ESPE Dental Products. St. Paul, MN, USA).



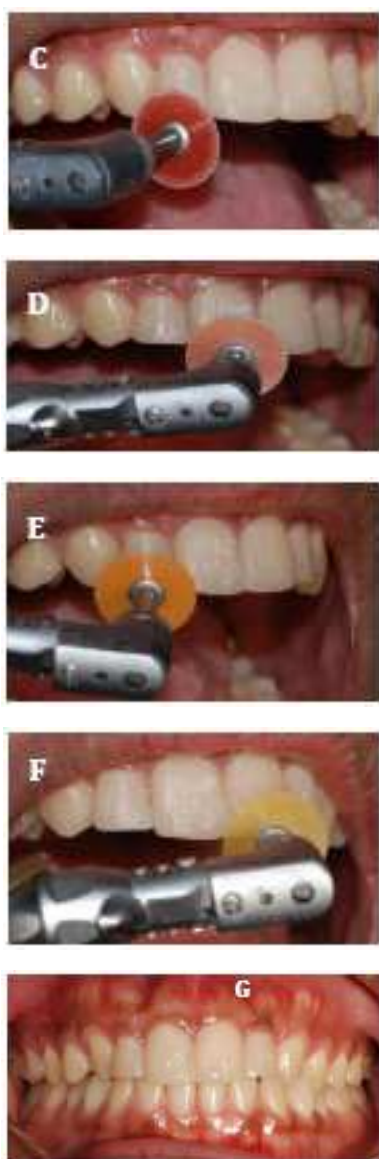


Figure 1. A,B) Finishing contouring with fissure superfine polishing bur. C,D,E,F) Polishing with Sof-Lex disc. G) Post operative

Discussion

Maxillary anterior teeth malformation such as enamel hypoplasia, peg shape laterals can present esthetic problems. Such situations also can demand

expeditious treatment from a psychosocial point of view. A peg lateral is defined as an undersized, tapered, maxillary incisor that may be associated with other dental anomalies, such as canine transposition and over retained deciduous teeth. Individuals with malformed lateral incisors often display a diastema in the midline region caused by the distal movement of the central incisor due to small size adjacent tooth. The incidence of peg shaped incisor was found to be 0.8% in 739 children. In other study it was found to be 0.4%. The treatment includes two primary objectives: to restore or replace, and to close the diastemas.³ Esthetic bonding with resin composite may be the most conservative approach in comparison to all ceramic restoration, resin composite does not have the potential for catastrophic brittle fracture, nor does it cause abrasive wear of the opposing dentition as seen in porcelain crown. The presence of a midline diastema or spaces in between anterior can be a major esthetic concern for patient. There are various treatment options available for diastema closure in adults like orthodontic movement, restorative and prosthodontic treatment. Amongst these, the use of direct resin composite restorations seems to be conservative and more practical.³ Direct bonded composite restorations can be undertaken quickly in a matter of hours. They offer great flexibility in that the restorations can be added to easily. Shapes can be changed including additions to the length and width of the teeth. Composite can be added to the teeth to give the illusion

that changes are made to the angulation and alignment of the teeth.²

Conclusion

Direct composite veneer provides good esthetic result at the lesser cost and time due to absence of laboratory procedure and completion of work in single appointments. This minimally invasive technique is a better option in treatment of peg laterals and midline diastema compared to full crown.

Daftar Pustaka

1. Korkut B, Yanikoglu, F, Tagtekin D. Direct midline diastema closure with composite layering technique: A one year follow-up. Vol:2016. Available from: <https://www.hindawi.com/journals/crid/2016/6810984/>
2. Greenwall L. Treatment options for peg-shaped laterals using direct composite bonding. IntDentSA; 12 (1). Available from: http://www.modern-dentistrymedia.com/jan_feb2010/greenwall.pdf
3. Jais PS, Shah RP, Sinhal TM. Direct composite veneer an aesthetic alternative: case series with one year follow up. IOSR-JDMS; Vol 15:78-82. Available from: <http://www.iosrjournals.org/iosr-jdms/papers/Vol15-issue1/Version-10/O0151107882.pdf>

ROOT CANAL RETREATMENT OF TRUE COMBINED LESION IN MANDIBULARY RIGHT CANINE

Silviana Swastiningtyas¹, Anggraini Margono²

¹ Post Graduate Student, Department of Conservative Dentistry, Faculty of Dentistry
Universitas Indonesia

² Lecturer, Department of Conservative Dentistry, Faculty of Dentistry,
Universitas Indonesia

ABSTRACT

The pulp and periodontium are closely related, they have embryonic, anatomic and functional inter-relationship. Pulpal infection communicates with periodontal disease through various routes, as a result they formed endo perio lesion. In this case, based on anamnesis, clinical and radiograph examination refer to as true combined lesion. The purpose of this case report is to present a clinical case of root canal retreatment of true combined lesion in right mandibulary canine. A 47-year-old man was referred for root canal retreatment of right mandibulary canine to the Conservative Dentistry Clinic. He felt pain and discomfort while chewing on his lower right tooth. Five years earlier, he had extensive cavity and swelling on his tooth so it had been treated and restored by former dentist. Four years later, the symptoms returned and from clinical examination showed a temporary filling on tooth #43, sensitive to percussion and palpation, no respond to cold test, tooth mobility °2, sinus tract on lingual side, periodontal pocket 6 mm in mesial and 4 mm on distal area. Pre-operative radiograph showed underfilled obturation and difused periapical radiolucency with diameter of 10 mm. Considering the clinical and radiographic findings, our final diagnosis was chronic apical abscess et causa inadequate root canal treatment and chronic marginalis periodontitis with true combined lesion according to Cohen's classification of endo perio lesion. Therefore, root canal retreatment and periodontal treatment was decided to be performed. Relief of pain, decrease in lesion size and tooth mobility have shown that these treatments gave us positive results.

Keywords : root canal retreatment, true combined lesion, mandibulary canine

INTRODUCTION

Endo perio lesions is a challenging condition for dental professionals regarding the diagnosis and treatment. Cross-infection between the root canal and the periodontal ligament can occur via the following pathways such as apical foramen, lateral and accessory canals, dentinal tubules, iatrogenic perforations and vertical root fracture.^{1,2} Endodontic-periodontal problems are responsible for more than 50% of tooth mortality.³⁻⁵ The relationship between periodontium and pulpa was first discovered by Simring and Goldberg in 1964. Since then, the term “endo-perio lesion” has been used to describe this type of lesions due to same inflammatory products found in both periodontal dan pulpal tissues.²⁻⁴

In this case report, considering the clinical and radiographic findings, the diagnosis was true combined endo perio lesion. Root canal reinfection due to endodontic failure and deep periodontal pocket on adjacent teeth was found in this case. Pre-operative radiograph showed underfilled obturation and difused periapical radiolucency with diameter of 10 mm.

The prognosis of this case was in good condition because the tooth had straight canals, no blockage or obliteration, well developed apical constriction and patient's medical history was non-contributory. Root canal retreatment and periodontal curettage had been our treatment planning. Healing process that happened was

forming granulomatous fibrovascular tissues and increasing osteoblast activity and mesenchymal cell on alveolar bone that can result bone regeneration.⁸ The purpose of this case report is to present a clinical case of root canal retreatment of true combined lesion in right mandibulary canine.

CASE REPORT

A 47-year-old man was referred for root canal retreatment of right mandibulary canine to the Conservative Dentistry Clinic. He felt pain and discomfort while chewing on his lower right tooth. Five years earlier, he had extensive cavity and swelling on his tooth so it had been treated and restored by former dentist. Four years later, the symptoms returned and from clinical examination showed a temporary filling on tooth #43, sensitive to percussion and palpation, no respond to cold test, tooth mobility °2, sinus tract on lingual side, periodontal pocket 6 mm in mesial and 4 mm on distal area. Pre-operative radiograph showed underfilled obturation and difused periapical radiolucency with diameter of 10 mm. Considering the clinical and radiographic findings, our final diagnosis was chronic apical abscess et causa inadequate root canal treatment and chronic marginalis periodontitis with true combined lesion according to Cohen's classification of endo perio lesion. Therefore root canal retreatment and periodontal treatment was decided to be performed. Our final restoration was porcelain fused to metal with fiber post.

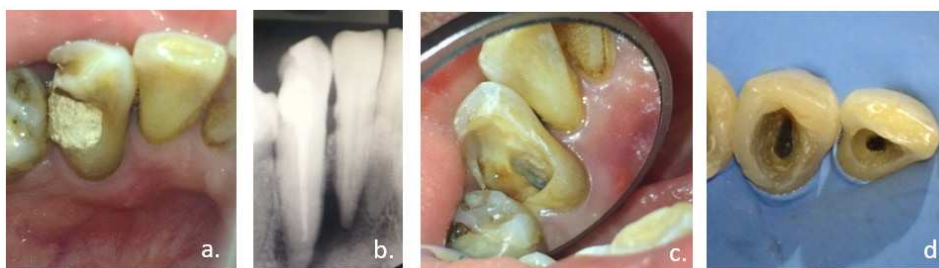


Figure-1. (a,b) Preoperative clinical photograph and radiograph (c) Access opening of tooth #43, (d) Artificial wall by composite resin on distal wall

TREATMENT PLANNING

After placing a rubber dam, the restoration was removed and the access cavities were prepared by Endo Access Bur and Endo Access Kit (Dentsply, Switzerland). Artificial wall on distal wall was made by composite resin. The deficient root canal filling materials were removed using Universal Rotary Retreatment files (Dentsply, Switzerland). Root canal was explored with number #10 K-file and Proglider (Dentsply, Switzerland) until working length then prepared by ProTaper Next (Dentsply, Switzerland) to size X4/24.5 mm. Working length were determine using electronic apex locator (Pixi, Dentsply, Switzerland). The canal was irrigated with 2.5% sodium hypochlorite and 17% EDTA solution by syringe with side-vented 30-gauge needle and activated by Endoactivator (Dentsply, Switzerland). The additional irrigation was using 2% chlorhexidine. Calcium hydroxide was placed as intracanal medicament and the canal was sealed by temporary filling.

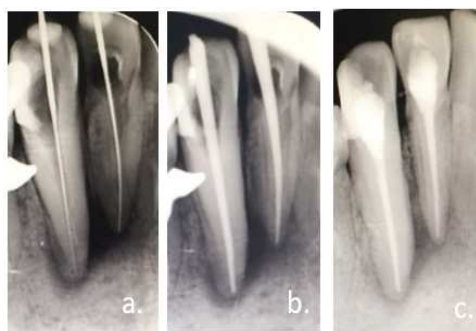


Figure-2. (a) Working length determination by initial file, (b) Master apical cone measurement, (c) Radiograph evaluation after obturation.

Two weeks later, root canal treatment was completed with no symptoms and no tenderness to percussion. The canals were rinsed with 2.5% sodium hypochlorite solution and 17% EDTA then dried by using sterile paper point. The root canal was obturated with gutta-percha and AHplus sealer by using lateral condensation technique. A radiograph was taken to evaluate the obturation. GIC was placed as bases and temporary filling. Final restoration was accomplished one month later by porcelain fused to metal with fiber post.

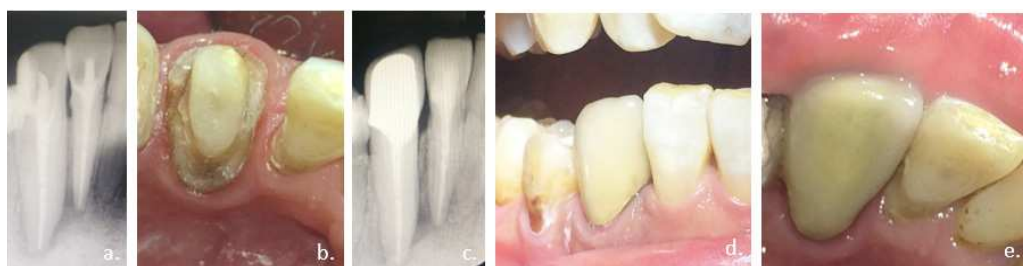

Figure-3. (a) Radiograph evaluation after fiber post placement, (b) Tooth preparation, (c) Crown try-in radiograph evaluation, (d,e) Crown cementation.

DISCUSSION

The endo-perio lesions is a challenging factor to clinicians as far as diagnosis and prognosis of the involved teeth are concern. Correct diagnosis is an important factor to determine the treatment and long-term prognosis.^{3,5,9} Complex root canal anatomy may prevent satisfactory removal of bacteria and biofilm from root canal surfaces resulting in failure of endodontic treatment. When pulpal and periodontal lesions occur concurrently, it is described as combined lesion.^{2,6} In this conditions, the treatment and prognosis of the tooth are different from those of teeth involved with only primary endodontic disease. The tooth requires both endodontic and periodontal treatments.^{7,11}

Based on anamnesis, clinical and radiographic findings, the tooth was diagnosed as chronic apical abscess et causa inadequate root canal treatment and chronic marginalis periodontitis with true combined lesion according to Cohen's classification of endo perio lesion. Endodontic failure on tooth #43 caused reinfection on root canal system that induced inflammation reaction on periapical tissue surrounding

foramen apical leading to destruction of the periapical alveolar bone causing breakdown of surrounding hard and soft tissues. Therefore, periapical abscess was formed and expanding to marginal area. Plaque and calculus accumulation around the tooth caused inflammation on periodontal tissues then evolved to periodontal pocket formation on mesial side was 6 mm deep and distal side was 4 mm deep. This periodontal lesion expanded to apical area that merge with periapical lesion forming true combined endo-perio lesion.

Proper endodontic and periodontal treatment is a key factor for treatment success. Zone of infection on root canal system can be removed by endodontic retreatment and provoke healing process on periapical area. Periodontal treatment such as periodontal curettage can eliminate the infection origin located in marginal area. Therefore, complete debridement can be done in both direction from apical and marginal, that leading to optimal result.

In this case report, the cleaning and shaping procedures of the root canals were performed in combination between

rotary NiTi instruments and irrigation with sodium hypochlorite, EDTA and CHX. According to Bird, Chambers and Peter, rotary nickel-titanium (NiTi) instruments have become a standard tool for shaping root canal system. Compared with conventional stainless-steel instruments, these instruments offer several advantages. For instance, they are more flexible and have increased cutting efficiency.¹⁸ The preparation of a reproducible glide path, a smooth passage that extends from the canal orifice in the pulp chamber to its opening at the apex of the root, makes a continuous and uninterrupted pathway for the rotary NiTi instrument to enter and to move freely to the root canal terminus. The main purpose of a glide path is to create a root canal diameter the same size as the first rotary instrument used or ideally, a size larger than that. In this case, a reproducible glide path had been created by #15 k-file then continued by rotary ProGlider (Dentsply®, Maillefer).

ProTaper Next (Dentsply®, Maillefer) was used because of its flexibility and cutting efficiency properties. ProTaper Next file has progressive properties taper design in the apical region and taper which is downward to the coronal with an off-centered rectangular cross-section design which is symmetrical on both sides with an offset from the central axis of rotation that is enable it to produce an asymmetrical rotational movement.^{15,16} This movements make an instrument move like a phenomenon which are called the rotational precision

or swagger.¹⁶ The swaggering motion initiates the activation of the irrigation solution during canal preparation, further improving debris removal.¹⁸ ProTaper Next files are manufactures using M-Wire NiTi to increase flexibility and cyclic fatigue resistance of the files.¹⁵ Each file comes with an increasing and decreasing percentage tapered design on a single file. This multiple progressive taper concept helps to reduce contact between the cutting flutes of the instrument and the dentine wall, thus reducing the possibility of taper lock (screw-in-effect). It also increases flexibility and cutting efficiency.¹⁸

The microbial flora in the canals of the teeth after failed endodontic therapy appears to be a very limited assortment of the microorganism that have been reported in untreated root canals. The common recovery of *E.faecalis*, from the root canals of the teeth in which the previous treatment has failed, is notable. *E.faecalis* appears to be highly resistant to the medicament used during treatment and is one of the few microorganism that has been shown in vitro to resist the antibacterial effect of calcium hydroxide. These microorganism appear to have an ability to utilize opportunities created by the removal of other microbes and also to have the capacity to grow in the low-nutrient environment of the treated canal.¹⁹⁻²¹

Additional irrigation used in this case was 2% chlorhexidine (CHX) as a final flush. CHX has a narrow spectrum for gram-negative bacteria but is effective

against most gram-positive bacteria and also fungi. CHX is the agent of choice when there are gram-positive resistant enterococci present in the root canal, which may be the case in retreatment situations.^{19,22}

Calcium hydroxide can be used as an intracanal medicament because of its bactericidal, anti-inflammatory and proteolytic properties that inhibits resorption and favor repair. It also inhibits periodontal contamination from instrumented canals via patent channels connecting the pulp and periodontium before periodontal treatment removes the contaminants. Calcium hydroxide promotes the formation of hard tissues and enhanced mineralization due to activation of alkaline phosphatase, resulting in the release of phosphate groups which then react with calcium ions.^{22,23,24}

CONCLUSION

This case demonstrates that proper diagnosis, followed by removal of etiological factors, will restore health and function to a tooth with attachment loss caused by an endo-perio lesion. Thereby, the immediate and true management of the endo-perio lesions can impede the loss of the natural tooth and delay the more complex treatments.

REFERENCE

1. Priyanka Mariam George JR. Endo Perio Lesion- A Case Report. *J Med Biomed Appl Sci*. 2017;5(2):108-110.
2. Kerns GD GNC. Endodontic and Periodontal Interrelationships. In: *Cohen's Pathway of the Pulp Pathway of the Pulp*. 10 edition. Elsevier Mosby; 2011:655-662.
3. Vinisha Pandey VK. The Periodontal - Endodontic Relationship. *GUIDENT*. 2016:49-53.
4. Abhishek Parolia, Toh Choo Gait, Isabel C. C.M. Porto KM. Endo-perio lesion: A dilemma from 19th until 21st century. *J Interdiscip Dent*. 2013;3(1):2-11.
5. Dr. Syed Wali Peeran, Madhumala Thiruneervannan, Khaled Awidat Abdalla MHM. Endo-Perio Lesions. *Int J Sci Technol Res*. 2013;2(5):268-274.
6. Khalid S. Al-Fouzan. A New Classification of Endodontic-Periodontal Lesions. *Int J Dentistry*. 2014:1-5.
7. Alexandre Pico-Blanco, DDS, Pablo Castelo-Baz, PhD, DDS, Leticia Caneiro-Queija, DDS, Antonio Liñares-González, PhD, DDS, Pablo Martín-Lancharro, PhD and Juan Blanco-Carrión, PhD D. Saving Single-rooted Teeth with Combined Endodontic-periodontal Lesions. *J Endod*. 2016:1-6.
8. M. Lin L T-JHG. Pathobiology of Periapex. In: *Cohen's Pathway of the Pulp*. 10 edition. Elsevier Mosby; 2011:529-554.
9. Hacer Aksel AS. A case series

- associated with different kinds of endo-perio lesions. *J Clin Exp Dent*. 2014;6(1):91-95.
10. Siqueira J RI. Microbiology and Treatment of Endodontic Infections. In: *Cohen's Pathway of the Pulp*. 10 edition. Elsevier Mosby; 2011:572-577.
 11. Hargreaves K CS. Nonsurgical Retreatment. In: *Cohen's Pathway of the Pulp*. 10 edition. Elsevier Mosby; 2011:890.
 12. Bodrumlu E SM. Antibacterial activity of a new endodontic sealer against *Enterococcus faecalis*. *J Can Dent Assoc*. 2006;72(7):637.
 13. Ilan Rotstein JHSS. Endodontic-Periodontal Interrelationship. In: *Ingle's Endodontics*. ; 2008:641-644.
 14. Chandra BS KV. *Grossman's Endodontic Practice*. 12 edition. Wolter Kluwer; 2010.
 15. A. M. Elnaghy. Cyclic fatigue resistance of ProTaper Next nickel-titanium rotary files. *Int Endod J*. 2014:1-6.
 16. Meilina Goenawan,*, Juni JektiNugroho CAR, Aries Chandra Trilaksana, Nurhayaty Natsir AS. Effectivity of convex triangular and rectangular cross section instruments on decreasing the amount of root canal *Enterococcus faecalis* bacteria colonies. *J Dentomaxillofacial Sci*. 2016;1(2):271-276.
 17. Michael J. Scianamblo MF. The advantages of instrument compressibility and ProTaper NEXT. *Endod Pract Us*. 2017.
 18. Vyver PJ van der, Scianamblo MJ. Clinical guidelines for the use of ProTaper Next instruments (Part I). *Dent Trib*. 2014:12-16.
 19. Evan M, Davies J.K S and F. Mechanisms Involved in the Resistance of the *Enterococcus faecalis* to Calcium Hydroxide. *Int Endod J*. 2002;35:221-228.
 20. Sundqvist G, Figdor D, Persson S SU. Microbiologic Analysis of Teeth with Failed Endodontic Treatment and the Outcome of Conservative Re-treatment. *Oral Surg Oral Med Oral Pathol Oral Radiol Endod*. 1998;85:86-93.
 21. Sundqvist GFD. Life as an Endodontic Pathogen: Ecological Difference between Untreated and Filled Root Canal. *Endod Top*. 2003;6:3-28.
 22. B Athanassiadis, PV Abbott LW. The Use of Calcium Hydroxide, Antibiotics and Biocides as Antimicrobial Medicaments in Endodontics. *Aust Dent J Suppl*. 2007;52:64-82.
 23. J.F. Siquera HPL. Mechanisms of Antimicrobial Activity of Calcium Hydroxide : A Critical Review. *Int Endod J*. 1999;32:361-369.
 24. P. C. Foreman IEB. A Review of Calcium Hydroxide. *Int Endod J*. 1990;23:283-297.

CASE REPORT

ENDOCROWN AS A FINAL RESTORATION FOR ENDODONTICALLY TREATED TEETH WITH CHRONIC APICAL ABSCESS– A CASE REPORT

Stephani Marthios¹, Sri Subekti Winanto², Elline²

¹Resident at Department of Conservative Dentistry Trisakti University,
Jakarta-Indonesia

²Staff at Department of Conservative Dentistry Trisakti University,
Jakarta-Indonesia

ABSTRACT

Background : Clinical success of posterior endodontically treated teeth is determined by the post-endodontic restoration. Endocrowns represent a conservative and esthetic restorative alternative to full coverage crowns. When the pulp chamber presents appropriate conditions for retention, the endocrown is indicated. The restoration can be made of different tooth-colored materials : ceramic or resin composite. Advances in adhesive dentistry have made great contributions to cosmetic & restorative dentistry over the past few decades. The preparation consists of a occlusal preparation, axial preparation, and preparation of the cavity floor. This endocrown is an alternative to conventional crown-root anchored restoration. **Objective :** The aim of this case report is to demonstrate a succeed root canal treatment (RCT) of chronic apical abscess in maxillary second premolar with endocrown as a final post-endodontic restoration. **Case :** A 22-year-old male patient with discomfort in his left maxillary second premolar while food chewing since 6 months ago. Objective assessment and radiographic examination showed the diagnostic for #25 was profunda caries with chronic apical abscess *et causa* pulp necrosis. RCT for #25 with endocrown as post-endodontic restoration was conducted. The preparation for endocrown begin with occlusal reduction 2 mm with diamond wheel bur. Axial preparation involves eliminating undercuts in the access cavity and the depth of the cavity should be at least 3 mm. Continuing with polishing the cervical band, preparation of the cavity floor, cleaning the pulp chamber, impression made, and bonding the endocrown to the prepared tooth. **Conclusion :** Root canal treatment with endocrown as treatment of choice for post-endodontic restoration on maxillary second premolar showed a successful treatment outcome.

Keyword : endocrown, post endodontic restoration, root canal treatment, chronic apical abscess

INTRODUCTION

The restoration of endodontically treated teeth has long been a challenge for dentists. These teeth often have little remaining crown, and the biomechanical principles of retention and resistance are compromised. Placement of the intracanal post risks root perforation and thinning of the root canal walls as a result of overpreparation. These cases often require preparation of the remaining or entire crown in order to stabilize the remaining tooth structure and replace the lost material.

¹ Many author disagree with the use of posts due to various risk associated with it such as root perforation, root weakness and failure of teeth restored with posts.² However, a simpler, faster, and more conservative alternative is needed. In order to devise a conservative treatment option for endodontically treated teeth, Bindl and Mormann proposed the restoration of nonvital teeth using the pulp chamber for support of the definitive onlay restoration. This restoration technique, called the endocrown. ¹By definition, endocrowns are partial crowns made out of ceramic or composite resin that are bonded by resin cements to the devitalized tooth. They offer a full occlusal coverage and they take advantage of the pulp chamber to increase the available adhesive surface. Different materials can be used to fabricate an endocrownfeldsphatic and glass-ceramic, hybrid composite resin and the newest computer aided design/ computer aided manufacturing (CAD/ CAM) ceramic

and composite resin blocks.²Endocrown has been discussed as a conservative and alternative treatment modality to post & core.The “Endocrown” provides good esthetic, better mechanical performance, can be performed with less cost & less clinical time.³

The aim of this case report is to demonstrate a succeed root canal treatment (RCT) of chronic apical abscess in maxillary second premolar with endocrown as a final post-endodontic restoration.

CASE REPORT

A 22-year-old male patient with discomfort in his left maxillary second premolar while food chewing since 6 months ago. Objective assessment showed a cavity extended to the pulp involving occlusal and distal area (Fig.A) (tender to percussion but the palpation and mobility was normal)and sinus tract in attached gingiva (Fig.B). Radiographic examination showed a cavity extended to the pulp with apical lesion and periodontal ligament widening (Fig.C).The diagnostic for tooth 25 was profunda caries with chronic apical abscess *et causa* pulp necrosis. Root canal treatment on tooth 25 with endocrown as post-endodontic restoration was conducted.

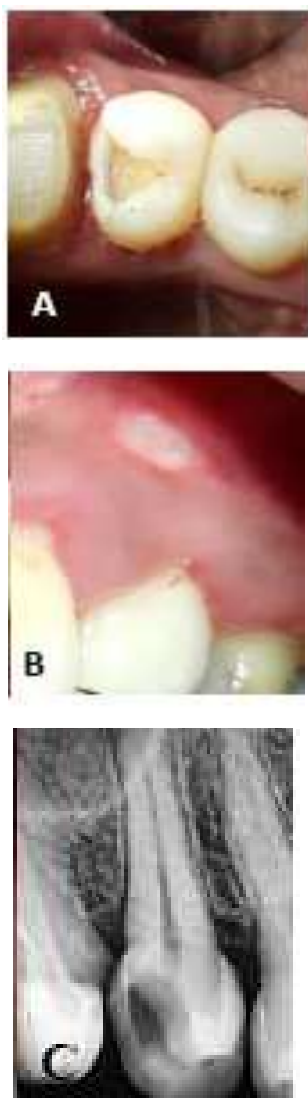


Figure A.Initial aspect of the maxillary second premolar,B.Sinus tract in attached gingiva,C. Initial radiograph

In the first session, the working models were obtained by taking impressions of the mandibular and maxillary in order to fabricate the provisional restoration. The endodontic access opening was made and followed by isolation of the tooth using rubber dam and artificial wall was made on distal wall with composit resin. Glide

path was established path with Proglider (16/.02) (Denstply, Maillefer), both canal were shaped with Protaper Next (Denstply, Maillefer) file X1 (17/.04) and X2 (25/.06) sequentially. In between instrumentation, copious irrigation was done with 5.25% NaOCl (Chloraxid, CerkaMed) and saline, and recapitulated with C+ file (Denstply, Maillefer) size #10. Calcium hidroxiide (Ultracal XS, Ultradent) was used as an intracanal medicament.

Second visit was ten days later, patient was clinically evaluated and the tooth remained asymptomatic. Intracanal medicament was flushed with distilled water and 5,25% sodium hypochlorite followed by rinse of saline. 2% chlorhexidine was used as the final irrigant. The canals were dried with absorbent paper points (Dentsply, Maillefer). Obturation was performed with gutta-percha Protaper Next X2 (Denstply, Maillefer) and root canal sealer (Saelapex, SybronEndo) using vertical condensation technique. On top of the obturation material, a 2 mm barrier was made using glass ionomer LC (Fuji II, GC). The preparation for endocrown begin with occlusal reduction 2 mm with diamond wheel bur. Axial preparation involves eliminating undercuts in the access cavity and the depth of the cavity should be at least 3 mm. Continuing with polishing the cervical band, preparation of the cavity floor and cleaning the pulp chamber. The impression of the tooth was taken by the double-impression technique, and the prepared tooth was covered with

provisional restoration (Luxatemp, DMG). The next visit was bonding the endocrown to the prepared tooth with resin cement (Maxcem, Kerr).

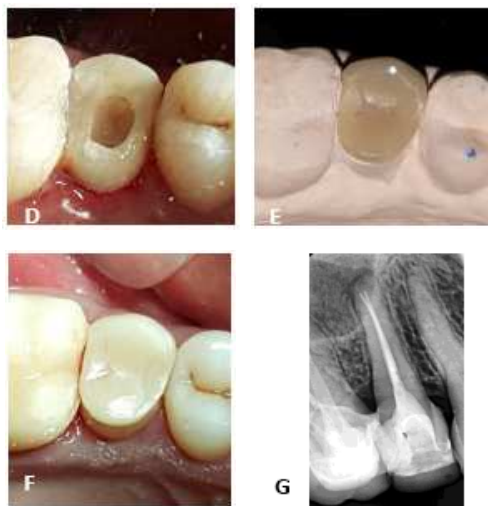


Figure D. Tooth preparation for endocrown, E. Occlusal view following final cementation, F. Composite restoration of the endocrown, G. Radiographic view postcementation

Clinical success of posterior endodontically treated teeth is determined by the post-endodontic restoration. Planning the restorative treatment of devitalized teeth is a challenge to the dentist, particularly with regards to the choice of the root retention system, making it difficult to decide which is the best treatment option to guarantee the clinical longevity of the treatment.

Endocrowns represent a conservative and esthetic restorative alternative to full coverage crowns. When the pulp chamber presents appropriate conditions for retention, the endocrown is indicated.

The restoration can be made of different tooth-colored materials : ceramic or resin composite. The endocrown is suitable for those with clinically low crowns, calcified root canals or very slender roots. The endocrown is contraindicated if adhesion cannot be assured, if the pulpal chamber is less than 3 mm deep or if the cervical margin is less than 2 mm wide for most of its circumference.⁴ Endocrowns are relatively new, easy and quick to perform. It has several advantages like less number of interfaces in the restorative system. Preparation design is conservative and biologic width is minimal.¹

In an evaluation of adhesively placed endocrowns after 2 years, Bindl and Mörmann concluded that “the overall clinical quality of the endocrowns was very good.” In another 2 year evaluation, Bernhart et al. concluded that endocrowns “represent a very promising treatment alternative. They concluded that endocrowns were more resistant to compressive forces than conventional crowns.”⁴

CONCLUSION

Endocrowns are relatively new, easy and quick to perform. It has several advantages like less number of interfaces in the restorative system. It represents a conservative and esthetic restorative alternative to full coverage crowns.

REFERENCES

1. Cunha LF, Mondelli J, Auersvald M, Gonzaga CC, Mondelli RFL, Correr GM, et al. Endocrown with leucite-reinforce ceramic : case of restoration of endodontically treated teeth – case report. Hindawi Publishing Corporation. 2015 : 1-4
2. Rocca GT, Krejci I. Crown and post-free adhesive restorations for endodontically treated posterior teeth : from direct composite to endocrowns. The European journal of esthetic dentistry. 2013 (8) : 154-177
3. Mahesh BA, Vandana G, Sanjay P, Jaykumar G, Deepika C, Aatif N. Endocrown: Conservative Treatment Modality for Restoration of Endodontically Treated Teeth – A Case Report. Endodontology. 2015 (27) : 188-191
4. Fages M, BennasarB. The endocrown : a different type of all-ceramic reconstruction for molars. J can dent assoc. 2013 (79) : 140.

LITERATURE REVIEW

DIFFERENT FERRULE DESIGNS ON FRACTURE RESISTANCE IN MAXILLARY ANTERIOR TOOTH : LITERATURE REVIEW

Tri Sari Dewi Purba * Dennis**Rasinta Tarigan**

** Resident of Specialist Program of Conservative Dentistry*

***Lecturer of Specialist of Conservative Dentistry*

Faculty of Dentistry, University of Sumatra Utara

Jln . Alumni No.2 Kampus USU Medan 20155

ABSTRACT

Fracture resistance of endodontically treated tooth is less than healthy ones due to their hard tissue loss because of caries, restorative and endodontic procedures. These teeth also have a higher chance to fracture because of their severe loss of vital dentinal moisture. In cases of endodontically treated teeth, using a post as the retentive factor for core build up is helpful. A ferrule has been described as a key element of tooth preparation when using post core. Ferrule effect enhances fracture resistance and prevents fracture of coronal structure. It has been stated that ferrule can improve resistance on dynamic occlusal loading, maintain the integrity of the cement seal for the full crown retention, and reduce the potential for concentration of stress at the junction of the post and core. Various different ferrule designs have been suggested like ferrule height, ferrule width, number of walls and ferrule location. Breakthrough in dentinal adhesive technology in recent years have built a new generation of bondable root canal sealers and post systems. Thus arose the concept of monoblock, with its advantages of simultaneously improving the seal and fracture resistance of the filled canals. The purpose of this article is to explain that final restoration with post that requires proper ferrule designs as retentive factor.

Key words : Ferrule; Fracture Resistance; Bonded Post and Core

Introduction

Successful restoration of endodontically treated teeth requires an effective coronal seal, protection of the remaining tooth, restored function and acceptable aesthetics. A post retained crown may be indicated to fulfil these requirements. However, one mode of failure of tooth restored post is fracture.¹ Fracture resistance

of endodontically treated tooth is less than sound tooth due to their hard tissue loss because of caries, restorative and endodontic procedures. This tooth also has a higher chance for fracture because of their severe loss of dentinal moisture. In cases of severe hard tissue loss of endodontically treated tooth, using a post as the retentive factor for core build up is helpful.²

The maxillary incisors are usually damaged centrally or laterally. Traumatic accidents cause cracks in the crown at the facial side in 90% of the cases which extend to the cervical and palatal sides, just opposite to the mandibular incisors in which the crack extends lingually. Schmitter and Naumann et al reported that failure is more frequent in anterior teeth. This could be position in arch, the vertical overlap level and the frequent loss of posterior teeth.³

In recent years, more emphasis has been placed on the “ferrule effect” in the restoration of endodontically treated teeth with posts and cores. A ferrule has been described as a key element of tooth preparation when using a post and core. It is a generally accepted restorative strategy to include a ferrule in the design of the tooth preparation when restoring an endodontically treated tooth with a post and core and then restored with a crown⁴. Placing a ferrule around a preparation creates a protective ‘ferrule effect’, which has been claimed to ‘prevent shattering of the root’ of the abutment and aid in ‘providing resistance to dislodgment and preventing fracture. It has been stated ferrule can improve resistance on dynamic occlusal loading, maintain the integrity of the cement seal for the full crown retention, and reduce the potential for concentration of stress at the junction of the post and core.⁴⁻⁵

In addition, Raygot et al emphasized clinical cases where little or no coronal

tooth structure remained and crown lengthening or a sufficient ferrule could not be placed, post and core restoration served as the primary source of retention for a crown⁶. Breakthrough in dentinal adhesive technology in the recent past have built a new generation of bondable root canal sealers and post systems. Thus arose the concept of monoblock, in which the core material, post, sealing agent and the root canal dentine form a single cohesive unit. The closer contact between resin cement and the dentin wall, promoted by better adaptation of the post, simultaneously improve the contact area, which, consequently, increase the frictional retention. Improving the seal and fracture resistance of the filled canals.⁷⁻⁸

Ferrule

The ‘ferrule’ is the tooth structure that extends 1.5-2.0 mm in the occlusal direction from the projected ferrule margin, and will be encircled by the apical 1.5-2.0 mm of the intaglio surface of the crown or ferrule margin. The ferrule tooth structure, compared to post, core, cement, or resin bond materials, adds most substantially to the ability of a tooth, core, and post complex, after a ferrule or crown is placed on it, to resist fracture at the level of the ferrule margin, and also adds most to reducing the forces that a post places on a root after a crown is placed on a tooth, core, and post complex. The ‘ferrule tooth complex’ is the complex of tooth structure, and/or core material and/or post material that exists within the volume encircled

by the apical 1.5-2.0 mm of the ferrule margin. An adequate ferrule is necessary for a successful post-retained restoration. Several studies reported an improved resistance to fracture of endodontically treated tooth when an encircling ferrule was used with a post. The ferrule can reduce significantly the incidence of fractures in non-vital teeth by reinforcing the tooth at its external surface and redistributing applied forces which concentrate at the narrowest point around the circumference of the tooth. In addition, it helps to maintain the integrity of the cement seal of the crown.⁹

Various different ferrule designs have been suggested but currently there is a few researches supporting one design over another. Most publications discussed the required height of ferrule, however, other design characteristics like dentine thickness, location of the remaining dentine walls, and the load the restoration has to withstand were not considered. Posts are frequently used for the retention of a core material in teeth that have had extensive loss of coronal tooth structure. Their use, however, may increase root fracture due to excessive pressures during insertion or because of lateral movement of the post within the root, thus ironically increasing the risk of root fracture and treatment failure. Therefore, the use of a correct ferrule design is of particular importance in teeth restored with post and cores.¹⁰

Numerous studies have linked the ferrule design with various factors such as remaining dentine thickness and

distribution (Tjan & Whang), different designs of the cervical collar (Barkhordar et al., Sorensen & Engelman), ferrule height and configuration (Sorensen & Engelman, Libman & Nicholls).¹⁰⁻¹¹

Ferrule height

The overwhelming majority of the literature presents the importance of having enough height of dentine to be embraced by the crown. A ferrule of 1 mm of vertical height successfully doubled the resistance to fracture versus teeth without a ferrule, and appears to be the minimal acceptable amount of ferrule height. Other studies have shown the maximum benefit to be achieved out of having 1.5-2 mm vertical tooth structure. Some authors suggest that the crown must extend at least 2 mm beyond the tooth core junction to ensure a protective ferrule effect, or that even 3 mm of height provides even further fracture resistance. What seems clear is that the greater the height of remaining tooth structure above the margin of the preparation, the better fracture resistance provided.^{1,10-11}

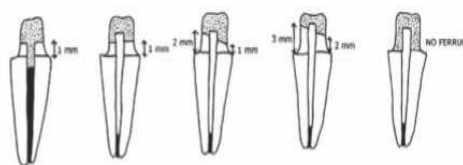


Figure. 1 different height of ferrule⁵

Based on the effective ferrule demonstrated by Sorensen & Engelman, the influence of ferrule length on resistance to preliminary failure was investigated

(Libman & Nicholls). The authors defined preliminary failure as the propagation of a crack in or around the luting cement of the crown. Twenty-five extracted maxillary central incisors were split into five groups; a control group and four test groups. The test groups had ferrule lengths of 0.5, 1, 1.5 and 2 mm. The teeth were prepared with 1-mm-wide shoulders. The test teeth had cast post and cores cemented and the control group did not. All the teeth were restored with cast crowns. The teeth were subjected to cyclic loading until preliminary failure was detected, using a strain gauge. The control group and the teeth with 1.5- and 2-mm ferrules were found to be significantly better than the teeth with 0.5- and 1-mm ferrules in resistance to preliminary failure. The authors concluded that 1.5 mm should be the minimum ferrule length when restoring a root-filled maxillary central incisor with a post-and core-retained crown.¹²

Libman & Nicholls paid particular attention to the shortcomings of some methods of in vitro testing. The use of cyclic loading in their study was based upon the rationale that failure within the dental complex was associated with repeated fatigue loads rather than a single fracture-inducing load. Furthermore, the ferrule height in the study was constant around the circumference of the tooth, which may differ from the clinical situation where the finish line follows the morphology of the interproximal gingivae. Study done by Libman & Nicholls were based on rigid

parameters. Their study used short (8-mm long) and narrow (1.25-mm diameter) posts and there was no simulation of periodontal support. Their finding of a 1.5-mm minimum effective ferrule may not be the case clinically.¹

Ferrule width

Esthetic restoration often requires fairly aggressive preparation at the gingival margin and sometimes buccal defects such as abfraction may compromise the buccal dentin wall. Generally it has been accepted that the walls are considered too thin if they are less than 1 mm in thickness, and would negate the ferrule effect. Therefore crown lengthening on teeth with conical roots may add dentin height but the dentin width at the margin may not be adequate.^{1,10-11}

Tjan and Whang looked at four groups of varying thicknesses: 1 mm, 1 mm with a 60° bevel, 2 mm and 3 mm of remaining buccal dentine. No significant differences were noted between the different groups other than that the two groups of 1 mm thick dentine were more likely to fail due to fracture rather than cement failure.¹³ Similarly Sorenson and Engleman in 1990 seemed to negate the importance of dentine thickness. However, their study looked at the thickness of dentine at the margin when using various contra-bevel ferrule designs, rather than at the thickness of the coronal extension of dentine. It is the thickness of the coronal extension above the crown margin that is thought to have significance

in the fracture resistance of crowned teeth.¹²

A laboratory study by Gegauff in 2000 investigated whether crown lengthening in decoronated premolars so as to achieve an acceptable ferrule height improved the fracture resistance of these teeth. He concluded that it did not improve the fracture resistance of these teeth.¹⁴ The question was raised by Hinkfuss and Wilson, whether the reason the ferrule did not prove to be effective in this study was because the teeth used in Gegauff's study were mandibular premolars. These teeth have conical roots, therefore although by performing crown lengthening, it will result in increase of dentine height results and a decrease in dentine width at the margin is inevitable after the tooth is further prepared for a new margin. This is possibly the cause for their poorer fracture resistance results. In their own study Hinkfuss and Wilson attributed the increased fracture resistance witnessed with the incorporation of a 2 mm ferrule to be attributed to the use of molar teeth with a thick amount of remaining dentine (2.4 mm). Perhaps the thickness of axial dentine after crown preparation has more of a role than previously thought. They concluded that further investigation needs to be done as to the effect of remaining dentine thickness on endodontic treated teeth prepared for crowns.¹⁵

Number of walls and ferrule location

Another aspect that should be re-thought is the assumption that a full 'all

around' ferrule is needed in every case. This has substantial clinical significance. Caries frequently affects some walls (primarily the proximal ones), but not others, and erosion and abrasion more commonly affect only the buccal walls. Similarly, tooth preparation aiming to achieve maximum aesthetics may result in remaining low and/ or excessively thin buccal walls. In each of these examples it is common for only a partial ferrule to remain after crown preparation.¹⁰⁻¹¹

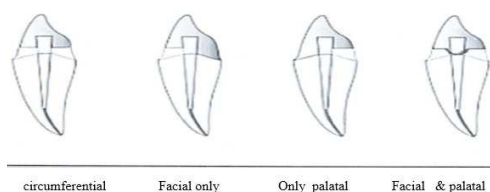


Figure. 2 different number of wall and ferrule location

The concept of partial ferrule should not be ruled out. The literature suggests that a non-uniform ferrule is still superior to no ferrule at all.¹⁰ Al-Wahadni et al in 2002 looked at the presence of a partial ferrule on anterior teeth. They compared no ferrule to 3 mm or more height of ferrule on the buccal surface alone. They concluded that teeth with retained buccal dentine of 3 mm height, but no other dentine walls remaining, had significantly higher resistance to fracture compared to the control. Heights greater than 3 mm did not produce statistically significant improvements.¹⁶

Ng et al. investigated the common clinical scenario of only a partial ferrule being present due to destruction by the

caries process. They suggest that it is the location of sound tooth structure to resist occlusal forces that is more important than having 360° of circumferential axial wall dentine. They depicted an in vitro replication of the maxillary incisor. Their results showed that having good palatal ferrule only is as effective as having a complete 'all around' ferrule, as this tooth structure will resist the forces applied in function to the palatal surface of the maxillary incisor¹⁷. Similarly, a maxillary incisor that is only missing the palatal wall despite the presence of three other favourable walls shows poor fracture resistance and is at greater risk of failing than some conditions with fewer walls remaining, for example when both the mesial and distal walls are missing. This is because when the palatal wall is missing, the non-axial load from the palatal side in a maxillary anterior crown challenges the post/core/root junction. When a palatal wall is present, it is the remaining wall that resists the load.¹⁰⁻¹¹

Alternative results, study done by Arunpraditkal et al. in 2009, negated the relevance of the site of the missing wall, when only one wall was deficient in having adequate ferrule. Their study showed that although the lack of a buccal wall displayed the poorest mean failure load, their result was not statistically significant. It should be noted, however, that even though their study did not find significance in the location of a single missing wall on mandibular second premolars, this study

was performed using a static load from the buccal direction which does not accurately reflect the clinical setting - neither the direction of the load nor the nature of the load. They acknowledge that the direction of the load may be the critical point and using a thermocycling/fatigue model may have more accurately depicted the clinical/functional setting.¹⁸ If this had been done, the missing buccal coronal wall may have had more significance than their results showed. Thus, there is evidence to suggest that a partial ferrule, although not as ideal as a full 360°, 2 mm ferrule, still has value in providing fracture resistance.^{10,18}

Monoblock system

The term monoblock literally means a single unit. The advancement in field of dental adhesion has led to birth of this concept in endodontics. Two prerequisites are simultaneously required for a monoblock to function successfully as a mechanically homogenous unit. Firstly, the materials that constitute a monoblock should have the ability to bond strongly and mutually to one another, as well as to the substrate that the monoblock is intended to reinforce. Secondly, these materials should have a modulus of elasticity that is similar to that of the substrate.¹⁹

The monoblocks created in the root canal spaces were classified as primary, secondary or tertiary depending on the number of the interfaces present between the bonding substrate and the bulk core material (Fig. 3). According to

this classification, a primary monoblock has only one interface that extends circumferentially between the material and the root canal wall. Mineral Trioxide Aggregate (MTA; ProRoot MTA, Dentsply, Tulsa, OK, USA) represents a contemporary version of the primary monoblock (Fig. 3a). Secondary monoblocks have two circumferential interfaces. Resilon is applied using a methacrylate-based sealer to root dentine and can be classified as a type of secondary monoblock (Fig. 3b). Tertiary monoblocks are the ones having an additional third circumferential interface between the bonding substrate and the abutment material. Fiber posts that contain either an external silicate coating or those that contain unpolymerized resin composite for relining root canals that are too wide or not perfectly round for the fitting of conventional fiber posts may be considered as tertiary monoblocks. Tenax Fibre post (Coltene) have a specific resin coating on its surface, which when cured with dual cure resin ParaCore (Coltene) forms a typical Tertiary monoblock: with one interface between the fibre post and the resin coating; the second one between the resin coating and the luting cement; and the third one between the luting cement and the root canal wall.²⁰⁻²¹

Another product that falls into this category is the EndoRez system (Ultradent), in which the conventional gutta-percha cones are coated with a proprietary resin coating. (Fig. 3c). In this system, conventional guttapercha cones are

coated with a proprietary resin coating.²⁰⁻²¹

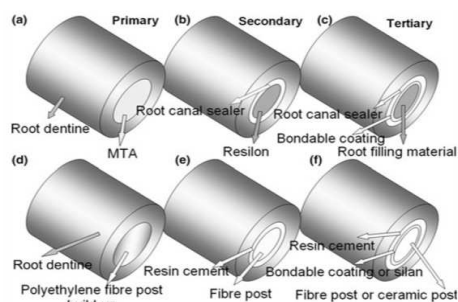


Figure. 3 Schematic representation of the monoblocks created in the root canal spaces classified as primary, secondary or tertiary depending on the number of the interfaces present between the bonding substrate and the bulk material core.¹⁴

In 2007, another adhesive obturating system was introduced commercially known as ActiV GP (Brasseler USA, Savannah GA, USA). It is a root filling system marketed as a monoblock system by using conventional Guttapercha cones that are surface coated with glass ionomer fillers composed of barium aluminosilicate glass powder and polyacrylic acid using a proprietary technique. By doing so, a stiffer Guttapercha cone is achieved that transforms it into a Guttapercha core/cone, enabling it to be functional as both the tapered filling cone and its own carrier core, thus avoiding the need for a separate interior carrier of plastic or metal. It is bonded to root dentine via a glass ionomer sealer creating a single cone monoblock obturation. It represents a tertiary monoblock system in which there are 3 interfaces between the bonding substrate and bulk material core.²²

Fisher MA et al reported that bond strength of Activ GP to the canal walls were significantly higher over other obturation systems.²³ In a similar study by Kazadang MK et al, it was observed that reinforcement with ActiV GP and RealSeal (Resilon) was significant when compared with unobturated prepared root.²⁴ Ghoneim AG et al reported that ActiV GP sealer used with normal Gutta Percha cone led to lower fracture resistance values as compared to ActiV GP sealer used with ActiV GP cone.²⁵ Thus presenting a strong case in favour of presence of tertiary monoblock formation as suggested in literature with added reinforcement.²²

Naumann et al, reported that post, core and the dentin have formed a unit called monoblock which will distribute the loading along the root more effectively and this is an advantage of bonded posts. This study was carried out with high precision to have homogeneity among the samples and the teeth were randomly classified into groups, despite all these efforts, it was impossible to have 100% homogeneous samples as there are lots of interfering factors involved such as the variety in humidity, the number of dentinal tubules, different extraction time and the root anatomy.²⁶

Discussion

Several studies have been performed on ferrule effects, many of them suggested that ferrule strengthens the teeth against functional, wedging and lateral forces

during post insertion. Ferrule length, with about 2 mm of the tooth structure above the shoulder finish line or gingival margin as ferrule is effective, but a few studies showed no effect of different ferrule designs on fracture resistance.

On the other hand, in the situation of a shorter root, these options may not be advisable. Saupe et al demonstrated that when a bonded resin system was used in structurally compromised teeth, there was no statistically significant difference in fracture resistance between postand-core restorations that used a ferrule and those without a ferrule.²⁷

In the study performed by Al-Amro and Wilson in 2009, regarding the effect of ferrule placement on fracture resistance of cyclically loaded bovine teeth restored with cemented cast post-cores and crowns, there was no difference in fracture resistance between ferrule and non ferrule teeth restored with crowns.²⁸

Lima et al conducted a study in 2010 on the influence of ferrule preparation with or without glass fiber posts on fracture resistance of endodontically treated teeth. They reported that there was no significant interaction between the ferrule preparation and post factors. The ferrule preparation increased the fracture resistance of endodontically treated teeth.²⁹

In a study carried out by Cho et al in 2009, on the impact of interproximal groove placement and remaining coronal tooth structure on the fracture resistance of

endodontically treated maxillary anterior teeth, it was reported that inclusion of interproximal grooves on the cast dowel and cores of endodontically treated anterior teeth with 1–2 mm of remaining coronal tooth structure does not significantly lower the failure threshold.³⁰

In 2007, the study by Dikbasi was performed on the evaluation of different ferrule designs on fracture resistance of endodontically maxillary central incisors with fiber post, composite cores and crowns. It showed that different ferrule designs have no effect on fracture resistance of teeth having fiber posts.³¹

Abbas MA et al compare the ferrule effect and two types of bonded post material. Results of the study showed that the teeth placed with titanium post generally has higher failure load than glass fiber reinforced composite post and teeth with 2 mm ferrule has higher failure load than without ferrule preparation even not statistically significant.³² Previous studies findings lead to the general consensus which need a 2 mm ferrule in prevention of fracture of the endodontically treated teeth. The ferrule preparation reinforces the tooth at the external surface by dissipating the forces that concentrate at the narrowest circumference of the tooth. It also resists lateral forces from posts and leverage from the crown in function, thus increases the retention and resistance of the restoration. However, with the production of new materials nowadays, this consensus might need revision. This current study found that

no significant effect of ferrule compared to previous studies, which may be due to several factors such as type of luting cement and methods and type of post. Previously, the posts were commonly cemented with conventional zinc-phosphate cement or resin modified glass ionomer cements. These materials depend on friction forces or chemical bonding for retention of the posts, but in this study, resin cement were used which adopt dentinal bonding system and could provide internal bracing of the root that becomes the substitute for the extracoronary ferrule. Few other studies found similar conclusion. Clinical benefits achieved by omitting the ferrule preparation includes minimize periodontal effect or trauma of extending the finishing line gingivally and also any tooth with minimal remaining coronal dentine not enough for ferrule preparation can be simply restored by bonding the post to the radicular dentine. This is a better option than crown lengthening procedures as it will not affect the crown-root ratio, more cost effective and less time consuming.³²

Conclusion

The ferrule preparation reinforces the tooth at the external surface by dissipating the forces that concentrate at the narrowest circumference of the tooth. Use of a correct ferrule design is of particular importance in teeth restored with post and cores. The concept of monoblock, in which the core material, post, sealing agent and the root canal dentine forms a single cohesive unit. The closer contact between resin cement

and the dentin wall, promotes better adaptation for post, simultaneously improve the contact area, which, consequently, increases the frictional retention.

References

1. Stankiewicz N R, Wilson P R. The ferrule effect: a literature review. *Int Endod J* 2002; 35: 575-58.
2. Mancebo JC, Castellanos EJ, Diego C. Effect of tooth type and ferrule on the survival of pulpless teeth restored with fiber posts: A 3-year clinical study. *Am J Dent* 2010;23:351-56.
3. Izadi ZM et al. Evaluation of the Effect of Different Ferrule Designs on Fracture Resistance of Maxillary Incisors Restored with Bonded Posts and Cores. *Journal of Dentistry* 2010;7(3):146-55.
4. Dikbas I et al. Evaluation of the effect of different crown ferrule designs on the fracture resistance of endodontically treated maxillary central incisors in incorporating fiber posts, composite cores and crown restorations. *J Contemp Dent Pract* 2007 Nov 1;8(7):62-9.
5. Sherfudhin H et al. Effect of different ferrule designs on the fracture resistance and failure pattern of endodontically treated teeth restored with fiber posts and all ceramic crown. *J Appl Oral Sci* 2011;19(1):28-33
6. Raygot CG, Chai J, Jameson DL. Fracture resistance and primary failure mode of endodontically treated teeth restored with a carbon fiber-reinforced resin post system in vitro. *Int J Prosthodont* 2001;14(2):141-5
7. Lara Ferro MC, Fracture Strength of Weakened Anterior Teeth Associated to Different Reconstructive Techniques. *Brazilian Dental Journal* 2016;27(5):556-61.
8. Sophia Tet al. The concept of monobloc in Endodontic - A review. *Journal of Dentistry* 2014;6(2):83-7.
9. Mamoun JS, On the ferrule effect and the biomechanical stability of teeth restored with cores, posts, and crowns. *Eur J Dent.* 2014 Apr-Jun;8(2):281-6.
10. Jotkowitz A, Samet N. Rethinking ferrule – a new approach to an old dilemma. *British Dental Journal* 2010;209:25-33.
11. Trushkowsky RD, Restoration of endodontically treated teeth : Criteria and technique considerations. *Quintessence Int.* 2014;45:557-67.
12. Sorensen J A, Engelman M J. Ferrule design and fracture resistance of endodontically treated teeth. *J Prosthet Dent* 1990;63:529-36.
13. Tjan A H, Whang S B. Resistance to root fracture of dowel channels with various thicknesses of buccal dentin walls. *J Prosthet Dent* 1985;53:496-500.
14. Gegauff A G. Effect of crown lengthening and ferrule placement on static load failure of cemented cast post-cores and crowns. *J Prosthet*

- Dent 2000;84:169-79.
15. Hinckfuss S, Wilson P R. Effect of core material and restoration design on strength of endodontically treated bovine teeth: a laboratory study. J Prosthodont 2008;17:456-61.
 16. Al-Wahadni A, Gutteridge D L. An in vitro investigation into the effects of retained coronal dentine on the strength of a tooth restored with a cemented post and partial core restoration. Int Endod J 2002;35:913-18.
 17. Ng C C, Dumbrigue H B, Al-Bayat M I, Griggs J A, Wakefi eld C W. Infl uence of remaining coronal tooth structure location on the fracture resistance of restored endodontically treated anterior teeth. J Prosthet Dent 2006;95:290–6.
 18. Arunpraditkul S, Saengsanon S, Pakviwat W. Fracture Resistance of Endodontically Treated Teeth: Three Walls versus Four Walls of Remaining Coronal Tooth Structure. Journal of Prosthodontics 2009;18:49–53.
 19. Singh H et al. “Endodontic Sealers”: Current concepts and comparative analysis. Dent Open J. 2015;2(1):32-7.
 20. Tay FR, Pashley DH, Monoblocks in root canals - a hypothetical or a tangible goal. J Endod. 2007 April ;33(4):391–8.
 21. Belli S, Monoblocks in root canals: a finite elemental stress analysis study. International Endodontic Journal 2011;44:817–26.
 22. Arora V et al. Effect of Adhesive Obturation and Post Obturation Monoblock Systems on Reinforcement of Peri-Cervical Dentin (PCD). International Journal of Biotech Trends and Technology 2015 Jan-Feb;8(1):1-6.
 23. Fisher MA, Berzins DW, Bahcall JK. An in vitro comparison of bond strength of various obturation materials to root canal dentin using a pushout test design. J Endod 2007;33:856-8.
 24. Karapinar Kazandag M, Sunay H, Tanalp J, Bayirli G. Fracture resistance of roots using different canal filling systems. Int Endod J 2009;42:705-10
 25. Ghoneim AG, Lutfy RA, Sabet NE, Fayyad DM. Resistance to fracture of roots obturated with Novel canal filling systems. J Endod 2011;37:1590-2.
 26. Naumann M, Preuss A, Rosentritt M. Effect of incomplete crown ferrules on load capacity of endodontically treated maxillary incisors restored with fiber posts, composite build-ups, and allceramic crowns: an in vitro evaluation after chewing simulation. Acta Odontol Scand 2006 Feb;64(1):31-6.
 27. Saupe WA, Gluskin AH, Radke RA Jr. A comparative study of fracture resistance between morphologic dowel and cores and a resin-reinforced dowel system in the intraradicular

- restoration of structurally compromised roots. Quintessence Int 1996;27:483-91.
28. AL-Amro AA, Wilson PR. Effect of ferrule placement on the fracture resistance of cyclically loaded bovine teeth restored with cemented cast post-cores and crowns. Eur J Prosthodont Restor Dent 2009 Sep;17(3):105-10.
29. Trushkowsky RD. Restoration of endodontically treated teeth : criteria and technique considerations. Quintessence Int 2014;45:557-67.
30. Cho H, Michalakakis KX, Kim Y, Hiriyama H. Impact of interproximal groove placement and remaining coronal tooth structure on the fracture resistance of endodontically treated maxillary anterior teeth. J Prosthodont 2009 Jan;18(1):43-8.
31. Dikbas I, Tanalp J, Ozel E, Koksall T, Ersoy M. Evaluation of the effect of different crown ferrule designs on the fracture resistance of endodontically treated maxillary central incisors in incorporating fiber posts, composite cores and crown restorations. J Contemp Dent Pract 2007 Nov 1;8(7):62-9.
32. Abbas MA, Bakar WZW, Masudi SM, In vitro evaluation of the ferrule effect and post material on failure load and mode in endodontically treated teeth. Dentistry 2014;4:3.

ROOT CANAL RETREATMENT OF A RIGHT MAXILLARY LATERAL INCISOR TEETH CAUSED OF INADEQUATE ROOT CANAL TREATMENT

Waviyatul Ahdi¹, Nilakesuma Djauhari²

¹ Post Graduate Student, Department of Conservative Dentistry,
Faculty of Dentistry Universitas Indonesia

² Lecturer, Department of Conservative Dentistry, Faculty of Dentistry,
Universitas Indonesia

ABSTRACT

Root canal retreatment is performed if inadequate initial treatment or presence of microorganisms in the root canal. Good root canal retreatment procedure plays a crucial role in the success of the root canal treatment. The primary aim of this article was to describe successful non-surgical retreatment of right maxillary lateral incisor teeth caused by inadequate root canal treatment. A 21-year-old woman was referred for root canal retreatment of right maxillary lateral incisor to the Department of Conservative Dentistry. She felt pain while hit the spoon and biting on her anterior teeth since 2 weeks ago. Four years earlier, she had been treated and restored by a former dentist. A clinical examination showed composite restoration on tooth #12 and sensitive to percussion. The pre-operative radiograph showed underfilled obturation and diffused periapical radiolucency in the apex area. Considering the clinical and radiographic findings, our final diagnosis was chronic apical abscess et causa inadequate root canal treatment.

Teeth were retreated by remove out guttapercha using Hedstroem files and Eucalyptus oil solvents, followed by root canal preparation using protaper hand use, irrigation with 2.5% NaOCl, 17% EDTA and 2% Chlorhexidine, activated by Irrisafe ultrasonic, and Calcium Hydroxide used as a medicament. The root canal obturated with guttap percha and sealer with MTA Fillapex. On clinical examination, there are no clinical complaints and nor percussive or palpation sensitivity. On radiographic examination, the picture shows a reduced diameter of the periapical lesion. This condition indicates the success of retreatment.

Key Words: Root Canal Retreatment, Maxillary Lateral Incisor, Inadequate Root Canal Treatment

INTRODUCTION

Root canal treatment is performed if inadequate initial treatment or presence of microorganisms persisting in the root canal, usually accompanied by subjective complaints of pain, percussive sensation and palpation of soft tissue, and enlargement of periodontal lesions. Root canal treatment consists of procedures initiated by removing root canal material, enlarging and filling the root canals.¹ The proper use of tools and materials in root canal treatment greatly affects the outcome of treatment. In this case report, radiographically the root canal filling only reaches the middle third of the root and diffuse radiolucent features in periapical. Clinically, there is leak restoration that can also cause root canal treatment failure. Under these conditions, root canal treatment is required with dowel crown restoration with fiber post, to maintain the tooth and function in the oral cavity.

CASE

A female patient, age 21, came to the RSGMP Dental Conservation Clinic FKG UI with complaints of the maxillary front teeth, pain when hit the spoon and bite with the teeth since two weeks ago. The tooth has been treated 4 years ago due to caries. Patients have no history of systemic disease.

Objective examination showed restoration of class 2 composite resin in #12, negative vitality test, positive percussion, negative palpation and absence

of pocket. Radiographic examination showed wide radiolucency of the apex area to the middle third of the root on the distal side and underfilled obturation. Based on the subjective, objective and radiographic examination, the diagnosis was a chronic apical abscess et causa of incomplete root canal treatment. The treatment of this teeth is root canal treatment with dowel crown restoration.

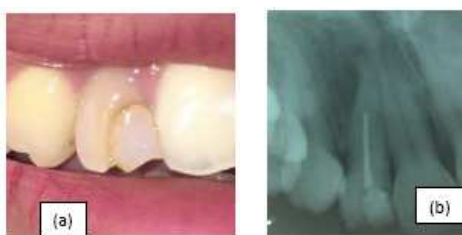

Figure 1. (a) Clinical features and (b) dental preoperative radiographic features 12

On the first visit, the teeth was accessed with bur diamond and diamendo (Dentsply Maillefer, Switzerland), visualization by using a dental loupe (Keeler) with 3x magnification and root canal irrigation by using 2.5% NaOCl. Determination of the estimated working length of the radiograph. Due to the filling of the root canal has long occurred, guttap percha tend to hard, then used Eucalyptus oil solvent. Eucalyptus oil is dripped into the root canal in the coronal section by using a syringe for 5 minutes.

By using the Hedstroem file, the filling of the root canal removed. Used of the # 25 Hedstroem file with circumferential filling motion (push-pull motion), followed by a smaller file # 20 until it is certain there is no guttappercha left in the file.

All guttapercha have been removed and the root canal checked again. After that, irrigation was done with saline solution. Radiograph examination was performed.

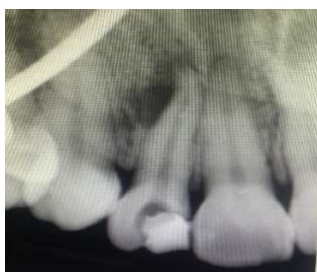

Figure 2. Radiographic feature after removal of the root canal filling on the teeth 12

After the root canal filling was removed and the root canal system was cleaned, the root canal negotiation was carried out according to the estimated working length (22 mm). Root canal preparation was done by crown-down technique. Flaring 2/3 corona root canals used Universal Hand Use Sx Protaper (Dentsply, Maillefer, Switzerland). Determination of actual working length used electronic apex locator ((VDW, Munich, Germany) and confirmed with photo radiograph using K-file #20, length 19 mm.

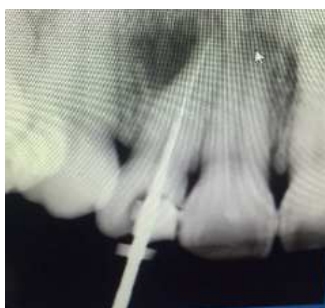

Figure 3. Radiographic feature of the actual length determination on the teeth 12

The initial file was K-file #25 with a working length of 21 mm. The root canal was prepared with Universal Use Hand Protaper (Dentsply, Maillefer, Switzerland) until the dentin was clean and obtained the master apical file (F5/21 mm). At each change of the file, irrigation with 2.5% NaOCl and rinse with aquabidest. Thereafter, master cone guttap percha (F5 / 21 mm) fitted to the root canal throughout the working length. The size of the master cone guttap percha is the same as the master apical file size and confirmed by the radiograph. The teeth were re-irrigated with 2.5% NaOCl, aquabidest rinse, 17% EDTA, aquabidest rinse, and lastly with 2% chlorhexidine (Cerkamed) with syringe and end-side vented needles in 2/3 root canals. Irrigation is activated with an Irrisafe ultrasonic file (Satelec) for 1 minute with in and out motion up to 2/3 of root canal length without any obstacles. The root canal was dried with paper points and medicament applications between visits with calcium hydroxide (Calcipect®, Nippon Sika-Yakuhin, Shimonoseki, Japan). The cavity was sealing with temporary filling materials (Cavition, GC Corporation, Japan).

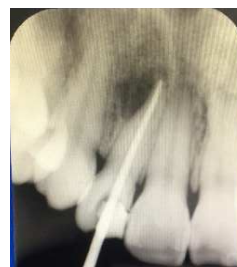

Figure 4. Radiograph feature of the master cone gutta percha on teeth 12

On the second visit, two days after the first visit, there is no subjective complaint, negative palpation and the percussion was positive but not as painful at first visit and. This indicates the process of healing on the previous treatment was already begin. Then injected anesthesia by using 2% lidocaine with epinephrine 1: 100.000 and applied the rubber dam. The temporary and old fillings were remove, and artificial wall with the composite resin prepared on the distal wall. The circumferencial filling is performed until working length. The root canal was irrigated with 2.5% NaOCl, aquabidest, EDTA 17%, aquabidest and lastly with 2% chlorhexidine (Cerkamed) and activated with ultrasonic instrument. The root canal was dried with paper points and applied medicament between visits with calcium hydroxide (Calcipex®, Nippon Sika-Yakuhi, Shimonoseki, Japan). Then the cavity was sealed with temporary filling materials (Cavition, GC Corporation, Japan).

Evaluation of dental treatment is no subjective complaints, negative percussion, and negative palpation. Temporary filling materials were removed and the root canal medicament was cleaned. Then the root canal filled with cold lateral condensation technique using gutta percha (Protaper® Universal Gutta Percha, Dentsply Tulsa Dental, Switzerland) and accessories con. The sealer used MTA fillapex. Once the root canal is filled, seal the cavity with the glass ionomer cement base and cover it with temporary fillings (Cavition, GC Corporation, Japan).

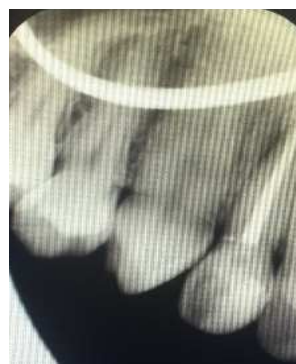

Figure 5. Radiographic features of root canal filling on the teeth 12

On the fourth visit, control post retreatment was performed with no subjective complaints from the patient, negative percussion on the teeth, negative palpation of the soft tissue and reduced diameter of the lesion on radiographic photo examination. After that, proceed with post-retreatment restoration with dowel crown. Measurement of the post length of the tooth was 15 mm from the reference point. Removed the obturation materials using gates glidden drill and used fiber drill throughout the post working length and evaluation used radiographic images. Post cemented in root canals using a self-etch self-bonded cement resin (Breeze). Evaluation of fiber post was done by radiographic images.

Next, the preparation of the tooth core used a composite resin and continued crown preparation for the final restoration using a straight flat cylindrical bur (2 mm incisal reduction, 1 mm buccal and palatal reduction and 0.8-1 mm shoulder edges). Double impression material in the maxilla and alginate in the antagonist jaw

used to duplicate tooth morphology. Bite registration and the appropriate color shade recorded. The temporary crown was done with composite resin. A week later, trials of dowel crown were done on the teeth.

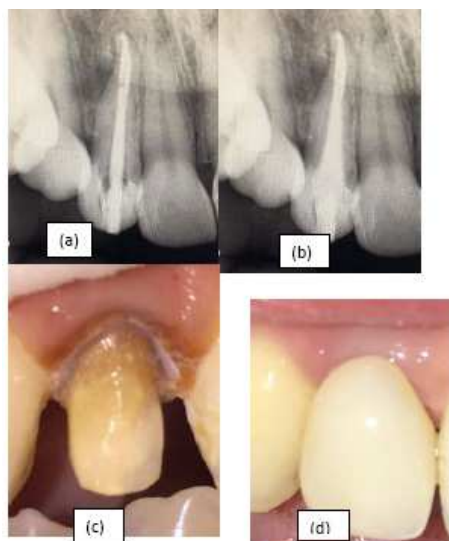


Figure 6. Radiographic and dental clinical images of the tooth 12. (a) Post experiment, (b) stake cementation with breeze, (c) clinical core photo, (d) dowel crown

DISCUSSION

Based on anamnesis, subjective, objective and radiographic examination concluded that the diagnosis, in this case, is a chronic apical abscess et causa inadequate root canal treatment. The condition the teeth with inadequate root canal treatment causes a re-infection of the root canal that triggers an inflammatory reaction to form a lesion around the apical foramen. Chronic infection causes the lesion to extend into the alveolar bone in the middle third of the root.

In the case of reinfection, generally, the bacteria that plays a crucial role is *E. faecalis*. These bacteria is gram-positive bacteria and anaerobic facultative. *E. faecalis* live and survive in a low nutritional environment in the long term. *E. faecalis* has resistance to antibiotics and able to survive in extreme environments with low pH.² *E. faecalis* is also capable of forming biofilms in the root canal, attached to collagen in the dentin and invading the fluid in the dentinal tubules so that these bacteria become resistant in the root canal.³ At pH 11.5, most of the *E. faecalis* bacteria will die. However, the ability of the dentin tubules buffer makes pH 11.5 difficult to achieve.⁴ Happasalo et al (2007) suggests that buffer capacity in dentine can stabilize pH.⁵ In addition, the survival of *E. faecalis* at high pH is associated with the presence of proton pumps. When negatively charged hydroxyl ions penetrate into the bacterial cytoplasm, there is an increasing pH. Then the proton pump works by moving the positively charged potassium ion into the cell to acidify the cytoplasm. It aims to prevent disruption of enzymes in the bacterial cytoplasm.⁴

In this case, *E. faecalis* persists because of the inadequate filling resulting proliferate, grow and develop bacteria, with nutrients obtained from the periapical tissue and from coronal leakage in the restorations. The condition of underfilled obturation result remaining necrotic tissue and debris caused by less of debridement and disinfection. Because the root canal

preparation is not working length, irrigation could not reach all areas of the root canal. Without adequate irrigation techniques, treatment also becomes ineffective. This is because the irrigation material is not activated so it could not remove all debris residue and dissolve organic, nonorganic and smear layer tissues. Activated irrigation can disinfect areas that could not be reached by endodontic instruments.

There are 3 kinds of removing guttapercha from the root canal, by using heat, solvent and mechanical instrumentation. Removing guttapercha with mechanical instrumentation could use Hedstroem, Rotary machine and Gates Glidden Drill files.⁵ The treatment in this case, the removal of filling material in the root canal by using the Hedstroem file and eucalyptus oil solvent.

Hedstroem files are hand instruments which made of stainless steel and have sharper spiral edges than K-files and have a positive rake angle on their flute so this file can efficiently cut and have screw effects into the root canal.⁶ However, Hedstroem files has a positive rake angle, resulting rough root canal wall. According to Bergenholtz et al (2010), Hedstroem files are used in a push-pull motion until the work length is reached.⁷ The consideration of using the Hedstroem files in this case because the filling only reaches the middle third of the root so that the filler tends to be easier to remove. The use of Hedstroem files could also reduce debris extrusion to apical and able to clean the root canals

cleanly.

In one study found hand use file with solvents was more effective at cleaning the root canal and avoiding debris extrusion to apical. The use of solvents is given because the root canal filling has been done long enough so that guttapercha is generally already fragile and hard. The selection of ideal organic solvents is widely considered for safety reasons of toxicity, biocompatibility and noncarcinogenicity. The eucalyptol solvent exhibits antibacterial and anti-inflammatory properties, and it is able to soften and dissolve the endodontic sealant. The eucalyptol dissolution capacity is slower than the commonly used solvents at room temperature. However, when heated, the dissolution effect may increase.⁸

After guttapercha is removed and the root canal is cleaned, preflaring is done to enlarge the coronal portion of the root canal up to 2/3 of the root canal. In most cases, the use of electric (apex locator) in ensuring the length of work is still in doubt. This is due to the cut off of apical barriers and residual root canal fillers. Files covered with fillers may affect the conductivity of the apex locator.⁹ Therefore, it should be combined using a radiographic image with a root canal instrument. However, the study states that once all fillers have been taken, the apex locator can be accurate again if using a clean file.

Having obtained a good length of work, repetition of the preparation is done. The goal is to form a tapered preparation,

but also maintain as much hard tissue as possible, especially at the apical end, and provide optimum conditions for root canal irrigation and obturation. Cleaning and shaping procedures focus on crown down techniques to minimize irritant extrusion into periradicular tissues. The crown-down technique also aims to enlarge the preparation coronal part so that apical debris can be taken entirely.⁶

Mechanical instrumentation is not sufficient to disinfect root canals. With the use of irrigation materials accompanied by activation with sonic/ultrasonic devices, good disinfection can be obtained. Chemical disinfection is an important basis for the success of a root canal treatment because it eliminates microorganisms within the dentin tubules and root canal ramifications.

Irrigation aims to remove residual debris, dissolve organic and nonorganic tissue and lubricate the root canal. Irrigation is also able to open the dentinal tubules by discharging the smear layer formed during instrumentation and disinfection and cleaning up areas that could not be reached by endodontic instruments.^{5,6} Irrigation materials that commonly used are sodium hypochlorite, chlorhexidine and EDTA.⁶

The additional irrigation used in this case is 2% chlorhexidine which has strong antibacterial activity against gram positive, gram negative, anaerobic facultative, aerobic and fungus. Chlorhexidine can diffuse into dentine. It has low toxicity properties and substantivity properties

so that the antimicrobial effects could be released gradually.¹⁰ The chlorhexidine substantivity is characterized by the ability to absorb onto negatively charged surfaces in the mouth (eg, teeth, mucosa, and restorative materials) and released slowly. This may prolong antimicrobial activity and the effect persists within a few days after treatment. Chlorhexidin has the potential to prevent bacterial colonization in a long time. Chlorhexidine can also damage the cell wall or the outer membrane of bacterial cells and invade the cytoplasm or membrane in bacteria. However, chlorhexidine is unable to dissolve organic tissues such as NaOCl.^{6,11}

Irrigation also needs to be activated with ultrasonic energy. The files are designed for oscillations with ultrasonic frequencies between 25-30 kHz. Ultrasonic use provides better root canal cleaning compared to hand-instrumentation. Ultrasonic tips can freely oscillate in the root canal. In this condition, acoustic streams that produce shear forces interfere bacterial aggregation (Plotino, 2007). In order to work effectively, ultrasonic files must move freely without contact with the root canal wall.⁶

After good preparation and irrigation with ultrasonic irrigation technique, the teeth medicate with medicaments which able to inhibit bacterial growth, reduce the remaining microbial biofilm and organic tissue and kill the remaining bacteria.⁶ The medicament is able to prevent recolonization bacteria in the root canal,

which left behind after preparation or through lateral canals.

In this condition, Ca(OH)_2 was used because it has a high pH (reach 12.5) and strong bactericidal. Ca(OH)_2 used when root canal preparation has reached the working length to allow direct contact with infected periapical tissue. High pH is able to support repair and activate calcification by neutralizing the lactic acid from osteoclasts. It prevents the dissolution of mineral components from the periapical region. The low of Ca(OH)_2 solubility causes the medicament could be last long. Ca(OH)_2 is capable of being a physical barrier thus avoiding reinfection of the root canal and disrupting the remaining supply of bacterial nutrients.¹²

When reacting, Ca(OH)_2 dissociates into calcium and hydroxyl ions. The calcium ion activate calcium-dependent adenosine triphosphate that causes calcium bind to carbon dioxide. The bond forms calcium carbonate crystals which important for mineralization. Calcium ions also cause a blood vessel pre-capillary contraction, resulting reduce the accumulation of exudate and supporting the healing process of the lesion. In addition, hydroxyl ions act as antimicrobials which capable of damaging the bacterial cytoplasmic membrane. The bacterial cytoplasmic membrane plays a role in metabolism, cell division and development. The hydroxyl ions are also capable of denaturing proteins, damaging DNA, and disabling endotoxins. The hydroxyl ions are able to activate

the alkaline phosphatase that produces phosphate ions and bind to the calcium ion for the bone mineralization process.¹²

Cold lateral condensation technique with guttapercha and fillapex MTA sealer used for the filling of the root canal. A hermetic root canal makes weaken bacteria trapped inside the root canal. According to Scarparo et al. (2010), this sealer can adhesion on dentin and has a good density so prevent leakage of periapical. The sealer also has an antibacterial effect on *E.faecalis*. However, it was also reported that MTA fillapex did not maintain antibacterial activity after 7 days. MTA fillapex is able to induce the formation of mineral tissue.¹³

In this case, there has been extensive coronal destruction and root canal treatment. Therefore, a dowel restoration is required to provide retention for the crown which obtained from the remaining crown structure of the tooth. The use of e-max (Ivoclar Vivadent AG, Schann, Liechtenstein) aims to gain high strength, excellent aesthetics and fracture resistance. The preparation of e-max used shoulder type because it has resistance to occlusal pressure and minimizes the stress that can trigger fracture.

Regular control through clinical and radiographic evaluation is a great way to evaluate the success of the treatment. In the case of healing of periapical lesions, a long-term evaluation of 1-4 years is required.⁹ In this case, treatment has a good prognosis because based on the clinical and radiographic evaluation, it appears tissue

repair. After 1 month retreatment, there is a reduction in the periapical lesion area. Evaluation of care should be done up to 1 year ahead.

CONCLUSION

In root canal retreatment, the elimination of microorganisms and adequate care is essential to prevent reoccurrence of secondary or persistent bacterial infection in the root canal. In this case with unhealing endodontic periapical lesions requires treatment of root canals. By doing a good root canal treatment procedure, the success of root canal treatment can be achieved.

Post-treatment after three months, clinical and radiographic evaluation showed good progress. On clinical examination, no clinical complaints, no inflammation of the gingiva, nor fistula formation, nor percussive or palpation sensitivity. Radiographic features show reduced lesion diameter. This indicates that the healing process of the lesion is going on the process. Thus, the teeth can be maintained and function normally.

DAFTAR PUSTAKA

1. Michael H, Edgar S. Problem in Endodontic. Etiology, Diagnosis and Treatment. Quintessence Pub; 2009. P. 435-439.
2. Jose F. Siquiera. Treatment of Endodontics Infection. Quintessence Pub; 2010. P. 125-133.
3. Walton RE, Torabinejad M. Principle and Practice in Endodontics. 4th ed. Penerbit Buku Kedokteran EGC; 2003. P. 340-356
4. Weckwerth P. H, Zapata R. O, Vivan R. R., Filho M.T., Maliza A.G, Duarte M.A. *In Vitro* Alkaline pH Resistance of *Enterococcus faecalis*. Braz. Dent. Journal. 2013; 24; 5.
5. Morgenta RD, Singh A, Kopper PM, Pelisser FV, Peters OA. Dentin Inhibits the Antibacterial Effect of New and Conventional Endodontic Irrigants. [Journal of Endodontics](#). 2013; [39:3](#): 406-410.
6. Hardgreaves KM, Cohen S. Cohen's Pathways of the Pulp. 11th ed. St. Louis, Missouri: Mosby Elsevier; 2015. P. 211-270, 324-382.
7. A. Kfir, I. Tsesis, E. Yakirevich, S. Matalon, I. Abramovitz. The Efficacy of Five Techniques for Removing Root Filling Material: Microscopic Versus Radiographic Evaluation. International Endodontic Journal. 2012; 45: 35-41.
8. [Hemant Kumar Yadav](#), [Rakesh Kumar Yadav](#), [Anil Chandra](#), and [Rahul Rameshbhai Thakkar](#). The Effectiveness of Eucalyptus Oil, Orange Oil, and Xylene in Dissolving Different Endodontic Sealers. [Journal of Conserv Dent](#). 2016; 19(4): 332-337.
9. Pitt Ford TR, Rhodes JS, Pitt Ford HE. Endodontics. Problem Solving in Clinical Practice. Martin Dunitz Ltd; 2002. P. 137-148.

10. SJ Ran, WL Jiang, CL Zhu.
Exsploration of the Mechanisms of
Biofilm Formation by *Enterococcus*
faecalis in Glucose Starvation
Environments. Australian Dental
Journal. 2015.
11. Gomes B, Vianna ME, Zaia AA,
Almeida JF, Souza-Filhp FJ, Ferra
CCR. Chlorhexidine in Endodontics.
Braz. Dent. Journal. 2013; 24 (2).
12. Bornsteins MM, Bingisser AC,
Reichart PA, Sendi P, Bosshardt D, Arx
T. Comparison between Radiographic
(2-dimensional and 3-dimensional)
and Histologic Findings of Periapical
Lesions Treated with Apical Surgery.
Journal of Endodontics. 2015
13. Morgenta R.D, Vier-Pelisser F.V,
Oliveira S.D, Antunes F.C, Cogo
D.M, Kopper P.M.P. Antibacterial
activity of two MTA-based root canal
sealers. International Endodontic
Journal. 2011; 44: 1128–1133.

LITERATURE REVIEW

A COMPARATIVE EVALUATION OF FRACTURE RESISTANCE OF ENDODONTICALLY TREATED TEETH OBTURATED WITH AH PLUS AND GUTTAFLOW SEALERS USING DIFFERENT OBTURATION TECHNIQUES: LITERATURE REVIEW

Yeamy Agustina Marpaung* Trimurni Abidin ** Indra N***

** Resident of Specialist Program of Conservative Dentistry*

***Lecturer of Specialist of Conservative Dentistry*

****Lecturer of Engineering*

Faculty of Dentistry, University of North Sumatra

Jln . Alumni No.2 Kampus USU Medan 20155

ABSTRACT

Endodontic therapy provides opportunities to maintain teeth in function and improve the health of the dentition. It would be advantageous, if the root canal obturation incidence could reinforce the tooth and decrease the incidence of root fractures. Endodontic post-treatment failures are nonhermetic filling, final restorative leakage and tooth fracture. Tooth fractures may occur after endodontic treatment due to chemical factors such as improper use of irrigation and medicaments, loss of tooth structure during root canal preparation, improper use of post and core effects, selection of sealer materials used. The current endodontic development involves the use of an adhesive sealer material that creates a monoblock system in the root canal. However, if the endodontic material is less adhesive to the root canal wall and guttaperca can result voids in the filling of the root canal, causing more easily occur fracture. Currently there are many sealers that are based on resins (*AH Plus*, *Dentsply*) that are adhesive, which is able to react with the amino group in collagen to form covalent bonds between the resins and collagen, but also develop a sealer based on mixture of gutta powder, Poly-dimethylsiloxane and silver particles (*Guttaflow*, *Coltene*) which have high flowing power so that there is a good adaptation to the wall of the root canal. The purpose of this article is to expose the comparison of fracture resistance from endodontically treated teeth to obturation using the Guttaflow and AH Plus sealer using different obturation techniques.

Keywords : Fracture Resistance, Obturation Techniques, Sealer, AH Plus, Guttaflow

INTRODUCTION

Successful root canal treatment depends on proper diagnosis, adequate cleaning and shaping and finally three-dimensional obturation of the root canal system. The long-term prognosis for endodontically treated teeth is greatly influenced by how well the coronal and apical seal are achieved. Root fracture, another reason for endodontic failure. Many *in vivo* studies have highlighted endodontic treatment as the major etiological factor for tooth fracture.^{1,2}

The risk factors for fracture predilection in endodontically treated teeth are (1.) Chemical factors: effects of endodontic irrigants and medicaments on dentine; (2.) Microbial factors: effects of bacteria-dentin interaction; (3.) Dentin factors: effects of tooth structural loss; (4.) Restorative factors: effects of post and core restorations and (5.) Age factors: effects of age changes in dentin.²⁻⁵

Thus, it would be advantageous if the root canal obturation could reinforce the tooth and decrease the incidence of root fractures. The type of root canal sealer may affect root fracture resistance and the pattern of root fracture.^{6,7,8}

Conventional root canal sealers do not bond strongly to dentin and gutta-percha, they do not behave as mechanically homogenous units with the root dentin.⁸ Interest in utilizing the classical monoblock concept for sealing and reinforcing the root canal space was rekindled with the advent

of bondable root filling materials that are advocated as alternatives to conventional gutta-percha. It is thought that adhesion and mechanical interlocking between the material and root canal dentin will strengthen the remaining tooth structure, and thus reduce fracture risk^{9,10,11}

The aim of this paper is to expose the comparison of fracture resistance from endodontically treated teeth to obturation using the Guttaflow and AH Plus sealer using different obturation techniques.

SEALERS

Sealers are used between dentin surfaces and core materials to fill spaces that are created due to the physical inability of the core materials to fill all areas of the canal. Traditionally desirable characteristics were to adhere to dentin and the core material as well as to have adequate cohesive strength. Newer generation sealers are being engineered to improve their ability to penetrate into dentinal tubules and bond to, instead of just adhering to, both the dentin and core material surfaces. Various types of delivery systems such as auto-mix syringes have improved not only the efficiency of mixing, but also the quality of the mix and ultimately the properties of the set material.¹²

Various types of sealers :

1. Conventional root canal sealer

Early sealers were modified zinc oxide–eugenol (ZOE) cements based on

Grossman or Rickerts's formula that were widely used throughout the world. Unlike the resin-based sealers, setting reaction of ZOE-based sealers is a chelation reaction occurring between eugenol and the zinc ion of the zinc oxide. This reaction might also occur with the zinc oxide phase of GP along with the calcium ions of dentin. This might explain the decreased setting shrinkage associated with the ZOE-based sealers.^{1,11,12}

Michaud et al. evaluated the three - dimensional expansion of GP at various powder/liquid ratios of Pulp Canal Sealer extended working time (EWT) (ZOE-based sealer) by using spiral (helical) computed tomography (SCT). They concluded that increasing the ratio of eugenol in sealer resulted in volumetric increase of GP. It is celebrated that the free eugenol component of freshly mixed ZOE sealer can seep out and cause various cytotoxic effects on human gingival fibroblasts, periodontal ligament (PDL) cells, and osteoblast-like cells. However, Haseih et al. reported that leakage of eugenol into periapical tissues is very low, and it dramatically decreases over time.^{11,12}

Sealing properties of ZOE ZnOE sealers were inferior in comparison to other sealers due to the relatively high solubility of the ZOE sealer; so, adhesion between GP and ZOE is weak in comparison to other sealers. Eugenol is cytotoxic and the same has been shown frequently for ZOE with different cell culture systems, especially after mixing, but also in a

set state. Even higher cytotoxicity was observed with formaldehyde-containing ZOE sealers, which were classified as highly/extremely cytotoxic. An ZOE sealer in the pulp chamber disinfected the dental tubules to a depth of 250 μm ^[18] and had a good antimicrobial property compared to other sealers.^{11,12}

2. Contemporary sealers are (1) AH Plus; (2) GuttaFlow; (3) MTA-based sealer; (4) EndoSequence bioceramic sealer; (5) Methacrylate-based resin sealer; (6) Calcium phosphate-based sealer; (7) Calcium-enriched mixture (CEM).

AH Plus

AH Plus consists of a paste-paste system, delivered in two tubes in a new double barrel syringe. The components of AH Plus The epoxide paste contains radiopaque fillers and aerosil. The amine paste consists of three different types of amines, radiopaque fillers, and aerosil.¹² AH Plus has shown positive results when compared to other sealers. It showed significantly lowest weight loss among the different root canal sealers in water and in artificial saliva with different pH values, independent of the solubility medium used. Furthermore, AH Plus showed the greatest stability in solution, as compared to the conventional sealers.^{10,12} AH Plus has a film thickness of 26 mm, which is clearly below the value of less than 50 mm required by the ISO standard for root canal sealing materials. AH Plus has been designed to be slightly thixotropic. A flow of 36 mm also

perfectly meets the requirements of the ISO standard (>25 mm).¹²

It is known from the literature that pure epoxy resins develop mutagenic activities under the conditions of the Ames test. Therefore, the epoxide paste (paste A) and amine paste (paste B) were studied in the Ames test, in which the aqueous extracts did not induce any mutagenic effects.¹² In numerous *in vivo* studies, the pure epoxy resins never showed any genotoxic effects. Recently, the antimicrobial effects of endodontic sealers (Endion, AH-26, AH-Plus, Procosol, and Ketac Endo) were investigated after 2, 20, and 40 days. AH Plus produced slight inhibition on *Streptococcus mutants* at 20 days and on *Actinomyces israelii* at every time interval. No effect was found on *Candida albicans* and *Staphylococcus aureus*.¹²

The studies showed that AH26 and Endomethasone sealers released formaldehyde after setting. Only a minimum release was observed for AH Plus (3.9 ppm), followed by EZ-Fill (540 ppm) endodontic cement and AH26 (1347 ppm) endodontic cement which yielded the greatest formaldehyde release.^{8,12} Due to its excellent properties, such as low solubility, small expansion, adhesion to dentin, and very good sealing ability, AH Plus is considered as a benchmark "Gold Standard."¹²

Guttaflow

In 1984, silicone was first introduced as a root canal sealer. A-silicones show

comparatively little leakage, are virtually non-toxic, but display no antibacterial activity. GP powder with a particle size of less than 30 nm has been introduced into a silicone matrix (polydimethylsiloxane (PDMS)). Silver particles have been added as preservative. Working time is 15 min and setting time is 25-30 min. GuttaFlow is a cold, fluid obturation system that combines sealer and GP in a single material. It consists of a PDMS matrix which is highly filled with very finely ground GP. PDMS has only limited dimensional change in setting (about 0.6%-0.15%) and low water sorption. The finely ground GP powder and the silicone-based matrix are distributed homogeneously after mixing. Guttaflow has very promising properties because of its insolubility, biocompatibility, post-setting expansion, great fluidity, and ability for providing a thin film of sealer, and hence greater adhesion with the dentinal wall.¹²

Guttaflow has nanosilver in its composition. Nanosilver is metallic silver which is distributed uniformly on the surface of the filling. It does not cause corrosion or color changes in the Guttaflow. There is sufficient nanosilver in the material to prevent further spread of bacteria and is highly biocompatible. Guttaflow also showed poor wetting on the root dentin surface because of the presence of silicone, which possibly produces high surface tension forces, making the spreading of these materials more difficult.^{11,12}

Guttaflow showed good

spreadability in the group where root dentin surface was treated with both ethylenediaminetetraacetic acid (EDTA) and sodium hypochlorite (NaOCl). The reason for this could be the increase in the surface energy of the root dentinal wall which was free of the smear layer. A GP containing silicone sealer expands slightly, and thus leakage was reported to be less than for AH 26 with GP over a period of 12 months. Dentin surface treated only with EDTA showed high contact angle value, suggesting the poor wettability of GuttaFlow. The high concentration of EDTA could have caused mild etching of the dentin surface leading to the exposure of collagen fibers, and the exposure of this hydrophobic moiety could have resulted in the increased contact angle.^{10, 12}

No data for systemic toxicity and allergy are available. However, based on the composition of the material, no adverse type reaction is to be expected.^{9,12}

Monoblock System of AH Plus and Guttaflow sealers in Endodontic Treatment

Replacement monoblocks created in the root canal spaces may be classified as primary, secondary and tertiary depending on the number of interfaces present between the bonding substrate and the bulk material core (Fig. 1).¹³ A primary monoblock has only one interface that extends circumferentially between the sealer and the root canal wall. Secondary monoblocks are those that have two

circumferential interfaces, one between the cement and dentin, the other between the cement and the core material. A secondary monoblock is the type of monoblock that is classically perceived in the restorative and endodontic literature.¹³

AH plus is used as a sealer with gutta-percha (primary monoblock) but Gutta flow is a first sealer/guttapercha combination which is flowable at room temperature that can be used as sealer without a solid master cone (primary monoblock) as well as obturating paste with gutta-percha (secondary monoblock).^{5,6}

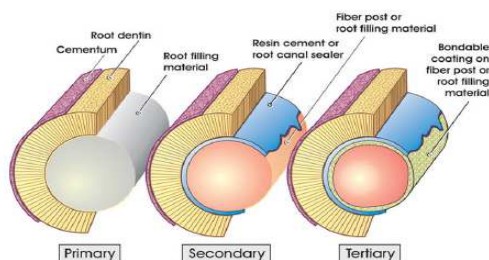


Fig.1. The schem of endodontic monoblocks classification (Tay at al, 2007)

Fracture Resistance of Endodontically Treated Teeth

According to Kishen at al (2006), the mechanisms and risk factors for fracture predilection in endodontically treated teeth are described under the following headings:

1. The mechanisms of fracture resistance in dentine
 - (1.1) Biomaterial considerations of dentine substrate

- (1.2) Biomechanical considerations in intact and post–core restored teeth
- 2. The risk factors for fracture predilection in endodontically treated teeth
 - (2.1) Chemical factors: effects of endodontic irrigants and medicaments on dentine
 - (2.2) Microbial factors: effects of bacteria-dentine interaction
 - (2.3) Dentine factors: effects of tooth structural loss
 - (2.4) Restorative factors: effects of post and core restorations
 - (2.5) Age factors: effects of age changes in dentine.

Kruzic et al. studied the fracture toughness properties of dentine, based on resistance-curve (Rcurve) behavior i.e. fracture resistance increasing with crack extension, particularly with different toughening mechanisms operating in the dentine. On the basis of this fracture mechanics based experiments, two types of toughening mechanisms have been suggested in dentine: (i) intrinsic and (ii) extrinsic. The intrinsic toughening mechanisms operate ahead of the crack tip and act to enhance the material's inherent resistance to microstructural damage and cracking. The extrinsic toughening mechanisms operate primarily behind the crack tip by promoting crack-tip shielding, which reduces the local stress intensity experienced at the crack tip. Basically, toughness is increased by mechanisms that increase the amount of energy required for fracture or methods that prevent strain energy from reaching the crack tip. It is

suggested that the viscous effects within the material will slow down the rate of delivery of energy to the crack tip so that the crack can be propagated only slowly and with difficulty. The movement of water from one site to another within the material falls in this category and seems to be a mechanism for toughening dentine.

Microcracking, crack blunting, and crack bridging by ligament formation and collagen fibrils are examples of extrinsic toughening mechanisms in dentine. Microcracking causes dilation and increase the compliance of the region surrounding the crack. Sharpness of the crack tip focuses strain energy onto the next susceptible bond and is an important factor governing fracture propagation. Crack blunting causes the stresses at the crack tip to be defocused. In crack bridging, as the crack opens, fibers or filaments extend across it, dissipating energy by their own deformation or by friction as they pull out from the bulk of the material. In addition, strain energy may not be transmitted to the crack tip if the shear stiffness of the matrix material is too low (evidenced by a Jshaped stress–strain curve, commonly found in soft tissues). Intrinsic mechanisms, such as crack blunting, tend to affect the initiation toughness, whereas extrinsic mechanisms, such as crack bridging, promote crack growth toughness. Hydration also increases the fracture toughness of dentin by extensive crack blunting, which elevates the crack-initiation toughness, and additionally from enhanced uncracked-

ligament bridging, which promotes the crack-growth toughness. In comparison, dehydrated dentin shows little blunting, which results in a lower crack-initiation toughness; however, with crack extension, significant crack bridging occurs, although the bridging does not develop as quickly as in the hydrated state. These investigations highlight that the collagen microstructure and the water of hydration are the foremost factors that contribute to the fracture toughness of dentine.

DISCUSSION

The strength of an endodontically treated tooth is directly related to the amount of remaining sound tooth structure and three dimension obturation. Although the use of gutta-percha with an insoluble root canal sealer can be considered as the gold standard of root canal fillings yet the ability of these materials to reinforce endodontically treated root is discussed with some controversy. Some studies have quoted the ability of different root canal filling materials to significantly strengthen the roots, where as in other investigations these materials did not increase the fracture resistance of root filled teeth . Hence, adhesive dental materials are now available that may offer an opportunity to reinforce endodontically treated tooth through the use of adhesive sealers in the root canal system.^{6,7}

Various materials have been advocated for obturation e.g. gutta percha, silver points etc. Gutta percha

has universally been accepted as the gold standard for root canal filling materials. However, formation of interfaces between sealer - gutta percha cones and sealer – internal tooth structure which on setting cause shrinkage of sealer and thus voids are created resulting in the absence of complete seal and increase fracture. Gutta flow is a first sealer/guttapercha combination which is flowable at room temperature that can be used as sealer without a solid master cone. Gutta flow contains gutta-percha particles in powder form, with particle size of less than 30 µm, and sealer (polydimethylsiloxane). The manufacturer claims a better seal and good adaptability because of good flowability and the fact that this material expands slightly (0.2%) on setting, enhancing its adaptation to root dentin walls. Rana et al. studied A high value of mean leakage score (0.69 mm) was observed in the Gutta Flow without master cone, with range of (0.4-1 mm). The cause for the high leakage scores would be poor condensation of the material because of absence of solid master cone up to apex of root.^{6,7}

Bonding endodontic obturation materials could enhance the ability of endodontically treated teeth to resist fracture . Rashmi et al studied AH plus and real seal root canal sealers are used which can increase the fracture resistance of endodontically treated teeth. Studies have shown that AH Plus can enhance the fracture resistance of endodontically treated teeth as it has the highest bond

strength to dentin. The high bond strength to dentin was because AH was able to react with the exposed amino groups in collagen to form covalent bond between the resin and collagen when the epoxide ring opens. AH plus, a product introduced by Dentsply is characterised by very good mechanical properties, high radio opacity, little polymerisation shrinkage, low solubility and not least a high degree of stability on storage.⁶

Kala et al. studied AH plus sealer as an epoxy resin-based sealer had the high fracture resistance than guttaflow because it had better flow properties because of its viscosity, its penetration into the microirregularities because of its creep capacity and long setting time, increases the mechanical interlocking between sealer and dentinal walls of the pulp space/ root canal. This fact, allied to the cohesion among sealer molecules, increases the resistance to removal and/or displacement from dentin, which can be translated as greater adhesion.¹ Fracture strength testing was done using a universal testing machine (Lloyd LR 50K, United Kingdom). A metal indenter of 5mm diameter was fixed to the upper arm of the universal testing machine which was set to deliver an increasing load until fracture occurred. A cross head speed of 1 mm/min was set and the load was applied vertically down to the long axis of the tooth. The force required to fracture each tooth was recorded in Newtons. The data thus obtained was evaluated statistically using One-Way

ANOVA and Tukey's Post Hoc tests to determine the level of significance between different groups.

Savariz et al. studied there were differences in the ability of GuttaFlow® and AH Plus™ to seal root canals when using cold lateral compaction or single-cone techniques. According to our results, AH Plus™ would allow more coronal filtration than GuttaFlow® at 120 days' time, with either lateral condensation or single-cone as the technique applied. In terms of apical filtration, the AH Plus™ sealer also presented greater filtration than GuttaFlow® in conjunction with both these techniques at 30 days. The good adaptation to the root canal walls and to the gutta-percha of GuttaFlow® could be attributed to its capacity to expand slightly on setting.^{7,8}

Elayouti et al. studied the Guttaflow capacity to expand slightly on setting and its increased flowability allow for good adaptation to the root canal walls and to the gutta-percha. Although it had a homogeneous composition, after setting it presented small porous areas or voids and it increased the low resistance fracture.⁶

Nunes et al. studied AH plus sealer has greater adhesion to root dentin than Epiphany. This is likely due to the fact that, as an epoxy resin-based sealer, AH Plus has better flow properties because of its viscosity, its penetration into the microirregularities because of its creep capacity and long setting time, increases the mechanical interlocking between sealer

and dentinal walls of the pulp space/ root canal. This fact, allied to the cohesion among sealer molecules, increases the resistance to removal and/or displacement from dentin, which can be translated as greater adhesion. The passive diffusion evaluation of tracers is the simplest and most commonly used technique to evaluate the sealing ability of root canal fillings and the longitudinal splitting of the root combined with dye penetration enhances demonstration of the pattern of dye penetration. Among the new techniques for preparation of the root canal, as well as new materials for root sealing, the single-cone method or the application of sealer as the only filling material are increasingly recommended procedures.^{6,7}

Deus et al. using lateral condensation, found that silicone-based sealers (GuttaFlow® and RoekoSeal) resulted in a lesser number of samples contaminated by human saliva than AH Plus™ or Pulp Canal Sealer after 9 weeks of storage. Edelniz et al. evaluated the resistance to bacterial penetration of different sealers with the single-cone technique, finding that GuttaFlow®, Epiphany® and Apexit® were more effective than AH Plus™, RoekoSeal, RCS, EndoRez® and Acroseal. Meanwhile, Bouillaguet et al. carried out a long-term comparison of the apical sealing capacity of different sealers in conjunction with the single-cone technique, reporting better results using GuttaFlow® and Epiphany® than with PCS and AH Plus™; according to these authors, the leakage

of AH-Plus™ may have resulted from inadequate bonding between the sealer and the gutta-percha point, allowing fluid to flow at the interface. However, the epoxy resin-based sealers have shown better adhesion to the root dentin than others groups of sealers. The epoxy resin-based sealer, like AH 26 or AH Plus™, is thought to be able to react with any exposed amino groups in collagen to form covalent bonds between the resin and collagen when the epoxide ring opens.^{11,13}

V. Conclusion

Under the present studies, we may conclude that the fracture resistance of teeth was lateral compaction obturated with AH Plus and GuttaPercha were significantly superior to teeth obturated with Guttaflow and GuttaPercha, but in the other hand there was a study that concluded GuttaFlow® shows a greater apical and coronal sealing capacity than AH Plus™. That is still a lot of controversy in previous research so that further research is needed to know the comparative evaluation of fracture resistance of endodontically treated teeth obturated with AH plus and Guttaflow using different obturation techniques.

REFERENCES

1. Kala M, Shaktidar PR Mds, Allappanavarkeerti S, Gupthanagendra Vr . A Comparative Evaluation of Fracture Resistance of Endodontically Treated Teeth Obturated with AH Plus with

- GuttaPercha, Guttaflow with GuttaPercha and Resilon Epiphany-an Invitro Study. *IOSR Journal of Dental and Medical Sciences*, 13(3), 2014 :54-8.
2. Hulsmann M, Peters OA, Dummer PM. Mechanical preparation of root canals: shaping goals, techniques and means. *Endodontic Topics*, 10, 2005: 30-76.
3. Kishen A. Mechanisms and risk factors for fracture predilection in endodontically treated teeth. *Endodontic Topics*, 13, 2006: 57-83.
4. Sedgley CM, Messer HH. Are endodontically treated teeth more brittle? *Journal of Endodontics*, 1992;18(7) : 332-5.
5. Peroz I, Blankenstein F, Lange KP, Naumann M. Restoring endodontically treated teeth with posts and cores- a review. *Quintessence int*, 36(9), 2005: 737-746.
6. Ricks-Williamson LJ, Fotos PG, Goel VK, Spivey JD, Rivera EM, Khera SC. A three dimensional finite element analysis of an endodontically prepared maxillary central incisor. *Journal of Endodontics*, 21(7), 1995, 362-7.
7. Chadha R, Taneja S, Kumar M, Gupta S. An in vitro comparative evaluation of depth of tubular penetration of three resin based root canal sealers. *Journal of Conservative Dentistry*, 15(1), 2012: 18-21.
8. Lertchirakarn V, Timyam A, Messer HH. Effects of Root Canal Sealers on Vertical Root Fracture Resistance of Endodontically Treated Teeth. *Journal of Endodontics*, 28, 2002, 217-219.
9. Tay FR, Pashley DH. Monoblocks in Root Canals: A Hypothetical or a Tangible Goal. *Journal of Endodontics*, 33(4), 2007: 391-8.
10. Wadhvani KK, Gurung S. Evaluation of root canal sealers on the fracture resistance of root canal treated teeth - An in vitro study. *Endodontology*, 22, 2010, 51-6.
11. Kandaswamy D, Venkateshbabu N, Krishna RG, Hannah R, Arathi G, Roohi R. Comparison of laterally condensed, vertically compacted thermoplasticized, cold free-flow GP obturations- A volumetric analysis using spiral CT. *Journal of Conservative Dentistry*, 12(4), 2009, 145-9.
12. Sanjeev Tyagi, Priyesh Mishra, Parimala Tyagi. Evolution of root canal sealers: An insight story. *European Journal of General Dentistry*, 2(3), 2013: 200-218.
13. Savariz A, Rodriguez M, Luque C. Long-term sealing ability of GuttaFlow versus Ah Plus using different obturation techniques. *Med Oral Patol Oral Cir Bucal*, 15 (6) : 936-41.

CASE REPORT: SURGICAL ENDODONTIC TREATMENT OF MAXILLARY CENTRAL INCISORS WITH LARGE PERIAPICAL LESION

Ekhtiyanto Cahyadi KY.¹, Ira Widjiastuti²

¹ Resident Department of Conservative Dentistry,

² Staff Department of Conservative Dentistry,
Faculty of Dental Medicine – Airlangga University, Surabaya

ABSTRACT

Background : In approximately 20 percent of cases that involve periapical lesions, nonsurgical endodontic treatment may simply not work due to the cystic nature of the lesions. Surgical endodontics is a reliable method for the treatment of teeth with periapical lesions that do not respond to conventional root canal treatment is not feasible. Successful outcomes have been reported in over 80% of cases in recent years. This case report describes periapical lesions in maxillary incisors (11 and 12) with large granuloma. **Case:** 38 years old male with uncomfortable taste and discolored teeth on maxillary incisors. Intra oral examination obtained teeth # 11 discolored changed. Overjet 6 mm, Radiographic examination showed periapical lesions in teeth #11 and #12. **Case management :** Teeth #11, will be treated with root canal treatment, apical surgery and it will be treated with internal bleaching. **Conclusion :** Apical surgery belongs to the field of endodontic surgery. Surgical endo surgery can be performed if there is a large periapical lesion which cannot be resolved by conventional endodontic re-treatment.

Keywords: Surgical Endodontic Treatment, Apex resection, Periapical Lesion

Correspondence author: Ira Widjiastuti, Staff Department of Conservative Dentistry, Faculty of Dental Medicine – Universitas Airlangga, Jl. Dr. Moestopo 47 Surabaya, ira-w@fkg-unair.ac.id

Introduction

Unsuccessful root canal treatment will cause periradicular inflammatory lesions to persist or increase after treatment.¹ There are approximately 20 percent of dental cases with periapical lesions treated with endodontic treatment failure, possibly due to the cystic nature of the lesion. This type of periapical lesion should be treated with surgical intervention.² Several studies have shown that there is an increased success in root canal treatment in dental

cases with periapical lesions with endo surgical intervention compared with tooth cases with periapical lesions without endo surgical intervention.³

Endodontic surgery is a reliable method for maintaining teeth with periapical lesions that do not respond by simply performing conventional endo measures or by orthograde MTA action. Surgical endo care has been reported with a success rate of more than 80 percent in

recent years.⁴ Endodontic surgery can be performed in situations such as: no conventional endodontic pathologic tissue disposal, a difficult crooked root condition with treatment measures root canals conventionally, handling conventional root canal treatment failures or conventional treatment accidents. One of the measures of an endodontic surgical procedure is apex resection or tooth root resection.⁵

Apex resection is cutting the tip of the root which aims to remove or lift the tissue that is thought to be pathological. Grossman (1995) suggests that root resection is the disposal of one or more roots of the upper first molars, Weine (1882) provides a definition of root resection as the removal of one root or root from many rooted teeth, Filipowicz (1984) states that resection root is the act of separating one or two roots from the teeth (molar) but the crown is kept intact. An apex resection is a minor surgical procedure intended to remove an infection tissue to a dead / dead root tooth or a failed root canal post.⁶

Not all teeth may be endodontic surgical and may even consult interdisciplinary linkages in determining the treatment plan for maximum results to be achieved.⁷ Endodontic surgical indication is extensive damage of periapical tissue, bone or periodontal membrane involving 1/3 or more the root apex of the tooth, the root canal instrument is broken on 1/3 of the root or blocked block of the pulp stone, the perforation on the 1/3 of the root canal, on a perfectly closed apex teeth and the

filling of the root canal is difficult to obtain good results due to trumpet root canals, the root canal becomes irritant because it enters the periapical tissue, the root canal has been treated and filled properly but there is apical periodontitis, a highly curved root canal with a refraction area, internal and external resorption of the tooth root. Overfilling of root canal, 1/3 apical fracture with pulp mortality, no negative seedling in endodontic treatment, presence of abnormalities in the periapical region of the tooth that has been dyed crown, crown and bridge.^{7,8}

Contra indications are that if the cutting of the root tip and curettage results in the support of the alveolar bone being greatly reduced, the teeth with deep periodontal sulcus and severe tooth agitation, there are periodontal abscesses, in areas that are difficult to achieve due to less widespread views, irreversible traumatic occlusion, endo-surgical procedures are repeatedly performed, the existence of systemic diseases that are contra indications for surgery.⁹

There are several methods that are influential or favored in the implementation of apex resection, each method having a slight difference, for example, leads to root filling before surgery, while the other leads to root canal filling during surgery after the root apex has been uncovered and resected, there is also one that leads to the manufacture of one type of flap only and some of which contain several other types of flaps, some are alveolar bone with bone

chisels while other operators use bur ; there is a coating of the root tip with silver nitrate, there is also a place sulfanilamide or antibiotics above the wound, there are also other opponents who close the wound only with surgical thread only and so on.¹⁰

The purpose of this article is to describe the successful disposal of pathological tissue on the periapical maxillary anterior teeth with apical resection technique

Case Report

A 38-year-old male patient came to the RSGM Airlangga University FKG Conservation Clinic with complaints of right upper teeth. Subjective examination of patients said to have fallen as a child, never treated and never sick, about three months ago the patient complained on the area of the tooth is often out of white fluid. On the objective examination, the dental 11 changes color, thermal test results with chlor ethyl negative, percussion examination and palpation results are negative. On radiographic examination, visible agent on the teeth 12 and 13, there are radiolucent features on the periapical region of the teeth 11 and the 42nd gear with a diameter of ± 3 cm, spherical and clearly bounded. Laboratory examination was obtained at bleeding time 2.5 minutes and freezing time 9.5 minutes with hba1c examination 4.5%.

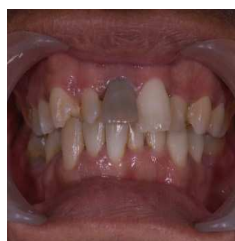

Fig.1 Clinical image prior to treatment

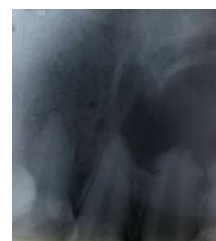

Fig.2 Periapical x-ray

Case management

In this case the management will be done is with root canal treatment first and then the next visit is the resection apex surgery, then continued with internal bleaching to equate the color of the teeth.

First visit

The acces opening action is then performed with a diagnostic wired photo, to find the working length of the tooth 11, the working length is known 19 mm, then continued with the root canal shaping with brushing motion using K-file with the largest number 100, each needle replacement is irrigated with NaOCl, EDTA, and Chlorhexidin in turn, followed by dressing using Ca (OH) 2, the patient was ordered 1 week later.



Fig. 3 Diagnostic Wired Photo

Second Visit

On the second visit, Ca (OH) 2 was cleaned and then irrigated with NaOCl, EDTA, and Chlorhexidine alternately until clean, followed by drying the root canal using paper point, then continued with obturation trial when it was in accordance with obturation length, control 1 week later.

3rd Visit

The plan for this visit was resection apex surgery, patient filling informed consent, blood tension examination where patient had blood pressure 120/80 mmHG, occupational asepsis, local anesthesia done block in palatinus minus and intra ligament at buccal area, semilunar flap making bending area, disclosure of flap using rasparatorium, with bur low straight handpiece and round bur done bone opening until obtained clear acces to periapical lesion area, the taking and curettage of periapical lesion followed by cutting periapikal tooth 11 with angle 0 ° to place the MTA material by orthograde , removal of gutta point by using piezoscaller as deep as about 3mm then followed by giving of MTA by orthograde, giving bone graft on bone cavity area formed by periapical lesion then followed by giving membrane bonegraft, and continued action of hect ing. Patients are advised to maintain oral hygiene, gargle with disinfectant and drugs taken by the rules. Patient control post 1 day operation.

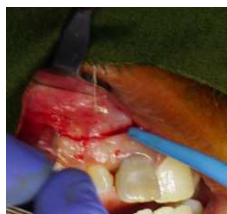

Fig. 4 Semilunar insicion

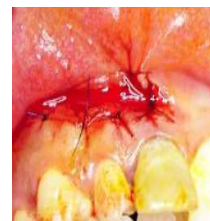

Fig. 5 Hecting result

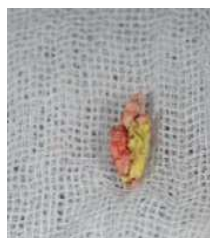

Fig. 6 nekrotik Mass

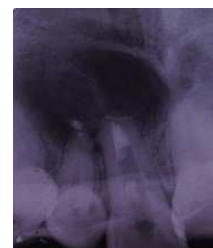

Fig. 7 Post apex resection x-ray with MTA



Fig.8 obturation x-ray

4th visit

There is swelling of the maxillary anterior region, pain (+), gingival pack is still in good condition, the patient is advised to continue drug therapy as appropriate. Patients were ordered 3 day postoperative control.

5th Visit

Swelling is negative, pain (+), patients are advised to continue drug therapy according to usage, gingival pack is still in good condition. Patients were ordered 7 day postoperative control.

6th Visit

Swelling (-), pain (-), opening of gingival pack then followed by removal of stitches. Followed by internal bleaching action by giving endobleaching materials, color determination, color 4M1 then tumpatan while in dispose, cavity base given glass ionomer, after that internal bleaching material applied, then cover with glass ionomer. Patients were told to control 3 days.

7th Visit

Glass ionomer fillings are still in good condition, the color of the tooth slightly changed whitish but still not equal to the neighboring teeth. So do re-application of internal bleaching material.

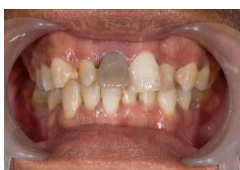

Fig. 9 Prior treatment

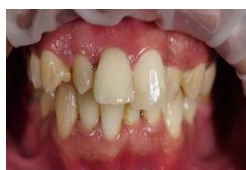

Fig. 10 Final treatment

Discussion

The purpose of the resection apex is to maintain a periapical tooth-damaged tooth by cutting off the root tip of an infected tooth.¹¹ The size of the infected periapical tissue in this causus is ± 2 cm.

The resection apex in this case is carried out by cutting the root tip of the tooth 11 and curation of the infected pertiapical tissue to ensure that all infection tissues have been removed in the hope that the infection will not grow again, followed

by the provision of bonegraft and wound closure by membrane administration prior to the tailoring .

Day 7 postoperative wound closes well, there is no sign of secondary infection, then proceed with internal bleaching treatment, which found there have been discoloration on gear 11 after 3 days. Because the color is still not the same then continued again the provision of internal materials bleaching to get the same color with the neighboring teeth.

Apeks resection is one of the reliable surgical endo measures for treating teeth with extensive periapical lesions. If there is a change of color on the dental care internal bleaching can be used as an alternative treatment to get a good aesthetic value.

References

1. Aznur L., *Bedah endodontik suatu pendekatan konservatif dalam penanggulangan kista yang lebih dari 2/3 panjang saluran akar gigi anterior*, Makasar Dental Jurnal, 2012:1 (4),
2. Fall E., *Contemporary Endodontic Microsurgery: Procedural Advancements and Treatment Planning Considerations*, American Association of Endodontists:2010, 1-7
3. Lin L., Ricucci D., Lin J., Rosenberg P., *Nonsurgical root canal therapy of large cyst-like inflammatory periapical lesions and inflammatory apical cysts*, J Endodon 2009:35, 607-15.

4. Maddalone M., Gagliani M., *Periapical endodontic surgery: a 3-year follow-up study*, International Endodontic Journal, 2003;36, 193-198,
5. Von Arx T., *Apical surgery: A review of current techniques and outcome*, The Saudi Dental Journal, 2011;23, 9–15
6. Widiyanta E., *Apikoektomi Gigi 12 dengan Anestesi Lokal*, CDK-190; 2012;39 (2), 121-123.
7. Dym H. *The Impacted Canine*, in *Atlas of Minor Oral Surgery*. Toronto: WB Saunders Co. 2001.
8. Walton RE. *Principles of Endodontic Surgery*. In: Peterson LJ. *Contemporary Oral and Maxillofacial Surgery*. 2nd ed. St.Louis: C.V. Mosby C:2003, 380-97
9. Atlas of apicoentomy: *Root Canal Treatment*. 2002. Available from: drdorfmann.com
10. Naik RR., Prashanth DM., *Techniques of root end preparation for the successful peri-radicular surgery: A literature review*, International Journal of Applied Dental Sciences 2016; 2(2): 06-10
11. Gonul O., Göker K., Aktop S., Garip H., *Surgical Treatment of Odontogenic Periapical Lesions*, A Textbook of Advanced Oral and Maxillofacial Surgery, 2015 (2), 209-234

CASE REPORT

MANAGEMENT OF TRAUMATIZED TOOTH WITH OPEN APICAL AND DISCOLORATION: A CASE REPORT

Farida Widhi Astuti¹, Edhie Arif Prasetyo²

¹Resident Departement of Conservative Dentistry

² Staff Department of Conservative Dentistry

Faculty of Dental Medicine, Universitas Airlangga Surabaya, Indonesia

ABSTRACT

Background: Trauma is the most etiology of pulp necrosis. Pulp Necrosis that appeared in an immature permanent tooth can lead to an uncompleteness apical anatomy which is characterized by wide root canal space and absence of apical constriction and sometimes discoloration happens on the crown. **Purpose:** To describe the clinical and radiographic appearance of open apical that was treated by Mineral Trioxide Aggregate (MTA) apical plug technique. And discoloration was treated by hydrogen peroxide with walking bleach technique. **Case:** A 49-year-old female patient came to the Department of Conservative Dentistry at Dental Hospital of Airlangga University with a non contributory medical history was referred for endodontic treatment in the right maxillary central incisor after trauma that occurred when patient at elementary school age. The chief complaints are bad esthetic with dark grey appearance and discomfort when smiling. The tooth has never been symptomatic. Clinical examination showed the right maxillary central incisor with dark grey appearance. Soft tissue surrounding tooth was normal. Periapical radiographic appearance shows wide open apice with periapical lesion. **Case Management:** Root canal treatment with debridement procedure by K-file 90#. The canal was irrigated by saline solution and a paste of calcium hydroxide was kept for one week as intracanal dressing. The apical portion of the canal was filled with MTA to create an apical plug/apical barrier, then obturated by the thermoplastic gutta-percha. Then walking bleach procedure was did in two cycles by 35% hydrogen peroxide gel resulting a good color of the tooth. Follow up periods at both 3 months and 6 months showed clinical and radiographic favorable response and absence of symptoms, there was no evidence of cervical resorption. **Conclusion:** MTA as an apical plug material is a good choice for open apical tooth and walking bleach technique was effective for discoloration problem.

Keywords: mineral trioxide aggregate, open apice, apical plug, discoloration, walking bleach, dental trauma

Correspondence: Farida Widhi Astuti, Resident of Conservative Dentistry, Faculty of Dental Medicine, Airlangga University. Email: faridawidhiastuti@gmail.com

INTRODUCTION

Trauma is the most etiology of pulp necrosis. Pulp Necrosis that appeared in an immature permanent tooth can lead to an incompleteness apical anatomy which is characterized by wide root canal space and absence of apical constriction.

Obtaining an optimal seal of the root-canal system is a major problem in performing endodontics in immature tooth with necrotic pulp and wide open apice. The initial aim of the therapy was to induce a hard tissue barrier at the tooth apex. This process is known as apexification. The aim of the procedure is to limit bacterial infection and create an environment conducive to the production of mineralized tissue in the apical region. In the past, calcium hydroxide is commonly used for this purpose. The conventional method of apexification with calcium hydroxide has certain disadvantages such as very long period of treatment, tooth fracture and an incomplete calcification of the bridge.¹

Recently, Mineral trioxide aggregate (MTA) as an apical sealing material has gained importance as an alternative treatment for open apice. It prevents the extrusion of filling material and also decreases the apical leakage. MTA is composed of fine hydrophilic particles that set in the presence of moisture.² As a material for perforation repair, MTA offers many favorable properties, including good sealing ability, biocompatibility, radiopacity, acceptable setting time (4 hours) and moisture resistance. It is

also capable of inducing the deposition of mineralized tissue, stimulating the regeneration of the dentin and providing satisfactory antibacterial activity.³

Crown discoloration is a common post-traumatic complication. A haemorrhage in the pulp chamber result from either a blow, death of the pulp. The penetration of blood into the dentinal tubules, followed by haemolysis of the red cells, which results in the release of haemoglobin and its breakdown products, produces a yellowish brown discolouration. This discolouration occurs when the iron pigments get degraded to iron sulfide.³

CASE

A 49-year-old female patient came to the Department of Conservative Dentistry at Dental Hospital of Airlangga University with complaints of the discolored and unaesthetic appearance of her upper anterior tooth. The tooth had suffered previously traumatic injury when elementary school age, for which she did not undergo any treatment. Her medical history was non contributory.

Clinical examination showed discoloration (dark grey) of the right maxillary central incisor (#11) with no mobility (figure 1). The tooth has never been symptomatic. Soft tissue surrounding tooth was normal. Periapical radiographic examination showed open apice with periapical lesion in tooth #11 (Figure 2).

From both the clinical and radiographic examination, the diagnosis was made as pulp necrosis with open apex in tooth #11.

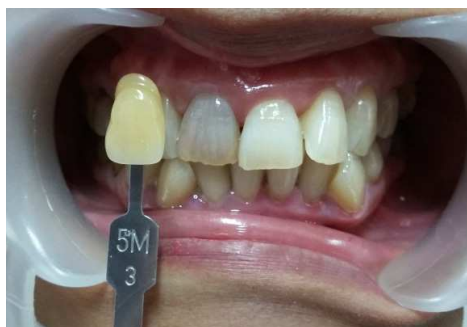

Figure 1: Pre-operative Clinical Appearance

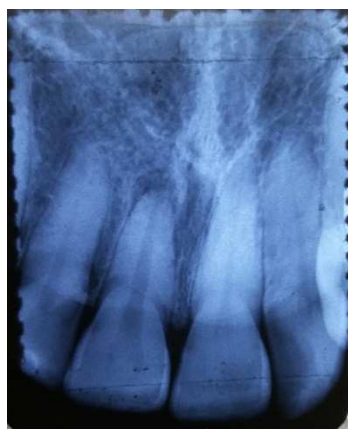

Figure 2. Preoperative periapical radiograph showing open apex with periapical lesion in maxillary right central incisor

CASE MANAGEMENT

The tooth was isolated by rubber dam, and access cavity was made, working length was established (Figure 3) and biomechanical preparation was completed with K-Files (Maillefer Dentsply, Baillaigues, Switzerland) along until #90 with copious irrigation using 2,5 % sodium hypochlorite solution and saline. Calcium

hydroxide (Ultracal-Ultradent, St. Louis, MO, USA) was used for dressing and a intermediary filling with Cavit (3M ESPE, Seefeld, Germany) (Figure 4).

The patient was recalled after one weeks. The calcium hydroxide was flushed with 2,5% sodium hypochlorite and saline. Final irrigation was done with 17 % EDTA, 3% Chlorhexidine and the canal was dried with paper points. MTA (Dentsply, Tulsa Dental, Johnson City, USA) was mixed according to the manufacturer's instructions and carried to the canal with a messing gun. A plugger was used to condense the MTA at the apex. A radiograph was exposed to confirm adequate placement of MTA to form an apical stop approximately 4 mm thick (Figure 5). A moist cotton pellet was sealed inside for setting of MTA and access cavity was sealed with Cavit .

After 1 day, the hard set of MTA was confirmed and the remainder of the root canal was obturated with injection thermoplastic (Beefill-VDW, Germany) and AH-Plus sealer (Dentsply, De- Trey, Konstanz, Germany) (Figure 6)

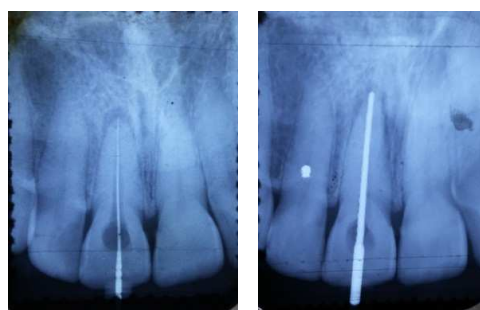


Figure 3. Working Length radiograph

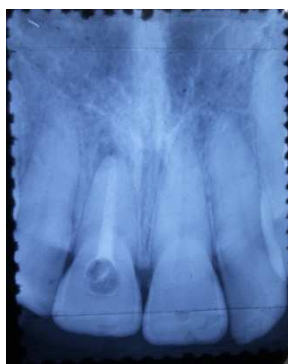

Figure 4. Calcium hydroxide dressing

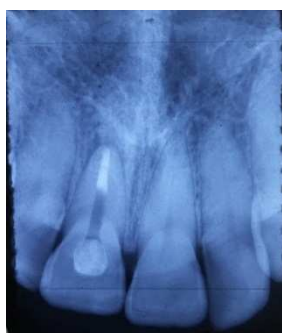

Figure 5. Radiograph confirming 4mm MTA apical plug

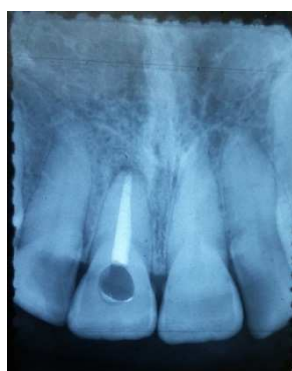

Figure 6. Radiograph after thermoplastic obturation

The endodontic treatment was done and recalled after seven days for internal bleaching procedure. Then walking bleach procedure was did in two cycles by 35%

hydrogen peroxide gel In the subsequent visit, the shade was noted (VITA 3D shade guide) . A rubber dam was applied to ensure the complete isolation of the tooth. Remove the temporary filling and Gutta-percha filling was removed from the access cavity to 2 mm bellow cemento-enamel junction with gates glidden drill (Dentsply Maillefer, Ballaigues, Switzerland).

A base of 2 mm glass ionomer cement (GC Fuji Plus, GC Corporation, Tokyo, Japan) was placed over the gutta-percha in cervical region to assure a mechanical barrier between the sealed root canal and the bleaching agent. The chamber was etched with 37 % phosphoric acid (Total Etch, Ivoclar Vivadent, Liechtenstein) for 30 seconds and it was washed and dried. Opalescence Endo gel (Ultradent, St. Louis, MO, USA), containing 35% hydrogen peroxide was placed in the pulp chamber and a piece of dry cotton was placed over and the access cavity was sealed with glass ionomer cement.

After 3 days, the tooth showed a definitive improvement in the shade, except at the incisal third tooth (Figure 7). So, the internal bleaching procedure was repeated and the patient was recalled after 7 days. The follow up showed significant improvement in the shade of the bleached tooth with satisfactory result (Figure 8). The Opalescence Endo was removed from the pulp chamber and the access cavity was dressed by Calcium hydroxide and temporary sealed with with Cavit.

After 3 week pulp chamber was rinsed with aquadest and the access cavity was restored by composite resin (Filtek Z350, 3MESPE, MN, USA).

Radiograph was taken to serve as comparison for the subsequent follow up visit. The Patient was asked to report after 3 months for review. No symptoms or signs were noted. Radiographic examination showed the external root resorption had been arrested.

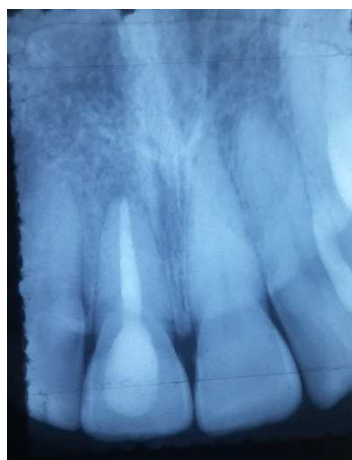

Figure 9. After 3 months follow-up radiograph

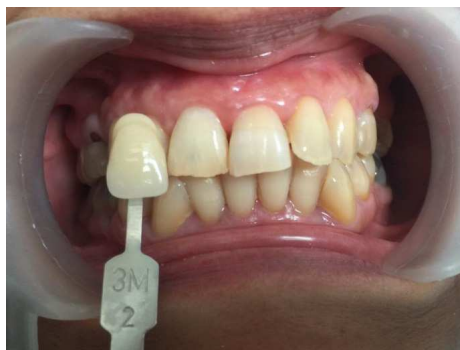

Figure 7. 3-days post internal bleaching

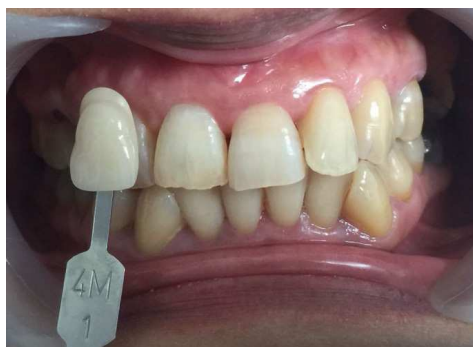

Figure 8. 7 day post internal bleaching

DISCUSSION

The purposes of calcium hydroxide dressing were disinfection, creation of a physicochemical barrier, and apexification. The calcium hydroxide dressing can also help control infection and maintain the root canal of high PH value an environment suitable for hard tissue formation and MTA setting. In addition to instrumentation and irrigation, the disinfecting action of calcium hydroxide is effective after its application for at least 1 week.⁵ Further treatment should not be delayed for more than 1 month because the calcium hydroxide could be washed out by tissue fluids through the open apice, leaving the canal susceptible to reinfection.⁶

An apical seal is important for the prognosis of root canal therapy. The purpose of placing an apical plug is to establish an effective barrier between the root canal and the periapical tissues.⁵ The case reported the applicability of MTA as

a material used for apical plug in infected immature tooth. The use of MTA presents some advantages, such as the possibility of its placement in as little as one visit or after 1 application of root canal dressings, thus eliminating the waiting time required for calcium hydroxide apexification. This advantage is especially relevant because it has been proved that the placement of a permanent restoration after a short treatment time serves to increase fracture resistance of the immature tooth. Also, calcium hydroxide long term treatment may increase the risk of root fracture.²

Root resorption may occasionally be detected as early as 6 months after bleaching. Early detection improves the prognosis since corrective therapy may still be applied. Bleached teeth should be frequently examined both clinically and radiographically. Some modifications have been done in an attempt to minimize the risk of cervical or apical resorption thus a base of 2 mm glass ionomer cement was placed over filling material of the root canal to have a mechanical barrier between the sealed root canal and the bleaching gel.⁷

The pulp chamber was filled by calcium hydroxide for one week before the final filling material. This was necessary to allow for elimination of residual oxygen, which interferes with the polymerization of the filling material and to neutralize and render the medium alkaline that reduces the risk of cervical resorption. During this period, the color of the bleached tooth should be stable.⁸

CONCLUSION

Placement of an apical barrier using MTA is an alternative to conventional long-term calcium hydroxide therapy, which reduces the treatment time. MTA apical plug can be considered very effective in stimulating regeneration of apical tissue in immature permanent tooth with open apices. Internal bleaching can be used as a very effective and safe post-endodontic treatment for discoloured anterior tooth.

REFERENCES

1. Giuliani V, Baccetti T, Pace R, Pagavino G. 2002. *The use of MTA in teeth with necrotic pulps and open apices*. Dent Traumatol 18:217-221.
2. Souza MA, Barbizam JV, Cecchin D and Scarparo RK. 2011. Mineral Trioxide Aggregate As an Apical Plug in Infected Immature Teeth: A Case Series. Rivista Odonto Ciencia 26(3): 262-266.
3. Ghaziani p, Aghasizadeh N and Sheikh_Nezami M. 2007. Endodontic Treatment with MTA Apical Plugs: A Case Report. Journal of Oral Science. 49(4): 325-329.
4. NeelaKantan P and Jagannathan N. 2012. Non Vital Bleaching – A Non Invasive Post Endodontic Treatment Option: A Case Report. Journal of Clinical and Diagnostic Research. 6(3):527-529.
5. Kuo TC, Cheng YA, Lin CP. 2004. Clinical Management of

Savere External Root Resorption.
Biomaterials.25 :787-793.

6. Trope M. 2010. Treatment of The Immature Tooth with a Non-Vital Pulp and Apical Periodontitis. Dental Clinics of North America 54:313-324
7. Ambalia SV and Ramgadhia HS. 2017. Nonvital Tooth Bleaching, Noninvasive Technique: A Case Report .Journal of Dental and Medical Sciences. 16(3): 80-82.
8. Plotino G, Buono L, Grande NM, Pameijer CH and Somma F.2008. *Nonvital Tooth Bleaching: A Review of the Literature and Clinical Procedures*. Journal of Endodontics 34(4): 394-407.

ROOT CANAL TREATMENT IN MAXILLARY SECOND PREMOLAR WITH CORONAL FLARING SHAPED OF THE TWO-THIRD ROOT CANAL

CASE REPORT

Dwi Arniawaty*, Dewa Ayu Nyoman Putri Artiningsih**

*Post Graduate Student, Departement of Conservative Dentistry, Faculty of Dentistry Universitas Indonesia

** Lecturer, Departement of Conservative Dentistry, Faculty of Dentistry Universitas Indonesia

ABSTRACT

Access to the complex root canal system is the first and the most important phase of root canal treatment procedure. Unfortunately, errors can occur in the preparation of an access cavity. Iatrogenic errors are might be the result of failure to follow the access guideline, or lack of understanding of the internal and external tooth morphology.

Root canal treatment on coronal flaring shaped of two-third root canal system requires a certain method of preparation and obturation to achieve the success of endodontic therapy. In this case, the maxillary second premolar with coronal flaring shaped of the two-third root canal, possibly because of iatrogenic error, which is diagnosed symptomatic apical periodontitis, treated with crown-down technique combined with circumferential filling. The obturation is using warm vertical compaction technique in order to achieve hermetically and three-dimensional root canal obturation. The result from this case shows that combination of crown-down and circumferential filing technique of root canal preparation and warm vertical compaction technique of obturation, significantly relief the symptomatic apical periodontitis and improve the prognosis of tooth survival.

Keywords: coronal flaring shaped of the two-third root canal, maxillary second premolar, circumferential filling, warm vertical compaction.

INTRODUCTION

The knowledge of common root canal morphology and frequent variations is a basic requirement for success during root canal procedures. The root canal morphology of teeth is often extremely complex and highly variable. Cleghorn et al

have shown that the variation in root canal system, including canal configurations of Vertucci, taurodontia, internal resorption etc had an irregular shape of cross-section. However, these irregular shape of cross-section root canal might be the result of an iatrogenic error by an operator while root canal preparation, such as overpreparation

(excessive removal of tooth structure). The complexities of root canal system create further challenges, emphasizing the necessity of disinfection measures, through access cavities, cleaning/shaping, and obturation. Designing and executing access cavities that give straight-line access to the main root canal is the first and crucial phase in root canal treatment. Unfortunately, errors can occur in the preparation of an access cavity. Iatrogenic errors are might be the result of failure to follow the access guideline or lack of understanding of the internal and external tooth morphology. Therefore, to achieve successful root canal treatment, clinicians must have adequate knowledge regarding normal root canal anatomy of the relevant tooth and its common variations.^{1,2}

In this case, the maxillary second premolar with coronal flaring shaped of the two-third root canal, possibly because of iatrogenic error, which is diagnosed symptomatic apical periodontitis, treated with crown-down technique combined with circumferential filing. The obturation is using warm vertical compaction technique in order to achieve hermetically and three-dimensional root canal obturation.

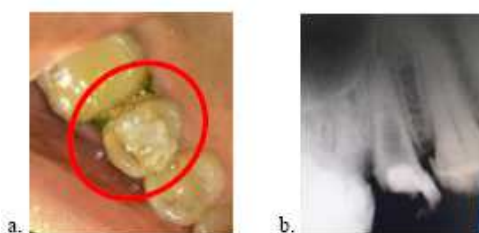
Circumferential filing is a method of filing whereby the instrument is moved first toward the buccal (or the labial) side of the canal, then reinserted, and removed slightly mesially. This continues around the preparation to lingual aspect and then to the distal until all the dentin walls have received planing. The purpose of circumferential

filing technique is removing necrotic or infected dentine of root canal and hard tissue removal by scraping against a side of the dentine wall, in order to obtain glassy smooth wall. This technique can be used for the oval or irregular shape of cross-section root canal, such as coronal flaring shaped, larger and/or not round canal. This technique enhances preparation when a flaring method is used by widening the orifice of the canal considerably, whereas the apical portion is kept relatively small. The use of filing action develops a preparation that is irregular, usually increasing any eccentricities in the original canal shape.^{3,4,5}

Warm vertical compaction is a more complex obturation technique, comparable to lateral condensation in its sealability. With the introduction of the new device, the warm vertical compaction technique has become less time-consuming. In general, vertical compaction can be used in the same case as lateral condensation. It is preferred in a few circumstances, such as root canal with internal resorption or other situations involving internal morphologic complexities. Schilder introduced warm vertical compaction technique as hermetic three-dimensional obturation. The principal advantage of vertical compaction over lateral condensation is the ability to adapt the warmed dan softened guttap percha to the irregular surface of root canal system, accessory or lateral canal.

CASE REPORT

A 47-years-old female was referred to the Conservative Dentistry Faculty of Dentistry Universitas Indonesia. The patient's chief complaint was painful on the maxillary right second premolar, especially when used eating and/or contact with the antagonist. Besides, there was food impaction next to maxillary right second premolar. Dental history of patient was already taken root canal preparation about 8 months ago but not finished yet. Clinical examination revealed a MOD (site 2, size 2) GIC filling in maxillary right second premolar and there was food impaction between maxillary right second premolar and maxillary right first molar, moderate tender to percussion but normal in palpation. the preoperative radiograph showed coronal flaring shaped until the one-third middle of root canal, thus looked thin dentine wall in mesial-distal perspective. There was no filling material yet in root canal, with lost of lamina dura in a distal side and 0,5 mm radiolucent appearance in periapical.



Picture 1. a. Clinical manifestation pre-operatif of tooth 15, b. radiograph pre-operatif

A diagnosis of symptomatic apical periodontitis was made and non-vital root

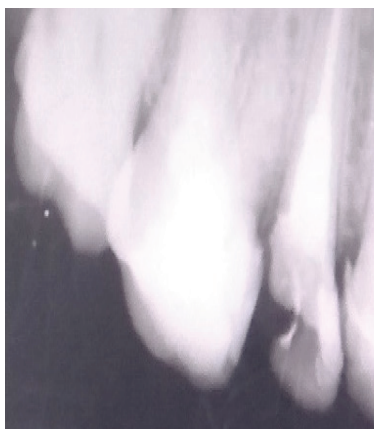
canal treatment was planned for tooth 15.

On the first appointment, after subjective and objective examination, a dental dam was applied in tooth 15 followed by removing MOD GIC filling. With better magnification using a dental loupe, orifice looked in the one-third middle of root canal to more palatal aspect. Determination of working length was using apex locator mini root ZX (Morita) verified with radiography. The initial file was #20/19mm. A slight mechanical preparation was performed to clean the one-third apical until the one-third middle of root canal using crown-down technique using protapper next files and circumferential filing technique was used to prepared one-third middle until one-third coronal of root canal with K file ISO #40. Irrigation with 2,5% sodium hypochlorite, saline and EDTA 17% followed by sonic activation (endoactivator) improved the debridement of root canal while root canal preparation. Master Apical Cone of tooth 15 was #X4/19 mm and a digital radiograph was taken as verification. Chlorhexidine 2% was used as final irrigation and calcium hydroxide as intracanal medicament followed by temporary restoration.



Picture 2. a. Tooth 15 after removal MOD GIC filling, b. radiograph of verified working length using guttap percha ISO #20, c. Radiograph of master apical cone #X4/19mm

On the second appointment, two weeks after the first one, there was no subjective complaint such as painful when eating or contact with antagonist tooth and normal to percussion. Removal of the temporary restoration under isolation with a dental dam. Debridement of calcium hydroxide paste was made using endodontic files under gentle irrigation with 2,5% sodium hypochlorite. Obturation was used warm vertical compaction technique which is initiated by single cone #X4/ 19mm, and MTA fillapex as obturation sealer, a heat endodontic spreader was used to cut #X4 until the two-third of root canal (10 mm from buccal cusp), then vertically condensation with cold endodontic plugger. A thermoplastic guttapercha was injected into root canal to fulfill two-third coronal until orifice and vertically condensation again with cold endodontic plugger. Digital radiography was taken to evaluate obturation of tooth 15, and continued with an application of GIC Fuji IX as a coronal seal.



Picture 3. Radiograph after obturation using warm vertical compaction

Two weeks recall, the clinical evaluation was taken with negative test in percussion, palpation and normal appearance of gingiva. In this case patient was planned used custom dowel crown as endodontic restoration.

DISCUSSION

Successful and predictable endodontic treatment requires knowledge of biology, physiology and root canal anatomy. In this case, tooth 15 was already taken root canal preparation but not finished yet. From evaluation of clinical and radiograph finding, the shaped of two-thirds of root canal was coronal flaring shaped. This shaped, probably as manifestation of iatrogenic errors such as excessive removal of dentin wall structure of two-thirds.¹

Irregular shaped of tooth 15 need certain root canal preparation and obturation in order to achieve successful root canal treatment. The crown-down technique with Protaper Next file for cleaning and shaping one-third middle until apical region. Crown down technique was chosen in this case to keep funnel-shaped of root canal, with less extruded debris into periapical. Besides, removes the majority of tissue and microbes before the apical third is approached, improves tactile awareness during apical preparation and create better and deeper penetration of irrigation. Protaper Next file was used in this technique because of design instrument of Protaper Next was made from M-wire technology that improves the resistance

to cyclic fatigue by almost 400% when comparing files of the same tip diameter. A unique offset mass of rotation, off-centered, rectangular cross section giving the file a unique, snake-like swaggering movement. This improved action creates an enlarged space for debris removal and initiated activation of irrigation while root canal preparation.^{3,8}

The circumferential filling was used to cleaning and shaping one-third coronal until the one-third middle of root canal using K file ISO #40. This technique was used for oval or irregular shape of cross-section root canal, such as coronal flaring shaped, larger and/or not round canal. In this case of tooth 15 with coronal flaring shaped on two-third root canal and thin dentine wall in mesial-distal perspective in 3600 fo a couple time, circumferential filing enhanced preparation when a flaring method is used by widening the orifice of the canal considerably, whereas the apical portion is kept relatively small. The function of this technique was to create smooth dentine wall of the whole buccal, mesial, palatal and distal aspect which cannot achieve maximally only from crown down technique using protpper next. Scraping in-out movement in circumferential filing aims to create smooth in all dimensions to eliminate necrotic and infected dentine wall. Irrigation of sodium hypochlorite 2,5%, EDTA 17 %, chlorhexidine 2% and calcium hydroxide as intracanal medicament was maximizing root canal debridement.

Schilder describes the final objective of endodontic procedures as being the total obturation of the root canal space. The following total debridement of the radicular space, the development of a fluid-tight seal of the apical foramen and the total obliteration of the root canal must follow to ensure the best chance of long-term success. The obturation in this case was warm vertical compaction had advantages that were fitting master apical cone and thermoplastic guttap percha in order to achieve hermetically and three-dimensional root canal obturation. Vertical compaction techniques use heat sources for both their downpack and backpack oburation. This method, results in a more fluid guttap percha, allowing a better flow of the material under compaction and therefore improved obturation. Wong et al in his study concluded the homogeneity of guttap percha without sealer obtained from warm vertical compaction technique compared to choloropercha and lateral condensation. Friedman et al. suggest that there is a 10% improvement in post-obturation treatment with warm vertical compaction for cases of apical periodontitis versus lateral condensation. Since Schilder introduced the warm vertical compaction technique, Glickman and Gutmann developed this obturation method with the addition of a special heat-conducting instrument and for placing the thermoplastic guttap percha on a three-dimensional hermetic root channel system. According to Budd et al, the addition of hot temperature to guttap-percha (guttap percha thermoplastic) from

warm vertical compaction technique can create the movement of plastic guttapercha inside root canal, so as to fill the irregular root canal and produce better apical seal.^{7,10} Warm vertical compaction also has disadvantages such as need for specific instruments, lack of control to maintain working length, excessive vertical pressure or condensation can potentially cause root fracture, as well as the possibility of extrusion of root canal into periradicular tissue.^{8,11}

CONCLUSION

In this case, coronal flaring shaped of two-third root canal system of maxillary right second premolar requires a certain method of preparation and obturation to achieve the success of endodontic therapy. Root canal preparation used combination of crown-down using protapper next file and circumferential filing using K file ISO, while the obturation used warm vertical compaction technique. A proper root canal treatment and prompt restoration post endodontic treatment, significantly relief the symptomatic apical periodontitis and improve the prognosis of tooth survival.

DAFTAR PUSTAKA

1. Cleghorn BM, Goodacre CJ, Christie WH. Morphology of Teeth and Their Root Canal Systems. In: *Ingle's Endodontics* 6. 6th ed. Washington: BC Decker; 2010:200.
2. Gutmann JL, Fan B. Tooth Morphology , Isolation , and Access. In: *Cohen's Pathways of the Pulp Expert Consult*. 11th ed. Elsevier Inc.; 2015:130-208. doi:10.1016/B978-0-323-09635-5.00005-1.
3. T W, Johnson, Anne E. Williamson. Cleaning and Shaping. In: *Endodontics: Principles and Practice*. 4th ed. St.Louis Missouri: Saunders Elsevier; 2009:230. <https://books.google.co.id/books?id=bbuYu0IX-EwC>.
4. Weine FS. *Endodontic Therapy*. 5th ed. St. Louis, Missouri: Mosby; 1996. <https://books.google.co.id/books?id=BdBpAAAAMAAJ>.
5. Paper C. Endodontics: Part 5 Basic Instrument and Material For Root Canal Treatment. *Br Dent J*. 2004;197. doi:10.1038/sj.bdj.4811738.
6. Blum J, Parahy E, Machtou P. Warm Vertical Compaction Sequences in Relation to Gutta-Percha Temperature. *J Endod*. 1997;23(5).
7. Fred W. Benenati. Obturation of the Radicular Space. In: *Ingle's Endodontics* 6ed. Washington: BC Decker; 2010:200.
8. Torabinejad M, Walton RE. *Endodontics Principles and Practice*. 5th ed. St.Louis, Missouri: Elsevier Saunders; 2015.
9. Wu M, Sluis LWM Van Der, Wesselink PR. The capability of two hand instrumentation techniques to remove the inner layer of dentine in oval canals. *Int Endod J*. 2003;36:218-224.

10. Attela MH, Saba AA. Pst Treatment Radiografic and clinical Evaluation of Matched-Taper Single-Cone versus Warm Vertical Compaction Technique: a One-Year Follow up Study. *Journal of Dental Health, Oral Disorder and Therapy*. 2015; 3(2).
11. Johnson W, Kulild JC, Tay F. Obturation of the Cleaned and Shaped Root Canal System. In: *Cohen's Pathways of the Pulp Expert Consult*. 11th ed. Elsevier Inc.; 2015:280-322. doi:10.1016/B978-0-323-09635-5.00007-5.

APEXIFICATION WITH MINERAL TRIOXIDE AGGREGATE (MTA) AND INTERNAL BLEACHING ON RIGHT UPPER CENTRAL INCISIVUS TOOTH WITH DISCOLORATION

Elisabeth Reni* dan Pribadi Santosa**

¹Post Graduate Student, Department of Conservative Dentistry, Faculty of Dentistry
Universitas Gajah Mada

² Lecturer, Department of Conservative Dentistry, Faculty of Dentistry,
Universitas Gajah Mada
email: reni.nursari@gmail.com

Background: traumatic injuries occurred during root completion process on young permanent teeth often lead to pulpal necrosis, and thus has adverse effect to the closure of the tooth apical foramen. Treatment of choice most commonly used for the case is apexification using mineral trioxide aggregate (MTA). MTA is the novel material widely used in apexification instead of calcium hydroxide because of its ability to form physical apical barrier more quickly. **Purpose:** This case report was presented to show the success of apexification using MTA in discolored upper right central incisor. **Case Management:** A 19 years old male patient was presented to the conservative dentistry department complained about his discolored upper right central incisor. The radiograph showed that the apical foramen was not completely formed and radiolucency was found in periapical. Objective findings showed that the crown was intact with no caries but Ellis Class IV Tooth Fracture was found, negative result showed on periradicular test (palpation and percussion) and thermal test as well. Apical plug was done using MTA and the root canal was obturated using thermoplastic obturation technique. Internal bleaching was done a week afterwards and tooth color shade was changed from brownish D4 to whitish A1. Tooth was restored using composite resin with prefabricated fiber post was used as intracanal reinforcement. Two weeks post treatment evaluation was done and no symptoms was found and clinical examination showed the tooth was in normal condition. **Conclusion:** MTA can be used for apexification and showed good result for apical barrier formation. The physical properties of MTA give benefit in reduced treatment time thus the obturation can be performed shortly afterwards, as well as internal bleaching and tooth restoration.

Keywords: apexification, mineral trioxide aggregate, internal bleaching, discolored tooth

Introduction

Immature permanent teeth are described as erupted permanent teeth with an apical closure that have not been completed. There are so many cases related to immature teeth that dentist

should take concern. Apical completion could be halted when the pulp in these young permanent teeth was compromised and then lead to pulp necrosis (e.g.: deep carious lesions, physical trauma, and tooth defect such as dens invaginatus) [1].

Conventional endodontic treatment could not be performed in this case due to broad opening [2]. Apexification is described as an endodontic treatment in which the aim is to do apical closure at immature teeth using biocompatible material. The apical closure could be done using set material acts as a barrier at the apical foramen (mineral trioxide aggregate, MTA) or osteocementum inducing material (calcium hydroxide) in which it can not be done physiologically due to a nonvital pulp. The main purpose of apexification is to achieve an apical barrier formation to provide apical stop when the obturating material is applied [3]. Dental management of non vital tooth with immature root completion basically has the same procedure as routine endodontic treatment (e.g.: cleaning and shaping, root canal disinfection, and three dimensional obturation). The apical closures could be done using conventional or surgical method after endodontic process is finished. Commonly used material to induce apical closure are MTA and calcium hydroxide that act as apex barrier or inducing cementum to perform apical closure [4].

Clinical Aspect

19-years old male patient came to Conservative Dentistry Clinic at RSGM Prof. Soedomo Faculty of Dentistry Universitas Gadjah Mada complained about his discolored upper right anterior tooth. His tooth looked greyish dark in color. Past dental history said that patient had experienced dental trauma when he was 10

years old. Then, he went to dentist office for first aid. At that time, the dentist only gave analgetics and did the observation. Several days later, patient experienced no pain and decided to postpone the treatment due to the financial issue. The patient stated that since then patient had not experienced pain and he asked for treatment to overcome his discolored tooth. Patient was also planned to undergo orthodontic treatment.

Diagnosis and Etiology

Intraoral findings showed there was a crown fracture at the incisal part of tooth 11 and 12. Palpation and percussion test was negative, and so was the thermal test. Oral hygiene index was good, periodontal tissue showed no abnormalities. The patient had Class I Angle Molar Relation. The periapical radiograph showed incomplete apical foramen with radiolucencies found in periapical and the root canal was wide and straight (figure 1. (a)). The tooth crown was found dark brown greyish in color (figure 1.(b))

The etiologic factor of this case report originated from dental trauma patient had suffered when he was 10-years old. This trauma then causing pulp tissue necrosis and thus odontoblast could not undergo its physiological process depositing new dentin which was then led to incomplete apical closure. Bacterial invasion through fractured crown produced toxins that entered the root canal then activated inflammatory cells that damaging periodontal tissue and thus causing periapical lesion.

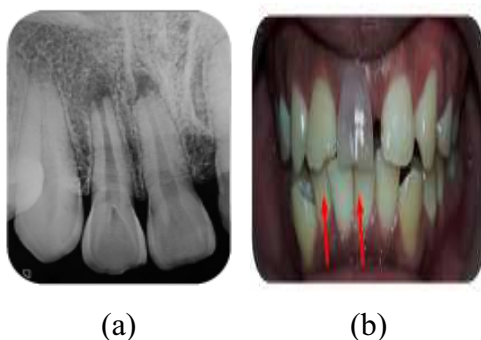


Figure 1.(a)Periapical radiograph tooth 11 and 21. Radiolucencies were found at the apical portion of both teeth. Open apex was also seen., (b). Clinical photograph tooth 11 and 21 from the facial aspect, no cavities found but the crown fracture was seen at the incisal edge of both teeth (red arrow).

Tooth 11 was diagnosed with Ellis Class IV fracture with pulp necrosis and incomplete apical closure with severe discoloration and periapical lesions. Tooth 12 was diagnosed with Ellis Class IV fracture with pulp necrosis and incomplete apical closure with periapical lesions. The patient was then explained with treatment plans that he would undergo, those were:

1. Apexification using Mineral Trioxide Aggregate for tooth 11, 12
2. Non-vital bleaching for tooth 11
3. Restoration using direct composite resin with intracanal fiber post 11 and direct composite restoration for 12.

Those treatment plans came with good prognosis because patient was co-operative, good oral hygiene, no

abnormalities were found in periodontal tissue, straight root canal projection and restorable tooth structure remaining.

CASE MANAGEMENT

1st Visit

The subjective and objective examination was conducted. A clinical photograph and clinical radiograph were taken, a diagnosis was established and treatment plans were made. The patient was explained about planned treatment procedure, treatment time, and treatment cost. The Patient agreed with the plans and then fill and sign the informed consent sheet. After rubberdam placement (figure 2a) , access opening was made using endo access bur and diamendo from palatal aspect (figure 2. (b)). Pulp was then debrided using 2.5% sodium hypochlorite solution in adequate amount to remove debris and necrotic remnants of the pulp tissue. Working length was established at 23mm for both teeth using radiograph confirmation aided by #40 k-file (figure 2 (c)).

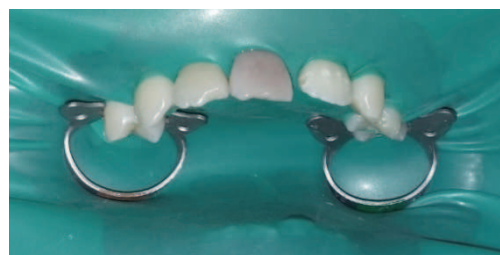
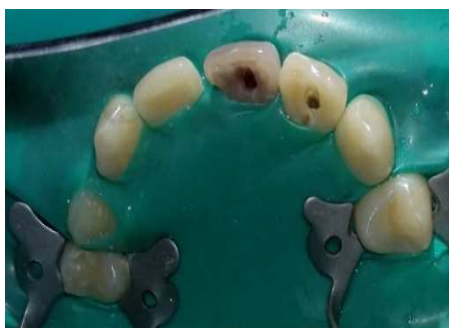
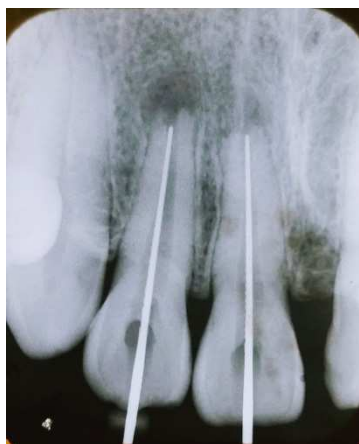Figure 2.(a). Rubber dam placement



(b) Cavity access from palatal aspect.



Gambar 3. Working length determination using periapical radiograph. The #40 k-files stopped just right at the opened apex of the tooth.

Cleaning and shaping were done using K-file #45, #50, # 55 and #60 at specified working length(23mm)followed conventional method. Copious amount of 2.5% sodium hypochlorite solutionswere introduced in to the root canal as irrigation. Further preparation beyond apex was not advised since it could damaging barrier forming tissue.Final rinse was done using 2.5% sodium hypochlorite solution, root canal was then immersed for approximately 5 minutes. The root canal was subsequently irrigated using EDTA 17% (*Smear Clear*,

SybronEndo)solution and then disinfected using *chlorhexidine digluconate 2%*(*Cavity Cleanser*; *Bisco*) solution. Between those irrigation solution, saline solution was used as intermediary. Root canal was then dried and medicated using calcium hydroxide paste (*UltraCal XS*, *Ultradent*), cavity was sealed using temporary filling (*Caviton*, GC Corp). Patient was instructed to visit in one week.

2nd Visit

No symptoms and clinical signs of infection, thus the treatment could be continued. After rubberdam placement, temporary filling was opened. Intracanal medication was then flushed away using irrigation solution (2.5% sodium hypochlorite solution), EDTA 17% solution with saline solution as an intermediary. The root canal was then dried using absorbent paper point. MTA powder and liquid were mixed according to manufacturer instruction (W:P ratio 3:1) then applied to an apical portion of the root canal until 4mm thickness achieved. A small amount of moistened cotton pellet was placed inside the pulp chamber and then cavity was sealed using temporary filling. After rubber dam was removed, periapical radiograph was taken to check apical adaptation of MTA (Figure 4)

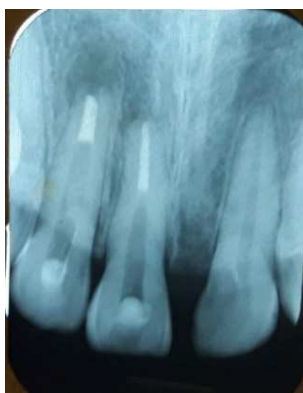

Figure 4. Periapical Radiograph of Tooth 12 11 showed good apical adaptation of MTA.

3rd Visit

No symptoms were reported by patient between visits. The objective examination found no abnormalities as percussion and palpation test showed a negative result, and mobility test as well. Obturation was done using *thermoplastic injection* until 2mm below orifice. Gutta percha was then gently condensed apically. A periapical radiograph was then taken to evaluate obturation (Figure 5).

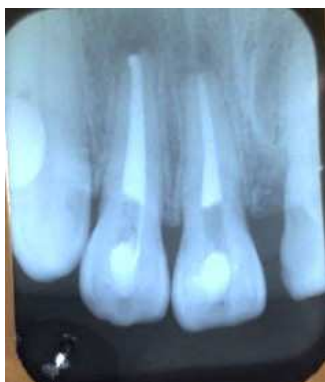

Figure 5. Post obturation periapical radiograph showed hermetically obturated root canal of teeth 12 11

4th Visit

Intracoronary bleaching was planned to be done at this visit. Subjective and objective findings showed no abnormalities. No symptoms were reported. A negative result showed on percussion, palpation and mobility test. Shade guide check prior to dental bleaching treatment was done using Vita Shade Guide with similar to D4 shade color confirmed (Figure 6).

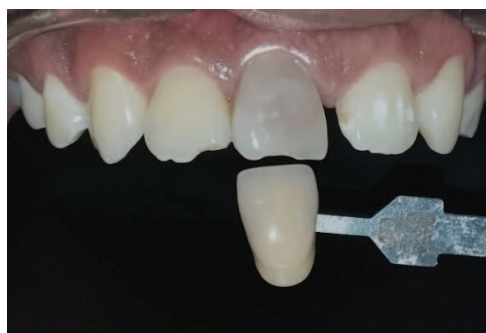

Figure 6. Clinical photograph of tooth color checking with D4 Vita Shade Guide Confirmed

Temporary filing of 11 was opened and gutta percha was removed 2mm apically beyond marginal gingiva using peeso reamer. A periapical radiograph was then taken to check gutta percha removal (figure 7.(a)). After gutta percha had been removed, cervical barrier was made using resin modified glass ionomer cement (Figure 7.(b)).

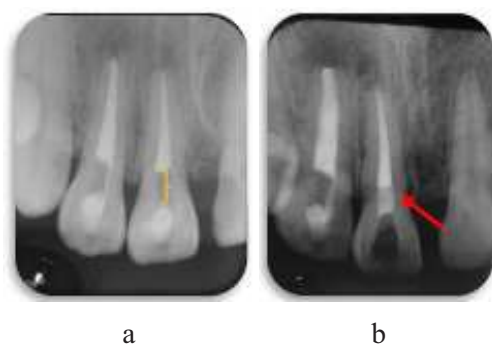


Figure 7. a. Gutta percha removal evaluation. Periapical radiograph showed void area after removal at the cervical level (yellow line)b.Periapical Radiograph of Tooth 11 after cervical barrier placement (red arrow).

Bleaching agent (Opalescence Endo, Ultradent) then placed inside the pulp chamber using proprietary cannula. The dry cotton pellet was then placed atop of bleaching agent before then double seal was applied to the cavity. The patient was instructed to check the tooth everyday and report if there was color the change to the brighter shade. After three days, patient reported the significant color change on tooth 11 and made a visit to the dental office.

5th Visit

Tooth shade was checked using Vita Shade Guide. Tooth shade was confirmed similar to A1 shade guide (Figure 8). The Double seal was removed and so with the bleaching agent. The cavity was then rinsed using warm water and calcium hydroxide paste was applied into the pulp chamber. Cavity was then sealed with temporary filling.

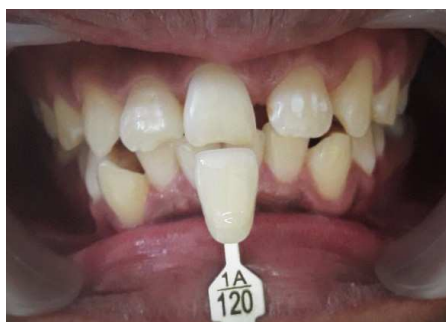

Figure 8. Shade checking showed color change to A1.

6th Visit

No symptoms were reported between visits. Percussion and palpation test was negative. Patient was planned to undergo fiber post placement as intracanal reinforcement in endodontically treated tooth. The periapical radiograph was traced using precision drill (Radix Fiber Post, Dentsply) in order to find fiber post that corresponds with root canal diameter. Fiber post #4 (green color indicator) was chosen as it fitted with root canal diameter. Gutta percha was then removed two thirds apically from the orifice using peeso reamer and proprietary precision drill was used as final drill and checked using periapical radiograph (figure 9a). Trial insertion was then done and checked with radiograph (Figure 9b and 9c). Root canal was then rinsed using CHX 2% solution, and dried subsequently using absorbent paper point. Tooth 11 was then isolated using cotton roll. The surface of the fiber post was silanized then air dried. Self-adhesive resin cement was then applied on the post surface and root canal as well. The fiber post was then inserted gently into the root

canal to prevent air bubble getting trapped. Fiber post was then cured using light cure for 20 seconds. The tooth cavity was then restored using packable composite resin (Herculite Dentin, Kerr).

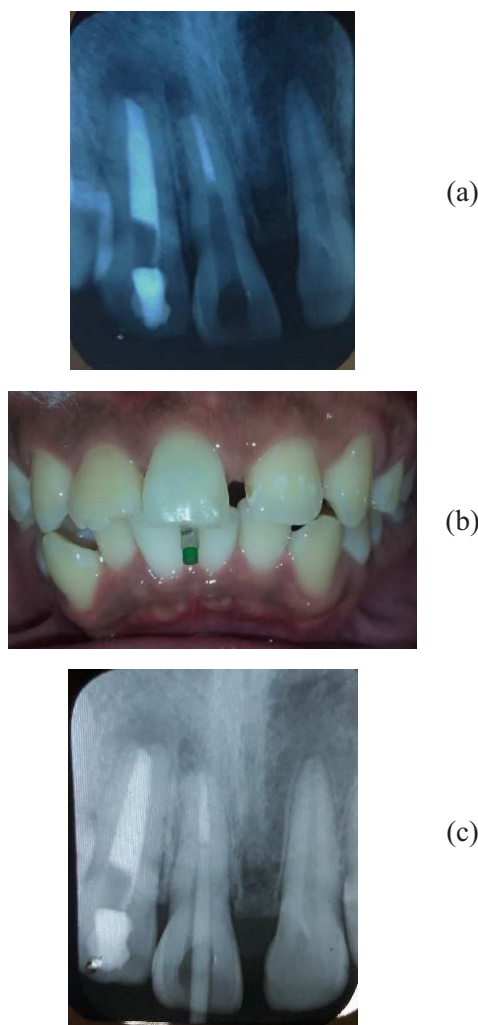


Figure 9. (a) Gutta percha removal at tooth 11, (a) Clinical photograph of trial insertion, (c). Radiograph checking of trial insertion.

Tooth 12 was restored using SDR (Dentsply) as coronal seal and then using packable resin composite (Herculite Dentin A3, Kerr). Periapical radiograph was then

taken to evaluate fiber post insertion of 11 and coronal seal of 12 (figure 10a). Palatal aspect of 11 and 12 restored using packable composite (Herculite Dentin A3, Kerr) (figure 10b). Incisal fracture of 11 and 12 was also restored using packable composite (Herculite Dentin A3, Kerr) (figure 10c).

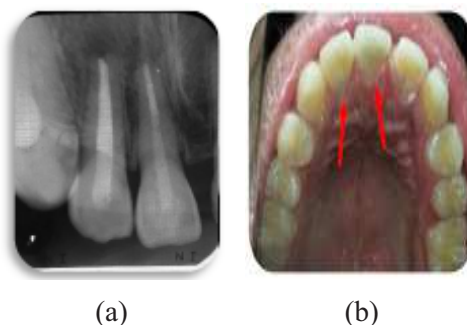


Figure 10. (a) Post operative periapical radiograph showed good adaptation between fiber post and root canal dentin on tooth 11 and good coronal sealing on tooth 12 (b) Post operative clinical photograph of tooth 12 11 from palatal aspect (red arrow).

7th Visit

Patient recall

Patient was recalled 6 months after treatment for evaluation purpose. Subjective examination found no complaints and no symptoms were reported. Objective examination found negative results on palpation test, percussion test, and mobility test. Radiography image was taken to evaluate periapical lesion and the result the periapical lesion was getting smaller.

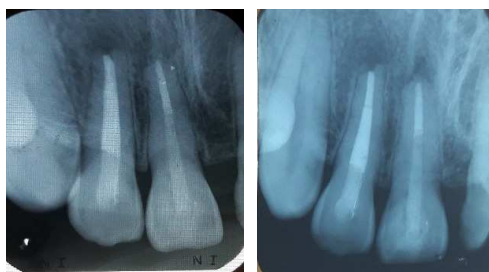

Figure 11. Radiography image of 11, 12 showed periapical lesion was getting smaller

Discussion

Tooth 12 and 11 that were reported in this case report experienced physical trauma that led those two teeth into disruption before apical portion of the teeth was completed. Maturation of permanent tooth occurred 2-3 years post eruption. Maxillary incisors eruption occurs at age 7-9 years. Physical trauma that occurred to the patient caused pulp necrosis thus root completion process was disrupted [5].

Endodontic treatment for immature teeth has its own technical difficulties especially due to its wide root canal and therefore no apical constriction where the root preparation should be ended. To overcome such problems, apexification is advised to be done. Apexification was non-surgical approach which the aim is to induce apical closure in immature non-vital tooth. Apical opening has to be sealed to prevent bacterial toxins infiltrate into periradicular and periodontal tissue and provides apical stop for further obturation [6].

Meticulous cleaning and shaping is mandatory, commonly using conventional

method since there is no apical stops. Root canal disinfection commonly done using irrigation solution (sequence of sodium hypochlorite solution, EDTA solution, and CHX solution with saline or sterile aquadest in between as intermediary solution) and intracanal medication. Commonly used intracanal medication is calcium hydroxide with 7 days of minimum application time [7].

Conventional material used for apexification is calcium hydroxide. Other materials such as tri-calcium phosphate, collagen calcium phosphate, osteogenic protein-1, bone growth factors and mineral trioxide aggregate (MTA) was reported had been used also as apexification material. MTA getting its popularity as apexification material since it first introduced by Torabinejad in 1994. MTA has more advantages than calcium hydroxide as apexification material such as shorter treatment time, faster setting time, more predictable result and does not have problem with blood contamination [6]. Due to these advantages, MTA was chosen as apical plug material in this case report. In contrast, calcium hydroxide needs 3-20 months of treatment time, and patient should be recalled every 3 months for evaluation [8].

MTA also has several good properties such as excellent biocompatibility, antimicrobial, non-toxic to periapical and periodontal tissue and stimulate cytokine release from bone cell to enhance hard tissue formation. MTA, in contrast, also has

several disadvantages such as expensive price and difficult to manipulate compared to calcium hydroxide. MTA was a mixture of Portland cement and bismuth oxide which also has dicalcium silicate, tricalcium silicate, tricalcium aluminate and tetracalcium aluminoferrite. It has alkaline pH. MTA also reported had unique ability to stimulate cementum and enhancing periodontal tissue regeneration^[6]. The minimum thickness of MTA application in order to achieve good mechanical retention is 1-4mm^[8].

MTA has 2-3 hours working time, and is a hydrophilic substance so it needs moist environment to set. Recommended W:P ratio is 1:3, mixed thoroughly in 30 seconds until putty-like consistency is achieved. Putty like consistency is the best form of MTA to be applied effectively ^[2]. There are two form of MTA, white MTA (WMTA) and grey MTA (GMTA) with the later was introduced first. WMTA was developed after, due to tooth discoloration potential of GMTA^[9]. WMTA did not contain tetracalcium aluminoferrite. In this case report WMTA was used due to aesthetic consideration since the teeth being treated was anterior teeth^[10].

When patient recalled for 6 months post treatment, radiograph showed that the size of periapical lesion was smaller than pre-operative radiograph. It was concluded that apexification using MTA brought favorable result.

Internal bleaching was also done in this case report to treat tooth discoloration

in tooth 11. Discoloration occurred in this case report was caused by dental trauma. This trauma led blood vessel to rupture and the blood seeped into dentinal tubules. The blood contains hemoglobin that would break down into iron containing substance. This substance then incorporated further with hydrogen sulfide forming ferric (III) sulfide compounds which has blackish dark in color. The color changes after trauma occurred follows the order from pale pink, orange, blue and at the end become brownish or blackish dark^[2].

When performing internal bleaching, cervical barrier must be concerned to be done first due to high risk of hydrogen peroxide used as bleaching agent. Hydrogen peroxide that leaches out of the dentinal tubules into the periodontium can lead to cervical resorption. Cervical barrier should be 2mm thick below the margin to cover internal area at the level of CEJ to prevent bleaching agent leaked out to the periodontal tissue. This was done by removing gutta percha using peeso reamer or heated hand plugger. Cervical barrier can be made from GIC, intermediate restorative material (IRM), cavitec, composite resin, and temporary material like zinc oxide eugenol, polycarboxylic cement, and zinc phosphate cement. The color of the cervical barrier material should be considered carefully as it could give color discoloration^[12].

Bleaching agent used in this case report was hydrogen peroxide in 35% concentration. The efficacy of this bleaching agent occurs in 2-7 days. In this case

report, desired color change occurred in 3 days after placement. Calcium hydroxide was placed inside the pulp chamber to change the pH from acidic to neutral after bleaching agent was removed^[7].

Fiber post was used as intracanal retention for tooth 11 because it suffers high occlusion load due to tooth position so the tooth had slight traumatic occlusion with its antagonist tooth. These fiber post is translucent, more favorable for conditions with high esthetic demands. Besides, fibers have modulus elasticity (about 20 GPa) similar to dentin (which has a flexural modulus of about 18 GPa), high tensile strength, low electrical conductivity, resistance to solubility, and resistance to biochemical degradation^[11]. Palatal aspect and incisal fracture restored with composite resin

Daftar Pustaka

1. Report AC, Chen X, Bao Z, Liu Y, Liu M. Regenerative Endodontic Treatment of an Immature Permanent Tooth at an Early Stage of Root Development : J Endod [Internet]. 2017;39(5):719– 22. Available from: <http://dx.doi.org/10.1016/j.joen.2012.12.023>
2. Rao, R.N., 2009, Advanced Endodontics, 1st Ed, Jypee-Highlight Medical Publisher Inc
3. Garg A, Garg N., 2014, Textbook of Endodontics 3rd Edition, Jaypee Medical Brother Publishing, India, p298.
4. Umashetty, G., Patil, B., Rao, N., Ajgaonkar, N., 2015, Apical Closure of Nonvital Permanent Teeth: 15 Months Follow-up Study of Four Cases, *Journal of International Oral Health*, 7(5):71-73.
5. Budiyaniti, A. 2006. Perawatan Endodontik pada Anak. Jakarta: Penerbit Buku Kedokteran EGC.
6. Cheng Lin Jia, QI Ling Jun, 2016, Comparison of mineral trioxide aggregate and calcium hydroxide for apexification of immature permanent teeth :A systemic review and meta analysis, *Journal of the Formosan Medical Association*, Vol 115, issue 7: 523-530.
7. Hargreaves, K.M, Berman, L.H., 2016, Cohen's pathways of the pulp, 11th Ed, Elsevier Inc.
8. Fouad, A.F., 2009, Endodontic microbiology, 1st Ed, Wiley-Blackwell.
9. Chemical RPI. Mineral Trioxide Aggregate : A Comprehensive Literature. J Endod [Internet]. 2017;36(1):16–27. Available from: <http://dx.doi.org/10.1016/j.joen.2009.09.006>.
10. Gaitonde P, Bishop K., 2007, Apexification with Mineral Trioxide Aggregate : an overview of the material and technique, 15(1):41–5.
11. Lamichhane, A., Xu, C., Zhang, F., 2014, Dental fiber-post resin base material: a review, *J Adv Prosthodont* 6:60-5
12. Bahuguna, N., 2013, Cervical root resorption and non vital bleaching, *ENDODONTOLOGY* Volume: 25 Issue 2

CASE REPORT

MESIAL ROOT HEMISECTION AND RESTORATION AS A TREATMENT OPTION OF MANDIBULAR FIRST MOLAR : A CASE REPORT

Dinda Dewi Artini, drg¹, Prof. Dr. Ruslan Effendy, drg. MS., Sp.KG(K)²

¹Resident of Conservative Dentistry

²Lecturer of Departement of Conservative Dentistry

Departement of Conservative Dentistry

Faculty of Dental Medicine – Airlangga University

Surabaya, Indonesia

ABSTRACT :

Background : Hemisection is a treatment procedure involving removal of the involved tooth root and its associated crown portion, which is done with the purpose of preserving as much tooth structure as possible rather than sacrificing the whole tooth. This treatment can produce predictable results as long as proper diagnostic, endodontic, surgical, restoration and maintenance procedures are performed. **Purpose :** This case report to describe a procedure of hemisection in lower first mandibular molar and its restoration of the remaining tooth. **Case report :** A 31 year-old male patient referred to the Conservative Specialist Clinic Airlangga University . His complaint was about history of pain in lower right first molar one month ago. The tooth had been treated root canal treatment 3 years ago. On intraoral examination there was fistula in lower right first molar. This tooth had been restored with porcelain fused to metal crown. Radiographic finding showed radiolucency in the furcation and radiolucency on mesial root. **Method :** Hemisection was performed and the fragment of mesial root was removed. The bone graft material and fiber splint were placed. After 1 month fiber post was placed in distal root and preparation for this porcelain fused to metal (PFM) crown with occlusal rest. After 3 month patient was recalled for re-evaluation. **Conclusion:** Hemisection effective to preserve posterior tooth structure and its function for occlusal rehabilitation. The results of hemisection are predictable and success rates are high if certain basic considerations are taken into account.

Keyword : Hemisection, mandibular molar, crown with occlusal rest

Correspondence : Dinda Dewi Artini, Resident of Conservative Dentistry, Faculty of Dental Medicine, Airlangga University, Surabaya – Indonesia. Email : dindadewiartini@yahoo.com. Phone : +6282117654555

INTRODUCTION :

A molar with extensive decay, periodontal problem or a root fracture may be unsuitable for restoration. In such cases, the treatment options are limited and may include extraction of the involved tooth.¹

The loss of posterior molar can result in several undesirable effects including shifting of teeth, collapse of the vertical dimension of occlusion, super eruption of opposite teeth, loss of supporting alveolar bone and a decrease in chewing ability. The treatment options to replace severely damaged and possibly unrestorable teeth include removable partial denture, fixed partial denture or dental implants. A guiding principle should be to try and maintain what is present.^{2,3}

Hemisection of the effected tooth allows the preservation of tooth structure, alveolar bone and cost savings (time and money) over other treatment options. The term hemisection refers to the sectioning of a molar tooth with the removal of an unrestorable root which may be affected by periodontal, endodontic, structural (cracked roots), or caries. Careful case selection determines the long term success of the procedure.^{3,4}

Indication for hemisection can be endodontic or periodontal. Weine has listed the following indications for tooth hemisection.³

Periodontal Indications :

1. Severe vertical bone loss involving only one root of multi-rooted teeth.

2. Through and through furcation destruction
3. The unfavourable proximity of roots of adjacent teeth, preventing adequate hygiene maintenance in proximal areas
4. Severe root exposure due to dehiscence.

Endodontic and restorative indications :

1. Prosthetic failure of abutments within a splint
2. Endodontic failure/perforation through the floor of the pulp chamber.
3. Vertical fracture of one root.
4. Severe destructive process: This may occur as a result of furcation or subgingival caries, traumatic injury, and large root perforation during endodontic therapy.

Contraindications :

1. Poorly shaped roots or fused roots
2. Poor endodontic candidates or inoperable endodontic roots.
3. Patient unwilling to undergo surgical and endodontic treatments and undertake the care or the resulting restoration.

This case report describes a procedure of hemisection in mandibular right first molar. which was chosen to retain the endodontically treated distal root and its subsequent restoration. The key to long term success appear to be through diagnosis, selection of patients with

good oral hygiene, careful surgical and restorative management.

CASE REPORT :

A 31 year-old male patient referred to the Conservative Specialist Clinic Airlangga University. His complaint was about history of pain in lower right first molar one month ago. The tooth had been treated root canal treatment 3 years ago.

On intraoral examination there was fistula in mandibula right first molar gingiva. (Fig 1) The tooth was tender to percussion along with pain on biting. This tooth had been restored with porcelain fused to metal crown. Periodontal probing revealed a deep periodontal pocket associated with the buccal aspect of the mesiobuccal root. Laboratory investigations showed a good level of glycemic control (fasting blood sugar : 98 mg/dl and postprandial blood sugar : 100 mg/dl).

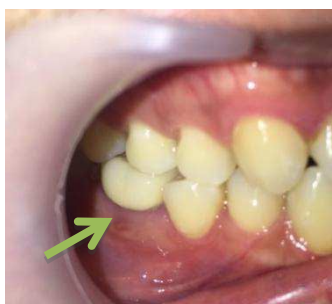


Fig 1 : Clinical features show PFM crown in 46 with fistula at the gingiva

A periapical radiographic finding showed radiolucency in the furcation and around the mesial root apex. (Fig 2)

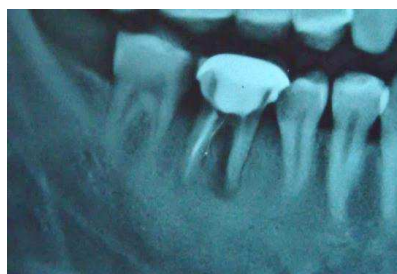

Fig 2 : Radiography view

As first step was the removal porcelain fused to metal crown using fissure bur and crown retractor. (Fig 3)

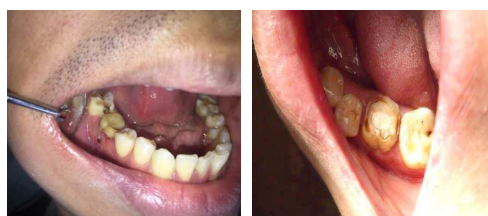

Fig 3 : PFM crown was removed

The patient was recalled after one week for hemisection of the tooth (46). The patient performed a blood pressure measurement and the result was 120/80 mmHG. Asepsis with povidone iodine in the operative area. Block anesthesia on the right mandibular nerve and infiltration anesthesia on vestibulum 46 with 2% lidocaine and 1:80.000 adrenalin. (Fig 4)

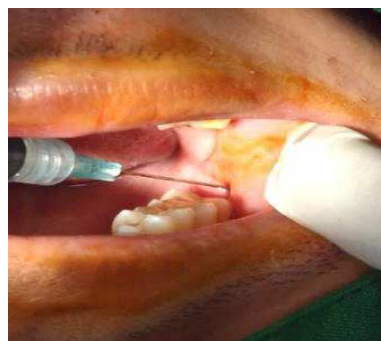

Fig 4 : Local anesthesia

The vertical cut method was used to resect the crown with distal root. High speed handpiece with long shank tapered fissure carbide bur was used to make vertical cut facio-lingually toward the bifurcation area. (Fig 5) A fine probe was passed through the cut to ensure separation. (Fig 6)

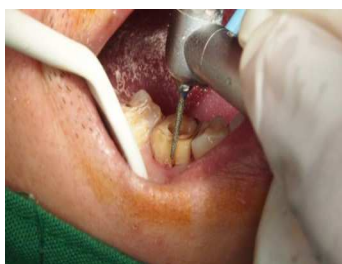

Fig 5 : Separation using long shank tapered fissure bur

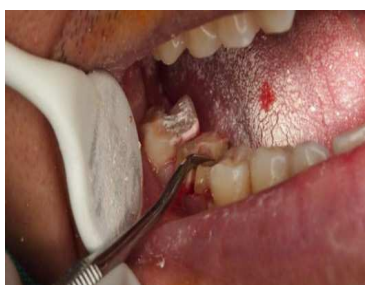

Fig 6 : A vertical cut made towards the bifurcation area

After separation, mesial root was extracted with extraction forceps. (Fig 7) The occlusal table was minimized to redirect forces along the long axis of the distal root.

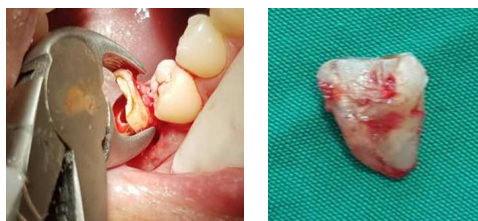

Fig 7 : Mesial root extracted

Debridement and irrigation with sterile saline of the socket were performed to remove bony chips and debris. Socket preservation was done after extraction of mesial root. (Fig 8)

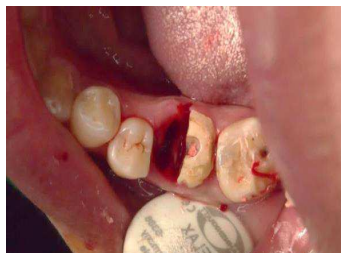

Fig 8 : Socket after mesial root was extracted

Bone graft (Gamacha®) was placed in the extraction site and sutured with 3-0 black silk suture. (Fig 9)

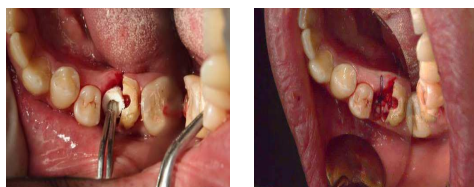

Fig 9 : Bone graft was placed into the socket and socket was sutured

After that, the retain distal tooth was splint using fiber splint with 47 tooth on the buccal surface. (Fig 10) Post operative radiography showing the mesial root was removed. (Fig 11) The surgical site covered with a periodontal dressing. Instruction post-operative was given and antibiotic was prescribed.

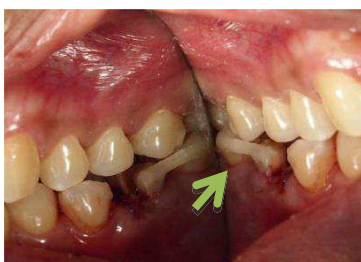

Fig 10 : Splinting of distal tooth (46) and second molar (47)

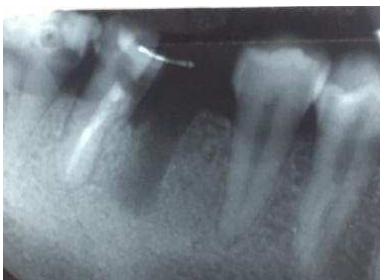

Fig 11 : Radiographic view after hemisection of mesial root

Patient was recalled after one week for evaluation. There was no subjective symptoms, good stitching conditions, good splinting conditions, negative percussion. Suture were removed and irrigation with saline.

After four week evaluation, there was healing of tissue and no tooth mobility. Fiber post (LuxaPost®, DMG) was replaced in distal root and cemented with Rely-X Self Adhesive Resin Cement (3M ESPE, Germany) (Fig 12) and build up with composite resin Core build up (Multi Core, Ivoclar).

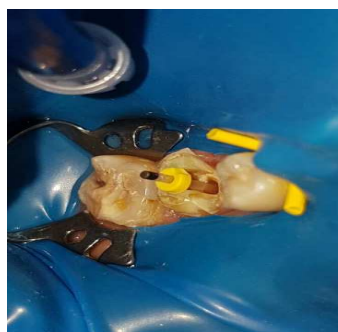


Fig 12: Fiber post inserted to distal root

Tooth preparation for porcelain fused to metal crown was performed. Chamfer finish line was established around margins of buccal distal and lingual using round end fissure bur. (Fig. 13).

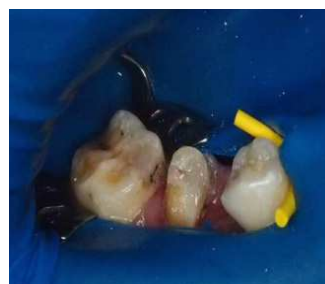

Fig 13 : Tooth preparation

Final impression was taken after the retraction of gingiva using gingival retraction cord. Polyvinyl siloxane (Flexitime® VPS Impression Material, Heraeus Kulzer) impression was made with two step and antagonist impression using alginate. The colour shade was determined with a shade guide (Vitapan 3D MasterVita, Germany). Temporary crown was cemented with temporary cement (Fregenol Temporary Pack, GC). (Fig 14)

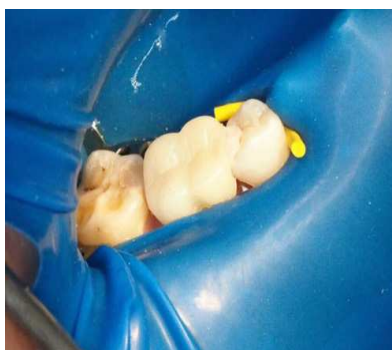

Fig 14 : Temporary crown

At the next visit, porcelain fused to metal (PFM) crown were try and checked of the occlusion, anatomical, contour, marginal adaptation, color similarity. This crown using occlusal rest at distal 45. The tooth was isolated and this crown was cemented using GIC luting cement (Fuji I, GC). (Fig 16)

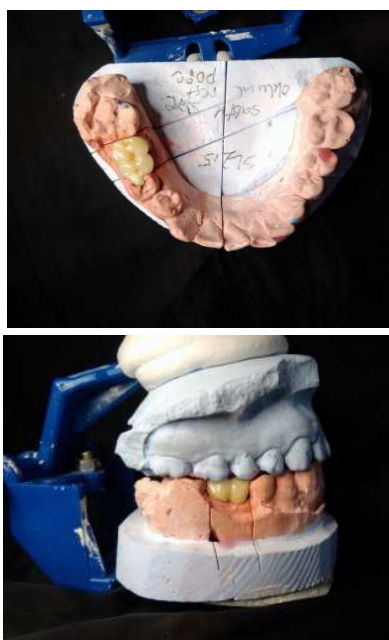


Fig 15 : PFM crown on the model

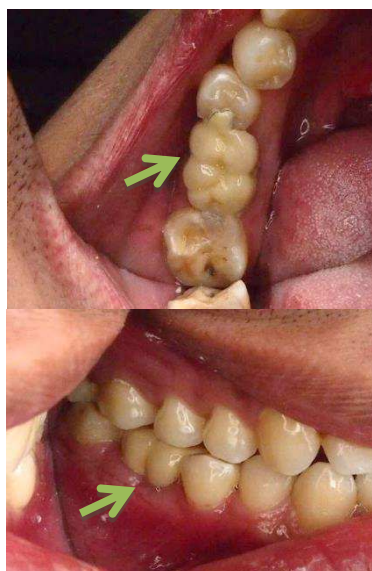

Fig 16 : PFM crown inserted (occlusal view and buccal view)

After 3 month follow-up, periodontal probing depths were within normal range, there was absence of gingiva resession, and from radiography showing healing of the bony lesion along with final restoration. (Fig 17)

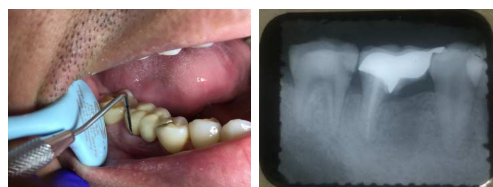

Fig 17 : Follow up after 3 month

DISCUSSION

A considerable number of management endo-perio problem such as furcation involvement of mandibular molar should be extracted, but furcation involvement can be treated successfully with hemisection. Furcation involvement is

defined as bone resorption and attachment loss in the inter-radicular space that results from plaque-associated periodontal disease. The complexities involved in treating a tooth with advanced periodontal disease involving the furcation region include periodontal, endodontic, and prosthodontic considerations. Hemisection is one of several treatment modalities that can be used in such case.⁵

Hemisection of a mandibular molar may be a suitable treatment option when the decay is restricted to one root and the other root is healthy and remaining portion of tooth can very well act as an abutment for its restorations.^{5,6}

Successfull of hemisection considering from the following factors: ⁶

- Advanced bone loss around one root with an acceptable level of bone around the remaining roots.
- Angulations and position of the tooth in the arch. A molar that is buccally, lingually, mesially or distally tilted cannot be resected.
- Divergence of the roots teeth with divergent roots are easier to resect
- Closely approximated or fused roots are poor prognose
- Length and curvature of roots long and straight roots are more favourable for resection than short, conical roots
- Feasibility of endodontics and restorative dentistry in the roots to be retained

In this case, a hemisected molar was selected for the treatment of endodontically

treated tooth with lesion of mesial root and furcation involvement grade II of bifurcation. The mesial root was resected because any lesion and bone loss around this root. However the distal root was retained because distal root is broader and straighter which is making it more suitable as an abutment for its restoration.⁷

This tooth has lost part of its root support, it will require a restoration to permit it to function independently or to serve as an abutment. This case use porcelain fused to metal crown with occlusal rest. A restoration can contribute to periodontal destruction if the margins are defective or if non-occlusal surfaces do not have physiologic form. An improperly shaped occlusal contact area may convert acceptable forces into destructive forces and predispose the tooth trauma from occlusion and ultimate failure of hemisection.⁸

CONCLUSION

Hemisection effective to preserve posterior tooth structure and its function for occlusal rehabilitation. The results of hemisection are predictable and success rates are high if certain basic considerations are taken into account. The success of the tooth with hemisection depends the supporting bone, the restorative treatment plan, and the oral hygiene of the patient.

REFERENCES

1. Yadav S, Agnihotri K, Vinayak V, Gurtu A. 2012. Hemisection – Divide & Rule : A Case Report. Journal of

- Dental Science & Oral Rehabilitation. 12(1): 54-56.
2. Sarangi P, Uppin VM, Gowdra RH. 2012. Hemisection A Case Report. Global Research Analysis. 1(5):103-104
3. Garg S, Goel M, Goel V. 2016. Salvaging a Young Lower Molar with Furcal Radiolucency by a Novel and Innovative Endodontic Procedure- A Case Report. Annals of International Medical & Dental Record. 2(6): 32-35
4. Mittal P, Prasad AB, Raisingani D, Amit, Mehta P, Soni D, Khurana D. 2016. Hemisection : A Savior for Hopeless Teeth. Journal of Mahatma Gandhi University. 1(1):30-34
5. Kurian B, Swapna DV, Nadig RR, Vedawathi B. 2016. Hemisection-Survival of fittest. International Journal of Applied Dental Sciences. 2(2):71-73
6. Balachandran A, Sundaram S. 2014. Resective procedures in the management of mandibular molar furcation involvement: A report of three cases. Journal of Interdisciplinary Dentistry. (4)1: 41-45
7. Behl, Ashima. 2012. Hemisection of a Multirooted Tooth-A Case Report. Scientific Reports. 1(6): 1-6
8. Shah S, Modi B, Desai K, Duseja S. Hemisection – A Conservative approach for A Periodontally Compromised Tooth – A Case Report. Journal of Advanced Oral Research. 3(2):31-35.

CASE REPORT

ROOT RESECTION OF MAXILLARY FIRST MOLAR: A CASE REPORT

Dina Ristyawati¹, M. Mudjiono²

¹Resident of Conservative Dentistry

²Lecturer of Department of Conservative Dentistry

Department of Conservative Dentistry

Faculty of Dental Medicine – Airlangga University

Surabaya - Indonesia

ABSTRACT

Background : Complicated treatment plan and questionable long term prognosis of a compromised tooth often pose a significant challenge to the clinician. Extraction and subsequent replacement are one of the treatment options for a severely decayed tooth. However, meticulous considerations and proper treatment such as root resection therapy enable the perseverance of the natural dentition. This study presents the case of a patient with pain on the upper left maxillary first molar associated with a horizontal/ oblique root fracture. **Purpose** : describes the treatment procedures of root resection of maxillary molar with mesiobuccal root fracture and a subsequent prosthetic rehabilitation. **Case report** : A 30 years old woman was referred to conservative specialist clinic, Airlangga University, with a chief complaint of a pain associated with the left maxillary first molar with a history of occlusal trauma. On intraoral examination, there was a deep carious lesion on mesio buccal aspect of the offending tooth. A periapical radiographic showed radiolucent oblique fracture line on mesio buccal root. **Methods** : Root canal treatment was done for the disto buccal and palatal root, and root resection of the mesio buccal root was performed. Bone graft material was applied at the mesiobuccal root socket, and fiber splint was placed. Fiber post was placed in the palatal root and prepared for prosthetic crown. **Conclusion** : With recent advancements in endodontics, periodontics and restorative dentistry, root resection has received acceptance as a conservative and effective treatment and have endured the demands of function.

Keywords : root canal treatment, maxillary molar, root resection, root separation.

Correspondence : Dina Ristyawati, Resident of Conservative Dentistry, Faculty of Dental Medicine, Airlangga University, Surabaya – Indonesia. Email : dina.ristya@gmail.com. Phone : +6281241023055

INTRODUCTION

Loss of molars can cause some undesirable conditions including the shift of adjacent tooth, reduced occlusal vertical dimensions, supra position of opposing teeth, loss of alveolar bone and decreased of chewing ability.

Severely decayed multirooted teeth with one of the roots in a compromised condition (eg: fractured root, failed endodontic treatment) are often successfully treated by resecting the fractured root, either by root resection or hemisection. Root resection is a surgical procedure in which one or more multi-rooted tooth roots are taken up to the furcation limit while the remaining crown and residual roots are maintained¹.

The root resection procedure was first introduced by Farrar in 1884², stated that root resection is one of the acceptable surgical treatments for compromised molar. The prognosis therapy of root resection has been well documented. Some researchers reported that molar root resection has a survival rate of more than 90%, while other researchers reported that 30% of molar root resections fail over a period of 10 years¹. Bulher (1988) reported that 89% of molar root resection survived for a period of 7 years and 32.1% molar root resection failed. Blomlof, et al. (1997) showed similar results that 32% of molar root resection failed over a period of 10 years. The reported survival rates differences were associated with techniques, case selection, patient compliance with oral

hygiene instructions and appropriate restorative care⁵.

CASE REPORT

A 30 years old woman was referred to the Conservative Specialist Clinic, Airlangga University, with a chief complaint of pain on left maxillary first molar after eating food. No history of any systemic diseases was reported. On clinical examination, there was a deep carious lesion on mesio buccal aspect and pain on percussion associated with tooth 26. Pulp vitality test, thermal and electronic pulp tester showed no response suggestive of necrosed pulp. The periapical radiographic showed a radiolucent oblique fracture line. Considering the clinical and radiographic findings, a vertical fracture of mesiobuccal root was suspected (fig, 1,2).

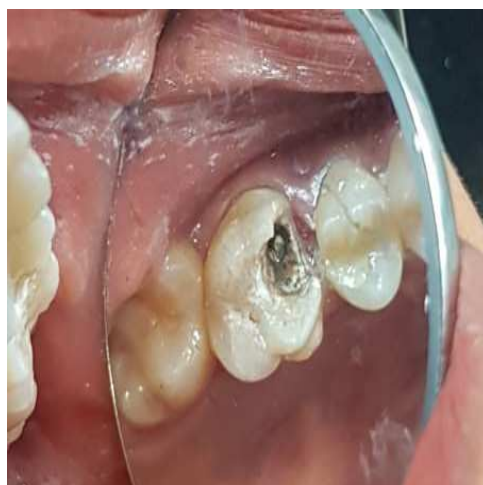

Figure 1. Clinical appearance before treatment

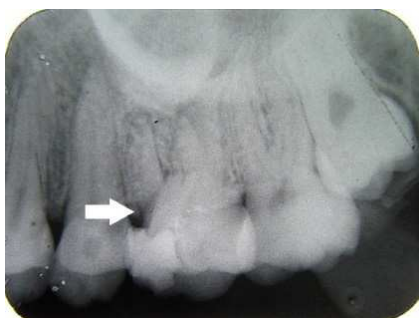

Figure 2. Pre operative radiograph, demonstrated a horizontal radiolucent line on mesiobuccal roots

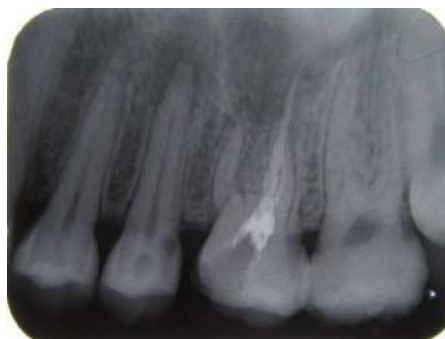

Figure 3. After Endodontic Treatment

Treatment

Treatment plan was decided: root canal treatment for 26, resection of the mesiobuccal root of 26, followed by restoring the teeth 26 with porcelain fused to metal crown.

a. Endodontic Phase

Isolated the tooth with rubber dam, then the next step is access opening to the pulp chamber. Measuring the length of distobuccal and palatal root with the aid of an electronic apex locator (Root ZX II, Morita). The root canal was cleaned and shaped by using the endodontic instrument ProTaper NEXT (Dentsply Sirona). Canals were irrigated with 2.5% sodium hypochlorite, 2% chlorhexidine and aquades. Dressing with calcium hydroxide paste for one week (UltraCal® XS, Ultradent Product, Inc.). A week later, the root canal was filled with AH-Plus® sealer and Protapper gutta-percha, followed by a temporary fill (Figure 3).

b. Root Resection Phase

Seven days after completing the root canal treatment and taking patient blood test, then it was followed by resection of the 26 mesiobuccal root. Asepsis with povidone iodine in the surgical area and then performed anesthesia on the area by buccal and palatal using 2% of lidocaine infiltration with 1: 80.000 adrenaline. Resection of mesiobuccal root was carried out using the vertical-cut method. Two vertical cuts were initiated in the furcation and along the crown using a long shank thin, tapering diamond point. First cut was initiated on the buccal aspect, whereas the second cut was made on the mesial aspect of 26. Both the vertical cuts were carried through the furcation toward the center of the tooth and connected with each other to separate the mesiobuccal root (figure 4). After the completion of root separation, the root was removed from the socket using the periosteal elevator and taken

out (Figure 5.6).

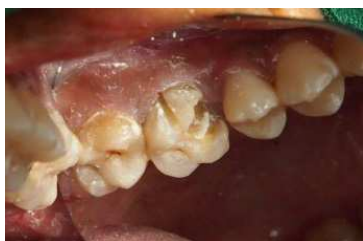

Figure 4. Sectioning the tooth

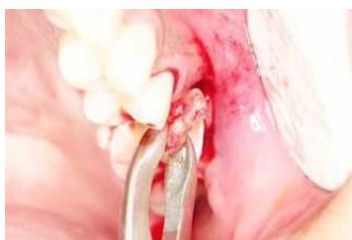

Figure 5. Resected mesiobuccal root

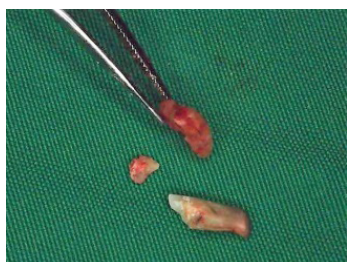


Figure 6. The extracted MB root fragment

An odontoplasty was then performed to remove the overhanging edges of the remaining tooth structure (fig.7).

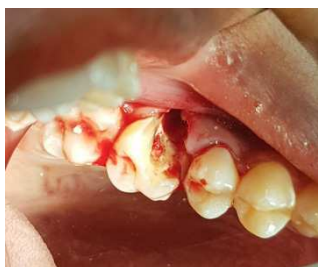

Figure 7. An odontoplasty remaining tooth structure

Then debridement and irrigation using sterile saline and bone graft (Gamacha®) were placed in sockets and sutured using 3-0 black silk suture. Thereafter for maintaining the tooth, fiber splint was used in associated with the 27 coronal (Fig. 8). Periodontal dressing was placed and instructions was given.

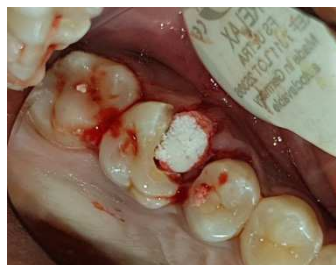

Figure 8. Bonegraft placement

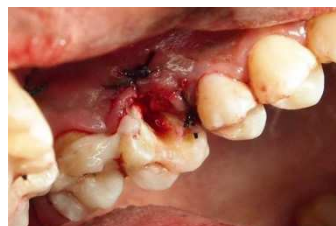

Figure 9. Sutures Given, placement of fiber splint.

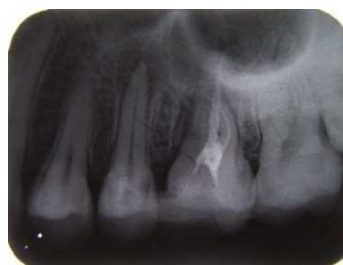

Figure 10. Post operative radiograph

After the surgery was done, a 7-day course of antibiotic and analgesic prescription was given. Patients were recalled after one week for evaluation. During the recall, there was no subjective complaint, the suturing was still good, the splinting was still good, the percussion was negative then the suture were removed (figure 11).

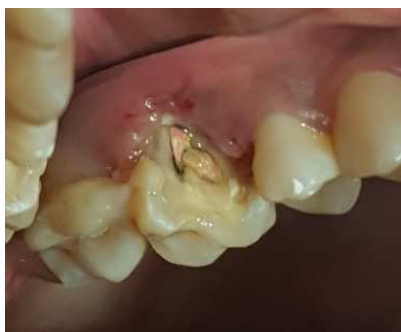

Figure 11. Suture Removal

c. Evaluation phase

After 4 weeks of evaluation, the patient did not complain any subjective symptoms, good soft tissue healing and showed the mobility of the teeth of grade 0-I. Then, guttapercha reduction and post-prefabricated preparation was done (LuxaPost®, DMG), then the post-cementation was done using Rely X Unicem Self Adhesive Universal Resin Cement (3M ESPE, Germany) followed by core build up with composite resin (Multi Core, Ivoclar). Tooth preparation for crown pfm with chamfer finish line with 2 mm width was done. (Figure 12).

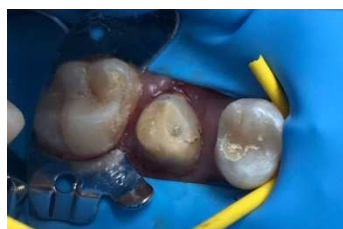

Figure 12. Crown preparation

Final impression was taken after retraction of gingiva using polyvinyl siloxane with 2-step system (Flexitime® VPS Impression Material, Heraeus Kulzer) and antagonist impression using alginate. Next step is the dental color determination with shade guide (3D Vitamin MasterVita, Germany). Then it is followed by crown temporization with Luxatemp Ultra from DMG America. Porcelain fused to metal (pfm) was fabricated and inserted by considering the occlusion, contour and color in the patient's mouth, then the tooth surface was rinsed by water spray and dry air and cemented with Fuji I (GC America) (Figure 13).

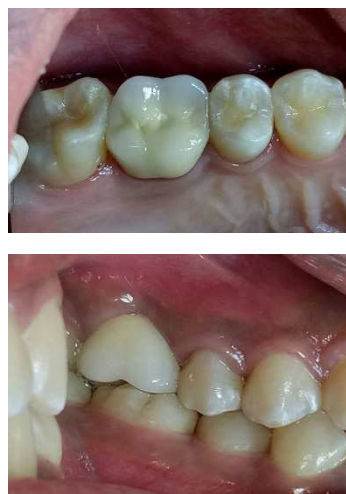

Figure 13. Cemented Porcelain Fused to Metal crown

Periodontal probing depths around the tooth were within normal range and it showed uneventful healing of the respected area after which prosthesis in the form of crown was given (Fig.14)

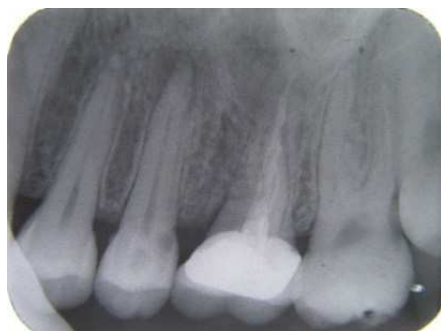

Figure 14. Radiograph taken after cemented final prosthesis

DISCUSSION

As there are more people are aware of dental health and want to keep their teeth maintained, a dentist should try to provide conservative treatment options based on clinical conditions, age, patient's economic considerations, and based on the best clinical evidence of successful treatment.

Root resection therapy is a treatment option for molars with endodontic, periodontal, or prosthetic problems. Weine⁶ mentioned the following dental resection indications:

Periodontal indications:

1. Severe vertical bone loss involving only one root of multi-rooted teeth.
2. Going through furcation destruction.
3. Unfavorable circumference of adjacent teeth roots, preventing

adequate hygiene maintenance in proximal areas.

4. Severe root exposure due to dehiscence.

Endodontic and restorative indications:

1. Prosthetic failure of abutments within a splinted prosthesis: If a single or multi-rooted tooth is periodontal involved within a fixed bridge, instead of removing the entire bridge, if the remaining abutment support is sufficient, the root of the involved tooth is extracted.
2. Endodontic failure: there is perforation perforation through the base of the pulp chamber, or root canal from one of the untenable roots.
3. One root vertical fracture: The vertical fracture prognosis is hopeless. If the vertical fracture crosses one root while the other root is unaffected, the broken root is resected.
4. Severe destructive: due to furcation or sub-gingival caries, traumatic injuries and large root perforations during endodontic therapy.

However, it is also necessary to consider the following factors before deciding to perform a root resection procedure:

1. The patient's oral hygiene status, caries and medical index status should be checked thoroughly.
2. Further bone damage around one

root with acceptable bone support levels which can be accepted by the remaining roots around.

3. Angulation and teeth position in the arch. The molar is too into buccal, or lingual, skewed to mesial or distal which cannot be resected.
4. Root divergence - teeth with divergent roots are easier to resect. Roots with close proximity to other roots have a poor prognosis.
5. The length and curvature of roots, long and straight roots are more favorable to resection than short and conical roots.
6. Length and curvature of roots - long and straight roots are more favorable for resection than short, conical roots

Contradiction:

1. Bad oral hygiene.
2. Unified roots
3. Unfavorable tissue architecture
4. Retained roots are endodontically untreatable.

In the current case, maxillary molars with mesiobuccal root fractures was preserved in the short term by surgical removal of the fractured roots. The cause of the fractured root in this case may be due to excessive chewing forces in the teeth with severe caries condition that weakens the tooth. Fractured roots are usually characterized by a history of severe pain when biting food.

In this case, the tooth has a healthy

periodontium supporting the distal and palatal roots, good oral hygiene, correct dental curvature position, divergent roots and absence of bruxism adds the advantages.

As a final restoration, full coverage crown was given, In this case, porcelain fuse to metal (pfm) was given. Crown helps prevent fracture and allows the clinician to control the occlusion. The final functional purpose of restoration should facilitate oral hygiene, preserve the coronal restorative seal, and provide occlusal harmony to decrease the probability of subsequent root fracture. Well contoured full coverage restorations that cover all of the exposed structure resected is indicated. But restorations can cause periodontal destruction if the margins are not good enough or if the non-occlusal surface has no physiological contours. Restoration must maintain its biological width and odontoplasty to flatten the mesial concavity and create a maintainable topography. Improper contoured occlusal surface can transfer destructive force and cause the tooth trauma due to occlusion and a major failure in root resection therapy. To achieve good results on periodontal tissue, > 50% of the bone buffer tissue from the remaining roots should be present⁷.

CONCLUSION

With recent advancements in endodontics, periodontics and restorative dentistry, root resection has received acceptance as a conservative and effective

treatment and have endured the demands of function.

REFERENCES

1. Park SY, Shin SY, Yang SM, Kye SB. Factors influencing the outcome of root- resection therapy in molars: A 10-year retrospective study. J Periodontol 2009;80:32-40
2. Farrar JM. Radical and heroic treatment of alveolar abscess by amputation of roots of teeth. Dental Cosmos 1884;26:7912
3. Buhler H. Evaluation of Root Resected Teeth. Result 10 Years. J Peiodontal 1988; 59:805-810
4. Blomlof L, Jansson L, Appelgren R, Ehnevid H, Lindskog S. Prognosis and mortality of root-resected molars. Int J Periodontics Restorative Dent. 1997;17(2):190-201.
5. Jamal Aqrabawi. Root Amputation: A Prudent Alternative to Tooth Extraction. Adv Dent & Oral Health. 2016; 2(2)
6. Franklin S. Weine, Endodontic therapy, 6th edition; Mosby Inc. 2004:423-451
7. Zeina Majzoub and Simao Konf. Tooth Morphology Following Root Resection Procedures in Maxillary First Molars. J Periodontol. April 1992 : 290-296

THE POTENTIAL ROLE OF PROPOLIS ON DENTIN REGENERATION AND REPAIR DURING DIRECT PULP CAPPING TREATMENT

Ardo Sabir^{1,2*}, Juni Jekti Nugroho²

¹Resident of Specialist Conservative Dentistry Program Study

²Department of Conservative Dentistry
Faculty of Dentistry, Hasanuddin University
Jl. Perintis Kemerdekaan KM 10, Tamalanrea
Makassar 90245, Indonesia

ABSTRACT

Dental pulp is sometimes exposed during clinical procedures, such as cavity preparation (iatrogenic) or caries removal. Until now, direct pulp capping is considered to be a valid treatment when pulp exposed because successful capping can preserve tooth vitality and function. Researchers have demonstrated that the exposed pulp possesses an inherent capacity for healing through reparative dentin formation in the injured site. It has been shown that dental pulp contains precursor cells capable of forming odontoblast-like cells in response to appropriate signals and materials. The sequential steps of proliferation, migration and differentiation of progenitor or stem cells were occurred during the reparative process. A unique population of multipotent mesenchymal progenitor cells known as Dental Pulp Stem Cells (DPSC) with high proliferative potential for self-renewal and multipotential differentiation into odontoblast-like cells has been described and may be important to the regenerative capacity of the tissue. Recently, propolis, a resinous substance produced by honeybee from various plants has been recognized as a useful material to improve oral health. It has several biological properties such as anti-inflammatory, antibacterial and immunomodulatory actions as well as improvement tissue repair. Therefore, the aim of this review is to discuss the potential role of propolis on dentin regeneration and repair during direct pulp capping treatment.

Keywords: Propolis, Dental Pulp Stem Cell (DPSC), Dentin regeneration, Direct pulp capping treatment

*Corresponding author

Dr. Ardo Sabir, DDS, M.Kes

E.mail : ardo.sabir@yahoo.com

INTRODUCTION

Dental pulp sometimes become exposed due to caries, accidental mechanical during cavity preparation or caries removal, tooth fracture or attrition¹. In this situation, the pulp is involved in a process called reparative dentinogenesis, where some of the cells deposit a new matrix as a barrier in the injured site. It has been shown that adult dental pulp contains precursor cells capable of forming odontoblast-like cells in response to appropriate signals and materials². So, in certain cases, using direct pulp capping to save pulpal health and function is recommended. Since the selection of the capping material is a critical factor to produce the best treatment outcome, many studies of capping materials are carried out by researchers. The ideal properties of pulp capping agents are infection control, ease of handling, prevention of microleakage and promotion of hard tissue formation³.

During the reparative process in exposed pulp primary odontoblasts that were lost are replaced with newly differentiated odontoblast-like cells. This process is known to follow the sequential steps of proliferation, migration and differentiation of progenitor or stem cells⁴. It has been suggested that these newly formed cells were the pulp cells and undifferentiated mesenchymal cells. However, Gronthos has reported the presence of a unique population of postnatal Dental Pulp Stem Cells (DPSC) with self-renewing, highly proliferative capacity and multipotential

differentiation into odontoblast-like cells which formed the dentin matrix with some tubular features *in vivo*⁵. Some other researchers have also identified a potential mesenchymal stem cell population derived from exfoliated deciduous human teeth, named as Stem cells of Human Exfoliated Deciduous (SHED) teeth, capable of extensive proliferation and multipotential differentiation to these cells^{5,6}.

Various materials have been used in vital pulp procedures, especially direct pulp capping. Calcium hydroxide has been extensively and regularly used for direct pulp capping in modern clinical dentistry. As it is known to have a potential role in inducing hard tissue repair, this material has been applied to the exposed pulp and the hard tissue is expected to be regenerated over the pulp. The antibacterial effect of calcium hydroxide relates directly to its high pH (12.5), which has destructive effect on cell membranes and protein structures. The action of calcium hydroxide is dependent on its dissociation and the release of hydroxyl ions (OH⁻), which diffuse into the surrounding tissues and result in the formation of a necrotic layer⁷. The reparative dentin which is formed by calcium hydroxide is porous and is not a complete barrier. As the result, development of biocompatible materials that induce normal dentin-pulp complex is preferred⁸.

Recently propolis (bee glue) has been recognized as a useful material for human health and veterinary medicine. Made by

the honeybee, it is a potent antibacterial and anti-inflammatory agent. Honeybees collect the resin from cracks in the bark of trees and leaf buds⁹. In general, propolis is composed of 50% resin and vegetable balsam, 30% wax, 10% essential and aromatic oils, 5% pollen and 5% other various substances, including organic debris depending on the place and time of its collection^{9,10}. The constituents of propolis vary widely due to climate, season and location; so its chemical formula is not stable¹¹.

Studies of propolis applications have increased because of its therapeutic and biological properties. Current research involving propolis in dentistry spans many fields such as in oral surgery, periodontics, conservative dentistry and endodontics. Using propolis in conservative dentistry and endodontic treatment to treat tooth and pulp diseases is a popular practice such as cariostatic agent in suppressing cariogenic bacteria¹², desensitizing agent to treat hypersensitivity dentin¹³, intracanal irrigant¹⁴, cavity disinfecting agent in atraumatic restorative treatment¹⁵, medicament during root canal treatment¹⁶, and also as direct pulp capping agent¹⁷. Therefore, the main aim of this review was to evaluate to discuss the potential role of propolis on dentin regeneration and repair during direct pulp capping treatment.

LITERATURE REVIEW

Stem cells in regenerative medicine

A stem cell is defined as a cell that can continuously produce unaltered daughters and, furthermore, has the ability to generate cells with different and more restricted properties. Stem cells can divide either symmetrically (allowing the increase of stem cell number) or asymmetrically. Asymmetric divisions keep the number of stem cells unaltered and are responsible for the generation of cells with different properties. These cells can either multiply (progenitors or transit amplifying cells) or be committed to terminal differentiation. Progenitors and transit amplifying cells have a limited lifespan and therefore can only reconstitute a tissue for a short period of time when transplanted. In contrast, stem cells are selfrenewing and thus can generate any tissue for a lifetime. This is a key property for a successful therapy. The capacity to expand stem cells in culture is an indispensable step for regenerative medicine, and a considerable effort has been made to evaluate the consequences of the cultivation on stem cell behaviour¹⁸.

Stem cells cannot be identified with certainty in any tissue: scientists rely on indirect properties such as the expression of a repertoire of surface proteins, slow cell cycle, clonogenicity, or an undifferentiated state. However, none of these criteria are specific. The evaluation of selfrenewal is the ultimate way to show “stemness”, which relies on the isolation and transplantation of a putative stem cell (clonal analysis)

followed by its serial transplantation and long-term reconstitution of a tissue¹⁸.

Recent years, stem cells have been used extensively in many medical disciplines for the repair and/or regeneration of defective tissues and organs (e.g. bone, ligament, heart). New therapeutic approaches are largely inspired and based on our knowledge of embryonic development. The aim of regenerative medicine is to stepwise re-create *in vitro* all the mechanisms and processes that nature uses during initiation and morphogenesis of a given organ. In this context, stem cell research offers an amazing and seductive potential for body homeostasis, repair, regeneration and pathology. The possibility of manipulating stem cells *in situ* using specific signalling molecules or by expanding them *ex vivo* is an exciting outcome of basic research. Hence, regenerative medicine has become a fashionable field and the isolation and manipulation of embryonic and adult (or post-natal) stem cells for the creation of new functional organs that will replace the missing or defective organs constitutes an enormous challenge. Embryonic and Adult Stem Cells (ASC) have been under intense investigation that focuses on the *in vitro* development of new organs such as hair, skin and bone. Adult Stem Cells, which possess a restricted potential of differentiation, can easily be isolated from a patient and after *in vitro* amplification and/or differentiation could be re-injected to the same patient thus avoiding immunerejection, as is the case

for allografts or xenografts. Since numerous problems remain, the ideal protocol for human pathologies is far away from being used. However, the knowledge in stem cell technology is increasing quickly in all medical disciplines and dictates the need for new strategic approaches in all fields, including reparative dentistry. Stem cell therapy constitutes a common challenge for dentists as well as biologists¹⁸.

Adult Dental Pulp Stem Cells (DPSC).

After a dental injury, dental pulp is involved in a process called reparative dentinogenesis, where cells elaborate and deposit a new dentin matrix for the repair of the injured site¹⁹. It has been shown that adult dental pulp contains precursors capable of forming odontoblasts under appropriate signals^{5,20-23}. Among these signals are the calcium hydroxide or calcium phosphate materials, which constitute pulp-capping materials used by dentists for common dental treatments. Dental pulp progenitors have not been clearly identified but some data suggest that pericytes, which are able to differentiate into osteoblasts, could also differentiate into odontoblasts²⁴⁻²⁶. Tooth repair is a lifetime process thus suggesting that Mesenchymal Stem Cells (MSC) might exist in adult dental pulp. The *in vivo* therapeutic targeting of these ASC remains to be explored.

Propolis and its characteristics

In a recent years the researchers were searching for natural products with medicinal properties, particularly those from plants and bees to found a natural anti-inflammatory agent. Several plants produce resinous exudates with strong antibacterial and anti-necrotic properties, in addition to impermeability provided by populus a substance from *Populus* sp²⁷. Bees collect resin exudates from certain plants and add their secretion, wood fragments, pollen, and wax; this product from bees and plants is called propolis. The word propolis comes from the Greek *pro* meaning in defense of and *polis* city, representing defense of bee cities (or beehives). Propolis has been used in folk medicine since primeval times. Nowadays, propolis is still used in home made remedies and cosmetics. Two characteristics of propolis are its smell and its various colors from dark green to brown²⁸.

The chemical composition of propolis has been correlated with plant diversity around the beehive¹¹. In general, raw propolis is composed of around 50% resins, 30% waxes, 10% essential oils, 5% pollen and 5% of various organic compounds. More than 300 constituents were identified in different samples and new ones are still being recognized during chemical characterization of new types of propolis^{9,10}. The proportions of the various substances present in the propolis depend upon its place and time of collection¹¹.

Many analytical methods have been used for separation and identification of propolis constituents and the substances identified belong to the following groups of chemically similar compounds: polyphenols; benzoic acids and derivatives; cinnamic alcohol and cinnamic acid and its derivatives; sesquiterpene and triterpene hydrocarbons; benzaldehyde derivatives; other acids and respective derivatives; alcohols, ketones, and heteroaromatic compounds; terpene and sesquiterpene alcohols and their derivatives; aliphatic hydrocarbons; minerals; sterols and steroid hydrocarbons; sugars and amino acids. The components of propolis are also rich in vitamins such as B1, B2, B6, C, E and mineral elements like Mg, Ca, I, K, Na, Cu, Zn, Mn and Fe. It also contains number of fatty acids and enzymes as succinic dehydrogenase, glucose-6-phosphatase, adenosine triphosphatase and acid phosphatase²⁹. Considering that propolis is a complex mixture, synergistic interactions between its compounds must also be considered as an important factor in its anti-inflammatory activity.

Ethanol, the most commonly used solvent for propolis preparations, and other solvents such as ethylic ether, water, methanol, petroleum ether, and chloroform are used for extracting and identifying many propolis compounds. Moreover, glycerin, propylene glycol and some solutions have been used in propolis preparations by the pharmaceutical and cosmetic industry³⁰.

Role of propolis on direct pulp capping treatment

Knowledge of pulp physiology has increased considerably in recent years and led to a better understanding of pulp healing. Nonetheless the criteria agreed to characterize successful direct pulp capping vary among authors. The clinical criteria for successful pulp capping are that the tooth is free of symptoms, there is adequate reaction to sensitivity tests and the tooth has a normal radiographic appearance. As inflammation complicates the healing of pulp, a critical evaluation of the results of pulp capping can only be made histologically. Following injury to mature tooth pulp, progenitor cells recruit the repair processes and differentiate into second generation odontoblasts. Although in general practice direct pulp capping is usually considered to be a temporary treatment, it has been suggested as a permanent treatment^{4,8}.

In restorative dentistry, calcium hydroxide compounds are the gold standard for vital pulp therapy in human teeth⁷. The procedure is carried out on pulps which are contaminated with bacteria and where there is a potential risk of bacterial leakage along the restoration margins⁸. Evidence shows limited effectiveness of calcium hydroxide to eliminate bacteria from human root canals completely^{31,32}. Propolis is a good antibacterial and antifungal agent³³. It breaks down bacterial cell walls, cytoplasm and prevents bacterial cell division³⁴.

Propolis can be used to decrease

permeability of the dentin and to direct pulp capping in order to create reparative dentin³⁵. Direct pulp capping with materials such as adhesive resins is a technique used to seal the dental pulp, which may become expose due to mechanical and/or chemical factors as well as bacterial activity in order to stimulate the pulp to create reparative dentin³⁶. The regenerative effect of propolis on the tooth pulp has been known for a long time³⁷. Nevertheless, there is no consent on the subject of propolis extracts effectiveness in comparison with calcium hydroxide which is most often used in stimulation of creation a reparative dentin.

Silva *etal*³⁸ compared between propolis to other experimental materials was the least irritant one which can make it a valuable alternative in endodontics. Al-Shaher*etal*³⁹ treated the fibroblasts of the pulp and periodontal ligament with propolis and concluded that this material is not toxic. Scheller*etal*³⁷ showed regeneration of the pulp by applying propolis on injured dental pulp, while calcium hydroxide caused necrosis of the pulp chamber⁸.

Bretz *et al*³⁹ state that there are no important differences in direct capping with propolis and with calcium hydroxide-based products. Both of them offer a similar degree of healing pulp inflammation, reducing quantity of microbes and stimulating creation of dentin bridge. Also the study carried out by Ozorio *et al*⁴¹ indicate that propolis and calcium hydroxide have similar effectiveness in induction to create reparative dentin.

However, the results of the research done by Ahangari *et al*⁴² on guinea pig incisor tooth prove clearly higher effectiveness of direct pulp capping with propolis than with calcium hydroxide-based products. It not only stops inflammatory reaction, infection with microbes and pulp necrosis but also induces formation of high quality tubular dentin through stimulation of stem cells. Flavonoids and caffeic acid present in propolis are known to play an important role in reducing the inflammatory response by inhibiting the lipoxygenase pathway of arachidonic acid. Flavonoids and Caffeic Acid Phenethyl Ester (CAPE) also aid the immune system by promoting phagocytic activities and stimulating cellular immunity⁴³.

Ansorge *et al*⁴⁴ has shown the ability of propolis to stimulate the production of Transforming Growth Factor-Beta 1 (TGF- β 1) which is important for the differentiation of odontoblasts. It also induces the synthesis of collagen by dental pulp cells⁴⁵. Bretz *et al*⁴⁶ reported formation of reparative dentin in direct pulp capping treatment with propolis. In our previous study, we found partial dental bridge formation after 4 weeks with propolis⁴⁷. Parolia *et al*¹⁷ conducted a study on permanent teeth. They concluded that dentinal bridge formation and tubular dentin were more evident in propolis and Mineral Trioxide Aggregates (MTA), whereas most of the calcium hydroxide specimens showed incomplete bridge formation with amorphous and

non-tubular dentin. In other studies incomplete formation of dentinal bridge and tunnel defects have been reported in cases treated with calcium hydroxide^{4,8}.

DISCUSSION

Our understanding of the biology of the pulp has improved significantly in recent years and this has allowed us to present more robust hypotheses regarding the molecular and cellular processes responsible for dental regeneration. However, it is still not possible to state with any certainty which cell populations and which specific molecular signalling pathways predominated during dental regeneration, although the variety of cell populations potentially involved and many of the signalling events are becoming clearer².

The intensity and duration of the tissue injury, the involvement of inflammatory processes and their possible exacerbation by bacteria will all impact on the tissue environment in which regeneration takes place. This environment will be further influenced by host factors, such as ageing, which will modify the cell populations present and systemic and innate immunity. A number of these factors may also influence the availability and/or the ability of cell-signalling molecules, which may be sequestered within the dentine²³.

It was biochemically and physiologically evident that calcium hydroxide increased the recruitment, migration, proliferation, and mineralization of the DPSC. Such a result is valuable for their *in vitro*

examination of the relationship between the DPSCs, recently focused as the source of cells that are important in the regeneration of dentin upon injury, and calcium hydroxide, the most commonly used pulp capping agent until now⁴.

Future studies must focus on the molecular and cellular changes playing an important role in tooth regeneration, physiology-embryology, the treatment-related procedures, and stem cell-related therapies, which will contribute to a better dental practice. We are now facing a new era of restorative dentistry, regulating the biological activity of the dental tissue to stimulate the wound healing process and tissue regeneration.

Recently, propolis, a resinous substance produced by honeybee from various plants has been recognized as a useful material to improve oral health. It has several biological properties such as anti-inflammatory⁴⁸, antibacterial^{11,12,16} and immunomodulatory⁴⁹ actions as well as improvement tissue repair. Propolis could stimulate dental stem progenitor cells⁴². It also provides evidence that propolis has advantages over calcium hydroxide as a capping agent in vital pulp therapy. In addition to producing no pulpal inflammation, infection or necrosis, this material induces the production of a tubular and high quality dentin¹⁷.

CONCLUSION

Propolis has a potential role on dentin regeneration and repair during direct pulp

capping treatment. However, clinical trials previously performed suggest that additional information about tooth stem cell and their medical application is essential to understand the therapeutic real efficacy, cell survival, and functionality in long terms.

REFERENCES

1. Mejäre IA, Axelsson S, Davidson T, Frisk F, Hakeberg M, Kvist T, et al. Diagnosis of the condition of the dental pulp: a systemic review. *Int Endod J*. 2012; 45: 597-613.
2. Bluteau G, Luder HU, De Bari C, Mitsiadis TA. Stem cells for tooth engineering. *Eur Cell Mater*. 2008; 31; 16: 1-9.
3. Schroder U. Effect of calcium hydroxide containing pulp-capping agent on pulp cell migration, proliferation, and differentiation. *J Dent Res*. 1985; 64, 541-8.
4. Ji YM, Jeon SH, Park JY, Chung JH, Choung YH, Choung PH. Dental stem cell therapy with calcium hydroxide in dental pulp capping. *Tissue Eng Part A*. 2010; 16; 6: 1823-33.
5. Gronthos S, Brahimi J, Li W, Fisher LW, Cherman N, Boyde A, Den Besten P, Robey PG, Shi S. Stem cell properties of human dental pulp stem cells. *J Dent Res*. 2002; 81; 8: 531-5.
6. Nourbakhsh N, Talebi A, Mousavi B, Nadali F, Torabinejad M, Karbalaie KH. Isolation of mesenchymal stem

- cells from dental pulp deciduous teeth. *Yakhteh*. 2008; 10; 2: 101-8.
7. Olsen H, Peterson K, Rohlin M. Formation of a hard tissue barrier after pulp capping in humans: A systemic review. *IntEndod J*. 2006; 39: 429-42.
 8. Hørsted-Bindslev P, Løvschall H. Treatment outcome of vital pulp treatment. *Endodontic Topics*. 2002; 2: 24-34.
 9. Bankova V, Castro SL, Marcucci MC. Propolis: recent advances in chemistry and plant origin. *Apidologie*. 2000; 31: 3-15.
 10. Markham KR, Mitchell KA, Wilkins AL, Daldy JA, Lu Y. HPLC and GC-MS identification of the major organic constituents in New Zealand propolis. *Phytochemistry*. 1996; 42; 1: 205-11.
 11. Sforcin JM, Fernandez A, Lopez CA, Bankova V, Funari SR. Seasonal effect on Brazilian propolis antibacterial activity. *J Ethnopharmacol*. 2000; 73; 1-3: 243-9.
 12. Anauate Netto C, Marcucci MC, Paulino N, Anido-Anido A, Amore R, de Mendonça S, et al. Effects of typified propolis on mutans streptococci and lactobacilli: a randomized clinical trial. *Braz Dent Sci*. 2013; 16; 2: 31-6.
 13. Purra AR, Mushtaq M, Acharya SR, Saraswati V. A comparative evaluation of propolis and 5.0% potassium nitrate as a dentine desensitizer: A clinical study. *J Indian SocPeriodontol*. 2014;18; 4:466-71.
 14. Bhardwaj A, Velmurugan N, Sumitha, Ballal S. Efficacy of passive ultrasonic irrigation with natural irrigants (Morindacitrifolia juice, Aloe Vera and Propolis) in comparison with 1% sodium hypochlorite for removal of *E. faecalis* biofilm: An in vitro study. *Indian J Dent Res*. 2013;24; 1:35-41.
 15. Prabhakar AR, Karuna YM, Yavagal C, Deepak BM. Cavity disinfection in minimally invasive dentistry- comparative evaluation of Aloe vera and propolis: A randomized clinical trial. *Contemp Clin Dent*. 2015; 6 (Suppl 1): S24-31.
 16. Bazvand L, Aminozarbian MG, Farhad A, Noormohammadi H, Hasheminia SM, Mobasherizadeh S. Antibacterial effect of triantibiotic mixture, chlorhexidine gel, and two natural materials Propolis and Aloe vera against *Enterococcus faecalis*: An ex vivo study. *Dent Res J*. 2014; 11: 469-74.
 17. Parolia A, Kundabala M, Rao NN, Acharya SR, Agrawal P, Mohan M, et al. A comparative histological analysis of human pulp following direct pulp capping with Propolis, Mineral Trioxide Aggregate and Dycal. *Aust Dent J*. 2010; 55; 1:59-64.
 18. Bluteau G, Luder HU, De Bari C, Mitsiadis TA. Stem cells for tooth engineering. *European Cells and Materials*. 2008; 16: 1-9.
 19. Mitsiadis TA, Rahiotis C. Parallels between tooth development and repair:

- conserved molecular mechanisms following carious and dental injury. *J Dent Res.* 2004; 83: 896-902.
20. About I, Mitsiadis TA. Molecular aspects of tooth pathogenesis and repair: *in vivo* and *in vitro* models. *Adv Dent Res.* 2001; 15: 59-62.
 21. Miura M, Gronthos S, Zhao M, Lu B, Fisher LW, Robey PG, Shi S. SHED: stem cells from human exfoliated deciduous teeth. *Proc Natl AcadSci USA.* 2003; 100: 5807-12.
 22. Alliot-Licht B, Bluteau G, Magne D, Lopez-Cazaux S, Lieubeau B, Daculsi G, Guicheux J. Dexamethasone stimulates differentiation of odontoblast-like cells in human dental pulp cultures. *Cell Tissue Res.* 2005; 321: 391-400.
 23. Téclès O, Laurent P, Zygouritsas S, Burger AS, Camps J, Dejou J, About I. Activation of human dental pulp progenitor/stem cells in response to odontoblast injury. *Arch Oral Biol.* 2005; 50: 103-8.
 24. Shi S, Gronthos S. Perivascular niche of postnatal mesenchymal stem cells in human bone marrow and dental pulp. *J Bone Miner Res.* 2003; 18: 696-704.
 25. Alliot-Licht B, Bluteau G, Magne D, Lopez-Cazaux S, Lieubeau B, Daculsi G, Guicheux J. Dexamethasone stimulates differentiation of odontoblast-like cells in human dental pulp cultures. *Cell Tissue Res.* 2005; 321: 391-400.
 26. Lovschall H, Mitsiadis TA, Poulsen K, Jensen KH, Kjeldsen AL. Coexpression of Notch 3 and Rgs 5 in the pericyte-vascular smooth muscle cell axis in response to pulp injury. *Int J Dev Biol.* 2007; 51: 715-21.
 27. Greenaway W, Scaysbrook T, Whatley FR. The composition and plant origins of propolis: A report of work at Oxford. *Bee World.* 1990; 71: 107-18.
 28. Marcucci M. C., Rodriguez J., Ferrerez F., Bankova V., Grotor, Popov, S. Chemical composition of Brazilian propolis from São Paulo State. *Z. Naturforsch [C].* 1998; 53: 117-9.
 29. Parolia A, Thomas MS, Kundabala M, Mohan M. Propolis and its potential uses in oral health. *Int J Med and Med Science.* 2010; 2; 7: 210-15.
 30. Castaldo S, Capasso F. Propolis, an old remedy used in modern medicine. *Fitoterapia.* 2002; 73 Suppl 1: S1-S6.
 31. Asgary S, Eghbal MJ, Parirokh M, Ghoddusi J. SEM evaluation of pulp reaction to different pulp capping materials in dog's teeth. *Iranian Endodontic J.* 2007; 1; 4: 117-23.
 32. Sathorn C, Parashos P, Messer H. Antibacterial efficacy of calcium hydroxide intracanal dressing: a systematic review and meta-analysis. *IntEndod J.* 2007; 40; 1: 2-10.
 33. Ahangari Z, Eslami G, Koosedghi H, Ayatollahi A. Comparative study of antibacterial activity of

- propolis and Ca(OH)₂ against lactobacillus, enterococcus faecalis, peptostreptococcus and candida albicans. JIDA. 2009; 21; 1: 50-6.
34. Takaisi-Kikuni NB, Schilcher H. Electron microscopic and microcalorimetric investigations of the possible mechanism of the antibacterial action of a defined propolis provenance. Planta Med. 1994; 60; 3: 222-7.
 35. Parolia A, Kundabala M, Rao NN, Acharya SR, Agrawal P, Mohan M. A comparative histological analysis of human pulp following direct pulp capping with Propolis, Mineral Trioxide Aggregate and Dycal. Aust Dent J. 2010; 55; 1: 59-64.
 36. de Souza Costa CA, Hebling J, Hanks CT. Current status of pulp capping with dentin adhesive systems: a review. Dent Mater. 2000; 16: 188-97.
 37. Scheller S, Ilewicz L, Luciak M, Skrobudurska D, Stojko A, Matuga W. Biological properties and clinical application of propolis IX. Experimental observation on the influence of ethanol extracts of propolis (EEP) on dental pulp regeneration. ArzneimForsch. 1978; 28: 289-91.
 38. Silva FB, Almeida JM, Sousa SM. Natural medicaments in endodontics- a comparative study of the anti-inflammatory action. Braz Oral Res. 2004; 18; 2: 174-9.
 39. Al-Shaher A, Wallace J, Agarwal S, Bretz W, Baugh D. Effect of propolis on human fibroblasts from the pulp and periodontal ligament. J Endod. 2004; 30; 5: 359-61.
 40. Bretz WA, Chiego DJ Jr, Marcucci MC, Cunha I, Custódio, Schneider LG. Preliminary report on the effects of propolis on wound healing in the dental pulp. Z Naturforsch C. 1998; 53; 11-12: 1045-8.
 41. Ozorio JE, Carvalho LF, de Oliveira DA, de Sousa-Neto MD, Perez DE. Standardized propolis extract and calcium hydroxide as pulpotomy agents in primary pig teeth. J Dent for Child. 2012;79; 2: 53-8.
 42. Ahangari Z, Naseri M, Jalili M, Mansouri Y, Mashhadiabbas F, Torkaman- Pharm A. Effect of propolis on dentin regeneration and the potential role of dental pulp stem cell in Guinea Pigs. Cell J. 2012; 13; 4: 223-8.
 43. Djurica G, Danilovic V, Krsljak E. The effect of caffeic acid phenethyl ester on healing capacity and repair of the dentin-pulp complex *in vivo* study. ActaVeterinaria. 2008; 58; 1: 99-108.
 44. Ansorge A, Reinhold D, Lendeckel U. Propolis and some of its constituents down-regulate DNA synthesis and inflammatory cytokine production but induce TGF- β 1 production of human immune cells. Z Naturforsch [C]. 2003; 58; 7-8: 580-9.

45. Sabir A. 2015. Expression of TNF- α , COX-2 and collagen fibre density as a result of *Trigonasp*propolis application in dental pulp inflammation Sprague-Dawley rats. Dissertation. Hasanuddin University, Makassar (In Indonesian).
46. Bretz WA, Chiego Jr DJ, Marcucci MC, Cunha I, Custódio A, Schneider LG. Preliminary report on the effects of propolis on wound healing in the dental pulp. *Z Naturforsch [C]*. 1998; 53; 11-12: 1045-8.
47. Sabir A, Tabbu CR, Agustiono P, Sosroseno W. Histological analysis of rat dental pulp tissue capped with propolis. *J Oral Sci*. 2005; 47; 3: 135-8.
48. Wang K, Zhang J, Ping S, Ma Q, Chen X, Xuan H, et al. Anti-inflammatory effects of ethanol extracts of Chinese propolis and buds from poplar (*Populus x canadensis*). *J Ethnopharmacol*. 2014; 155; 1: 300-11.
49. Sforcin JM. Propolis and the immune system : a review. *J Ethnopharmacol*. 2007; 113; 1: 1-14.

AESTHETIC CORRECTION OF A MICRODONTIC TOOTH USING DIRECT COMPOSITE RESIN : A CASE REPORT

Mulia Rahmah¹, Cecilia G Lunardhi²

¹ PPDGS, Bagian Konservasi Gigi, Fakultas Kedokteran Gigi, Universitas Airlangga

² Staf Pengajar Bagian Konservasi Gigi, Fakultas Kedokteran Gigi, Universitas Airlangga

ABSTRACT

Background: *Microdontia is of the commonest developmental anomaly affecting dentition. The commonly is lateral incisors. The conservative aesthetic treatment approach is composite resin restorations.* **Purpose:** *To correct esthetics right lateral incisor due to small size.* **Case report:** *A 21 year old female with microdontia in relation to left maxillary lateral incisor. Clinical examination and periapical radiograph tooth was small, An esthetic correction the tooth was done by putty index assisted composite resin restoration.* **Management :** *Dental impression was taken to made wax-up tooth 12. Then, palatal matrix was made to assist in guiding palatal portion. Direct resin composite was used as final restoration to correct the tooth esthetic view.* **Conclusion:** *The most conservative and esthetic restorative option for microdontic is composite resin restorations.*

KEY WORDS: *Aesthetic restoration, composite resin, microdontia, palatal matrix technique.*

Correspondence : Mulia Rahmah, Resident of Conservative Dentistry, Faculty of Dental Medicine, Airlangga University, Surabaya – Indonesia. Email : mulia_zilal@yahoo.com

INTRODUCTION

Microdontia is a case tooth morphology which rare phenomenon. Microdontia is defined as the condition which having abnormalities as a small tooth. Based on Boyle, generally, microdontia as the tooth is small, the crowns short, and usually in the proximal, normal contact area is missing. Based on Shafer, there are three types of microdontia: (1) microdontia which only a single tooth, (2) relative generalized microdontia due to relatively small teeth in large jaws, and (3) true generalized microdontia in which all the teeth are smaller than normal.¹

Microdontia of a single tooth can be involving the whole tooth, only crown of the tooth, or root alone.²

The most frequently involved single tooth microdontia is found in maxillary lateral incisor. Aesthetic restorative options for microdontic anterior teeth include, composite resin restorations, porcelain veneers, and full coverage crowns. From all the options, the most conservative is composite resin restorations. In this case report we discuss palatal matrix composite resin restorative technique for treating microdontia tooth.

CASE REPORT

A 21 year old female came to RSGMP Dentistry Faculty of Airlangga University. She was consult from department of orthodontic with the chief complaint of small teeth. The medical and dental histories were normal. Oral examination revealed a permanent dentition, There were tooth 12 microdontic and tooth 22 agenesis (figure 1), on electrical and thermal pulp testing showed normal vital response, radiographic examination was carried out which reveal reduction or small size of root of right lateral incisor as compared to adjacent left incisor which confirmed the diagnosis (figure 2). Operator decided treatment planning to restore tooth 12 with composite resin.

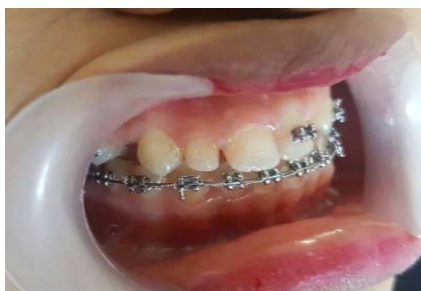

Figure 1. Initial visit

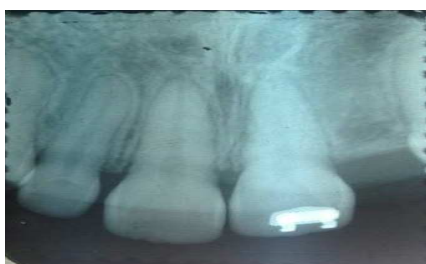

Figure 2. Periapical radiograph

Upper and lower alginate impressions were taken to the patient and then poured with dental stone. On the dental cast 12

waxed – up (figure 3). Then, matrix palatal by silicone impression was made, it made to assist in guiding the application of the first layer palatal and proximal composite layer. Isolation of the operating area with quick dam (Optragate, Ivoclar). The selection of the proper resin shade guide was accomplished based on the maxillary right central incisor (Figure 4).

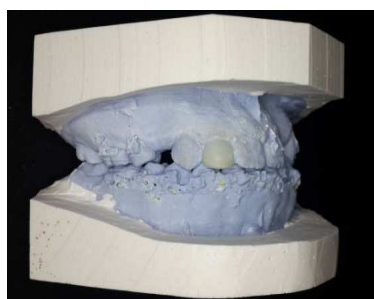

Figure 3. waxed up tooth 12

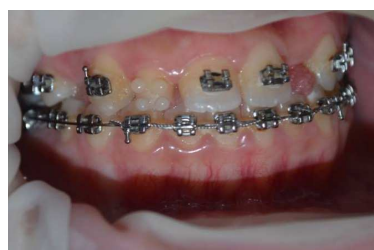

Figure 4. Selection colour shade guide

Tooth 12 was minimally prepared with a diamond bur. The preparation tooth was etched with 37% phosphoric acid for 20 seconds, rinsed with water and dried. The adjacent tooth was separated by using celuloid strip. A single layer of bonding agent (G-Bond, GC) was applied according manufacturer direction and cured for 20 seconds with LED composite curing unit (Figure 5).

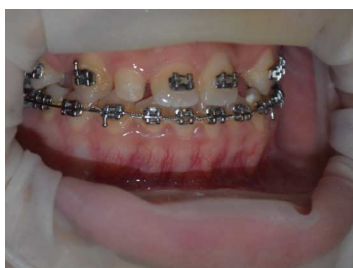

Figure 5. a. .Preparation tooth 12

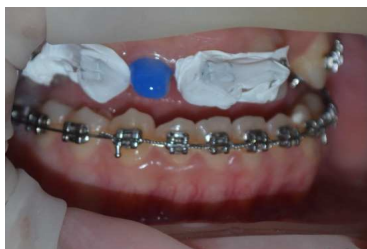

Figure 5.b. Etching phosphoric acid

Palatal matrix was fitted on the patient, palatal layer of teeth were restored by put on the matrix with flowable composite as a thin layer of translucent enamel composite (G-aenial flow, GC) to establish the palatal contour and new incisal edge, then placing matrix on respected tooth. Curing with LED for 20 seconds and matrix palatal was removed (Figure 6).

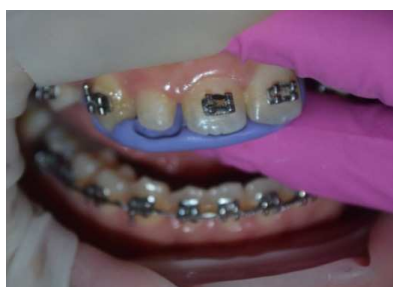

Figure 6. a. Fitting putty impression for palatal and proximal

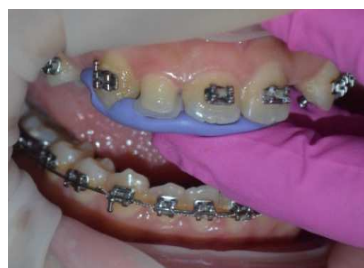

Figure 6. b. Seating palatal matrix with composite resin.

The artificial dentin (custom shade G- aenial, GC) was placed over the facial portion and sculpted in the shape of mammelons. The simulating a depth effect in restoration was sculpted TE (G-aenial TE, GC) in incisal edge. The final layer, which corresponded to artificial enamel was restored with shade A3 for the cervical third, shade A2 enamel for the medial third. The last filled was the whole labial surfaces of tooth were restored with a thin layer of translucent enamel (G-aenial JE, GC) and cured for 20 seconds. Finishing, counturing labial surface and proximal and polishing with sof-lex™XT disc (2381M, 2381F, 2381SF 3M ESPE) (Figure 7). After completing the procedure of oral hygiene was given. And patient was recalled after 6 months so on for follow up.

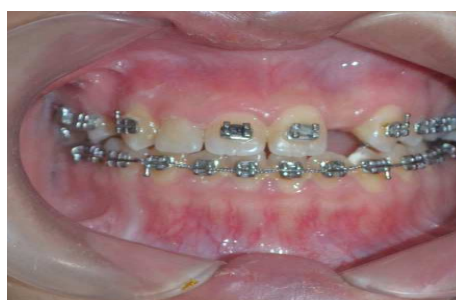

Figure 7. a.. Artificial enamel and dentin was applied

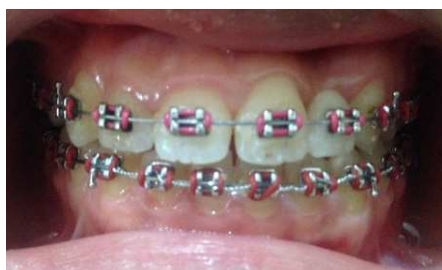

Figure 7. b. Follow up after 6 month

DISCUSSION

Manifestation developmental dental anomalies has various type. It can be occur from the size, number, color, contour. Various local and systemic factors may be responsible for the developmental disturbances of teeth.³ Anomalies shape of morphology tooth like microdontia and macrodontia. Microdontia refers to tooth that are clinically smaller in size than normally. The tooth which always affected with microdontia are maxillary lateral incisors and third molars.⁴

Tooth size can be different between the sexes. When tooth in both arches are smaller than normal is termed as generalized microdontia. If all teeth are uniformly smaller than normal as seen in pituitary dwarfism, the condition known as true generalized microdontia. The condition relative generalized microdontia is used when both arches are somewhat larger than normal but the teeth are of normal size, giving perception of generalized microdontia. One of the most common localized microdontia is peg lateral and its root is shorter than usual.¹

Microdontia has occurred frequently

in the maxillary teeth dan mandibular. The prevalence of microdontia ranges from 0.8% to 8.4%. The clinical manifestation in lateral incisors appears as a reduction in mesiodistal diameter and convergence of mesial and distal surfaces towards the incisal edge and it is defined as peg shaped incisors. its condition is mainly due to genetic factor.⁴

An autosomal-dominant inheritance pattern has been associated with this condition. Factor that play a role in occurring microdontia remain obscured. Mutation in developmental genes are known to cause variety of dental defects. Both genetic and environmental factors are involved in the complex etiology of microdontia. Genetic factors probably play a role in the formation of microdontia.

The development of a tooth has been shown to have neural crest, ectodermal and mesodermal contributions. The variation in size of a particular tooth arises during the period when the form of the tooth is being determined by the enamel organ and the hertwig epithelial sheath at the bell stage of enamel organ of tooth development. The determination of the form of the crown is thought to be related to different regions of the oral epithelium or to the ectomesenchyme. Studies have shown that different regions of the oral epithelium rather than the underlying ectomesenchyme are initially responsible for the shape of the crown.¹

Management of these teeth includes composite resin restoration or full

coverage restoration. Treatment could be the combination of orthodontic treatment first to align the teeth in the arch and crown lengthening surgery to get better gingival heights. But composite resin restoration are very conservative as compared to full coverage restorations.⁵ This palatal matrix technique was developed to make less time correction for microdontic tooth, operator must make palatal matrix by putty type impression material. This technique was described for tooth wear by Mizrahi *et al*, the technique is unique and easy as well as time saving, less chair side time is needed for it and it gives satisfactory aesthetic results.³ In this case report patient's esthetic expectations were successfully met through conservative direct composite resin restorations. Despite the many advantages using composite resin, there are still some difficulties in regard to color selection. This aspect must consider several elements for achieving esthetic success restoration, but if the anatomical shape is not adequate, the result will not appear natural and harmonious within the dentofacial complex. Selection colour of shade guide is not an easy task, the shade of a tooth is determined by correlation among enamel, dentin, and light during the process of light refraction and reflection. While dentin gives the tooth chroma, opacity, and fluorescence enamel modifies the aspect of dentin by providing translucency and opalescence. Thus clinician should have a simple and accurate technique for shade interpretation for the identification of different tooth regions and for their reproduction with restoration.⁶

Conclusion:

The direct composite resin restoration by palatal matrix technique can easily be used to aesthetically correct microdontia tooth. Direct composite resin restoration provide a good esthetic result at the lesser cost and time due to absence of laboratory procedure and completion of work in single appointments. This minimally invasive technique is a better option to correct microdontia compared to full crown.

REFERENCES

1. Gupta, Shalini., Nitish Garg, Kavita., Gupta., Tripathi, Anurag.. Non Syndromic True Localized Microdontia Of Permanent Central Incisor- A case Report. Indian Journal of Dental Science. 2012.5(4): 64-6
2. Yoncheva, Vera Krumova. Hypodontia of The Upper Lateral Incisor – A Therapeutic Approach And Factor, Which have Determined It (A Clinical Case). Annual Proceeding 2008. Book 2. 55-7
3. Kiran, Shital., Patel, Mega., Shah, Nilay., Dholakiya, Niyati. Aesthetic Microdontia Tooth Using Direct Composite Resin. European Journal of Dental Therapy and Research. 2015. 4(2):274-6
4. Guttal, Kruthika S., Naikmasur, Venkatesh G., Bhargava, Puneet., Bathi, Renuka J. Frequency of Developmental Dental Anomalies in the Indian Population. European Dental Journal. 2010. 4(3):263-9

5. Khanna, Shally., Purwar, Anupam., Gupta, Shalni. Developmental variations in Maxillary Lateral Incisor- A Case Report. Journal Dentofacial Science. 2013.2(2):21-5
6. Scaffa, Pollana MC., Silva, Luciana M., Nahsan, Flavia PS., Sampalo, Costa P., Fransisco, Paulo AS., Rios, Luciana FF. Esthetic Restoration of The Smile : Directly Veneering a Discolored Anterior Tooth. Clinical and Laboratorial Research in Dentistry.2015. 21(1):44-51

ESTHETIC REHABILITATION OF SEVERELY DISCOLORED ANTERIOR TOOTH WITH INTERNAL BLEACHING FOLLOWED BY DIRECT COMPOSITE LAMINATE VENEER

Gustantyo Wahyu Wibowo¹ and R. Tri Endra Untara²

¹Resident of Conservative Dentistry

²Staff Department of Conservative Dentistry
Faculty of Dentistry, Universitas Gadjah Mada
Yogyakarta - Indonesia

ABSTRACT

Background: Conservative and aesthetic treatment of a single darkened discolored anterior tooth represents a great challenge to the dentist. Endodontic treatment and intra-pulpal hemorrhage caused by dental trauma are common reasons for tooth discoloration. If bleaching procedure has been tried without pleasing result, other conservative treatment plans should be considered under the scope of minimal intervention. A relevant application would be the construction of a direct composite laminate veneer. **Purpose:** The aim of this case reports is to report the use of direct composite laminate veneer after internal bleaching procedure in the patient with a single severely discolored tooth due to dental trauma. **Case:** A 25 years old male complained about the darkness of his maxillary right central incisor. This tooth has traumatic history 7 years ago. On clinical examination there was a crack and chipped in the incisal and radiographic examination showed open apices and radiopaque at the coronal third of the root canal. **Case management:** Apexification with MTA was performed followed by obturation with thermoplastic gutta-percha technique and internal bleaching procedure with walking bleach technique. Internal bleaching procedure was repeated four times every 5 days. The color of the tooth was still not the same as the color of the teeth next to it. Direct composite laminate veneer was done to improve the color of the tooth while restoring the crack and chipped tooth. **Conclusion:** The simultaneous use of internal bleaching and direct composite laminate veneer, provide to be a conservative treatment option with a pleasing aesthetic and functional result.

Key Words: Dental trauma, discoloration, internal bleaching, direct composite laminate veneer

Correspondence: Gustantyo Wahyu Wibowo, Resident of Conservative Dentistry, Faculty of Dentistry, Universitas Gadjah Mada, Jl. Denta Sekip Utara Yogyakarta, Indonesia.
E-mail address: gustantyo.wahyu.w@mail.ugm.ac.id

INTRODUCTION

Increasing demands for aesthetic restorative treatments and recent advances in adhesive dentistry have led to the development of materials and techniques aimed at restoring the natural tooth appearance, especially in the anterior segment. Esthetic restoration of anterior non-vital teeth presents a challenge to the dental practitioner. It is also a common esthetic concern for most of the patients because of the high expectations of their appearances and the importance of smile within the society.

Anterior tooth discoloration is one of the most frequent causes of dental treatment. Discoloration can be an extrinsic or intrinsic origin. An intrinsic discoloration is defined as it is originated from the pulp chamber. This type of discoloration can be caused by pulpal necrosis, pulp tissue remnants after endodontic therapy, endodontic materials (medications/irrigants, root canal sealers), coronal filling materials, root resorption, aging, and intrapulpal hemorrhage (following severe trauma).¹ Trauma of the pulp might result in tissue necrosis as well, causing release of noxious by-products that can penetrate tubules and discolor the surrounding dentin. The degree of discoloration is directly related to the duration of time that the pulp has been necrotic. The longer the discoloration compounds are present in the pulp chamber, the greater the discoloration.²

After endodontic treatment, internal bleaching should be done before any

kind of aesthetic restoration in order to overcome this displeasing discoloration. One of the most popular technique for non-vital tooth bleaching is walking bleaching technique that is relatively reliable, fairly simple for the clinicians and for the patients.³ Following the bleaching procedure, the most frequently used treatment for discolored teeth was direct composite laminate veneer if bleaching procedure has been tried without pleasing result. In terms of conservative treatment options, direct composite laminate veneer are the restorations that are widely preferred to correct the abnormalities, close diastemas, and restore aesthetic defects and fractures.^{4,5} Direct composite laminate veneer preparations result in lower mass losses than the conventional indirect ceramic veneer preparations. Direct composite laminate veneer is also related to fewer expenses in comparison with its indirect counterparts; this treatment is relative reversible and there is no need for further cementation steps. In addition, intraoral polishing is simple, and any cracks or fractures can be easily repaired, while the marginal adaptation is better than that of indirect laminate veneer restorations. In contrast to the proclaimed main disadvantages of direct laminate veneers, namely low resistance to wear and susceptibility to discoloration and fractures.⁶

In this case report, direct composite laminate veneer is used for a patient with an aesthetic problem related to a severely

discolored, a crack and chipped anterior non-vital tooth due to dental trauma and the six-month follow-up is discussed.

CASE REPORT

A 24 years old male patient, reported to the Department of Conservative Dentistry Faculty of Dentistry Universitas Gadjah Mada, with the chief complaint of the darkness on his maxillary right central incisor. During the anamnesis, the patient reported that he had a motorcycle accident 7 years ago. The accident made two of his maxillary anterior teeth fractured. He also indicated that after the accident, full-crown restorations were done without endodontic treatment. One year after the accident, the patient realizes that his teeth (not treated with full-crown restorations) getting brown and darker. Because there is no pain, the patient let it and did not go to the dentist. The patient wants the tooth treated because he starts feeling not confident when smiling.

On clinical examination, there was a yellowish-brown discoloration of tooth 11. Based on shade guide (Vitapan Classical), tooth discoloration C4 occurred on tooth 11. The occlusion examination showed normal occlusion with overjet 2 mm and overbite 2 mm. The percussion and palpation were negative, there was no mobility. The Simplified Oral Hygiene Index (OHI-S) score was 2.9 (fair). According to vitality test, tooth 11 was nonvital. There was Porcelain Fused to Metal (PFM) crown on tooth 21 and composite resin crown

on tooth 12. The color of tooth 21 and 12 was A2 checked with the Vitapan Classical shade guide. There was a crack and chipped on the incisal and composite resin restoration on the palatal surface of tooth 11 (Figure 1).

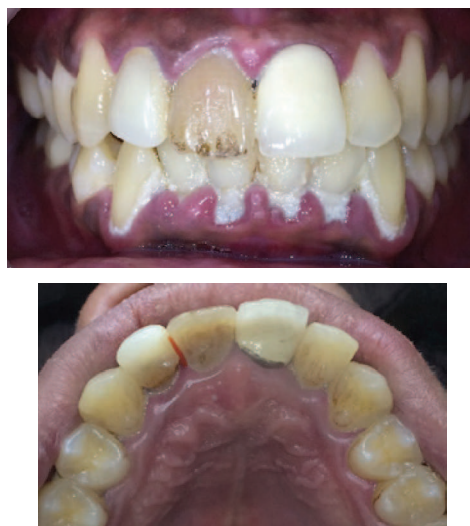

Figure 1. Preoperative intraoral view showed a yellowish-brown discoloration of tooth 11.

The preoperative periapical radiograph showed open apices and radiopacity at the crown and coronal third of the root canal of tooth 11. There was no periapical radiolucency at the root apices of tooth 11 (Figure 2). The clinical diagnosis for tooth 11 was pulp necrosis with an open apex and discoloration. The treatment plan for tooth 11 was root canal treatment and apexification with MTA, after that internal bleaching treatment was performed using the walking bleach technique. For the final restoration was used direct composite laminate veneer restoration.

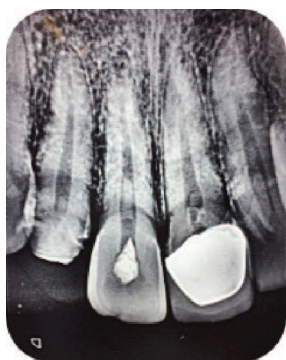

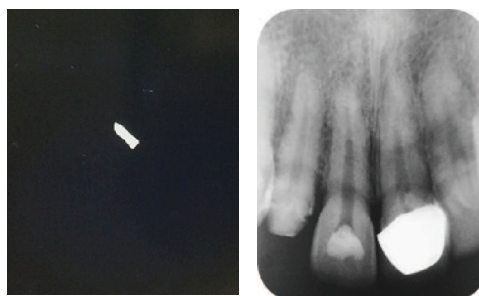
Figure 2. Preoperative periapical radiograph showed open apices and radiopacity at the coronal third of tooth 11.

CASE MANAGEMENT

On the first visit, it was done subjective and objective examinations, intraoral clinical photos and radiographic photos to support the diagnosis and treatment plan. Then the patient was explained about the cause of the discoloration of the teeth, stage of treatments which would be carried out, the results which could be achieved, and side effects which could occur, as well as the costs involved. After the patient understood and agreed on the treatment plan procedures, the patient was asked to sign a letter of medical consent (informed consent).

After scaling and root planing was done, tooth 11 was anesthetized with 2 ml of 2% lidocaine containing 1:200.000 epinephrine and isolated with a rubber dam. The coronal restoration was removed, then opening of the pulp chamber using endo access bur to make the access cavity in the tooth. Pulp debridement using

barbed broach, the root canal than irrigated with 2.5% NaOCl and saline. There was a foreign body comes out during pulp debridement, the periapical radiograph was taken for confirmation (Figure 3).



(a) (b)

Figure 3. (a) Foreign body that comes out during pulpal debridement \pm 4 mm length, irregular form, white bone color; (b) Periapical radiograph of tooth 11, a radiopaque view of a coronal third root canal has been lost.

Working length determination using Electronic Apex Locator (EAL) (DentaPort ZX, J.Morita MFG Corp. Japan) with size 25 K-file, and radiograph for confirmation. The working length of tooth 11 was 24 mm (Figure 4). The preparation of root canals on tooth 11 using K-file up to size 50 with a circumferential filing technique. Each turn of the files was done the irrigation of 2.5% NaOCl and saline to remove necrotic tissue and dentin powder that was in the root canal using a syringe and irrigation needle 30G side vented. Final irrigation of the root canals with 2.5% NaOCl, 17% EDTA, 2% Chlorhexidine digluconate. The root canal was dried with sterile paper points and the dressing was done using calcium hydroxide paste (Ultracal XS, Ultradent),

then the cavity was given cotton pellet and filled with temporary restoration (Caviton, GC).

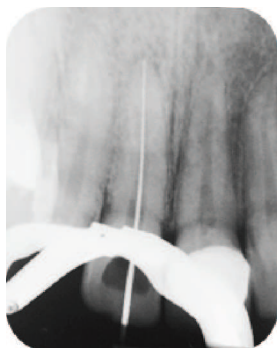

Figure 4. Working length determination radiograph.

At the second visit (1 week after the first visit), subjective and objective examinations were done. The patient didn't have any complaints, the temporary filling was still good, no exudate and blood in the root canal, and percussion was negative. Dressing materials were cleaned using irrigation with 2.5% NaOCl until clean and dried by sterile paper point. To prevent the filling of the root canal in the tip of apical was out, the apical plug was done with Mineral Trioxide Aggregate (MTA) (ProRoot MTA White, Dentsply) with the consistency of wet sand at a ratio of 1:1 (mixed with sterile distilled water). Application of MTA into the root canal with the Micro Apical Placement (MAP systems) and condensed with the plugger (Figure 5a). The thickness of MTA was ± 4 mm on apical of tooth 11. Then it was closed with sterile cotton which was moistened with sterile distilled water placed in the orifice dan filled with temporary restoration (Caviton, GC). The

periapical radiograph of tooth 11 was taken for confirmation (Figure 5b).

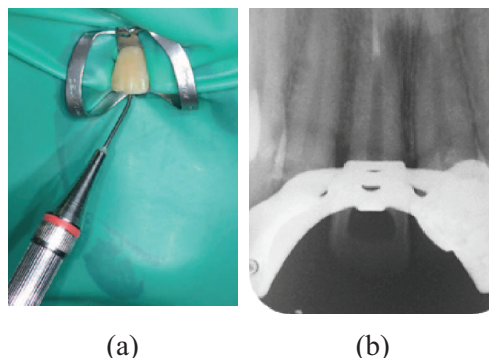


Figure 5. (a) MTA application using Micro Apical Placement systems; (b) The overview of periapical radiograph applications of MTA on apical third tooth 11.

On the third visit (1 weeks later), the remaining root canal was filled using thermoplastic gutta-percha technique (Elements Obturation Unit, SybronEndo) with an epoxy resin-based sealers (Top Seal, Dentsply), then the cavity was given cotton and filled with temporary restoration (Caviton, GC). The periapical radiograph of tooth 11 was taken to ensure that the root canal was filled perfectly and looks hermetic (Figure 6).

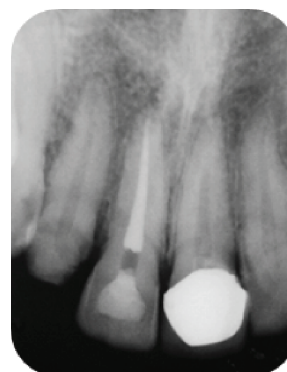


Figure 6. Post-operative radiograph.

On the fourth visit, the root canal obturation post control was done and there were no complaints. Based on shade guide (Vitapan Classical), tooth discoloration C4 occurred on tooth 11 (Figure 7). Then, it was followed by internal bleaching procedures with the walking bleach technique. The next treatment step was the removal of gutta-percha on tooth 11. The material was removed up to the level of the bone crest, about 3 mm below the gingival margin. This will allow space for sealing material, a resin-modified glass ionomer cement (Fuji II LC, GC) to protect and minimize the risk of penetration of the bleaching material to the apical or out to the cemento enamel junction (CEJ) because it could lead to external resorption. In order to calibrate the correct level of gutta-percha removal, a periodontal probe was used. The 35% hydrogen peroxide gel (Opalescence Endo, Ultradent) was placed into the pulp chamber avoiding soft tissue. A tiny cotton pellet was put over the bleaching agent and the access cavity was double seal with temporary restoration (Cavition, GC) and a resin-modified glass ionomer cement (Fuji II LC, GC) (Figure 8). Protrusive and laterotrusive movements were checked out to avoid premature contacts that could cause fracture resulting leakage and loss of bleaching material from the access cavity. The patient was instructed to return after 5 days to evaluate the results.

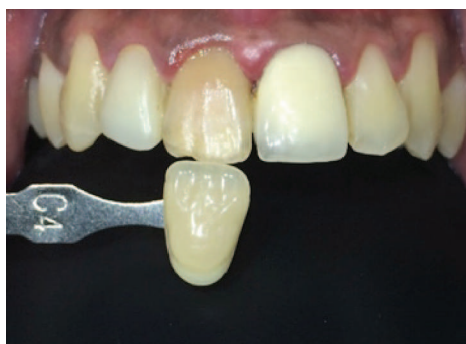

Figure 7. Clinical features of tooth 11 before internal bleaching.

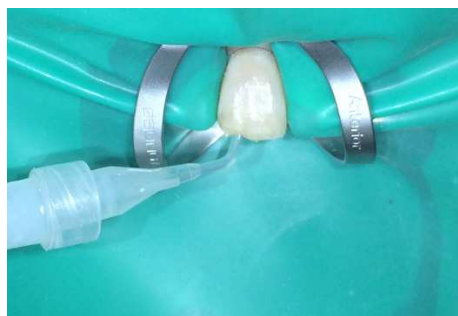

Figure 8. Application of bleaching materials on tooth 11.

The 35% hydrogen peroxide was used as the internal bleaching agent during 4 sessions, for periods of 5 days between each session. The color of the tooth 11 was still not the same as the color of the teeth next to it, based on Vitapan Classical shade guide the color of tooth 11 was A3.5 (Figure 9). The internal bleaching was stopped. The bleaching material was removed, the pulp chamber was cleaned and irrigated with warm sterile distilled water. Calcium hydroxide paste (Ultracal XS, Ultradent) was applied to balance pH for 1 week, then the cavity was given cotton pellet and filled with temporary restoration (Cavition, GC).

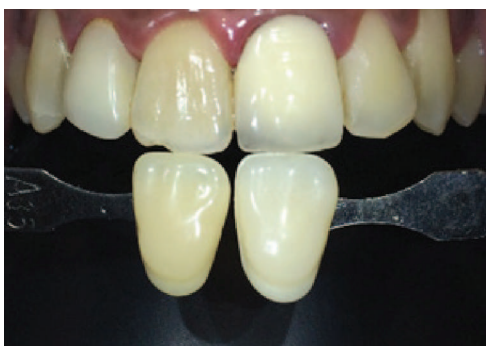

Figure 9. Clinical features of tooth 11 after internal bleaching during 4 sessions.

After 1 weeks applied of the calcium hydroxide paste, the cavity on the palate of tooth 11 was prepared for a permanent restoration with composite resin. Direct composite laminate veneer was done to improve the color of the tooth while restoring the crack and chipped of tooth 11. The depth of the labial veneer preparation is marked using a depth marker bur to obtain a preparation thickness of 0.5 mm (Figure 10). Size #000 retraction cord (Ultrapak, Ultradent) was placed into the gingival sulcus with No. 170 Fischer's Ultrapak Packer (Ultradent) in order to protect the gingival tissue during the preparation of the tooth. The preparation is continued using a 0.5 mm guide pin bur to obtain a chamfer finishing lines paralleling the entire gingival margin, extended proximally without removing proximal contact with the principle of extension for esthetic. Incisal edge of the tooth was reduced 1-1.5 mm in order to manage incisal edge coverage. After finishing the preparations (Figure 11), the shade was selected as A2 from the Vitapan Classical.

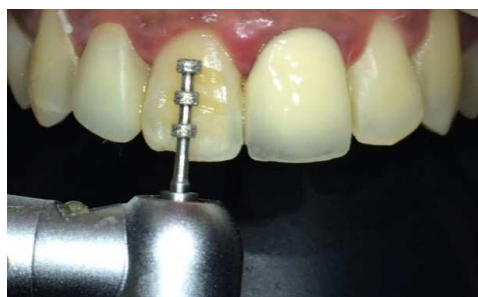

Figure 10. A depth marker bur was used to marking the depth of the labial veneer preparation of tooth 11.

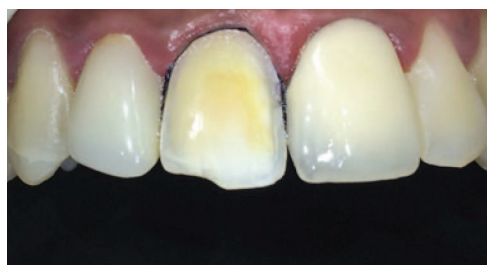

Figure 11. Final labial veneer preparation of tooth 11.

After preparation, the teeth were isolated with cotton rolls than for the mesial and distal proximal margins, clear celluloid matrix strips were placed and fixed with plastic wedges. The total-etch technique with 37 % phosphoric acid (DenFil Etchant-37 syringe, Vericom) was applied to the surfaces (30 seconds to enamel, 15 seconds to dentin), rinsed with water spray for 20 seconds and dried slightly. Bonding agents 5th generation (Stae, SDI) was applied to the etched tooth surfaces using a microbrush and then polymerized with a light curing unit. For the restoration of the teeth, a nano-hybrid composite resin (Filtek Z350 XT, 3M ESPE) was chosen. First, A2 Dentin (A2D) then A2 Body (A2B), and A2 Enamel (A2E) were placed. Then to create

the incisal edge translucency, Translucent Clear was used.

All of the resin composites were applied to the tooth surfaces in the form of very thin layers of less than 1 mm and after every composite placement polymerization was completed according to the manufacturer's suggestions. As the restoration finished, plastic wedges and the clear celluloid matrix strips were removed then from the vestibule and palatal surfaces polymerization was repeated in order to eliminate any uncured monomers left in the composite material. The finishing procedures of the composite resin veneer were done with a green-banded then a yellow-banded diamond tapered bur. The transition line (mesial, distal, incisal, cervical), incisal edge, embrasure (incisal, facial, cervical), cervical bulge, developmental groove were made and the suitability of color restoration with tooth color was checked. Early contacts were controlled with the articulation paper. For the polishing procedures, a polishing discs (Sof-Lex Disc, 3M ESPE) were applied from coarse to fine grits. At the end, a polishing bur (PoGo, Dentsply) and polishing brush (Astrobrush, Ivoclar) was used (Figure 12). Proximal surfaces smoothen with finishing and polishing strip (Sof-Lex Finishing and Polishing Strip, 3M ESPE). The periapical radiograph was done to confirm the quality of restoration (Figure 14).

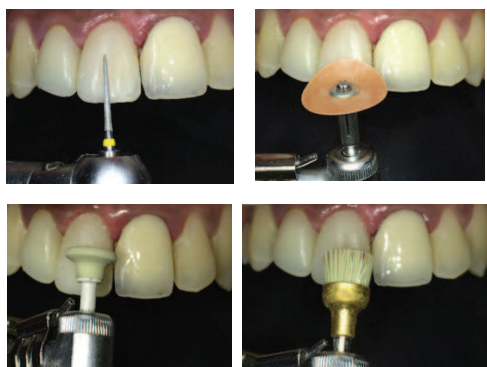


Figure 12. The finishing and polishing procedures of direct composite laminate veneer of tooth 11.

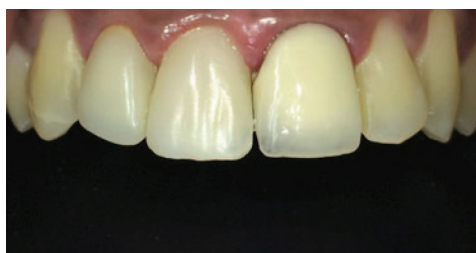

Figure 13. The final view of tooth 11 after restored with direct composite laminate veneer.

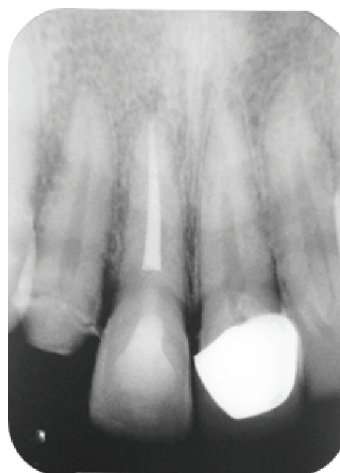


Figure 14. Post-operative radiograph showing final restoration. The overhanging restoration was not visible and the contact point was good.

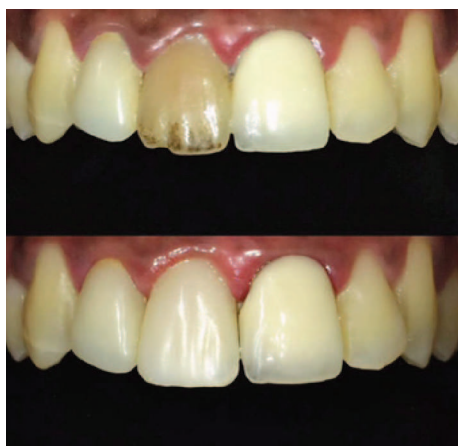

Figure 15. Clinical features of tooth 11 before and after internal bleaching and direct composite veneer restoration.

On the next visit, after 6 months, post-treatment for control of internal bleaching was administered. On the subjective examination, was obtained the results that no complaints from the patient and he is very satisfied with the treatment results. While the objective examination was obtained that the color of tooth 11 did not change and matched the color of the Vitapan Classical shade guide was A2. Direct composite laminate veneer was in a good condition and the periapical radiograph of tooth 11 showed complete closure of the apices and there was no present of external tooth resorption (Figure 16).

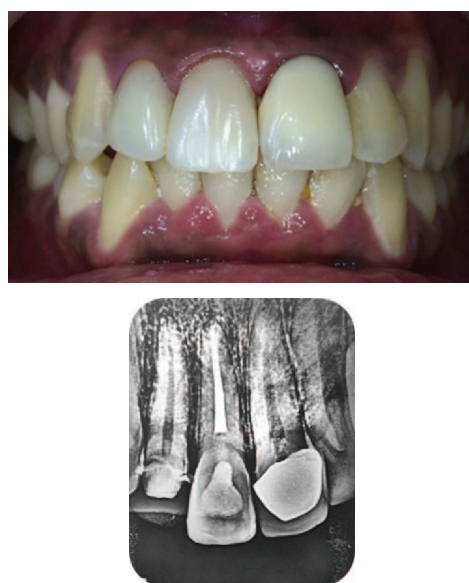

Figure 16. Clinical features and periapical radiograph view of tooth 11, 6 months after restoration.

DISCUSSION

An intrinsic discoloration of non-vital permanent anterior teeth due to trauma may have a significant aesthetic and social impact. Dental trauma cause discoloration on one or several teeth that could lead to the breaking down of the blood vessels in the tooth crown, bleeding as well as the lysis of erythrocytes. Iron product in hemoglobin joined with hydrogen sulfide which was a product of the bacteria to form iron sulfide, entered into the tubules and colored the dentin. When a tooth became necrotic, the discoloration would be more severe.⁷

Prior any treatment options for the discolored non-vital teeth, internal bleaching should be applied to overcome this displeasing discoloration.³ Discoloration of teeth due to trauma or

necrosis could be bleached with 95% success rate compared to the effect of the use of drugs or restoration.⁸ One of the most popular technique for lightening non-vital teeth is the walking bleach techniques.⁴ Bleaching process was based on oxidation-reduction reactions. On the redox reaction, oxidizing agent would release free radicals that do not have pair of electrons. These electrons would bind to organic molecules to achieve stability, the districts which had double bonds would be disconnected into simpler bond which gave lighter color.⁹

In this case, the patient suffered trauma in the upper front teeth 7 years ago, resulting an open apex. The open apex will complicate the endodontic treatment. Therefore, it was required the formation of an apical barrier. In this case, Mineral Trioxide Aggregate (MTA) acts as an apical plug that will induce apical calcific barrier formation and healing process. After getting the apical plug, root canal filling process can done without waiting for the formation of calcific barrier, so that the definitive restoration can be completed. MTA has several advantages over calcium hydroxide which includes superior biocompatibility, cementogenesis properties, ability to set in the presence of moisture and blood, superior sealing ability, high pH, radiopacity and its ability to aid in the release of bioactive dentin matrix proteins.¹⁰ The application of MTA immediately after root canal preparation favored the establishment of a normal periodontal ligament and formation of new

bone and cementum. MTA behaved in a similar manner to the calcium hydroxide paste, even in the presence of exudate and contamination observed at the time of preparation, and promoted the disinfection of the canal and stimulated the formation of an apical barrier of hard tissue.¹¹

On the anterior teeth which had pulp necrosis due to intrinsic discoloration, walking bleach method using 35% hydrogen peroxide gel gave satisfactory results due to its easy application and shorter time of visit as well as safety and comfort for the patient. Buttke said that 2 of 3 patient with internal bleaching treatment, having stable color for nearly 16 years and without any internal or external resorption.¹² The use of glass ionomer cement with the thickness 3 mm below the gingival margin to protect and minimize the risk of penetration of the bleaching material to the apical and it also could serve as a basis for the final restoration after the treatment finished. The selection of glass ionomer cement as a cervical seal because it had adhesive properties which could chemically bind to dentin so it could prevent the coronal leakage. It was also biocompatibility, anticaries, compressive strength which was similar to dentin and easy to use.^{13,14}

In our case report, after internal bleaching, aesthetic restorations were planned due to the remaining discoloration and restoring the crack and chipped tooth. The result of a color change that is not as expected as 4 sessions application of the bleaching material is likely caused the

severity of internal tooth discoloration and the gel dosage form of the bleaching materials. Some researchers mentioned that the teeth that had been discolored for years are not responding as well as the teeth that had just been discolored. The gel dosage form of bleaching materials was insoluble and it did not easily penetrate like liquid form.¹⁵ In this case, direct composite laminate veneer was planned for the teeth to masking and improved the color of the tooth while restoring the crack and chipped tooth. This conservative option was chosen in order to preserve dental hard tissues. Also, this type of procedure is a lower cost option when compared to indirect restorations. The reversible nature of this procedure allows for the other treatment options in the future. Also, the possibility of repairing intraorally without the risk of modifying aesthetics or mechanical performance is another positive advantage of this technique.¹⁶

For the direct composite laminate veneer restorations, a nano-hybrid composite resin was chosen. One of the reasons for selecting a nano-hybrid composite resin is, these composites are proposed as universal restorative dental materials in a wide range of applications. Also nano-hybrid composites are promoted as materials with improved mechanical properties which are showing an acceptable clinical performance.¹⁷ The most important reason for choosing a nano-hybrid composite is the excellent aesthetic properties of this material that is

very important especially when restoring anterior teeth.¹⁸ To reproduce the perceived color of a tooth which is a combination of an inner substrate (dentin) and outer substrate (enamel), direct composite laminate veneer restoration mainly consists of two different layers, dentin and labial enamel. Dentin is 20% more opaque than enamel, providing most of tooth's hue, which falls in the red-yellow spectra.¹⁹ Enamel is a layer that adjusts the perception of the underlying dentin color and its translucency based on factors like enamel thickness, genetics, and age. Enamel translucency influences the chroma and value. Highly translucent enamel (low value enamel) allows light to transmitted through it to reach a high-chroma dentin without much change in its color. More opacious enamel (high value enamel) act as a barrier that disperses, absorbs, and reflects light such that a minimal amount of color is perceived.¹⁹

In our case report, after six-month follow-up, the patient was very satisfied with his tooth restoration, which still preserve the natural tooth-like appearance with an acceptable clinical performance. The periapical radiograph showed complete closure of the apices and there was no present of external tooth resorption.

CONCLUSIONS

On the basis of the result, it can be concluded that in anterior aesthetic problems it's important to understand the etiology of the discoloration. A multidisciplinary approach is to consider

it necessary to resolve the problem: at first apical plug, endodontic treatment, internal bleaching and coronal restoration. If bleaching procedure has been tried out without a pleasing outcome and subsequent color rebounds, other conservative procedures should be considered, such as the placement of direct composite laminate veneer that can be completed in a single dental appointment, offer ease of reparability, cost-effective and often require minimal tooth preparation.

REFERENCES

1. Plotino G, Buono L, Grande NM, Pameijer CH, Somma F. Nonvital Tooth Bleaching: A Review of the Literature and Clinical Procedures. *JOE*. 2008; 34: 394-404.
2. Attin T, Paque F, Ajam F, Lennon AM. Review of The Current Status of Tooth Whitening with The Walking Bleach Technique. *Int Endod J*. 2003; 36: 313-29.
3. Zimmerli B, Jeger F, Lussi A. Bleaching of Nonvital Teeth. *Schweiz Monatsschr Zahnmed*. 2010; 120: 306-13.
4. Seyfioğlu PZ, Tacir İH, Eskimez Ş, Özcan M. Esthetic Rehabilitation of Anterior Teeth (Direct Laminate Veneer Restorations) in Three Cases. *Türkiye Klinikleri J Dental Sci*. 2008;14: 27-30.
5. İzgi AD, Ayna E. Direct Restorative Treatment of Peg-shaped Maxillary Lateral Incisors with Resin Composite: A Clinical Report. *J Prosthet Dent*. 2005; 93: 526-9.
6. Korkut B, Yanıkoğlu F, Günday M. Direct Composite Laminate Veneers: Three Case Reports. *J Dent Res Dent Clin Dent Prospects*. 2013; 7(2):105-11.
7. Abbott P, Heah SY. Internal Bleaching of Teeth: An Analysis of 255 Teeth. *Australia Dental Journal*. 2009; 54: 326-33.
8. Deliperi S. Clinical Evaluation of Non-Vital Tooth Whitening and Composite Resin Restorations: Five Year Result. *The European J of Esthetic Dentistry*. 2008; 3: 14-25.
9. Ascheim KW, Dal BG. *Esthetics In Dentistry*. 2nd ed. St. Louis: Mosby; 2001. P. 255-63.
10. Parirokh M, Torabinejad M. Mineral Trioxide Aggregate: A Comprehensive Literature Review-Part I: Chemical Physical and Antibacterial Properties. *J Endod*. 2010; 36: 16-27.
11. Felipe WT, Felipe MCS, Rocha MJC. The Effect of MTA on The Apexification and Periapical Healing of Teeth with Incomplete Root Formation. *Int End J*. 2006; 39: 2-9.
12. Buttke TM. Internal Bleaching of Non Vital Teeth. *Int Journal of Endodontics*. 2009; 32: 376-78.
13. Garg N, Garg A. *Textbook of Endodontics*. 2nd ed. New Delhi: Jaypee Brother Medical Publisher; 2007. P. 8-56.

14. Brenna F. Restorative Dentistry. St. Louis: Elsevier Mosby; 2009. P. 251-73.
15. Canoglu E, Guldahi K, Sahin C, Altundasar E, Cehreli ZC. Effect of Bleaching Agents on Sealing Properties of Different Intraorifice Barriers and Root Filling Material. Med Oral Patol Cir Bucal. 2012; 17(4): e710-5.
16. Magne P, Belser UC. Porcelain Versus Composite Inlays/Onlays: Effect of Mechanical Loads on Stress Distribution, Adhesion and Crown Flexure. Int J Periodontics Restorative Dent. 2003; 23: 543-55.
17. Frauscher KE, Illie N. Depth of Cure and Mechanical Properties of Nano-hybrid Resin-based Composite with Novel and Conventional Matrix Formulation. Clin Oral Invest. 2012; 16: 1425-34.
18. Ilie N, Rencz A, Hickel R. Investigations Towards Nano-hybrid Resin-based Composites. Clin Oral Invest. 2013; 17: 185-93.
19. Fahl N. Coronal Reconstruction of a Severely Compromised Central Incisor with Composite Resin: A Case Report. Journal of Cosmetic Dentistry. 2010; 26 (1): 92-113.

CASE REPORT

MTA APPLICATION ON APICAL PERFORATION WITH FIBER POST AND COMPOSITE RESIN RESTORATION.

Ivan Salomo¹, Ira widjiastuti²

¹Resident of Conservative Dentistry

²Lecturer of Departement of Conservative Dentistry

Departement of Conservative Dentistry

Faculty of Dental Medicine, Airlangga University
Surabaya, Indonesia

Correspondence author *Ivan Salomo, Phone : +6282117654555,

Email : ivanjejaka@gmail.com

ABSTRACT

Background. Root perforation can be caused by two things: iatrogenic and pathology. Root perforation caused by iatrogenic is the most common condition. Error of determining the working length and root canal instrumentation with instruments that are too large or rigid causes root perforation in endodontic treatment. **Purpose.** To gain more effective and quick apical plug. **Case.** Male patient aged 22 years old came to RSGMP UNAIR with a complaint wanted to care his lower front teeth that had been treated previously but still in pain. Negative vitality check, positive percussion, positive palpation and 1 mobility degree. Radiographic representation of radiolucent area on apical third. **Management.** The diagnosis of tooth 31 is pulp necrosis accompanied by apical perforation. Root canal treatment is done by crown down technique using rotary instrument. MTA is applied in the root canal with root perforation and then the root canal is obturated by a warm vertical condensation technique. After 3 month patient was recalled for re- evaluation, the patient had no complaints as well as on percussion, palpation and negative mobility examination and then continued with the installation of fiber post and composite restoration. **Conclusion.** Apical perforation treatment with MTA accompanied by fiber post and composite resin give a good result.

Keywords: MTA; root perforation; endodontic treatment; composite restoration

Introduction

The anterior teeth, most commonly traumatized, and when pulp trauma occurs necrosis with periapical abnormalities. Such conditions can be maintained, many evidence of cases with periapex

abnormalities with either closed apex or open apex accompanied by abscesses, granulomas, even cysts can be done conventional endodontic treatment with good success.¹

The success of an endodontic treatment is highly dependent on the diagnosis, selection of cases and procedures nurse. These three are a sequence that can not be separated and interdependent from one another. A misdiagnosis will lead to errors in the selection of care so that the situation becomes more severe. Similarly, less careful case selection will harm the sufferer.

In principle instrumentation action should be required measurement of length of work, with attention to things. then the apical constriction which is the resistant form / retaining of the root canal remains intact.²

Root perforation can be caused by two things: iatrogenik and pathology. Iatrogenic root cause perforation is the most common condition. Error determining the length of work and root canal instrumentation with instruments that are too large or rigid causes root perforation in endodontic treatment. Root perforation is an unintended complication of endodontic treatment. Once the perforation has been diagnosed, treatment should be given to seal the perforated site effectively to minimize injury and prevent contamination of adjacent periodontal attachment apparatus. Although successful treatment and prognosis depend on many factors, the location of the perforation and the time interval between exposure and repair are the two most important factors for determining treatment and dental prognosis.³

The ideal material for treating radicular perforations should be non-toxic, non-absorbing, radiopak, and bacteriostatic or bactericidal. It should also provide an adequate seal to the microleakage of the perforation. The mineral trioxide aggregate (MTA) is found to have all the characteristics and has been applied with good results at root tip operations, direct pulp coating, apexification, radicular resorption, and lateral or apical perforation improvement and furcation.⁴

Case

The 22-year-old male patient came to RSGMP UNAIR with a complaint of wanting to care for his lower front teeth that had been treated before but ill (figure 1 (a)). Examination of vitality showed negative results, positive percussion, positive palpation and mobility degree 1. Radiographic visible radiolucent area on 1/3 fire (figure 1 (b)). The patient's medical history shows that he is in good health and has no systemic disease.

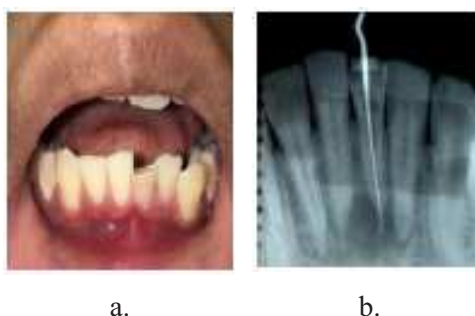


Figure 1: pre operative.
a) clinical Photo.
b) radiographic

Case Management

At the first visit made the making of Informed Consent. During treatment, the isolation of the working area with the installation of rubber insulator and saliva ejector (figure 2 (a)). Furthermore the pulp chamber is irrigated with 2.5% NaOCl to remove all debris and necrotic tissue. Followed by root canal explorations using K-file # 40 with estimated lengths calculated from radiographic images. Furthermore, the measurement of length of work with apex locator (Profex ® Pixi, Densply) obtained a working length of 20 mm that has been reduced 1 mm of apical, then the length of work is confirmed with radiographic images (Figure 3).

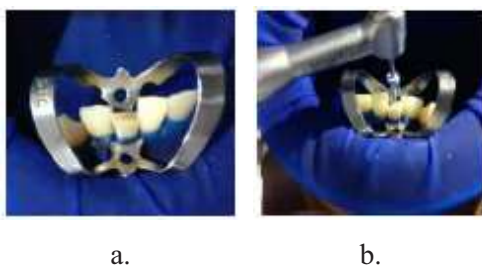


Figure 2 : root canal preparation.
a) isolation.
b) root canal preparation with rotary instrument.

Biomechanical preparation was performed using rotary instrumentation with motion brushing motion (figure 2 (b)) and accompanied by root canal irrigation using 2% NaOCL 2.5% solution then after root canal preparation, re-irrigation with NaOCL 2.5% as much as 2 ml, 17% liquid EDTA and lastly flooded with

chlorhexidine digikelonate 2% then root canal dikerigkan with sterile paper point. Root canal sterilization with calcium hydroxide paste plus saline solution then cavity closed temporarily with temporary cure. Saliva ejector was released and instructed the patient to come a week later.

Control 1 week later subjective and objective examination results no complaints on teeth 1.1. Furthermore, the working area is isolated by installation of rubber insulator and saliva ejector and then temporary discharge. Ca (OH) 2 was removed from the root canal and then irrigated with 2.5% NaOCL 2 ml and the last with aquadest. The root canal is dried with sterile paper points. MTA is prepared on stainless steel containers. The MTA powder and saline solution are mixed and stirred and then fed into the root canal using a 6mm apical placement (MAP) of apical placement (Fig. 3 (a)) and compacted with a paired stopper plugger finger. Furthermore, a radiographic shot is taken after the MTA application in the root canal for confirmation of MTA fill (figure 3 (b)). Wet cotton wetted aquades into the root canal and the cavity is covered with a temporary cure. Saliva ejector and rubber isolator are removed. Patients were instructed to control again one week later.

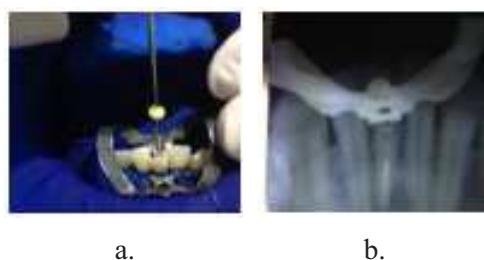


Figure 3 : MTA Application.

a) MTA Application with MAP (Micro Apical Placement).

b) Radiographi fotografi MTA application.

In subsequent controls there were no subjective and objective complaints. Treatment followed by isolation of the working area by installing saliva ejector and cotton roll. Temporary cotton and cotton swabs are taken from the cavity and then filling the root canal using warm gutta perca with backfill technique. The cavity closed with a temporary spill. Saliva ejector was released and instructed the patient to come a week later.

In subsequent control there were no subjective and objective complaints. Treatment is continued with removal of gutta perca with giden gliden bur, after which root canal irrigation with aquadest. then made the selection of fiber peg size (Luxapost, DMG) that is by matching the x-ray with the template. Do a try into a root canal that has been measured in length. The root canal is then dried with sterile paper points with indirect airflow. The cement material is applied to the fiber peg after it is inserted into the root canal (figure 4 (a)). Excess cement resin material can be used for core manufacture. Activated with light

for 20 seconds. Resin cement materials (Core Build-up FR) which can be used to manufacture the core was again applied to the closed cavity resin cement material then done activation with light for 20 seconds. Furthermore, radiographic confirmation of fiber post application result. Reinforcement of composite restorations to restore the shape, aesthetic and dental functions (figure 4 (b)).

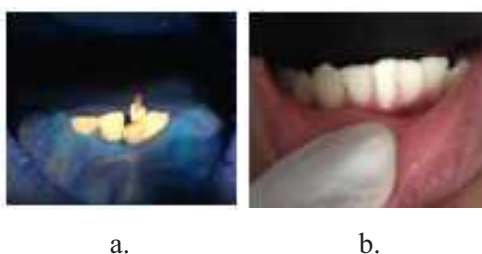

Figure 4 : Final Restoration.

a) Pemasangan Pasak fiber.

b) Post Treatment.

Discussion

Perforation is an undesirable problem that may occur during root canal treatment, caries removal and after root canal preparation. The repair time, perforation size and location of the perforation are the factors that affect the prognosis of perforation treatment. In case of any perforation, if the situation is quickly handled and treated promptly with appropriate material, this ensures a positive prognosis. In our current case, although patients reported to the clinic soon after perforation and small perforation size, the challenge was the location of perforations located in the 'critical zone' zone. Perforation occurs in apical, caused by

overinstrumentation of previous root canal treatment that may lead to overfilling of root canal fillers. Overfilling root ducts do not have a good density in apical. The leakage of tissue fluid through the apical becomes an additional nutrient for the remaining microorganisms in the apical so as to stimulate the occurrence of inflammation.

MTA is selected as the material of choice in this case because of its excellent sealing capabilities, biocompatibility, bactericidal effects, opaque radios and their successful use as root-tip fillings, surgical repair, pulp capping, apexification, root resorption and perforation.

In 1999 Torabinejad and Chivian recommended the use of an MTA acting as an apical plug that would induce the formation of an apical calcific barrier and a healing process so that the root canal filling process can be performed faster without waiting for an apical calcific barrier.⁵ MTA is an aggregate powder material containing mineral oxide. Perforation treatments using MTAs may be made twice into visits until final restorations are made to prevent fractures and may benefit in reducing the amount of radiographic exposure as well as improving co-operation of the patient.

In the MTA plug technique, root canals should be disinfected with calcium hydroxide for one week before placing the MTA. This is because doing chemo-mechanical preparations alone is not effective to remove microorganisms completely. Therefore, we used calcium hydroxide for one week in this case. The

operator should not push the MTA into the apical network in order for the treatment to work.⁶

Closure of apical perforation using MTA material as apical plug to fill apical end and induce apical calcific barrier formation as well as healing, Apical density and root canal filling process can be done easily without waiting for apical calcific barrier formation so that restoration can be completed soon. This can reduce the risk of root fracture and restoration between visits with thin root canals. In this case a fiber placement is placed into the root canal to reinforce the root canal wall without reducing the already thin root canal wall. Followed by the manufacture of composite restorations. The final restoration is done immediately to prevent fracture. Procedure of mounting fiber pegs and composite restorations without altering the inclination of dental archs given after the treatment of the patient will perform orthodontic treatment.^{7,8}

Conclusion

MTA is the best alternative option for apexification process that acts as apical plug and healing without waiting for apical calcific barrier formation so as to shorten the patient's visit time by directly filling the root canal and making final restoration to prevent fracture and reduce radiation exposure between visits and can be continued immediately-with the final restoration.

References

1. Fridland M, Rasado R. MTA solubility a long term study. *J Endod.* 2005; 31: 376-9.
2. Maroto M, Barberia E, Planells P, Vera V. Treatment of a non-vital immature incisor with mineral trioxide aggregate (MTA). *Dent Traumatol.* 2003; 19 :165-9.
3. El-Meligy AO, Avery DR. Comparison of apexification with mineral trioxide aggregate and calcium hydroxide. *Pediatric Dentistry.* 2006; 28 : 248-53.
4. Shabahang S, Torabinejad M. Treatment of teeth with open apices using mineral trioxide aggregate. *Pract. Periodontics Aesthet Dent.* 2000; 12: 315-20.
5. Tittle K, Farley J, Linkhart T, Torabinejad M. Apical closure induction using bone growth factors and mineral trioxide aggregate. *JOE.* 1996; 22:198 Restorations. *Operative Dentistry.* 2009; 34(5): 565-570.
6. Münchow EA, Martini T, Valente LL, Isolan CP, Piva E. In-Office Tooth Bleaching Treatment Using Light-Activated Hydrogen Peroxide Agent: A Case Report. *JSM Dent.* 2014 ;2(1): 1-4
7. Gutmann JL, Dumsha TC, Lovdahl PE. Problem Solving in Endodontics. (Mosby, 2006)
8. De-Deus G, Reis C, Brandão C, Fidel S, Fidel RA. The ability of Portland cement, MTA, and MTA Bio to prevent through-and-through fluid movement in repaired furcal perforations. *J Endod,* 33(11), 2007, 1374–7.

CASE REPORT

AESTHETIC ENHANCEMENT WITH A COMBINATION OF EXTRACORONAL BLEACHING AND VENEER PROCEDURE

Ketut Sri Widyawati*, Ema Mulyawati**

*) Conservative Dentistry Resident, Faculty of Dentistry, Gadjah Mada University

**) Staff of Conservative Dentistry Department Faculty of Dentistry, Gadjah Mada University

ABSTRACT

Background : Discoloration which has formed for various reasons leads to aesthetic problems, especially in the anterior region. The management of staining teeth depends on the etiology of discoloration itself. It is best to try a conservative procedure such as bleaching first then continued with invasive procedure like veneer and crown if needed. Dental bleaching offers a conservative, simplified, and low cost approach to change the color of discoloured teeth. **Objective** : This case report presents combination treatment to manage extrinsic discoloration. **Case Report** : A 34 years old male patient was not satisfied with the color of his anterior teeth and desired to have a teeth whitening procedure. Patient has dental history of restoring 21 with composite veneer a few years ago. Patient has a healthy lifestyle but often consumes colored beverages such as tea and coffee. Patient has no history of long term drug consumption. The diagnosis is that the maxillary and lower anterior teeth undergo extrinsic discoloration. **Case Management** : The patient's anterior teeth were treated with one visit extracoronary bleaching procedure by applications of 40% hydrogen peroxide gel that was applied by following the manufacturer directions. Three weeks post bleaching procedure composite veneer restoration was performed on the tooth 21. Finally, a satisfactory result was achieved, tooth color changes to be brighter ie from shade A3,5 to A1 after a combination of bleaching and veneer treatment. **Conclusion** : Continuous holistic care in the form of a combination of invasive and non invasive treatment in extrinsic discoloration cases is very effective in supporting aesthetics and function..

Keywords : extrinsic discoloration, extracoronary bleaching, hydrogen peroxide, veneer

INTRODUCTION

Discoloration is a color change in teeth that can be caused by external factor, internal factor or both of them.¹ Color changes can be a problem because it makes many people feel uncomfortable when talking and smiling, because they believe that white teeth can make them feel more beauty and confidence.² Scaling and

polishing of the teeth remove many extrinsic stains, but for more stubborn extrinsic discoloration and intrinsic stain, a variety of tooth whitening options are available that includes office bleaching procedures, at home bleaching kits, composite veneers, porcelain veneers and whitening tooth pastes. Among these procedures, bleaching procedures are more conservative than

restorative method, simple to perform and less expensive.³

Dental bleaching, also known as tooth whitening, is a common procedure in general dentistry. According to the FDA, whitening restores natural tooth color and bleaching whitens beyond the natural color.⁴ There are two main types of whitening procedures; (1) Non-vital whitening which is done on a tooth that has had root-canal treatment and no longer has a live nerve, Vital whitening is performed on teeth that have live nerves. The most common type of vital tooth whitening uses a gel-like whitening solution that is applied directly to the tooth surface. This product contains some form of hydrogen peroxide.⁵ (2) Vital bleaching is an in-office procedure and the most popular systems for in-office bleaching use high concentration hydrogen peroxides and are often referred to as “one-hour bleaching”. These high concentration hydrogen peroxides range from 25% to 35%. In-office bleaching can be provided to patients as either a one-visit of 1–1.5 hour treatment or a multiple visit procedure.⁵⁻⁶

Contemporary tooth whitening (tooth bleaching) systems are based primarily on hydrogen peroxide (H₂O₂) or one of its precursors, carbamide peroxide. These bleach the chromogens within the dentine, thereby reducing the body colour of the tooth and are often used in combination with an activating agent such as heat and/or light. Such agents can be applied externally to the teeth (vital bleaching) or internally within the pulp chamber (non-

vital bleaching).⁷ The oxidation-reduction reaction that takes place in the bleaching process is known as “Redox Reaction”. The oxidizing agents (e.g. hydrogen peroxide) has free radicals with unpaired electrons, which it gives up and thus becomes reduced. The reducing agent (the substance being bleached) accepts electrons and become oxidized.⁴

For successful aesthetic vital tooth bleaching, it is important to select patients with conditions that have the best prognosis for successful bleaching. Key factors that have an effect on the final result after bleaching include concentration of the bleaching agent, duration of use of the bleaching agent, type of tooth discoloration, color of the teeth, and patient's age.⁸ Many patients want to bleach their teeth but not every case give satisfactory result or satisfactory enough to meet the aesthetic needs of patients.⁹ Indication of in office bleaching include generalized staining, age related coloring, smoking and colorful diets such as tea and coffee, fluorosis and tetracycline staining. For very severe cases of tetracycline staining, it may not be enough with bleaching alone and should be combined with restorative treatment such as veneers. Fluorosis with multiple spots may require combination of bleaching and micro-abrassion treatment using hydrochloric acid and abrasive materials⁹⁻¹⁰

Bleaching can be done in many cases but in some cases it is contraindicated to do. Bleaching are contraindicated for patients with very high expectations, caries

and periapical lesions, pregnancy, sensitive dentin, crack and open dentine, crown or large restoration of the smile area, and elderly patients with gingival recession. The most contraindicated case to do in office bleaching is patients with very high expectation, because the likelihood of patients will never be satisfied with the result achieved.⁹⁻¹⁰

In cases where bleaching can not cope with dye staining, an invasive procedure is needed to restore the appropriate tooth color. One of the restorations indicated for the front teeth is veneer. Veneer is a thin layer of dental material that is applied to the colored tooth surface. Veneer restoration is divided into two types namely partial veneer and full veneer. Both types of restorations can be performed in accordance with the indication or extent of tooth decay that occurs.¹¹ Combination of bleaching and veneer treatment is recommended step to treat cases of discoloration under certain condition.

CASE REPORT

The 34-years old male patient came to Prof. Soedomo dental hospital to whiten his teeth that seemed yellowish. Patient have a healthy lifestyle but often consume coffee and tea. Patient have no history of long term consumption of drugs. The patient confessed that his left upper front teeth had been restored with veneer few months ago. Patient has never received any previous tooth whitening procedures. From the inspection results, it can be seen that there

are yellowish staining on the upper and lower teeth of patients with the initial shade obtained the color A3,5. A diagnosis that can be established from these conditions is that the maxillary and lower teeth undergo extrinsic discoloration. When the patient smiles, the visible teeth include 15 to 25 and 35 to 45, so it is necessary to have extracoronary bleaching treatment on that teeth.

The color changes that occurs in the patient's teeth may be caused by the patient's habit of consuming coffee and tea for long period of time. The discoloration due to tea and coffee consumption usually occurs as a result of tea and coffee dye attached to the surface of tooth enamel. Incomplete oral cleansing causes tea dye consumed daily then accumulate and penetrate into enamel and cause tooth color tend to be more yellow or dark.

CASE MANAGEMENT

At the first visit, the patient's dentition, soft tissue, and oral hygiene state are examined followed by cleaning and polishing the teeth. One week later, the preparation of in-office bleaching procedure starting by cleaning the patient's teeth using brush and pumice. After that, determine and record baseline shade of patient's teeth using shade guide (A3,5). After the placement of isoblock and optra dam to isolate the soft tissue, gingival barrier Opal Dam Green was applied to a 1,5-2 mm gingival margin with a height of 4-6 mm toward apical and 0,5 mm overlap

toward the enamel from distal tooth 15 to distal tooth 25 and from distal tooth 34 to distal tooth 45 then irradiated for 20 seconds with scanning motion.

Mixing of 2 syringe bleaching material (Opalescence Boost, Ultradent) before applying. The clear syringe containing chemical activator and red syringe contain 40% hydrogen peroxide. To activate, depress the red plugger forcing the contents of the red syringe into the clear syringe. Quickly and forcefully depress the small clear plugger into the middle small clear syringe to rupture internal membrane and combine bleach and activator. Continue depressing the clear plugger so all gel is in the red syringe. Reverse the action and mix a minimum 50 times (25 on each side). Finally, all mixed gel is in red syringe. The bleaching material was applied about a 0,5-1,5 mm thick layer of gel to labial surface of 15 to 25 and 34 to 45 and slightly onto the incisal surface. Allow gel to remain on the teeth 20 minutes, periodically checking and reapplying areas that have thinned or need replenishing. Suction gel from teeth using a surgical suction tip then thoroughly rinse teeth with an air / water spray and high volume suction. Evaluate shade change after each application and monitor patient for sensitivity. In this case, all steps were repeated two times until desired result was achieved (A1).

After the desired shade was achieved, using a dental instrument gently slide the tip beneath the Opal Dam Green and lift

off. Check and remove any interproximal remnant. To prevent post op sensitivity, desensitizing agent was applied into the labial surface of the bleaching teeth immediately after treatment, and patient are asked not to rinse, eat and drink for about 1 hour.

On the third visit, that was 2 weeks after bleaching procedure, printing of the patient's upper and lower jaw was performed to make work model. Work model performed mock up on tooth 21 using modeling wax, the mock up result was reprinted with elastomer material to obtain palatal guide for this veneer procedure. On the fourth visit, preparation was conducted on the labial surface of the tooth 21 using diamond round end fissure bur with J design. The contralateral teeth were isolated with teflon tape, mucosa isolated with cotton roll. Etching and bonding was applied, followed by composite (A1) layer by layer. Each layer was light curing for 20 seconds. Finally, finishing and polishing using composite polishing and finishing bur.

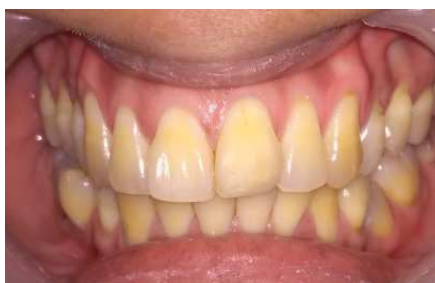

Figure 1. Preoperative view of patient.

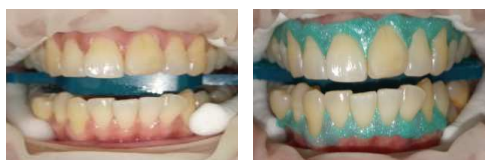
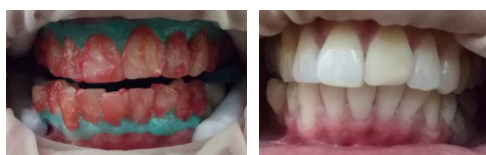
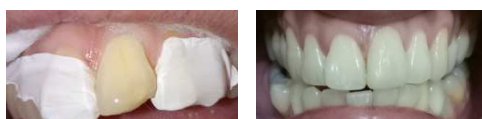Figure 2. Aplication of gingival barrier, cotton tampon, and isoblock



(A) (B)

Figure 3. Application of bleaching material
(A). Post operative view of patient after bleaching (B)



(A) (B)

Figure 4. The tooth after preparation
(A). Post operative view of patient with composite veneer

DISCUSSION

Extrinsic discoloration is defined as staining on outer surfaces of tooth structure caused by topical or extrinsic agents, excessive consumption of ingredients / beverages such as cigarettes, tea, or coffee. The material is integrated with the layers of the pellicles and the coloration that occurs is the result of the basic color of the chromogen.¹² There are six types of conservative treatment of discoloration include direct composite veneer, microabrasion and macroabrasion of email, vital bleaching, non vital bleaching, indirect veneer, and direct veneer combined with bleaching .¹³

Extracoronary bleaching is a non invasive way to eliminate extrinsic staining.¹⁴ The success of bleaching treatment is related to the ability of bleaching materials to penetrate into the dentinal tubules. the deeper the penetration, the more pigments that cause chromatic changes can be restored by oxidation reaction by converting dark molecules into carbondioxide and water.¹⁴ The main ingredients of teeth whitening agents include hydrogen peroxide, sodium perborate and carbamide peroxide.¹⁵ The most commonly used bleaching materials in procedure in office bleaching are carbamide peroxide and hydrogen peroxide. ¹¹ The bleach material ingrates through the intermediate email to the dentinal tubules and oxidize the pigment to the dentin, causing the color of the teeth to become brighter. The teeth whitening process is based on the oxidation reduction reaction mechanism. Spotted stains on enamel and dentine will be oxidizes by hidrogen peroxide from the bleaching material. Hydrogen peroxide will produce free radicals that will react with organic molecules in tooth enamel. Given this reaction, large and highly pigmented organic molecules converted inti smaller molecules and fewer pigment. This little molecules reflects less light so that the tooth looks brighter.¹⁶⁻¹⁷ In office bleaching technique was performed in dental clinic using 35-40 % hidrogen peroxide and 35 % carbamide peroxide. The advantage of this technique is the shorter time spent and the result is more quickly visible, can remove the brownish yellow color on the

teeth, motivating patients to do it at home after seeing the result. While the loss of this technique is more expensive, it takes several times visit, because one time application sometimes not enough to give maximum color change.¹⁸

The veneer procedure can be done if post bleaching can not get the appropriate color. Veneer restoration is a thin layer of dental materials applied to the tooth surface in order to coat the surface of the discolored tooth, experience defects, and shape changes, in order to have a better quality of appearance. In the case of the patient, veneer restoration is necessary to replace the old composite veneer on the labial surface of 21 whose color differs from the contralateral tooth following the extracoronary bleaching procedure. An anterior teeth restoration requires a restoration material that can resemble the appearance of natural teeth, in terms of color, transparency, or surface texture. In addition, the restoration material must have good strength and endurance. The advantages of the resin is easy to apply, does not require a lot of work stages, time efficiency, economical and have a good aesthetic. One of the restorative materials that meets that requirement is a composite resin..¹⁹

Based on material size and the type of composite, resin composite material is divided into 4 categories include conventional composite resin, composite resin microfilled, hybrid resin composite, nanofiller composite. The variety and

amount of filler as well as the nature and degree of the resin polymerization determine the physical and mechanical properties of composite. Conventional composite resins have particles of intermediate-sized fillers (1-100µm), microfilled composite resins have 0,01- 1 µm particle fillers, hybrid resins containing mixed filler particles between conventional and microfilled composite resin particles, nanofilled composite resins have particle fillers measuring 0,005- 0,01 µm.²⁰

The composite material used in this case is a nanofilled composite, that have very small particle size, so that it can fill the cavity on the resin matrix more perfectly, so it can give it greater strength, better endurance and easy polishing to produce smoother and shinier surfaces, more satisfying colors and better esthetic value. So that the purpose of making veneer restoration, to restore aesthetic function and restoration can last a long time can be obtained..²¹

CONCLUSION

In the case of a particular discoloration it is necessary to combine non invasive and invasive treatments to support aesthetic and dental function.

REFERENCES

1. GURSOY, U. K., EREN, D. I., BEKTAS, O. O., HURMUZLU, F., BOSTANCI, V., OZDEMIR, H., Effect of external tooth bleaching on dental plaque accumulation and tooth discoloration,

- J. Med Oral Patol Oral Cir Buccal*, 2008; 1,13(4), E266-9
2. Vanable , E. D dan LoPresti, L. R., Using Dental Material, Pearson Prentice Hall, New Jersey, 2004; 80-85
3. Garg N., Garg A., Textbook of endodontics. 1st ed. New Delhi. 2008
4. Sisodia S., Palekar A., Ali G., Vital teeth bleaching- review & case report. *NJDSR* ; 2014; 2(1)
5. Maiti, N., Das, U.K., Vital tooth bleaching: A case report, American Journal of Advances in Medical Science: 2004; 12(1)
6. Luk K, Tam L, Hubert M. 2004. Effect of light energy on peroxide tooth bleaching. *J Am Dent Assoc.*, 2004; 135 (2):194–201
7. Tredwin C J., Naik S., Lewis N S., Scully C., Hydrogen peroxide tooth whitening (bleaching) product : review of adverse effect and safety issues. *British Dental Journal*. 2006; 200 (7).
8. Haywood VB. Nightguard vital bleaching: Current concepts and research. *J Am Dent Assoc*. 1997; 128:19–25.
9. Sulieman M. An Overview of bleaching techniques: I. History, chemistry, safety and legal aspects. *Dent Update*. 2004 ; 608-10
10. Thosre D, Mulay S., Smile enhancement the conservative ways: tooth whitening procedures. *J Conserv Dent.*, 2009; 12: 164-6
11. Torabinejad M, Walton R.E., *Principles and practise of endodontic*. 4th Ed. Philadelphia: Saunders Company, 2009
12. Mithra H, Krishna S, Shishir S., Overview of in office bleaching of vital teeth. *Int Res J Pharm.*, 2012; 11: 12-4
13. Jordan J.E., Esthetic composite bonding, 2nd edition, St. Louis Mosby Year Book; 2000. p. 84-86
14. Joiner, A., The Bleaching of Teeth: A Review of The Literature. *J. Dent.*, 2006; 34, 412 – 419
15. Ferreira R., Effect of catalase, 2% chlorhexidine gel and 1% sodium hypochloride on the microtensile bond strength of teeth bleached with 35% hydrogen peroxide. *RSBO*, 2011; 3: 266-70
16. Greenwall L, Li Y., Safety issues of tooth whitening using peroxide-based materials. *Br Dent J.*, 2013; 215: 29-31
17. Mendonca LC., Permeability, roughness and topography of enamel after bleaching: tracking channels of penetration with silver nitrate. *Braz J Oral Sci*. 2011; 10:1-5
18. Goldstein RE, Garber D.A., Complete Dental Bleaching. *Quintessence*. 1995; 57-8
19. Eliades G., Watts D.C., Eliades T., Dental hard tissue and bonding, Springer-Verlag, 2005, p. 6; 36-41

20. Mitchell D.A., Mitchell L., Oxford
handbook of clinical dentistry, 4th ed.,
Oxford Universitypress; p. 19-33
21. Hargreaves K.M., Harold E.G.,
Dental pulp, 3 ed., Kimberly Drive,
Quintessence Pub. Co; 2002, p. 356-7

CASE REPORT

SUCCESSFUL USE OF BIODENTIN FOR A VITAL PULP THERAPY ON A LOWER MOLAR DEEP CAVITY

Mochammad Kennedy* Trimurni Abidin**

**Resident , Department of Conservative Dentistry.*

***Lecturer of Department of Conservative Dentistry.*

Faculty of Dentistry, University of Sumatera Utara.
Jl. Alumni No.2 Kampus USU Medan 20155

ABSTRACT

Background : Biodentin is a new bioactive cement with dentin-like mechanical properties, which can be used as a dentin substitute on crowns and roots. It has a positive effect on vital pulp cells and stimulates tertiary dentin formation. In direct contact with vital pulp tissue it also promotes the formation of reparative dentin. **Case :** This prompted its use for direct pulp capping after iatrogenic pulp exposure at tooth 36 in a 25-years-old male patient. **Case management :** Direct pulp capping was done with Biodentine and a composite filling was placed to replace the dentin and enamel layers. At the follow-up visit of 6 months the tooth was clinically normal and tested positive for sensitivity and negative for percussion. The radiograph showed the apical region without any pathological finding. Due to its improved material properties, Biodentine™ can be an alternative to conventional calcium hydroxide-based materials for direct pulp capping and, may contribute to the long-term maintenance of tooth vitality.

KEYWORDS : Biodentine, direct pulp capping, maintenance of tooth vitality, reparative dentin.

Introduction

The aim of treatment after pulp exposure is to promote the pulp tissue healing and facilitate the formation of reparative dentin in order to preserve the pulp vitality and health. Vital pulp therapy (VPT) procedures involve removal of local

irritants and placement of a protective material directly or indirectly over the pulp. These treatments must be followed by an overlying tight-sealed restoration to decrease bacterial leakage from the restorationdentin interface. VPT is performed to treat reversible pulpal injury

in order to promote root development, either. The purpose of this paper was to review the outcomes of VPT techniques,^{1,5}

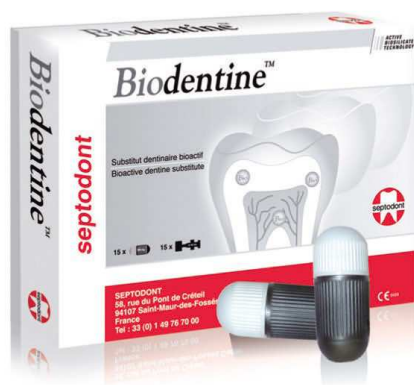

Fig 1. Biodentine

Biodentine is a new biologically active cement which has dentine-like mechanical properties and can be used as a dentine replacement in the tooth crown and root region. The cement consists mainly of a tri- and dicalcium silicate powder, which is mixed with an aqueous calcium chloride solution. As regards biocompatibility, long-term impermeability, antibacterial properties, induction of hard tissue regeneration, stability, low solubility, non-absorbability and ease of handling, Biodentine fulfils the requirements found in the literature for a material suitable for these purposes. On the basis of the good material properties of Biodentine, this cement is an interesting alternative to the conventional materials which were hitherto recommended. Biodentine can therefore confer advantages in day-to-day practice and – with correct diagnosis – contribute to the long-term maintenance of the vitality of the dental pulp and to the retention of

teeth². (Fig 1)

This has been documented by basic research and clinical studies with reported success rates in excess of 80 % for direct pulp capping procedures in humans (Baume and Holz, Hørsted et al. 1985). Calcium hydroxide has been shown to promote the differentiation of odontoblasts or odontoblast-like cells, which will form a hard tissue bridge in the pulp, i.e. calcium hydroxide contributes actively to the formation of new hard tissue by induction and up-regulation of the differentiation of odontoblast-like cells (Schröder 1972)¹. However, calcium hydroxide has some major drawbacks that have put into question its continued usage. The compound exhibits poor bonding to dentin, mechanical instability and continued resorption after placement. Thus, innovative materials have been employed as pulp capping agents and include hydrophilic resins, resin-modified glass ionomer cements, ozone technology, lasers, resins combined with bioactive agents and mineral trioxide aggregate (MTA). A new bioactive cement, Biodentine™ n (Septodont, St. Maur-des-Fossés, France), was recently launched on the dental market as a dentin substitute. It shares both its indications and mode of action with calcium hydroxide, but does not have its drawbacks. Biodentine™ consists of a powder in a capsule and liquid in a pipette. The powder mainly contains tricalcium and dicalcium silicate, the principal component of Portland cement, as well as calcium carbonate. Zirconium

dioxide serves as contrast medium. The liquid consists of calcium chloride in aqueous solution with an admixture of polycarboxylate. The powder is mixed with the liquid in a capsule in the triturator for 30 seconds. Once mixed, Biodentine sets in about 12 minutes. During the setting of the cement calcium hydroxide is formed. The consistency of Biodentine reminds of that of phosphate cement.³ In summary, Biodentine™ is both a dentin substitute base and a cement for maintaining pulp vitality and stimulating hard tissue formation, i.e. the formation of reactive or reparative (tertiary) dentin. The case report illustrates the use of Biodentine for direct pulp capping.³

Case

A 25 Year old male patient reported to the Department of Conservative Dentistry FKG USU. With the chief complaint of decay in the lower left back tooth region. In the initial examination revealed a deep carious lesion. The teeth were tested positive on pulp vitality and negative on percussion. Radiographic evaluation showed a deep carious lesion involving enamel, dentin and approximating the pulp. (Fig 2)

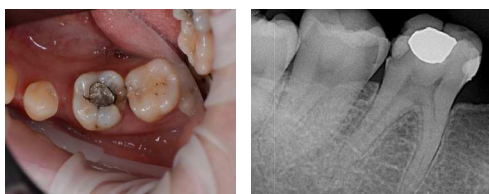

Figure 2: Pre Operative

After thorough information to the patient about the treatment consent was isolation with rubber dam. Following cavity preparation the carious dentin was completely excavated with slow speed hand piece and spoon excavator. In the process the pulp cavity was exposed iatrogenically. (Fig 3)

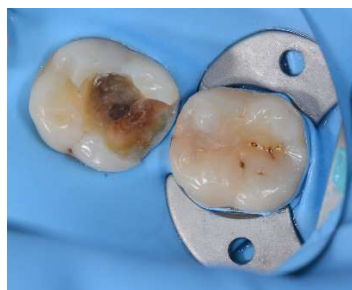


Fig 3. Cavity cleaning

Clinically the pulp tissue was vital without any major bleeding, so that maintenance of tooth vitality by direct pulp capping was decided upon. NaOCl (2.5%) was applied for hemostasis, clearing and disinfecting the cavity.

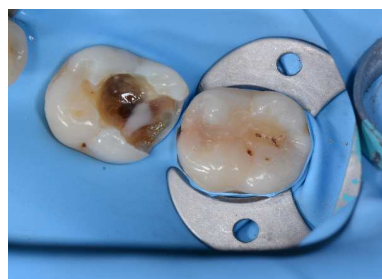


Fig 4. Biodentine application

Biodentine was chosen for direct pulp capping. Mixed as recommended by the manufacturer, and was gently applied on the exposed pulp tissue as direct capping. The tricalcium silicate was mixed as per the manufacturer's directions. The

Biodentine was dispensed to a mixing pad and was applied to the cavity preparation using an amalgam carrier. Care was taken not to place any pressure on the vital pulpal tissue. (Fig 4)

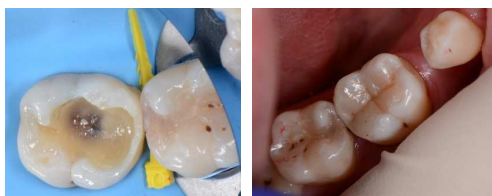

Fig 5. Restoration

The cavity preparation was bulk-filled and the material was adapted and contoured using a plastic filling instrument. The material was allowed to set for 10 minutes. Excess restorative material was contoured with disks. Based upon the most recent data the tricalcium silicate can be placed as a liner-base, allowed to set for 5 minutes, and then the preparation restored with composite resin. (Fig 5)

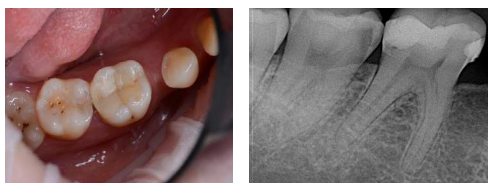

Fig 6. Six month after treatment

The outcome of the performed treatment was evaluated by pulp vitality tests and Radiographic evaluation for any periapical changes at 1month, 3month and 6 months interval. At the end of 6-month follow up: Clinically teeth were asymptomatic. The teeth responded positive for pulp vitality and negative for percussion tests. The radiographic evaluation showed no periapical changes.

Discussion

Bioactive cement, Biodentine (Septodont, France), was recently launched in the dental market as a dentin substitute. Having similarity in its indications and mode of action with calcium hydroxide, it eliminates its drawbacks. Biodentine consists of a powder in a capsule and liquid in a pipette. The powder mainly contains tricalcium and dicalcium silicate as well as calcium carbonate. Zirconium dioxide is the contrast medium. The liquid consists of calcium chloride in aqueous solution with an admixture of polycarboxylate. The powder is mixed with the liquid in a capsule in the triturator for 30 s. Once mixed, Biodentine sets in about 12 min. During the setting of the cement, calcium hydroxide is formed. The consistency of Biodentine is similar to that of phosphate cement ⁶

Biodentine can be used on crowns and roots. Its uses include pulp protection, temporary closure, deep caries management, cervical filling, direct and indirect pulp capping and pulpotomy. It can also be used in managing perforations of root canals or the pulp floor, internal and external resorption, apexification and retrograde root canal obturation.⁷

Biodentine has been proven to be biocompatible (it does not damage pulpal cells *in vitro* or *in vivo*). It has a capability of stimulating tertiary dentin formation. Hard tissue formation is seen after indirect and direct capping with Biodentine. In pulp capping, its benefits versus calcium

hydroxide are: It is stronger mechanically, less soluble and produces tighter seals. This qualifies it for avoiding three major drawbacks of calcium hydroxide, mechanical instability and the resultant failure of preventing microleakage.⁶

Compared with other materials, Biodentine displays ease of handling and decreased setting time. Unlike other Portland cement-based products, it is sufficiently stable so that it can be used both for pulp protection and temporary fillings. Apart from the choice of the agent used for pulp capping, the other factors that need to be considered are the clinical status of the pulp and the microbial contamination of the pulp at the site of injury. In clinical terms, this means the tooth should be asymptomatic and that pulp bleeding after exposure should be easily and rapidly controllable. Hemostasis is a prime factor. Blood clots left at the material/pulp interface act as factors for treatment failure. Sodium hypochlorite is an ideal agent for removal of surface clots and clearing the debris, while at the same time disinfecting the cavity. Microbial contamination of the pulp tissue during treatment should be avoided. This is best achieved with a rubber dam when treating on the dentin third close to the pulp, which reliably prevents the invasion of microorganisms from the oral cavity or saliva. Preventing microorganisms from entering the pulp is a key factor for successful direct capping.

Esthetic replacement of the fractured tooth is one of the most important factors

to be taken into consideration in treating a case of fractured anterior teeth in a young patient. A trauma accompanying with fracture of anterior teeth is a tragic experience for the young patient who requires immediate attention, not only because of damage to the dentition but also because of psychological effect of the trauma to the child and his parents. Reattached fragment to a great extent restores esthetics as it uses the original tooth's shape, color, translucence and surface structure. Reattachment of the tooth fragment of the anterior teeth is easy to practice and is an economic method that has the potential to assume the incisal strength during tooth functioning. The method ensures increased wearing steadiness and thus creates better function.^{6,7}

Conclusion

Biodentine is an interesting and promising product that has the potential to make major contributions to maintaining pulp vitality in patient judiciously selected for direct pulp capping. The reattachment of the fractured tooth segment appears to be the most conservative, simple and esthetically acceptable method of restoring the form and function of the teeth.

References

1. Najmeh Akhlaghi, Abbasali Khademi, Outcomes of vital pulp therapy in permanent teeth with different medicaments based on review of the literature, © 2015 Dental Research

Journal | Published by Wolters Kluwer
– Medknow.

2. Dr Till Dammaschke, Assistant Professor, DDM., Biodentine - an Overview, Septodont case studies collection No 3 – October 2012, University of Münster, Germany.
3. Nitish Kumar “Direct Pulpcapping with a New Material Biodentine: A Case Report”. Journal of Evolution of Medical and Dental Sciences 2015; Vol. 4, Issue 34, April 27; Page: 5990-5994, DOI: 10.14260/jemds/2015/873
4. Sham S. Bhat, Sundeep K. Hegde, Fardin Adhikari, Vidya S. Bhat., Direct pulp capping in an immature incisor using a new bioactive material, Contemporary Clinical Dentistry | Jul-Sep 2014 | Vol 5 | Issue 3 Camilleri J. Investigation of Biodentine as dentine replacement material. J Dent 2013;41:600-10
5. Sham S. Bhat, Sundeep K. Hegde, Fardin Adhikari, Vidya S. Bhat1 Direct pulp capping in an immature incisor using a new bioactive material, Contemporary Clinical Dentistry | Jul-Sep 2014 | Vol 5 | Issue 3
6. Guneser MB, Akbulut MB, Eldeniz AU. Effect of various endodontic irrigants on the push-out bond strength of biodentine and conventional root perforation repair materials. J Endo 2013;39:380-4

TREATMENT OF ENDO PERIO LESION WITH TRAUMATIC OCCLUSION ON RIGHT LATERAL INSICIVUS MAXILLARY

Norma Avanti ¹, Nila Kesuma Djauharie, drg, MPH, SpKG(K)²

¹ Resident, Department of Conservative Dentistry, Faculty of Dentistry,
Universitas Indonesia

² Lecturer, Department of Conservative Dentistry, Faculty of Dentistry,
Universitas Indonesia

E-mail address: noe.avanti@gmail.com

ABSTRACT:

The dental pulp and periodontium have anatomic interrelationships. As the tooth matures, and the root is formed, three main avenues are created between pulp and periodontal ligament, i.e. dentinal tubules, lateral and accessory canals, apical foramen. These are the pathways that may provide a means by which pathological agent pass between the pulp and periodontium, thereby creating the endo - period lesion. Etiologic factors such as bacteria, fungi, and viruses as well as contributing factors such as trauma, root resorption, and dental malformations play a significant role in the development and progression of such lesions. In the endodontic - periodontal lesion is necessary to plan appropriate dental treatment that can lead to a better prognosis. This case report describes the management of a lesion of primary periodontal and secondary endodontic. A 36 years man came to the Conservative Dentistry Clinic University of Indonesia with pain complaint on right lateral insicivus maxillary. There was no caries and vitality test gave non vital result. There was found traumatic occlusion. Radiographs showed an extensive defect of alveolar bone from coronal until apical third. Periodontal treatment consist of scaling, root planing, and flap surgery. Endodontic treatment consist of cleaning and shaping, medicament with calcium hydroxide was applied intracranial and periodically renewed up to two times and obturation with gutta percha and MTA fillapex sealer. One month after root canal obturation radiograph evaluation showed ossification at apical 12. Treatment plans in patients with primary periodontal lesions with secondary endodontic involvement were performed with combined periodontal and endodontic treatments to obtain more optimal results.

Keywords: Lesion of primary periodontal and secondary endodontic, pulp necroses, traumatic occlusion.

Introduction

The tooth structure consists of enamel, dentine and pulp. The dental pulp is a connective tissue located in the center of the tooth and surrounded by dentine. Pulp tissue contains cell fibers and

various structures of blood vessels, sensory nerves and lymph tissue. The pulp tissue is surrounded by dentine and associated with the periodontium through the apical foramen and the accessory / lateral canal. The periodontium is a tissue that supports

the teeth in the jaw. The supporting tissues consist of gingiva, cementum, periodontal ligament and alveolar bone.¹

The dental pulp and periodontal tissue have an embryonic, anatomical and physiological relationship. The dental pulp and periodontal tissue are derived from ectomesenchyme tissue. The dental pulp is derived from the dental papilla while the ligaments of the periodontium are derived from the dental follicle, both separated by the Hertwig root-sheath epithelium. The embryonic development continues to be an anatomical communication line between the dental pulp and periodontal tissue through the apical foramen, additional root canal and dentin tubules. The apical foramen and the additional root canal are the most important anatomical communication channels on the pulp and periodontal tissue through vascular, lymphatic, neural, and connective tissue.¹

The dental pulp and periodontal tissue have a very close relationship because they are both derived from ectomesenchyme tissue.¹ When the roots are perfectly formed, there are three main roads connecting the pulp cavity and the periodontal tissue include: (1) dentinal tubules, (2) lateralis and accessories canal, and (3) the apical foramen.²

According to Cohen, endodontic periodontal lesions may be classified into primary endodontic lesions, primary endodontic lesions with secondary periodontal involvement, primary periodontal lesion, primary periodontal

lesions with secondary endodontic involvement, true combined endo-perio lesions, and concomitant endo-perio lesion.⁵

The occlusal pressure that exceeds the adaptive capacity of the periodontium tissue can cause periodontal tissue damage. This damage is referred to as occlusion trauma. Occlusion trauma can be classified into two categories based on the etiology occurring, there are primary occlusion trauma and secondary occlusion trauma.⁷⁻⁸

Primary occlusion trauma occurs when there is an increase in strength and duration of excessive occlusal stress in normal or healthy periodontium tissue. Secondary occlusal trauma occurs when the accepted normal occlusal pressure becomes excessive because there has been severe tissue loss or reduced periodontium tissue ability to withstand occlusal stress.⁷⁻⁸

In this case report, we will discuss the primary periodontium lesions with secondary endodontic involvement. Patients were also diagnosed with generalized aggressive periodontitis. Periodontal disease extends to the apical so that the pulp is exposed through the lateral root canal or dentinal tubules⁶. Clinical features of this lesion are deep pockets, with a history of periodontal disease, and if the pulp is involved there will be pain complaints. Radiographically, lesions are difficult to distinguish from primary endodontic lesions with periodontal involvement. Prognosis depends on periodontal treatment that continues after

endodontic therapy.⁵

Treatment of primary periodontal lesions with secondary endodontic involvement includes endodontic treatment and periodontal treatment such as scaling, root planing, and surgery when necessary. Endodontic treatments in these lesions include root canal cleansing, root canal medication, and complete obturation. The occlusal trauma of the tooth is repaired by occlusal adjustment and splinting to reduce tooth mobility.

Case Report

This case report describes the management of a lesion of primary periodontal and secondary endodontic. A 36 years man came to the Conservative Dentistry Clinic University of Indonesia with pain complaint on right lateral insicivus maxillary. He was referred to a periodontist. Since 6 months ago the patient felt his teeth were mobile. One month ago the patient had performed a periodontal surgical flap in the Periodonsia Clinic University of Indonesia. Based on the information in medical consult from periodonsist, it is explained that there is an occlusion trauma on right lateral insicivus maxillary (edge to edge) and has been repaired by splinting and occlusal adjustment. Patients have no history of systemic disease.

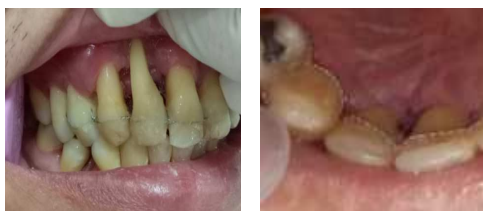Clinically, the tooth 12 was intact, caries free, vitality test gave non vital result, sensitive to percussion and palpation, splinting of the teeth 14 to 24 (Figure 3.1

(a and b). In radiographic examination showed alveolar bone destruction from coronal until apical third and loss of lamina dura. The diagnosis of this case is the primary periodontal lesion with secondary endodontic involvement with traumatic occlusion. The treatment plan is non vital root canal treatment, dowel and composite restorations.

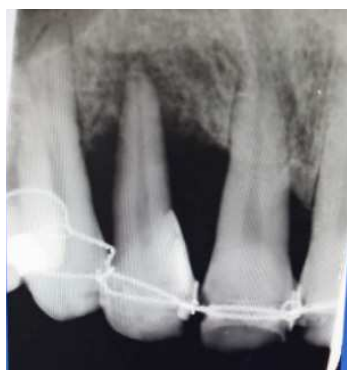On the first visit, the cavity was access with *endo access kit* (Dentsply) and canals patency was achieved using #10 K hand files. The working length was established with apex locator and radiograph. The canal was instrumented with protaper hand use up to size F3. The canal was irrigated with 2,5% sodium hypochlorite, then aquabidest, and 17% EDTA to remove the smear layer. Additional irrigation performed by 2% Chlorhexidine. The canal was dried with sterile paper points and dressed with Calcium Hydroxide and the the access opening was sealed with temporary filling.

Two week later, the teeth 12 was still sensitive to percussion and palpation. The tooth was reaccessed and calcium hydroxide was removed using hand files and irrigation with 2,5% sodium hypochlorite, then aquabidest, and 17% EDTA to remove the smear layer. Additional irrigation performed by 2% Chlorhexidine. The canal was dried with sterile paper points and dressed with Calcium Hydroxide and the the access opening was sealed with temporary filling.

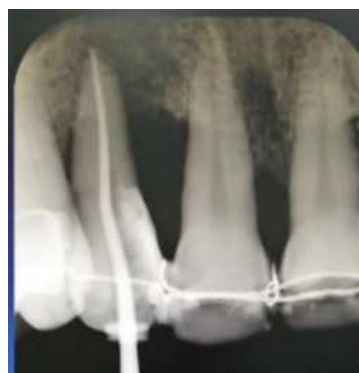On the third visit, that was no subjective complaints. On clinical examination, it was not sensitive to percussion and palpation. The tooth was reaccessed and calcium hydroxide was removed using hand files and irrigation with sodium hypochlorite with 2,5% sodium hypochlorite, then aquabidest, and 17% EDTA to remove the smear layer. Additional irrigation performed by 2% Chlorhexidine. The canal was dried with sterile paper points and obturated using gutta percha F3 and sealer MTA Fillapex. On the fourth visit, composite restoration is then performed. Patient was reevaluated 1 month, 4 months and 6 months later.



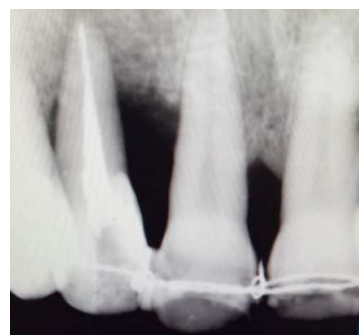Picture 3.1(a,b) preoperative clinical photographs (labial and palatal)



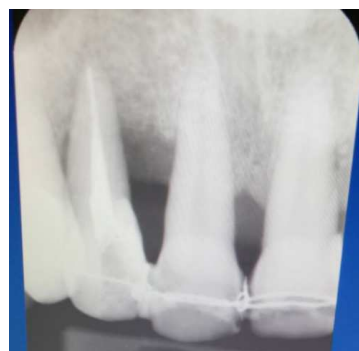Master apical cone radiograph



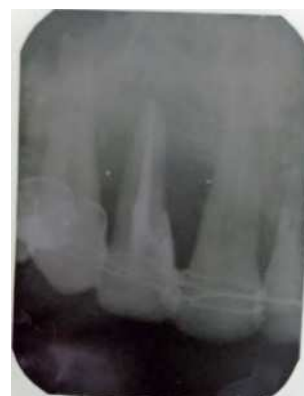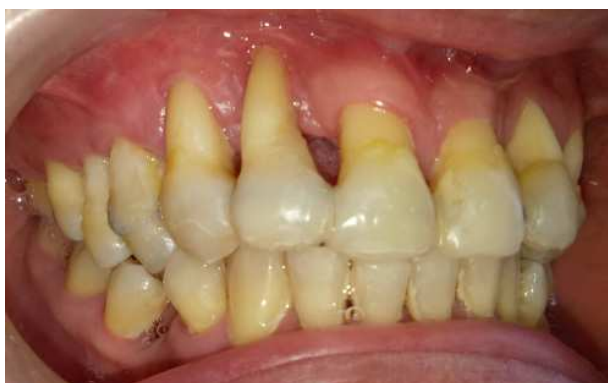Preoperative radiograph



Obturation radiograph



Radiographic images of teeth 12 at 1 month evaluation



Clinical photographs and radiographic images of teeth 12 at the 4 month reevaluation

Discussion

Patient with a endodontic periodontal lesion demonstrates that retaining a tooth with a poor prognosis is possible when the treatment follows a structured and interdisciplinary approach. Basic requirements leading to the decision to save rather than extract the tooth were the good oral hygiene and compliance of the patient as well as the restorability of the tooth.¹⁴

In this case report, bone destruction that occurs in the teeth 12 looks more severe than the other teeth. Bone destruction in the tooth 12 can be aggravated by trauma occlusion. The teeth 12 is repaired by splinting and occlusal adjustment to reduce the occlusal load. Root canal preparation on the tooth 12 uses protaper hand use with crown down technique. Preparation with the use of protaper hand use because it has better tactile control thus maintaining the original form of the root canal with small risk of transporting the root canal.⁹

The irrigation materials used in

this case are NaOCl 2.5%, EDTA 17% and chlorhexidine (CHX) 2%. NaOCl gives better tissue solvent effect, but dissolves necrotic and vital tissue where not the desired effect. The antibacterial activity of sodium hypochlorite is effective for *Enterococcus faecalis* bacteria, *Porphyromonas endodontalis*, *Porphyromonas gingivalis* and *Prevotella intermedia*. The use of NaOCl as an endodontic irrigation agent should be careful because it can cause complications that can arise from excessive irritation of NaOCl or the wrong irrigation technique is the occurrence of necrosis in the tissues below the apical foramen. While EDTA irrigation materials are used to clean the smear layer.¹⁰

Chlorhexidine (CHX) is recommended as an irrigation material because it has a broad spectrum of antimicrobial, substantive properties, and low toxicity properties. CHX is very effective against gram-positive and gram-negative bacteria and facultative anaerobic bacteria, especially *Candida albicans*.¹⁰

The root canal was dried with sterile paper points and Ca(OH)_2 medicament was injected into the root canal. According Tronstad et al., Ca(OH)_2 is able to dissociate into calcium ions and hydroxyl ions which will increase local pH. This leads to the creation of an alkaline environment that does not support bacterial growth. Ca(OH)_2 mediates the neutralization of bacterial lipopolysaccharide (LPS) and stimulates healing of periapical hard tissue. The ability of Ca(OH)_2 as an intracanal medicament is to absorb carbon dioxide in the root canal, thus inhibiting the supply of nutrients to bacteria. This leads to the elimination of some bacteria and prevents the growth of other bacteria. Gram-negative anaerobic bacteria are more susceptible to Ca(OH)_2 than the Gram-positive facultative bacteria.¹¹

Root canal filling in this case used gutta percha with Fillapex MTA sealer with lateral condensation technique. MTA fillapex has the advantages of containing MTA that can stimulate the formation of new tissues including cementum; biocompatible to stimulate rapid tissue repair / recovery without causing an inflammatory reaction; high radioopacity in order to provide a good visualization of the radiograph; has a good flow (consistency of the paste (flowable) MTA Fillapex can penetrate and fill the lateral channel); can provide root canal closure, avoiding the entry of tissue fluid and recurrent contamination of bacteria; can release calcium ions which can induce rapid tissue regeneration in

areas with periapical lesions and microbial activity; easy to insertion and handling; have adequate working time; and easy to remove (on retreatment, especially when used with gutta percha).¹²

Conclusion

This case report demonstrates that a concerted interdisciplinary approach can result in improving and maintaining the natural dentition in order to achieve health, comfort, esthetics, and function even in teeth with endodontic periodontal lesions with primary periodontal origin.¹⁵ Diagnosis in this case is primary periodontal lesion with secondary endodontic involvement requires a combination root canal treatment and periodontal treatment. Occlusal adjustment was done to reduce the occlusal load. Splinting was done to strengthen the mobile teeth and repaired the occlusion, so that the traumatic occlusion can be removed. After root canal preparation, the medicament used Ca(OH)_2 and after 4 weeks radiographically showed on apical third became more radioopaque than before. Evaluation 1 month and 4 month post treatment showed negative results to percussion and palpation, and no subjective complaints. The teeth can be maintained and functioned again.

References

1. Sunitha R, Emmadi P. The Periodontal – Endodontic Continuum: A Review. *J Conserv Dent*. 2008;11(2):54–62.
2. Rotstein I, Simon JH. The endo-

- perio lesion: a critical appraisal of the disease condition, *Endodontic Topics*. 2006; 13: 34-56.
3. Patil VA, Deshpande PS, Shivkumar PT. Endo-perio lesion: interdisciplinary approach. *Int J Dent Clin*. 2009; 1(1): 32-35.
4. Rotstein I, Simon JH. The Endo-Perio Lesion A Critical Appraisal of The Disease Condition. *Endodontic Topics*. 2006;13:34-56.
5. Hargreaves KM, Cohen S. Cohen's pathways of the pulp. 10th ed. St Louis: Mosby Elsevier. 2011.
6. Weine FS. *Endodontic therapy*. 1996. St. Louis: Mosby.
7. Kemal Y. Bahan Kuliah. Trauma Oklusi, Diagnosis dan Penanggulangannya. Departemen Periodontologi Fakultas Kedokteran Universitas Indonesia. Jakarta.
8. Pawlak EA, Philip MH. Essentials of Periodontics. 3rd ed. Missouri: The C.V Mosby Company. 1984:84-9.
9. Shen Y, Zhou H, Zheng Y, Peng B. Current Challenges and Concepts of the Thermomechanical Treatment of Ni-Ti Instruments. *J.Endod*. 2013;39(2):163-172.
10. Haapasalo M, Shen Y, Wang Z, Gao Y. Irrigation in Endodontic. *Br Dent J*. 2014;216:299-303.
11. Nilakesuma Djauharie. Disertasi: Efek Anti Mikroba Kalsium Hidroksida terhadap Kuman Anaerob Batang Gram Negatif Berpigmen Hitam Penyebab Infeksi Pulpa. Universitas Indonesia. 2002.
12. Rafael Pino Vitti et al. Physical Properties of MTA Fillapex Sealer. *JOE — Volume 39, Number 7, July 2013*.
13. Newman MG, Takai HH, Carranza FA. *Carranza's Clinical Periodontology*. 9 ed. Philadelphia: W. B. Saunders; 2002 hal.943-968.
14. P. Axelsson, B. Nystrom, and J. Lindhe. The long term effect of a plaque control program on tooth mortality, caries and periodontal disease in adults; results after 30 years of maintenance. *Journal of Clinical Periodontology*, vol. 31, no. 9, pp. 749-757, 2004.
15. AmericanAcademyofPeriodontology. Comprehensive periodontal therapy: a statement by the American Academy of Periodontology. *Journal of Periodontology*, vol. 82, no. 7, pp. 943-949, 2011.

ENDODONTIC RETREATMENT OF MAXILLARY SECOND PREMOLAR WITH ROOT CANAL CONFIGURATION VERTUCCI CLASS II

Mettasari Puspa Wardoyo¹, Dewa Ayu Nyoman Putri Artiningsih²

*¹Post Graduate Student, Department of Conservative Dentistry,
Faculty of Dentistry Universitas Indonesia*

*²Lecturer, Department of Conservative Dentistry, Faculty of Dentistry,
Universitas Indonesia*

ABSTRACT

The major cause of endodontic treatment failure is the persistence of bacterial infection in the root canal system. Inadequate obturation and coronal leakage can lead to such persistence. Clinicians should be aware of anatomical variations in premolars and be able to apply this knowledge in endodontic practice in order to avoid endodontic treatment failure. This article reports a clinical case of endodontic retreatment of maxillary second premolar with root canal configuration Vertucci class II. A 47-yearold female patient was referred to the Department of Conservative Dentistry with chief complaint of extreme pain in upper left quadrant for 2-3 days. Preoperative periapical radiograph showed underfilled obturation and diffuse periapical radiolucency with 5 mm diameter. Based on radiographic finding, the second premolar was diagnosed as chronic apical abscess due to inadequate endodontic treatment. The treatment of choice was endodontic retreatment with ProTaper Universal Retreatment to remove the root filling materials. The maxillary second premolar had two separate canals leave the pulp chamber and join to form one canal in the apical portion (2-1) or also known as Vertucci class II.

Keywords : Endodontic failure, maxillary second premolar, Vertucci class II, endodontic retreatment, ProTaper Universal Retreatment

INTRODUCTION

The knowledge of common root canal morphology and its frequent variations is a basic requirement for success during endodontic procedures. The variations in canal geometry before shaping and cleaning procedures had more influence on the changes that occur during preparation

than the instrumentation techniques themselves. The pulp canal system is complex, and canals may branch, divide, and rejoin. Vertucci et al. identified eight pulp space configurations. The only tooth to demonstrate all eight configurations was the maxillary second premolar.^{1,2}

Endodontic therapy is a conservative treatment modality yielding high long term tooth survival rate. Undesirable outcomes of endodontic therapy were described as failures.^{1,3} The major factors associated with endodontic failure are the persistence of microbial infection in the root canal system and/or the periradicular area. If microorganisms persist in the root canal at the time of root filling or if they penetrate into the canal after filling, there is a higher risk that the treatment will fail. How high the risk of reinfection will be is dependent on the quality of the root filling and the coronal seal.⁴ It was observed in the study by Ray and Trope that poor restorations in combination with good endodontic therapy had negative results.⁵

When endodontic treatment do inadequate, treatment choices include non-surgical endodontic retreatment, periradicular surgery, or extraction. Endodontic retreatment is often reported as the initial treatment option to resolve or decrease microbial infection, which is responsible for insufficient endodontic treatment.⁶ Surgery is indicated for teeth with persistent periradicular pathoses that have not responded to nonsurgical approaches, or if the cause of the posttreatment disease is persistent extraradicular infection, foreign body reaction, and the presence of a true cyst.¹

The primary difference between nonsurgical management of primary endodontic disease and endodontic failure

is the need to regain access to the apical area of the root canal space in the previously treated tooth.¹ Regardless of technique, gutta-percha is best removed from a root canal in a progressive manner to prevent inadvertent displacement of irritants periapically. Dividing the root into thirds, the obturation is initially removed from the canal in the coronal one-third, then the middle one-third, and finally eliminated from the apical one-third.⁵ There are various techniques available for removing the gutta-percha from the root canal such as hand instrumentation technique, rotary technique, heat carrying instrumentation technique, ultrasonic devices, and solvent.^{3,5,7} Rotary instrumentation is the most efficient method for removing gutta-percha from a previously treated root canal.⁵

This case report will discuss endodontic retreatment in the maxillary second premolar with a type 2 Vertucci configuration.

CASE REPORT

A 47 year old female patient came to the Department of Conservative Dentistry and Endodontics at University of Indonesia with the chief complaint of extreme pain in upper left quadrant for 2-3 days, and pain intensified when chewing. A few years ago, root canal treatment was done on the same tooth and had also been restored. Patients took painkillers to reduce her pain.

Clinical examination revealed a disto-occlusal composite restoration on

the maxillary second premolar(25). The tooth responded negative to cold stimuli, but sensitive to percussion, sensitive the palpation, and gingiva was swollen.

Radiographic examination showed the underfilled obturation, normal root canal, discontinuity of lamina dura in the apical one-third, and 5 mm-diameter periapical radiolucency.

The tooth was diagnosed as a chronic apical abscess etcausa inadequate endodontic treatment. The management of this case is the endodontic retreatment and post-endodontic restoration of fiber post and porcelain fused to metal crown.

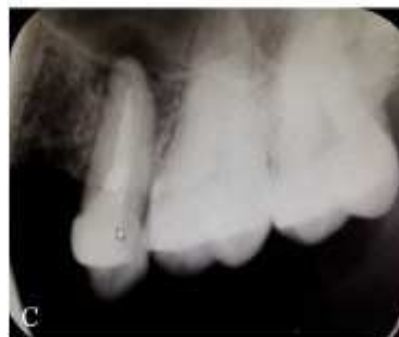
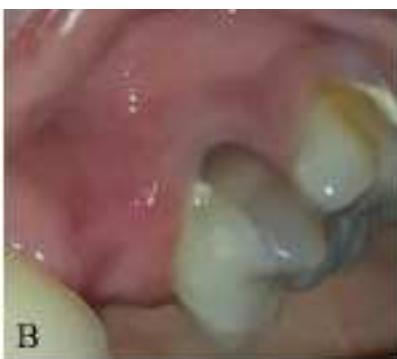
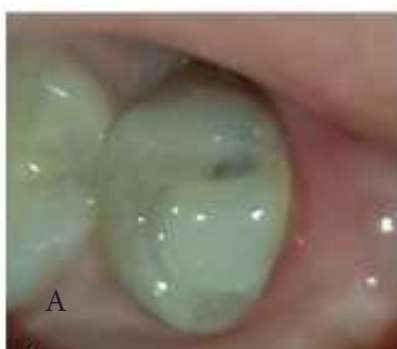Figure 1. Pre-operative images (A) Occlusal view. (B) Visible gingival swelling. (C) Radiographic image of the periapical radiolucency.

Access opening was done without removing the composite restoration. ProTaper Universal Retreatment (PTUR) instruments were used to remove the filling material in a crown-down technique as follows : D1 (#30/.09) for the cervical third, D2 (#25/.08) for the middle third, and D3 (#20/.07) for the apical third until the working length was reached. The instruments were used with an XSmart electric motor (DentsplyMaillefer) at aspeed of 400 rpm and with a torque of 3 Ncm. After root canal was clean, the canals were irrigated with 2.5% sodium hypochlorite. The canals were dried with sterile paper points, calcium hydroxide dressing was given and access cavity was closed.

On the second visit, root canal exploration was performed using k-file #10 with the estimated working length of the 19 mm measured from radiographic image. The definitive working length was obtained

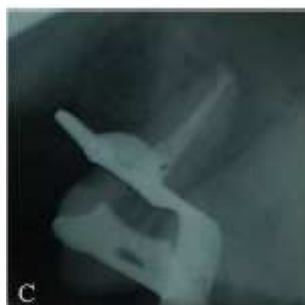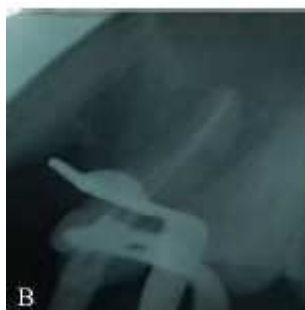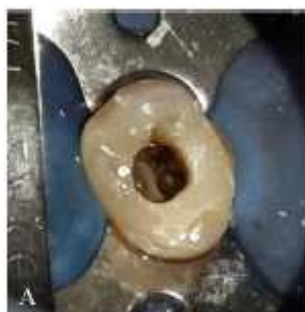by using apex locator, which are 19 mm for buccal root canal. Canal preparation was performed using ProTaper Next to X5/19 mm. After the canal preparation was finished, apical gauging was performed using file #50/19 mm and there was a sensation of snug/fit. The master apical cone X5 was inserted in the buccal canal and a sensation of tug-back was felt, then k-file #10 was introduced in the palatal canal along the estimated working length. The impression left on the gutta-percha indicated the confluence point of the two root canals. The working length of palatal canal was measured from the reference point to the confluence point, which was 17.5 mm. Palatal canal preparation was performed using ProTaper Next up to X3/17.5 mm. The canals were irrigated with 2.5% sodium hypochlorite between instruments. The irrigation sequence was EDTA, saline, 2.5% sodium hypochlorite, saline and final rinse with chlorhexidine. The irrigation material was activated using the endoactivator.

At the third visit as the tooth was asymptomatic, the root canal system was obturated with cold lateral compaction of guttapercha cones (protaper gutta-percha X5 and X3 on the buccal and palatal canal respectively) along with resin-based sealer (AH plus). The pulp chamber was sealed with glass ionomer cement and access cavity was closed with cavit.

During the fourth visit, the teeth was restored with a fiber post and composite build-up. After the old composite

restoration was removed from the cavity, removal of gutta-percha up to 4.5 mm short of apex and post space preparation was done using gates glidden drill and fiber clear drill respectively. Fiber post was cemented using breeze self-adhesive resin cement and cut 2 mm above the orifice. Core build-up was done with composite resins, then proceeded with preparation for porcelain fused to metal crown.

On the fifth visit, the cementation of the crown was performed with glass ionomer cement.



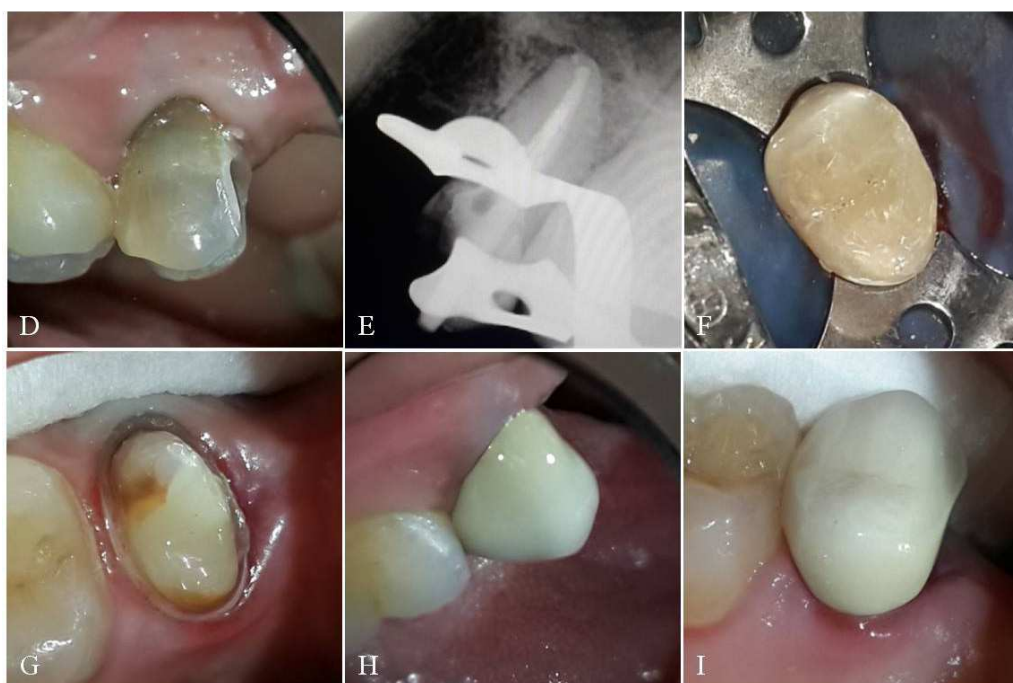

Figure 2. (A) Access opening after removal of obturation material. (B) Radiographic images of master apical cone. (C) Obturation. (D) Post-treatment follow up and discoloration was visible. (E) Fiber post cementation. (F) Core build-up. (G) Preparation of porcelain fused to metal crowns. (H dan I) Crown cementation.

DISCUSSION

In this case report, a previous endodontic treatment on the maxillary second premolar (25) showed underfilled obturation that was visible on the radiographic image. The previous post-endodontic restoration was composite restoration. Periapical radiolucency indicated a chronic apical abscess.

The etiologic factor in this case was persistent infection due to inadequate obturation of previous endodontic treatment and coronal leakage due to inadequate restorations. Unfilled apical region contain bacteria and necrotic tissue. The infecting flora are predominantly gram positive and a

commonly isolated species is *Enterococcus faecalis*, with prevalence values reaching up to 90% of cases.¹ Virulence of *E. faecalis* is associated with its resistance to intra-canal medicaments, its ability to persist in unfavorable root canal environment (alkaline pH to 9.6, high temperature to 60°C, and lack of nutrition), its ability to compete with other bacterial species, its ability to live as a single organism without the support of other bacteria, its ability to invade dentinal tubules, its ability to form biofilms and its ability to change host and environmental responses. In unfavorable environmental, *E. faecalis* will enter the viable but non-culturable (VBNC) stages as a defense reaction, and will reactivate

as environmental conditions improve. *E. faecalis* is also found to be resistant to the antimicrobial effects of calcium hydroxide due to several factors, including the ability of bacteria to maintain pH homeostasis (as a result of ion penetration in cell membranes and cytoplasmic buffer capabilities), proton pump mechanisms that will drives protons into the cell to acidify the cytoplasm and to lower the internal pH, the buffer capacity of dentine which causes the inability to maintain pH at 11.5 (*E. faecalis* cannot survive at $\text{pH} \geq 11.5$). These are the things that cause *E. faecalis* more common in persistent infections than other species. Taken together, all these properties help explain the significantly high prevalence of *E. faecalis* in root canal-treated teeth.^{1,8–}

¹⁰Inadequate coronal seal cause salivary contamination and the dissolution of the cement, thus microorganisms may invade and recolonize the root canal system. If microbial cells and their products reach the periradicular tissues, they can induce and/or perpetuate periradicular disease.^{4,5} in this case, since root canal filling does not provide a good apical seal and composite restoration does not provide a good coronal seal, seepage of tissue fluids can provide substrate for bacterial growth. when growing bacteria reach a significant number and gain access to the periradicular lesion, they will cause periradicular infection.

Removal of the filling material is fundamental for reshaping of the root canal system and for achievement of the desired goals in canal therapy. Root filling materials

act as a mechanical barrier against reaching the apex of the root during endodontic re-treatment, and any remnants of this material could hide the bacteria that may be responsible for failure of re-treatment. Complete removal of these residues may increase the success of endodontic re-treatment.³

The removal of root canal filling in this case report was performed using ProTaper Universal retreatment (PTUR) instruments. PTUR system consists of 3 instruments: D1, D2, and D3. D1 (#30.09), with the length of 16 mm, has an active tip and is used for the coronal third. D2 (#25.08), with the length of 18 mm, has an inactive tips and is used for the middle third. D3 (#20.07), with the length of 22 mm, also has an inactive tips and is used for the apical thirds. The system files have aconvex, triangular cross-section. The instruments are recommended to be used at a speed of 400-500 rpm and with a torque of 3 Ncm.^{3,6,7,11} ProTaper Universal retreatment instruments have progressive taper and lengths that enable them to cut and pull the GP into the file flutes and direct it toward the orifice.¹² Files should be withdrawn frequently for the removal of the debris from instrument flutes before being reintroduced in the root canal system.¹³

Hand instruments are undoubtedly the most commonly practiced, but they may be time consuming and occasionally yield limited results. The rotary technique is considered to be fast and safe for removal

of well-condensed obturation, even in curved canals. ProTaper retreatment files having larger tapers can be expected to result in a cleaner canal than stainless steel hand files.¹²

The better performance of ProTaper Universal retreatment files may be attributable not only to their design but also due to their cutting action. They cut not only GP but also a superficial layer of dentine during root filling removal.³ The apical diameter of the D3 is size 20 because this is the last instrument designed to reach the working length, but it does not permit a complete cleaning action.¹¹ Based on previous studies, among all techniques and instruments used for the removal of filled material in endodontic retreatment, none of the technique was 100% effective in removing the filling materials.^{3,6,7,13,14} Therefore, further root canal preparation is required.

Some researchers stated that a combination of solvents with a rotary instrument can complicate the removal of gutta-percha. The softening effect of solvents on gutta-percha results in inadvertent distribution of gutta-percha from the canal walls in the form of a film on the canal surface. The thin film of filling materials thus formed may reduce the action of irrigation material and intracanal antibacterial medicaments, as well as impair the adaptation of subsequent filling material on the canal walls.^{13,14} However, there are studies showing that the use of solvents can help the removal of gutta-percha with

rotary instruments.^{3,7} Solvents effectively dissolve gutta-percha and allow quicker access to the working length. Furthermore, the use of solvents eliminates the need for excessive force during negotiation of gutta-percha obturated canals and thus preventing canal transportation.³ Therefore, the use of solvent in this case is only at the beginning of root filling removal to soften the coronal part of gutta-percha so as to help the penetration of D1.

Cleaning and shaping two canals in the same root which merge to a common foramen requires particular precautions to prevent tearing of the apical foramen or pointless weakening of the root. It is important to establish as soon as possible if the two canals existing in the same root have a common apex or if they are independent. The working length of the first root canal was measured from the reference point to the apical constriction, while the working length of the second root canal was measured from the reference point to the confluence point of two root canals.¹⁵ The palatal root canal preparation was shorter than the buccal root since it only reached the confluence point.

In the case of two canals merging to a single foramen (type 2 Vertucci configuration), only one of the two gutta-percha cones can be engaged at the apical foramen. The endodontist must decide which of the two is preferable to advance to the apex and this would be the one that has better 'tug-back'¹⁵, which is buccal canal.

In this case, discoloration and the lack of thickness in the buccal, distal, and palatal walls lead to the selection of fiber post and porcelain fused to metal crown as post-endodontic restoration.

CONCLUSION

Knowledge and understanding of complex root canal morphology is necessary to perform adequate chemomechanical preparation and obturation. Adequate endodontic treatment procedures starting from access preparation to root canal filling supported by adequate post-endodontic restoration will prevent the failure of endodontic treatment. Inadequate root canal filling and inadequate post-endodontic restoration may result in the endodontic failure. Endodontic retreatment is the first choice for management of endodontic failure. An important factor in ensuring successful retreatment is the removal of root canal filling followed by chemomechanical preparation, adequate obturation, and post-endodontic restoration that can provide good coronal seals and support remaining tooth structure.

REFERENCES

1. Hargreaves K, Cohen S. *Cohen's Pathways of the Pulp*. 11th ed. Missouri: Mosby Elsevier; 2011.
2. Vertucci FJ. Root canal morphology and its relationship to endodontic procedures. *Endod Top*. 2005;10:3-29.
3. Dixit S, Kumar P, Agarwal S, Dixit

A. Comparative Evaluation Of Effectiveness Of Protaper Universal Rotary Retreatment System And Mtwo Retreatment System For Gutta-percha Removal With Or Without Solvent-an In Vitro Study. *Indian J Dent Sci*. 2014;3(6):12-15.

4. Siqueira Jr JF. Aetiology of root canal treatment failure: Why well-treated teeth can fail. *Int Endod J*. 2001;34(1):1-10.
5. Ingle JJ, Bakland LK, Baumgartner JC. *Ingle's Endodontics* 6. Hamilton, Ontario: BC Decker Inc; 2008.
6. Maiti N, Das UK, Mukherjee S. Evaluation of four different retreatment files in root canal retreatment using digital imaging software & stereomicroscope. *Guident*. 2014:84-90.
7. Mittal N, Jain J. Spiral computed tomography assessment of the efficacy of different rotary versus hand retreatment system. 2014;17(1):8-13.
8. Kayaoglu G, Ørstavik D. Virulence Factors of *Enterococcus faecalis*: Relationship to Endodontic Disease. *Crit Rev Oral Biol Med*. 2004;15(5):308-320.
9. Portenier I, Waltimo TMT, Haapasalo M. *Enterococcus faecalis*— the root canal survivor and “star” in post-treatment disease. *Endod Top*. 2003;6(1):135-159.
10. Stuart CH, Schwartz SA, Beeson TJ, Owatz CB. *Enterococcus faecalis*: Its

role in root canal treatment failure and current concepts in retreatment. *J Endod.* 2006;32(2):93-98.

11. Giuliani V, Cocchetti R, Pagavino G. Efficacy of ProTaper Universal Retreatment Files in Removing Filling Materials during Root Canal Retreatment. *J Endod.* 2008;34(11):1381-1384.
12. Kumar MSR, Sajjan GS, Satish K, Varma KM. A comparative evaluation of efficacy of protaper universal rotary retreatment system for gutta-percha removal with or without a solvent. *Contemp Clin Dent.* 2012;3(Suppl. 2):160-163.
13. Gu L-S, Ling J-Q, Wei X, Huang X-Y. Efficacy of ProTaper Universal rotary retreatment system for gutta-percha removal from root canals. *Int Endod J.* 2008;41(4):288-295.
14. Bhagavaldas M, Diwan A, Kusumvalli S, Pasha S, Devale M, Chava D. Efficacy of two rotary retreatment systems in removing Gutta-percha and sealer during endodontic retreatment with or without solvent: A comparative in vitro study. *J Conserv Dent.* 2017;20(1):12.
15. Castellucci A. Two canals in a single root: clinical and practical considerations. *Endod Prac.* 2001:17-23.

ROOT CANAL TREATMENT OF UPPER FIRST MOLAR WITH TWO-THIRD APICAL OBLITERATION

Celine Marissa¹, Munyati Usman²

¹Post Graduate Student, Department of Conservative Dentistry,
Faculty of Dentistry Universitas Indonesia

²Lecturer, Department of Conservative Dentistry,
Faculty of Dentistry Universitas Indonesia

ABSTRACT

Canal obliteration is defined as a deposition of hard tissue within the root canal space. These tissues can eventually produce the radiographic appearance of a root canal space that has become partial or completely calcified. Success in root canal treatment is based on proper debridement, disinfection and obturation of the root canal system. The purpose of this case report is to present a clinical case of the root canal treatment for first maxillary molar which was non-vital upon pulp testing. Radiograph shows 2/3 apikal partial obliteration in mesiobuccal and distobuccal canal. Canal exploring with C+ File #8 and lubrication of RC Prep Premiere. The working length was determined. Chemo-mechanical preparation was done with Protaper Hand use and obturated by using single cone technique with AH plus sealer.

Keywords: *obliteration root canal, upper maxillary molar*

INTRODUCTION

Root canal obliteration is a challenge in the diagnosis and treatment of endodontics. Teeth that have long experienced necrosis generally will be obliterated. Root canal obliteration is defined as a response to trauma that has a characteristic presence of hard tissue deposition in the root canal space.¹ This case presents its own challenge in endodontic treatment.

The main purpose of endodontic treatment is to prevent and or cure apical periodontitis through chemomechanical

preparation followed by obturation of the root canal space with hermetic in three dimensions³. However, this will be difficult if the pulp chamber and root canal are narrowed, obstructed or obliterated.

Clinically it can be seen that there has been root canal obliteration at least 3 months post trauma, but generally not detected up to 1-4 year. On clinical examination, the obliterated tooth is usually asymptomatic and has yellowish discoloration with decreased thermal response compared to the adjacent teeth⁵. Only 7-27% of teeth with root canal

obliteration will experience pulpal necrosis and are often discovered accidentally through radiographic examinations that have had apical periodontitis requiring endodontic treatment⁶. This becomes a challenge for the dentist in deciding on treatment, whether endodontic treatment will be performed when there is known obliteration of the root canal or wait until there are complaints or clinical symptoms due to pulp infection or periapical disorders.

According to AAE criteria, dental root obliteration teeth require high end difficulty with endodontic treatment⁷. Obliteration may inhibit some or all access to the root canal system making it difficult for preparation, disinfection or obturation. A narrow root canal assessment is difficult to do, so may increase the risk of perforation and breakage of the instrument. The use of a dental operating microscope (DOM) enlargement device when the root canal obliteration treatment procedure can provide better visibility so that the treatment has a predictable outcome.

In this case report, we will discuss the root canal treatment of the maxillary first molar tooth obliterated at 2/3 apical in the mesiobuccal and distobuccal root canal and 1/3 apical of the palatal root canal to gain access and assessment to apex followed by root canal preparation and obturation.

CASE REPORT

A 36-year-old female patients came to RSGMP with right upper tooth complaints are often hurt when it was used for eating.

The tooth had spontaneous pain a year ago and now it didn't hurt anymore. Percussion tests positive. There is no mobility and no swelling. A radiograph of tooth number 16 was taken which revealed that themesiobuccal and distobuccal canal could not be traced in two-third apical and palatal root canal looked narrow with obliteration in the apical third Radiographic examination of the tooth 16 shows large caries lesion reaches the pulp of the mesial and distal molar teeth, lamina dura thickened and periodontal space widened (Fig. 1). Tooth 16 was diagnosed as chronic apical periodontitis etcausa necrosis of the pulp. Based on the diagnosis, a treatment plan is defined in this case is non-vital root canal treatment with onlay restoration.

CASE MANAGEMENT

Treatment of tooth 16 begins with cavity access preparation and 2/3 corona preparation with File SX. Root canal treatment assisted with a dental loupe, there were 3 orifices seen: mesiobuccal, distobuccal and palatal. Then made an artificial wall on the mesial and distal side.

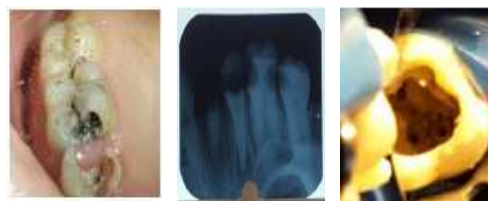

Figure 1. (a) Clinical preoperative photo. (b) Radiograph photo of tooth 16. (c) Artificial wall and access preparation

Next, we started the palatal root line exploration first with C + # 10 and lubrication with RC Prep. Files could enter 17 mm in length. From the radiograph seen the estimated working length is 20 mm, it turned out there is obliteration in 1/3 apical. The assessment was done repeatedly until definitive working length was reached with IAF #10, 20 mm. Irrigation using 2.5% NaOCL, rinsed with saline and then using 17% EDTA solution, rinsed with saline again every change of file.

Distobuccalroot canal exploration was done with C + # 8 and lubrication with RC Prep. From the radiograph seen the working length estimation is 16 mm, there was obliteration on 2/3 apical. The assessment was done repeatedly until it was reached Initial File # 8 with a definitive working length of 16 mm. Irrigation using 2.5% NaOCL, rinsed with saline and then using a 17% EDTA solution, rinsed with saline again every change of file

Mesiobuccal root canal assessment was done with C + # 8 and lubrication with RC Prep. Files can only fit 5 mm long. From the radiograph seen the working length estimation was 17 mm, there was obliteration in 2/3 apical. The assessment was done repeatedly until it was reached Initial File # 8 with a definitive working length of 17 mm. Irrigation using 2.5% NaOCL, rinsed with saline and then using a 17% EDTA solution, rinsed with saline again every change of file. Medicaments with CHKM, cotton pellet, and temporary cement




Figure 2. After IAF distobuccal and palatal, while mesiobuccal still less 5mm (left). After IAF obtained on the three canals according to the definitive working length (right)

The next visit was chemomechanical preparation using crown-down technique using Protaper Hand Use/manual until obtained master apical file (MAF) palatal # F3, 20 mm, mesiobuccal # F2,17 mm and distobuccal # F2,16 mm. (Figure 3). Medicaments used Ca (OH)₂, cottonpellet and temporary cement

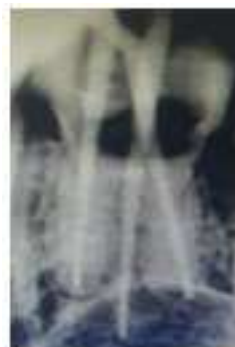

Figure 3. Master Apical File's Radiograph

The next visit, obturation was done using AH plus sealer and lining with GIC. Then temporarily restored.

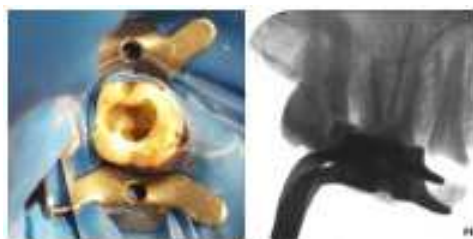


Figure 4. Obturation's Radiograph

Further composite preparation and composite restoration was done because the patient had to move out of town. (Figure 5).

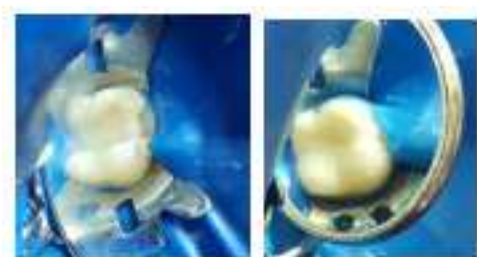


Figure 5. Preparation of direct composite and after direct composite restoration

DISCUSSION

Based on the objective and subjective examination, the main factor, in this case, was thought to be caused by deep caries. Dental caries is a chronic infection caused by bacterial penetration into enamel and dentin. Microorganisms will trigger an inflammatory response of the dental pulp. If irritant is not removed, chronic infection will generally persist within the pulp, this will induce a permanent loss of normal tissue thus affecting reparability, causing pulp necrosis and, if exposed, to periapical tissue damage⁵. In this case, it was decided to perform endodontic treatment because

there were periapical lesions on the radiographs.

In this case, the obliteration occurred in the mesiobuccal and distobuccal root canal due to caries in the mesial and distal portions of the tooth, resulting in obliteration from the pulp horn to the root canal in mesiobuccal and distobuccal. Dental Loupe is a very helpful tool in performing endodontic procedures on posterior teeth. dental loupe routinely used in endodontic procedures can improve visibility and lighting. The advantage gained when using the loupe is improving the visualization of the anatomy of the root canal so as to help the operator investigate the root canal system and form the root canal more efficiently. The success rate in detecting root orifice with higher loupe use compared to direct viewing without the aid of a magnification tool

Good cavity access preparation is one of the keys to successful endodontic treatment. The radiographic examination also plays an important role during initial examination and during treatment. It takes patience and knowledge of the anatomy of the root canal system in order to succeed in exploring the obliterated root canal. Knowing the morphology of the root canal system is essential in obtaining successful endodontic treatment. Based on Jacobsen and Kerekes classification, in the three root canals, there is partial obliteration.

After cavity access, operators have difficulty in root canal assessment, especially on mesiobuccal root canals.

Then the operator uses the file C + (Dentsply, Tulsa, OK, USA). because the stainless steel-based material that has cross-sectional design characteristics of the box-shaped material aims to resist distortion and reduce the risk of iatrogenic, rigid properties, cutting and pyramid-shaped tip design that can penetrate obliterated canal. This is in line with Mounce's research, that stainless steel files with rigid file properties are capable of exploring the obliterated canals³⁷.

Use of chelator materials should be used when exploring the root canal, especially in narrow root canals and obliteration³⁸. Ethylenediaminetetraacetic acid (EDTA) works on obliteration tissue by replacing calcium ions in sclerotic dentine with sodium ions, making it more soluble. At normal concentrations, EDTA removes 10.6 g of calcium from 100 g of calcium³⁹. EDTA resulted in demineralization of dentin with a depth of 20-30% within 5 min⁴⁰. Liquid irrigation materials are able to reduce the torque load while the paste/gel material is able to increase the ability to cut the network during instrumentation⁴¹.

Lubrication during root canal preparation may reduce the mechanical load on the instrument, thereby decreasing the risk of fracture in the instrument⁴². In this case lubrication with RC Prep (Premiere Dental, Philadelphia, PA, USA) contains 10% urea peroxide, 15% EDTA and glycol as a liquid base. The reaction between RC-Prep and NaOCL will produce free oxygen so that the rest of the pulp and

debris tissue can be more easily cleaned on the root canal wall (Stewart et al, 1969). Urea peroxide provides an antimicrobial effect whereas glycol will act as a lubricant during instrumentation⁴³

In this case, EDTA irrigation and lubrication of RC Prep is performed during the instrumentation stage, it is intended that the narrow and transliterated root canals can be easily and efficiently penetrated in the penetration of dentine tissue. After putting EDTA into the root canal, it is necessary to rinse with saline solution, because EDTA reaction with NaOCL can decrease the antibacterial effect of NaOCL or it can also use NaOCL as the last irrigation solution.

Root canal preparation, in this case, was performed using manual protaper instruments as an alternative to rotary instruments. Manual protaper based on Ni-Ti while rotary pro taper based on Ni-Ti M-wire. According to YaShen et al., The flexibility of the M-wire instrument is higher than that of conventional NiTi⁴⁴. Nevertheless, the manual protaper has several advantages such as the increased efficiency of cutting dentine tissue because it has the design characteristics of the triangular cross-sectional shape, no screw effect to dentin, better tactile control thus maintaining the original form of the root canal so false transportation risk can be decreased.

CONCLUSION

Endodontic treatment of obliterated root canals has a high degree of difficulty.

In this case the success of endodontic treatment can occur because it is supported by knowledge of anatomy and variation of root canal systems, good cavity access preparation, use of magnification aids, patience as well as the selection of appropriate tools, materials, and techniques when performing root canal instrumentation have an important role in overcoming difficulties while exploring and penetrating canal to the apex. If endodontic treatment of root canal obliteration is well done without an iatrogenic error will have a good prognosis as well.

REFERENCES

1. American Association of Endodontists. *Glossary of Endodontic Terms*. 8th ed.; 2012.
2. Thomas B, Patidar A, Deosarkar B, Kothari H. Calcified Canals – A Review. *IOSR J Dent Med Sci*. 2014;13(5):38-43.
3. Vertucci FJ. Root canal morphology and its relationship to endodontic procedures. 2005;3:29.
4. Amir FA, Gutmann JL W DE. Calcific metamorphosis: A challenge in endodontic diagnosis and treatment. *Quintessence Int*. 2001;32:44755.
5. Schindler WG & Gullickson DC. Rationale for the management of calcific metamorphosis secondary to traumatic injuries. *J Endod*. 1988;14(408-12).
6. McCabe PS, Dummer PMH. Pulp canal obliteration: An endodontic diagnosis and treatment challenge. *Int Endod J*. 2012;45(2):177-197. doi:10.1111/j.1365-2591.2011.01963.x.
7. American Association of Endodontics. Case Difficulty Assessment Form and Guidelines B. 2006.
8. Walton RE TM. *Principles and Practice of Endodontics*. 3rd ed. (W. B. Saunders, ed.). St. Louis; 2002.
9. Şener S, Cobankara FK, Akgünlü F. Calcifications of the pulp chamber: Prevalence and implicated factors. *Clin Oral Investig*. 2009;13(2):209-215. doi:10.1007/s00784-008-0212-x.
10. Nagaraj T, Sinha P, Goswami RD, Veerabasaviah BT. A radiographic assessment of the prevalence of idiopathic pulp calcifications in permanent teeth: A retrospective radiographic study. 2014;26(3):5-8. doi:10.4103/0972-1363.144993.
11. Soames J and SJ. *Oral Pathology*. 2nd ed. Oxford: Oxford University Press; 2005.
12. Stanley HR RR. Age changes in the human dental pulp. The quantity of collagen. *Oral Surg Oral Med Oral Pathol*. 1962;15:1396.
13. Andreason J AF. *Textbook and Colour Atlas of Traumatic Injuries to Teeth*. 3rd ed. Copenhagen: Munksgaard; 1994.
14. Robertson A, Andreasen FM, Bergenholz G AJ, JG N. Incidence of pulp necrosis subsequent to pulp canal

- obliteration from trauma of permanent incisors. *J Endod.* 1996;22:557-560.
15. de Cleen M. Obliteration of pulp canal spaces after concussion and subluxation. In: *Endodontic Considerations*. Quintessence Int; 2002:661-669.
16. Andreasen FM, Yu Z, Thomsen BI AP. Occurrence of pulp canal obliteration after luxation injuries in the permanent dentition. *Endod Dent Traumatol.* 1987;3:103-105.
17. Hargreaves K.M. and Berman L.H. *Cohen's Pathways of the Pulp Expert Consult*. 11th ed. St. Louis: Mosby; 2016.
18. Kim S, Trowbridge H SH. Pulpal reaction to caries and dental procedures. In: In Cohen S BR, ed. *Pathways of the Pulp*. 8th ed. St. Louis: Mosby; 2002:573-600.
19. Jacobsen I KK. Long-term prognosis of traumatized permanent anterior teeth showing calcifying processes in the pulp cavity. *Scand J DentRes.* 1977;85(7):588-598.
20. Bauss O, Rohling J, Rahman A KS. The effect of pulp obliteration on pulpal vitality of orthodontically intruded traumatized teeth. *J Endod.* 2008;34:417-420.
21. Piattelli A. Generalized "complete" calcific degeneration or pulp obliteration. *Endod Dent Traumatol.* 1992;8:25963.
22. Torneck CD. *The Clinical Significance and Management of Calcific Pulp Obliteration*. Alpha Omegan; 1990.
23. American Association of Endodontists; American Academy of Radiology. O and M. Use of conebeam computed tomography in endodontics 2011;111:2347. *J Oral Surg Oral Med Oral Pathol Oral Radiol Endod.* 2011;111:234-237.
24. Patterson SS MD. Calcific metamorphosis of the dental pulp. *Oral Surg Oral Med Oral Pathol.* 1965;20:94-101.
25. Chugal NM, Clive JM SL. A prognostic model for assessment of the outcome of endodontic treatment: Effect of biologic and diagnostic variables. *Oral Surg Oral Med Oral Pathol Oral Radiol Endod.* 2001;91:34252.
26. Robertson A, Lundgren T, Andreason JO, Dietz W, Hoyer IJG. N. Pulp calcifications in traumatized primary incisors. A morphological and inductive analysis study. *Eur J Oral Sci.* 1997;1997;105:1.
27. Utpal Kumar Das S Das. Dental Operating Microscope in Endodontics-A Review. *IOSR J Dent Med Sci.* 2013;5(6):1-8.
28. Johnson BR. *Endodontic Access*. Gen Dent; 2009.
29. Weine F. *Endodontic Therapy*. 3rd ed. St. Louis: Mosby; 1982.
30. Malagnino VA, Cantatore G SP. Studio sull'anatomia endodontica dei

- secondi molari inferiori. *G It Endo*. 1992;6.
31. Castelluci A, Becciani R, Patroni S BE. L'anatomia dei primi e secondi molari inferiori: considerazioni cliniche e chirurgiche. 1987;1287.
 32. Krasner P, Rankow HJ. Anatomy of the pulp-chamber floor. *J Endod*. 2004;30(1):5-16. doi:10.1097/00004770-200401000-00002.
 33. Andreasen JO. Luxation of permanent teeth due to trauma: a clinical and radiographic follow-up study of 189 injured teeth,. *Scand J Dent Res*. 1970;78:273.
 34. Oginni AO, Adekoya-Sofowora CA, Kolawole KA. Evaluation of radiographs, clinical signs and symptoms associated with pulp canal obliteration: An aid to treatment decision. *Dent Traumatol*. 2009;25(6):620-625. doi:10.1111/j.1600-9657.2009.00819.x.
 35. Garg P, Singh U, Tyagi S, Chaman C. Root canals-from concretion to patency. *Saudi Endod J*. 2015;5(1):13. doi:10.4103/1658-5984.149081.
 36. L G. Single vital tooth whitening. *Aesthet Dent Today*. 2007;1:42-44.
 37. Pedorella CA, Meyer RD WG. Whitening of endodontically untreated calcified anterior teeth. *Gen Dent*. 2000;48:2525.
 38. West JD. The aesthetic and endodontic dilemmas of calcific metamorphosis. *Pr Periodontics Aesthet Dent*. 2007;9:28993.
 39. McCabe P. Avoiding perforations in endodontics. *J Ir Dent Assoc*. 2006;52(3):139-148.
 40. Carrotte P. Surgical endodontics. *Br Dent J*. 2005;198:719.
 41. Sardhara Y, Dhanak M, Parmar G. Management of Maxillary Central Incisor with Calcified Canal : Case Report. 2016;15(1):24-27. doi:10.9790/0853-15112427.
 42. Sridevi N, Puspha S, Iqbal M, Prasad A, Singh P SR. Channels to cruise the calcified canal. *Rama Univ J Dent Sci*. 2015;2(1):47-52.
 43. Baumgartner JC MC. A scanning electron microscopic evaluation of four root canal irrigation regimens. *J Endod*. 1987;13:147-157.
 44. O'Connell MS, Morgan LA, Beeler WJ BJ. A comparative study of smear layer removal using different salts of EDTA. *J Endod*. 2000;26:739-743.
 45. Vassiliadis LP, Sklavounos SA SC. Depth of penetration and appearance of Grossman sealer in the dentinal tubules: An in vivo study. *J Endod*. 1994;20:373-376.

CASE REPORT

MANAGEMENT ON APICAL THIRD FRACTURE OF CENTRAL INCISOR : A CASE REPORT

Putu Ferbika¹, Latief Mooduto²

¹Resident of Conservative Dentistry

²Lecturer of Departement of Conservative Dentistry

Departement of Conservative Dentistry

Faculty of Dental Medicine – Universitas Airlangga

Surabaya, Indonesia

ABSTRACT :

Background :Horizontal root fractures present an interesting diagnostic and treatment challenge for the endodontist. These types of fractures comprise only 3% of all dental injuries. Fracture occurs often in the middle-third of the root and rarely at the apical-third. This article presents a clinical case of horizontal root fracture, in an adult patient, male, located in the apical third, due to a car accident. **Purpose :**This case report describes the procedure of apical resection in upper first incisor. **Case report :**A 26 year-old male patient came to the Conservative Department Faculty of Dental Medicine – Universitas Airlangga. His chief complaint was about history of pain upper first incisor a month ago after a car accident. On examination revealed upper first incisor with broken porcelain fused to metal crown. Radiographic finding showed horizontally root fracture on apical third. **Method :** Root resection after endodontic treatment was performed. The end of the root sealed with mineral trioxide aggregate (MTA) and bone graft application. Custom post was placed restored with porcelain fused to metal (PFM) crown. After 1 month patient was recalled for re-evaluation. **Conclusion:** This case report depicts the retrieval of apical fracture segment by surgical approach. At last, this case followed the successful prognosis due to the perfect sealing of the root canal system.

Keyword :Horizontal root fracture, apical resection, maxillary incisor

Introduction

Root fracture in one of the more unusual sequelae to the traumatic injury of a tooth. When the traumatic injury results in a root fracture that is oriented more horizontally and completely in cases in bone often there is a favorable prognosis.²

Surgical procedure decided when the conventional treatment did not succeed. The condition for the example anatomical reason, periapical lesion, fracture and etc. Root resection is a general surgical procedure that commonly choose. The purpose of this procedure is try to guarantee the tight/precision of placement materials between the apical foramen and

periodontium. Root resection is a root end cutting so the tooth is saved by the endodontic treatment. This procedure also offers the possibility to detect possible fractures of the tooth root. Several categories can be grouped in the case of a root resection recommendation, those are; anatomical problem, horizontal fractures of the root with apical necrosis, obstacles on the length of radicular canal, endodontic treatment procedural errors, persistent serious periapical lesions which endodontic treatment can not eliminated.^{3,5}

The success rate of root end resection relatively high, however not all the bone formation are showed completely done after the surgery. Monitoring any changes should be done at least on a yearly within regular follow ups in assessing the outcome. Clinical thoroughness during the treatment phase can potentially benefit both the clinician and the patient in the long run.⁵

Case

A 26 years old male came to Conservative Department Faculty of Dental Medicine Universitas Airlangga with a chief complain of his upper right first incisor. The tooth had been treated with previous dentist located from another city and it was not done yet. He had a car accident 2 months ago. He also reported persistent pain on the gingiva in the apical portion. His first right upper incisor was post endodontic treatment. Clinical examination found pain on palpation and

the porcelain fused to metal crown often fell-off easily. On radiograph examination showed gutta point the apical portion and horizontal root fracture (diastasis) on the apical third. After explanation we decided to do endodontic retreatment following root end resection apical surgery.

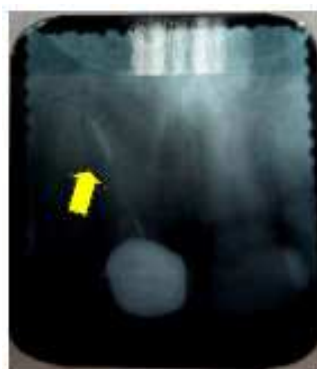

Figure 1 : Pre – operative radiograph

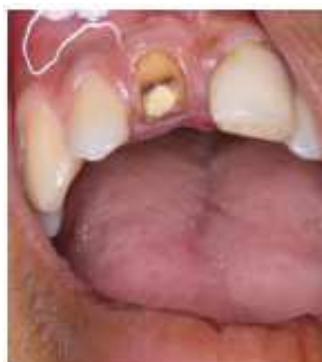

Figure2 : Pre-operative clinical view
(crown removed)

Case management

After working length determination root canal was prepared with Ni-Ti K-File hands instrument number 100. During instrumentation root canal was irrigated with sodium hypochlorite and aquades. Final irrigation was completed with sodium hypochlorite, edta and chlorexidine with

aquades every irrigants sequences, at last activated using sonic irrigation device. (*Eddy, VDW*, Germany) Root canal was obturated with guttap point and sealer. The patient referred to pathology clinic faculty of dentistry universitas airlangga in order to complete blood check – up examination pre-surgical procedure. After 7 days recall the patient ready for the surgical procedure.

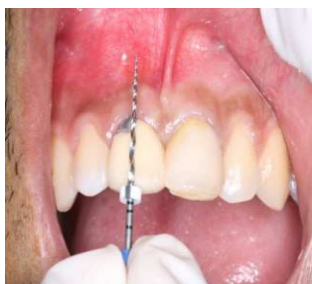

Figure 3: Bleeding point approximation

The root end apex resection was done under local anesthesia. Bleeding point was determined approximately on the fracture area (20 mm apically from coronal). A Full thickness semilunar mucoperiosteal flap was raised extending from mesial aspect of 11 to mesial aspect 12 using blade size #15 and rasparatorium. Following raising a flap, alveolar bone osteotomy was done using low speed bur to get the access of root end. Surgical area was irrigated using normal saline. Fracture fragment removed by bein. Once the root end exposed, the ultrasonic tips (*SatelecActeon Group, MérignacCedex, France*) were used to make a deep retro filling material. The retrograde filling was done with MTA (*Pro Root MTA, Dentsply, USA*). After bone graft application, the flap was then repositioned and approximated and then sutured.

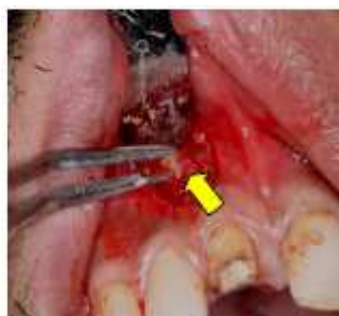

Figure 4 : Fracture fragment removal

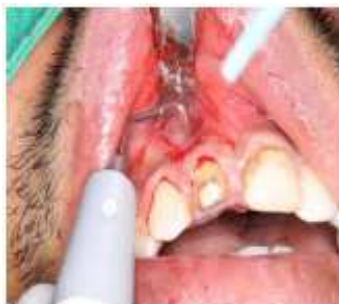

Figure 5 : Ultrasonic tips

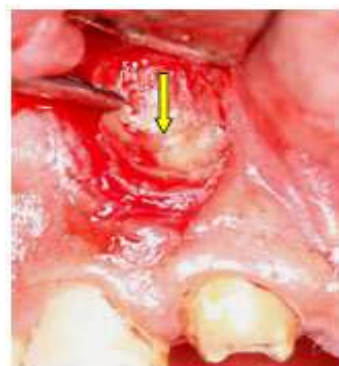

Figure 6 : MTA Filling Application

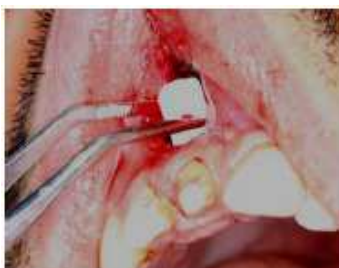

Figure 7 : Bone Graft application

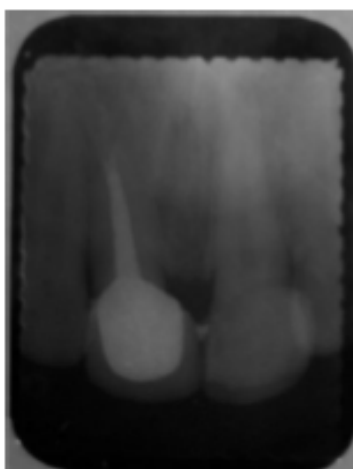


Figure 9 : Post - surgery

The post – operative medication prescribed to the patient. It was amoxicillin 500 mg 3 times daily for 3 days, and mefenamat acid 500 mg for analgesia. After 7 days the patient returned for suture removal and treatment evaluation. The tooth restored with porcelain fused to metal crown and metal custom post. A month later it was perserved that the pain symptom was completely absence and showed bone repair

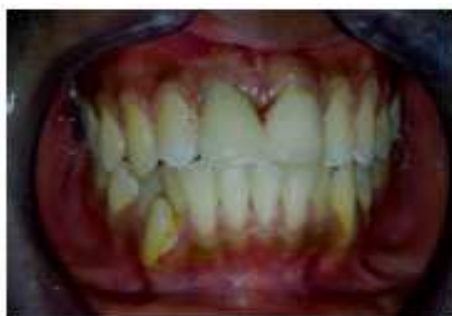

Figure 10 : Post Crown insertion

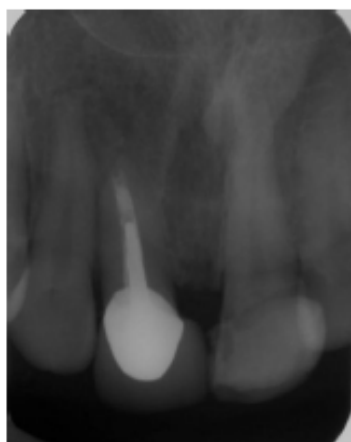

Figure 11: 1 month recall

Discussion

Horizontal root fractures present an interesting diagnostic and treatment challenge for the endodontist. These types of fractures comprise only 3% of all dental injuries. Fracture occurs often in the middle-third of the root and rarely at the apical-third. Clinician faced often difficulties in radiograph visualization of an intraalveolar root fracture lead to many root fractures undiagnosed. This is because the proximity of the fragments may be close when the first trauma occurs. Diastasis that increasing between root fragments may lead necrosis in coronal fragment, probably due to the increase pulp tissue damage and tend decrease potential for healing of the traumatic injury.^{1,2}

When nonsurgical treatment is impractical or unlikely improve the previous result, periradicular surgery is indicated. Endodontic treatment on the coronal fragment in traumatic injury signs and symptoms may suggest nonhealing.

Surgical intervention is recommended whereby the coronal fragment is stable when apical fragment removed. The location in new apical opening of the coronal fragment may be challenging to obtain accurate working length measurement determination.^{2,7}

MTA a material developed specifically in root end filling has undergone many in vitro or in vivo evidence examinations comparing with other materials. MTA show sealing ability and biocompatibility prevented leakage. Hydration of powder produces a colloidal gel that solidifies into hard structure consisting discrete crystals in matrix amorphous. 1

The wounding process varies depending on the types of tissue and injury however wound progress through three broad overlapping phases in the process of healing, inflammatory and maturation. The role of osteoclast found major difference between soft – and hard tissue wound healing. Granulation tissue begins to proliferate from the severed periodontal ligament by 2 to 4 days after root-end resection. The presence of appropriate inducible cell types, growth factors, and specific substances necessary for mineralisation is the key to regeneration. The prognosis may be more favorable on fracture which is located more apically. Fracture or cracks may lead to extraradicular infection, formation of sinus because the presence of numerous bacteria.^{1,6,7}

Conclusion

Surgical root canal treatment reported by many authors 90% success with careful case selection, surgical skill, the use of materials and techniques.

References

1. HARGREAVES, K. M., COHEN, S., & BERMAN, L. H. (2011). *Cohen's pathways of the pulp*. St. Louis, Mo, Mosby Elsevier. <http://www.clinicalkey.com/dura/browse/bookChapter/3-s2.0-C20090431714>
2. BERMAN, L. H., BLANCO, L. P. D., & COHEN, S. (2007). *A clinical guide to dental traumatology*. St. Louis, Mo, Mosby/Elsevier.
3. Nurliza C. Reseksi Akar Vital pada Gigi Molar Rahang Atas. e_USU Repository, 2004.
4. Das D, Srivastava A, Sridevi N, Singh S. *Surgical Endodontics is not just Apicoectomy: Report of Two Cases* Rama Univ. J. Dent Sci 2017 Mar;4(1):36-38
5. Tabassum S, Khan FR. *Failure of endodontic treatment: The usual suspects*. Eur J Dent 2016;10:144-7
6. Song M, Kim HC, Lee W, Kim E. *Analysis of the cause of failure in nonsurgical endodontic treatment by microscopic inspection during endodontic microsurgery*. J Endod 2011;37:1516-9.
7. Thomas von Arx, A Review of current techniques and outcomes. The Saudi Dental Journal (2011) 23,9-15

CASE REPORT

SMILE MAKEOVER IN THE PATIENT WITH MULTIPLE CARIES, FRACTURE AND LABIOVERSION

Ratih Elisa Nandarani¹, Kun Ismiyatin²

¹Resident of Department of Conservative, Faculty of Dental Medicine,
Universitas Airlangga, Surabaya, Indonesia.

²Department of Conservative, Faculty of Dental Medicine, Universitas Airlangga,
Surabaya, Indonesia.

ABSTRACT

Background : A charming smile plays a major role in building a person's self image and increases one's confidence. An esthetic smile is created by the position, size, shape, color, overjet, and overbite of the tooth. Multiple caries, fractured teeth, and the imperfect shape of teeth of the anterior teeth could result in an unesthetic smile which sometimes becomes a reason of a patient to visit the dentist. **Purpose:** To evaluate the success rate of smile make over treatment. **Case:** A 27-year-old female patient came with the diagnosis of caries on the 11, 21, 22, teeth, Ellis's class 2 fracture on 12, rotation and labioversion on 13, 23, overjet 8 mm on the 21 tooth, 7mm on the 12 tooth, 5mm on the 11, 21, 23 teeth, 3mm on the 13 tooth. **Case management:** Complex esthetic treatment consists of ten steps which are, making impression then making waxup and mock up, determining the enamel color before and after preparation, root canal treatment, crown lengthening and making provisional crowns, decapitation and mounting of casting, try-in for the porcelain crown, and insertion of the porcelain crown. Clinical and radiographic evaluation following one month after the insertion showed good marginal adaptation and aesthetics and fonetic. **Conclusion:** Smile make over with complex aesthetic treatment can be done by altering inclination, fixing the shape, position, and color will change smiles, functions and phonetics.

Keywords : Complex esthetic, esthetical smile, root canal treatment, multiple caries, casting

Correspondence : Kun Ismiyatin; Departement of Conservative Dentistry, Faculty of Dental Medicine, Universitas Airlangga, Surabaya-Indonesia. E-mail: ismiyatinkun@yahoo.com. Mobile: +628573320577

INTRODUCTION

Restorative dentistry is the art and science of replacing the tooth structure of a human. Confidence is an important aspect of one's personality and a confident

smile completes the picture. People seeking for dental treatment as of aesthetic purposes has significantly increased by time and increased awareness towards their appearance. Hence it has become

important to have techniques and materials which can meet the patients' aesthetic desires and also simultaneously provides a most conservative way to meet structural, biological and mechanical requirements that can provide a long term clinical durability.

A smile holds an important role in evaluating the treatment of complex aesthetics. A smile is a face expression that is made of a curve on the two angles of the lips. It is a change of facial expression which consists of the eye radiance, an upward curve from the angles of the mouth without any sound and a slight muscle change when compared to laughing. A smile is made of three components that interacts to each other which includes the teeth, the lips as the frame and the apparent gingiva.

Complex aesthetic is the treatment to treat teeth that are seen when smiling, usually the six anterior teeth. This treatment consists of the shape, position, color, size and inclination.

CASE REPORT

A 27-year-old female came to the Conservative department of Universitas Airlangga with a complain of multiple cavities, fractured, and discoloration on the upper front teeth which made her lose self-confidence and felt embarrassed when smiling. From the intra oral examination, it was obtained that there were caries on 11, 21, 22 teeth, class 3 Ellis fracture on tooth 12, rotation and labioversion on teeth 13,

23, 8 mm overjet on tooth 21, 7 mm on tooth 12, 5 mm on teeth 11, 21, 23, 3 mm on tooth 13. From the extra oral examination it was obtained that the patient was incompetent in closing her mouth (Figure 1). The radiographic supporting examination by panoramic and periapical imaging showed lesion on teeth 11, 12. There was no history of systemic disease on the patient (Figure 2).

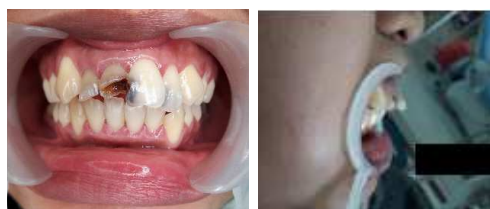

Figure1. The teeth condition before treatment.

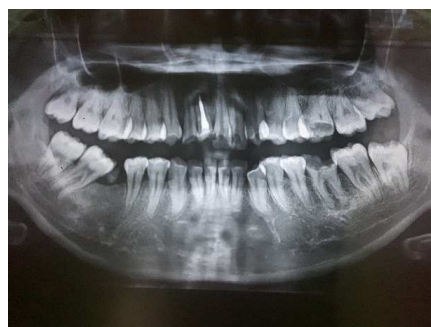

Figure 2. Panoramic Radiographic Imaging

CASE MANAGEMENT

The first step prior to the treatment was making impression of the teeth then casted the impression to provide a working model and a study model. After the new treatment plan for the crowns has been obtained, the patient was informed about the treatment plan which will be conducted using the study model. The working model was used for the fabrication of temporary crowns (Figure 3). The patient signed the informed consent.

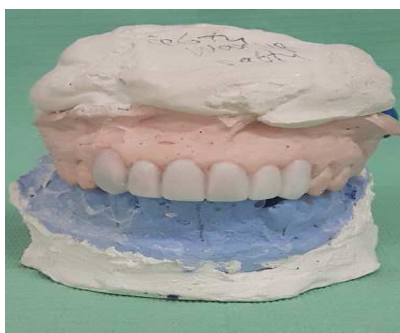

Figure 3.Diagnostic wax up

The second step was to match the tooth color before preparation to determine the enamel color (figure 4).

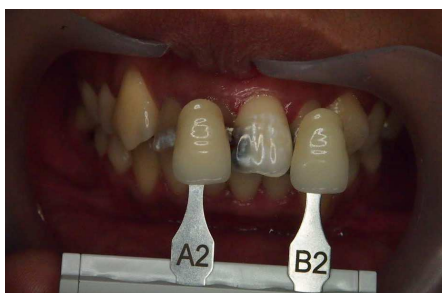


Figure 4. Enamel Shade Guide

The third step was a one-visit root canal treatment on teeth 11,12,21,22,23. Cavity treatment was also done to teeth 11,

12, 21, 22, 23 in a single visit. The aseptic working area was performed by inserting a rubber dam. Cavity entrance, Diagnostic Wire Photo and work length measurement were done. Afterwards, pulpal tissue extirpation, root canal space preparations were done with a conventional technique using K-file to confirm the working length. In every file change, the root canal space was irrigated with 2,5% NaOCl and sterile aquadest. The next step was gutta point trial and taking a radiographic image for a trial photo. The root canals were filled with AH Plus paste and gutta point filler material using the single cone technique (figure 5).



Figure 5. Periapical Radiographic Post Obturation

The fourth step was to do crown lengthening on teeth 11, 12, 23 (Figure 6).

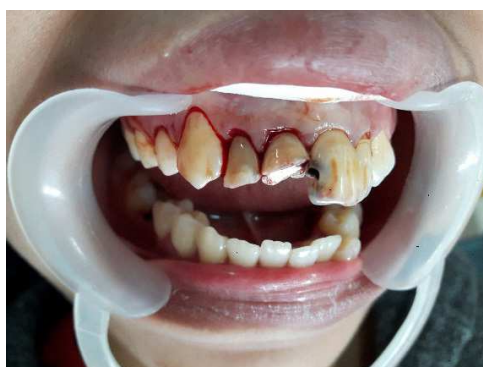

Figure 6. Crown Lengthening

The fifth step was to apply the provisional crowns on teeth 11, 12, 21, 22, 23 (figure 7).

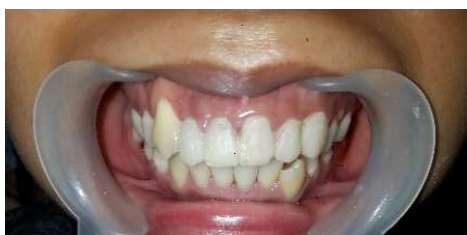

Figure 7. Provisional crowns

The sixth step was decapitation to teeth 12, 11, 21, 22, 23 (figure 8)

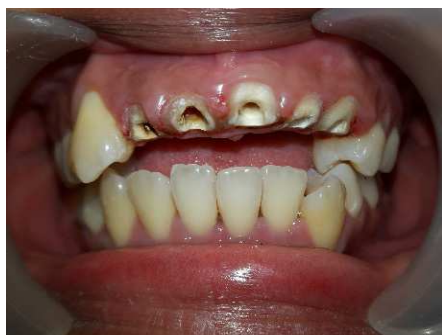

Figure 8. Decapitation Of The Dental Crown

The seventh step was to mount the castings that has been given opaquer on teeth 11, 12, 21, 22, 23 using adhesive resin (figure 9). On teeth 11, 12, 21, 22 and 23, teeth pin crowns were made by reducing the gutta point to two thirds of the root canal space using peeso reamer and crown decapitation then the double impression technique was applied. Bite record and provisional crown application with normal relation were made. The cast posts were inserted to teeth 11, 12, 21, 22 and 23 using type I glass ionomer cement then a crown preparation towards tooth 13 was done.

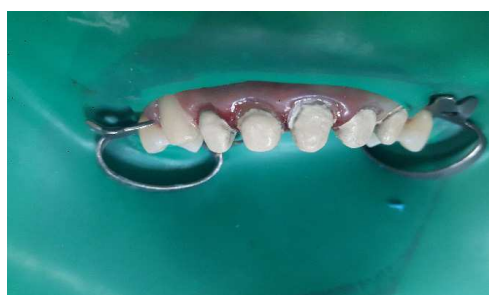

Figure 9. Pin Crown Installation

The eighth step was to cast those teeth crown preparation with double impression material. Before it was casted, a tissue management using hemostat liquefied retraction thread to gingival was applied to obtain a preparation result that is clearly visible on the cast product. The antagonist teeth were casted using alginate materials, bite, and color matched. Then the provisional crown was inserted. Dentin color matching was done after the mounting of casts and preparation of the 13 crown (figure 10).

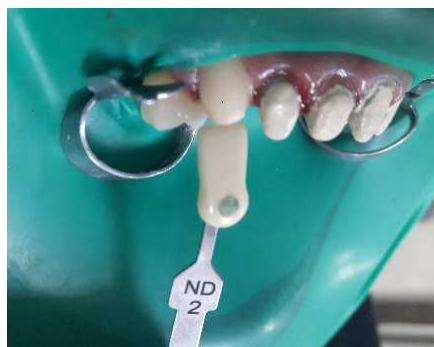

Figure 10. Dentin Color Matching

The ninth step was to try in the Emax full porcelain crown to teeth 11, 12, 13, 21, 22, 23 (figure 11). Emax porcelain crown trial insertion was done after the color and shape has fitted. Contact to antagonist teeth was also confirmed. Emax porcelain

crowns were made on teeth 11, 12, 13, 21, 22 and 23.

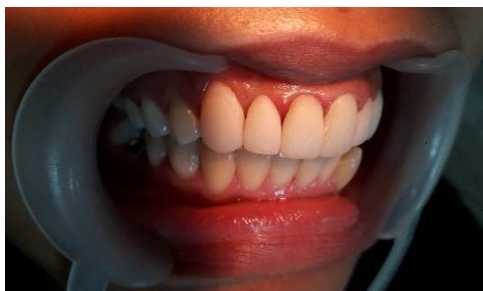

Figure 11. Try in of Emax Porcelain Crown

The tenth step was, on the next visit, if there was no more premature contact, the Emaxporcelain crowns were permanently inserted using resin adhesive cement (Figure 12). Control was done the week after and there was no pain after insertion. Lastly a photograph of the patient smiling was made (figure 12).

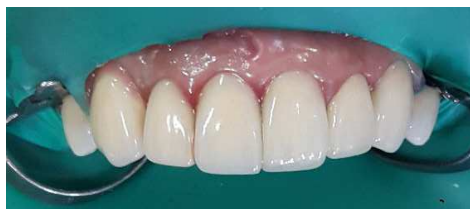

Figure 12. Immediate Post Insertion



Figure 13. The Patient With Her New Smile

On the first control (a week after treatment) there was no pain complaints, a normal color of the gingiva, no swelling, good radiographic photo showed no periapical anomaly. On the second control (six months after insertion) there was no lamentation on anamnesis, on intraoral percussion and pressure examination, and the gingival mucosa was normal.

DISCUSSION

To correct teeth malposition by minimum modification, dental conservation also has an important role i.e. by complex aesthetic treatment. Complex aesthetic treatment is a dental treatment by improving the shape, position and inclination which covers several teeth for better and natural contour, shape and teeth surface texture.

In this case the patient had no self confidence when she smiled therefore an aesthetic treatment was needed to improve the shape and position of her carious anterior teeth with malposition. Prior to treatment, the dentist explained about the therapy using a study model and panoramic photo, since communication and cooperation between patient and dentist are important keys to achieve a successful treatment.

Gingival margin retraction was needed while doing tooth preparation to cover the ceramic-to-teeth transition for a good aesthetic restoration, to get an entrance and to avoid soft tissue damage during the preparation procedure. Gingival retraction prior to casting was done to retract the

gingiva and facilitate the double impression materials to enter into the gingival and cast the marginal part accurately. The gingival retraction material used was a yellow color alum cord to facilitate the identification. The alum functioned as stiptic, obstructed local bleeding and at the same time compressed the gingival edge.

The Emax porcelain crown fitted to the surrounding teeth in perception of color, dimension, shape, arch position, age and sex to get natural and artistic appearance.

The treatment was applied in order to get the normal shape of teeth 11, 12, 21, 22 and 23, harmonic and fitted to the normal dental arch by endodontic treatment and post and vital crown of teeth 13 with Emax porcelain crown insertion.

CONCLUSION

A right dianosis, procedure and color matching with shade guide. Are important supporting factors to the success of the complex aesthetic treatment. The complex asthetic treatment of multiple caries, fractures and labioversion cases not only could alter a smile to be more aesthetic but could also increase the patient's self confidence.

REFERENCES

1. Fellippe LA, Baratieri LN. Direct resin composite veneer: Masking the dark prepared enamel surface. *J QuintessenceInt* 2000; 31: 557–62.

2. Qualtrough AJE, Burke FJT. A look at dental esthetics. *J QuintessenceInt* 1994; 25(1):7–9.
3. Goldstein RE, Haywood VB. *Esthetics in dentistry*. 2nd ed. London: BC Decker Inc; 2002.p.525–30.
4. Dale BG, Aschheim KW. *Esthetic dentistry a clinical approach to techniques and materials*. Philadelphia: Lea and Febiger; 1993.p.101–12.
5. Roger L. The challenge of esthetic dentistry and elective services. *J Am Dent Assoc* 2005;136:515–6.
6. Mount GJ, Hume WR. *Preservation and restoration of tooth structure*. Mosby International Ltd; 1998. p. 218–23.
7. Baum L, Phillips RW, Lund MR. *Textbook of operative dentistry*. 3rd ed. Philadelphia: WB Saunders Company; 1995. p. 494–514.
8. Soetanto S. Perawatan estetika konservatif untuk menanggulangi cacatfasial gigi. *Maj. Ked. Gigi (Dent J)* 2001; 34(4):756–9.

CASE REPORT

ROOT CANAL TREATMENT IN FIRST LOWER LEFT MOLAR WITH MIDDLE MESIAL AND RADIX ENTOMOLARIS : CASE REPORT

Raymond Kandou*, Nirawati Pribadi**

*Resident, Departement of Conservative Dentistry

** Staff Department of Conservative Dentistry

Faculty of Dental Medicine, Universitas Airlangga Surabaya, Indonesia

ABSTRACT

Background: Root canal treatment aims to eliminate bacteria, infected pulp, necrotic tissues, and debris which located inside the pulp chamber and root canal. **Aims:** To perform root canal treatment on first lower left molar with middle mesial and radix entomolaris case in order to maintain the teeth in the oral cavity for a long period of time. **Case:** A 25 year-old female patient came to RSGMP UNAIR clinic with a complaints of feel pain when chewing food and when being exposed to hot water since a week ago, and the patient wants to save her tooth. After being examined, it shows a negative in cold thermal test, and positive in percussion and palpation test, with mobility of one degree. The Radiographic shows an indication of radiolucent in 1/3 apical of the mesial and distal root. Hence, the patient is **diagnosed** with the presence of pulp necrosis with symptomatic apical periodontitis in tooth 36. **Case management :** Root canal preparation was then performed by crown down technique using manual k file 8 and 10 for scouting, pathfiles for glidepath and shaping with protaper next x1- x2. Then, irrigation is done by using Naocl 5,25%, EDTA 17%, Chlorhexidine 2% and Aquadest, accompanied by the use of endoactivator in the irrigation activation. A calcium hydroxide tooth canal dressing was applied for one week, obturation was then performed using single cone with warm vertical compaction technique, and restoration was done by using prefabricated fibre post placement and porcelain fused to metal crown.

Conclusion: Operator requires the knowledge of the anatomy of the root canal and the experience to perform a proper access opening techniques in order to avoid missed canal in endodontic treatment

Keywords: middle mesial, radix entomolaris, root canal treatment

Correspondence : Raymond Kandou, Resident of Conservative Dentistry, Faculty of Dental Medicine, Airlangga University. Email: raymondkandou@hotmail.com

INTRODUCTION

The final objective of endodontic procedures should be the total obturation of the root canal space. Biologic necessity requires the elimination of the protein degradation products, bacteria and bacterial toxins which produced from necrotic and gangrenous root canals. These can be achieved by thorough mechanical and chemical cleansing of the entire pulp cavity and its complete obturation with an inert filling material and a coronal filling preventing ingress of microorganisms.

However, variation in root and root canal systems anatomy may represent an additional difficulty to the final outcome. Endodontic failure may be associated with persistence of infection because of a missed canal or inefficient elimination of microorganisms and necrotic pulp remnants during chemomechanical instrumentation.

In the permanent dentition, the mandibular first molar has been considered to assume maximum bite force and possess the most important masticatory function. The majority of mandibular first molars are two-rooted with two mesial and one distal canal (Barker et al. 1974, Vertucci 1984). Carabelli was the first to mention the presence of a supernumerary third root as a frequent variation in this tooth group, located either lingually (radix entomolaris) or buccally (radix paramolaris) (Wang et al. 2011).

During the growth of the root, the connective pulp tissue is compressed by the

accumulation of secondary dentin, which would form vertical dentinal partitions inside the root canal activity, thus creating 3 mesial root canals. Some authors support the view that middle mesial canal can be easily located in patients of a younger age group, but progressively decrease its incidence with age (Gulabivala K. et al, 2001). This case report is about a patient who presented with pain and swelling in relation to 36. The initial treatment was started with removal old filling, removal caries, and pre-endodontic therapy (rewalling). Root canal treatment was planned in tooth 36. After all the symptoms disappear, fixed prosthesis was given in.

CASE

A 25 year old female patient reported to the Department Conservative Clinic with a complaints of feel pain when chewing food and when being exposed to hot water in lower left posterior tooth since a week ago, and the patient wants to save her tooth. After being examined, it got a negative in cold thermal test, positive in percussion and palpation test, with mobility of one degree. (figure 1)

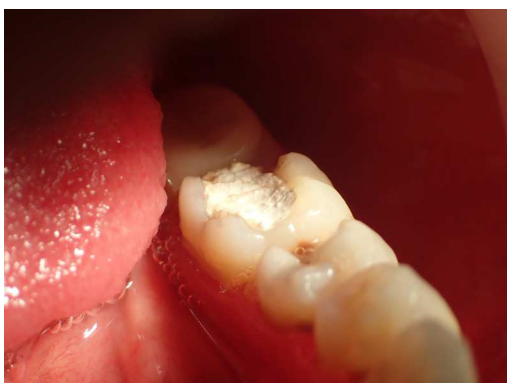

Figure 1. Pre-operative intra oral

In radiograph examination, There is a lesion found in tooth 36, described with radiolucent in 1/3 apical of the mesial and distal root (figure 2)

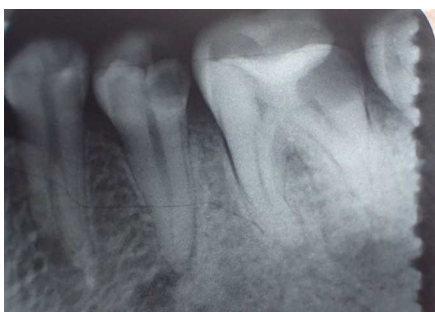

Figure 2. Pre-operative radiography

CASE MANAGEMENT

After going through the explanation of the treatment plan, the patient agreed to do the root canal treatment. The initial treatment was started with removal old filling (figure 3), rewalling (figure 4), and access opening (figure 5), followed by root canal treatment in tooth 36. Access to the pulp chamber was achieved. Working length was estimated by an apex locator (Root ZX: Morita, Japan)

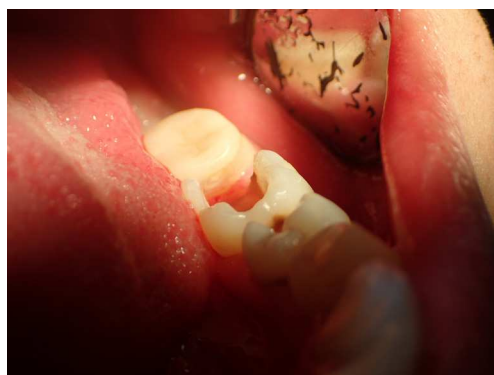

Figure 3. Removal old filling

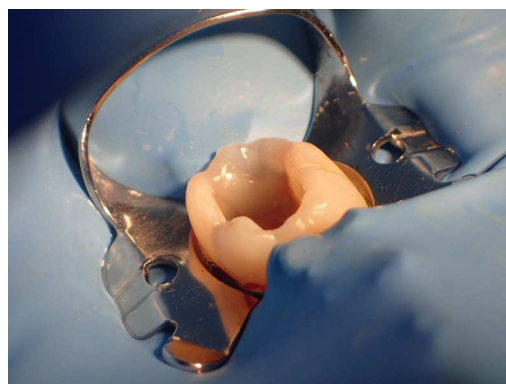


Figure 4. Rewalling

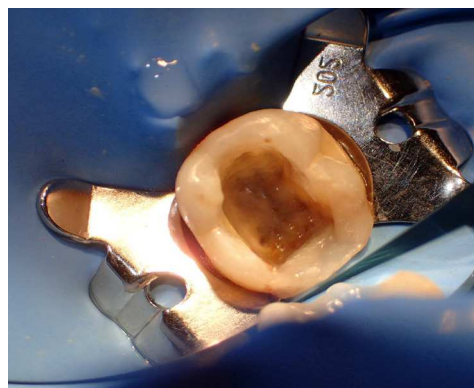


Figure 5. Access opening

Root canal preparation was then performed by crown down technique using manual k file 8 and 10 for scouting, pathfiles for glidepath and shaping with protaper next x1- x2 (figure 6). Then, irrigation

is done by using Naocl 5,25%, EDTA 17%, Chlorhexidine 2% and Aquadest, accompanied by the use of endoactivator in the irrigation activation.

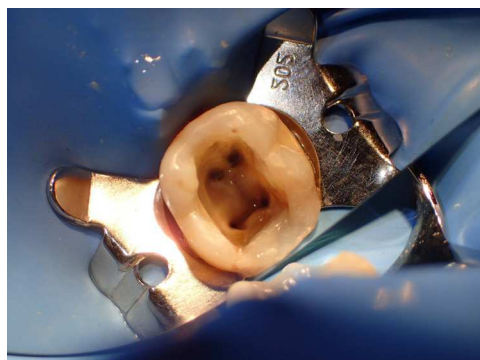

Figure 6. Root canal preparation

After all the main root canals have been prepared, re-examination was done on the mesial aspect, and an additional canal was found in the middle mesial canal (figure 7). It was then shaped using manual k file 8 and 10 for scouting, pathfiles for glidepath and shaping with protaper next x1- x2 (figure 8).

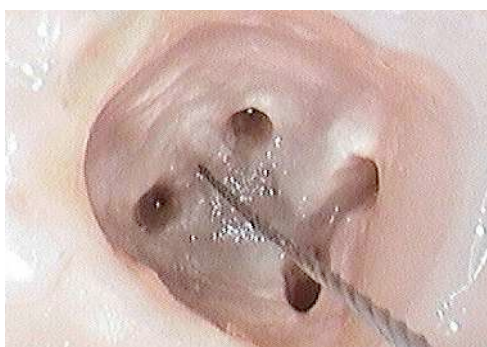

Figure 7. Middle mesial canal

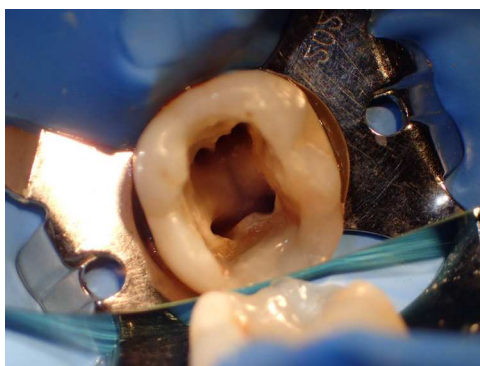


Figure 8. Middle mesial canal shaped

A calcium hydroxide tooth canal dressing was applied for one week (figure 9). One week later patient came with no symptoms. Trial guttup and working length confirmed (figure 10a and 10b), obturation was then performed using single cone with warm vertical compaction technique (figure 11 a and 11 b). Final restoration was done by using prefabricated fibre post placement and fluorocore for core build up (figure 12a and 12b). Fibre post placement confirmed by radiograph (figure 13). Followed by placement of porcelain fused to metal crown (figure 14).

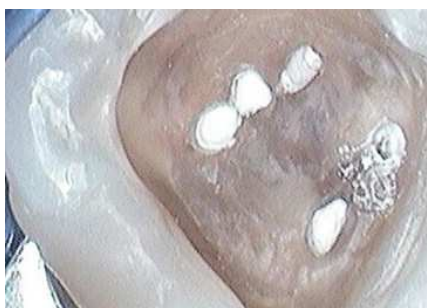

Figure 9. Calcium hydroxide dressing

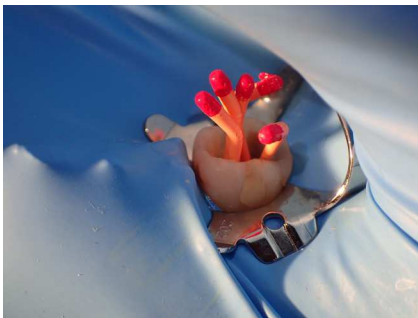


Figure 10 a. Trial gutta percha

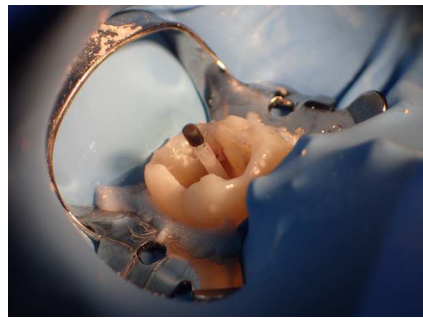


Figure 12 a. fibre post placement

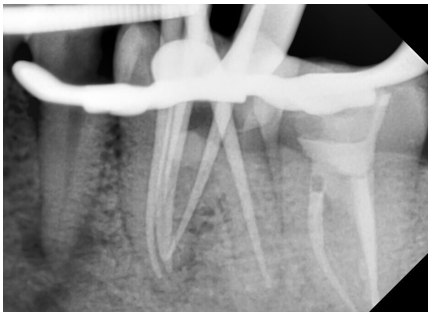

Figure 10 b. Working length confirmation

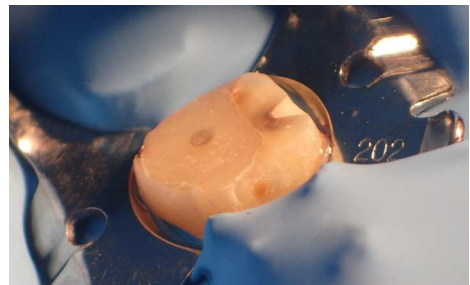


Figure 12 b. Core build up

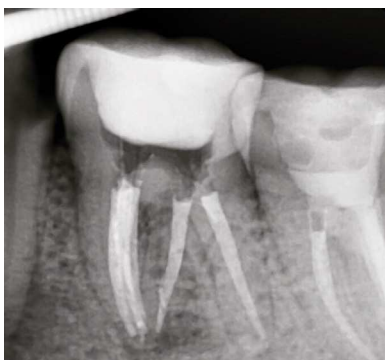

Figure 11 a. Obturation

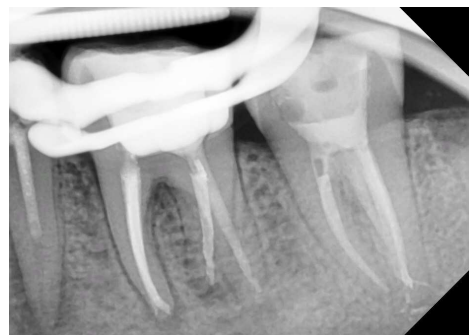

Figure 13. Fibre post in radiograph

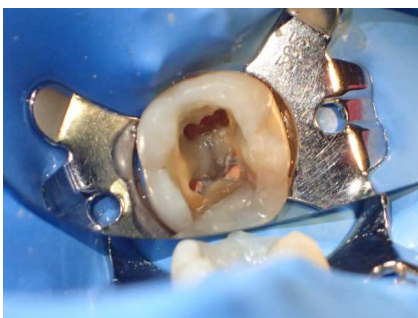

Figure 11 b. Obturation

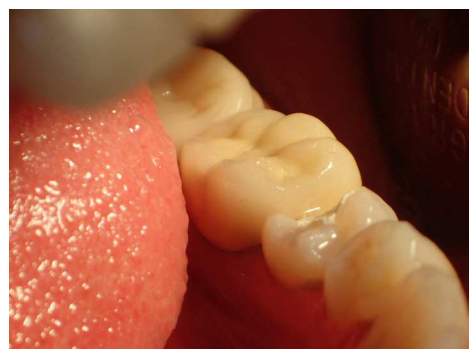


Figure 14. Crown placement

DISCUSSION

The mandibular molars usually have two roots with two canals in mesial roots and one canal in distal root. When an additional mesial canal is present, it is located between the two main canals and its orifice is often hidden by a dentinal projection of the pulp chamber wall. The presence of a third canal (middle mesial) in the mesial root of the mandibular molars has been reported to have an incidence of 0.95%-15%. This additional canal may be independent with a separate foramen, or the additional canal may have a separate foramen and join apically with either the mesiobuccal or mesiolingual canal.

Extra roots as the radix entomolaris in mandibular molars, are an additional challenge, which begins at case assessment and involves all operative stages; that's why an early detection of the presence of any anatomical variations is essential to let the clinician choose the best operative strategy in terms of access cavity design, root canal opening localization, canal shaping, filling and restorative techniques (Cardinali F. et al, 2009). Thus, an awareness and understanding of root canal anatomy is essential to carry out a safe shaping respectful of the original endodontic anatomy for improving the predictability of root canal treatment.

Radiograph is necessary to identified radix entomolaris cases. Periapical preoperative radiograph need to be taken for confirming radix entomolaris cases. But, sometimes single angle of periapical

radiograph is not enough to identified, and different angles need to be taken using SLOB (same lingual opposite buccal) technique. The prevalence of radix entomolaris on mandibular first molar has been reported by many literatures. Wang et al, 2011 reported that it has been found in a population of 95 patients in a total of 350 cases (27,14%) and (60,13%) cases (95 of 158) had the fourth canal arising from radix entomolaris, and the dimension of the radix entomolaris can vary from a short conical extension to a mature root with normal length and root canal, which are curved buccolingually. Basically, there are two classifications on radix entomolaris. One is a classification that has been classified by Ribeiro & Consolaro (1997) based on the curvature of the root, there are 3 types of radix entomolaris according to it's curvature : (1) a straight root / root canal, (2) initially curved entrance of the root canal and the continuation as a straight root or root canals, (3) initial curve in the coronal third of the root canal and a second buccally orientated curve starting from the middle third (the radix entomolaris may also have a pronounced 90 degree buccal curve in the apical part of the root).

Reference

1. De Moor RJ, Deroose CA, Calberson FL. The Radix Entomolaris in Mandibular First Molars: An Endodontic Challenge. International Endodontic Journal; 37 : 789-799, 2004

2. Calberson FL, De Moor RJ, Deroose CA. The Radix Entomolaris and Paramolaris : Clinical Approach in Endodontics. *Journal of Endodontic*; 33: 58-63, 2007
3. Gulabivala K, Aung TH, Alavi A, Ng YL. Root and canal morphology of Burmese mandibular molars. *Int Endod J* 2013; 34: 359-70
4. Wang Q, Yu G, Zhou XD, Peters OA, Zheng QH, Huang DM. Evaluation of X-Ray Projection Angulation for Successful Radix Entomolaris Diagnosis in Mandibular First Molars in Vitro. *Journal of Endodontic*; 37: 1063-1068, 2011
5. Cardinali F, Cerutti F, Cerutti A, Tosco E. Preoperative diagnosis of a third root canal in first and second maxillary premolars: a challenge for the clinician. *ENDO (Lond Engl)* 2009; 3 (1): 51-57

CASE REPORT

ROOT CANAL TREATMENT WITH COMPOSITE RESIN RESTORATION AND POLYETHYLENE FIBER AS REINFORCEMENT IN MANDIBULAR RIGHT SECOND MOLAR TOOTH WITH A SINGLE ROOT CANAL

Reni Nofika*, Tunjung Nugraheni**

*Resident of Conservative Dentistry

**Lecturer of Department of Conservative Dentistry

Department of Conservative Dentistry Faculty of Dental Medicine – Gadjah Mada University Yogyakarta, Indonesia

ABSTRACT

Background: Root canal treatment of necrotic tooth with apical periodontitis aims to clean the root canal of necrotic tissue and return periapical tissue to normal condition. Mandibular second molar teeth with a single root canal can be found in root canal treatment. **Purpose:** This case report aim to demonstrate the success of root canal treatment in mandibular second molars with a single root canal with final restoration using composite resin restoration reinforced with polyethylene fiber. **Case Report:** 31 year old female patient came to seek treatment with a complaint of mandibular right molar that had previously been accessed and restored temporarily, but still painful to chew. Clinical examination showed a large cavity in the dental crown, positive to percussion, and negative to palpation. The radiographic imaging showed the radiopaque area of the dental crown, a single root canal and the widening of the periodontal ligament at the root end of the tooth. **Case Management:** Root canal treatment was performed using conventional technique and obturation with lateral compaction. Three weeks post-root canal treatment the tooth was restored with composite resin with polyethylene fiber as reinforcement. Evaluation at the time of post restoration control showed no complaints of pain and good clinical condition. **Conclusion:** Root canal treatment on mandibular second molar teeth with a single root canal with composite resin restoration and polyethylene fiber as reinforced showed successful result.

Keywords: composite resin, polyethylene fiber, root canal treatment, single root canal.

INTRODUCTION

Bacteria and their products are a major contributing factor to the development of pulp inflammation and apical periodontitis¹. Maximum elimination of bacteria and its products from the root canal (debridement) will affect the success of root canal

treatment². Root canal treatment procedures should pay attention to endodontic triad. In addition to eliminating bacteria, root canal treatment also aims to establish a root canal system and perform adequate root canal obturation which is then followed by coronal restoration¹.

Total debridement can be done after measuring the working length. A good quality preoperative radiograph can be used to determine the working length and can provide information about the shape of teeth and the relationship of teeth with the surrounding structures, the number and length of roots and the root relationship with the crown of the tooth¹. The mandibular second molar with a single root canal is rare. The majority of mandibular second molars have two roots, but teeth with one root (27%) and teeth with three roots (2%) are also found. In single rooted teeth, 53% of the roots are straight, but may also bend distally (26%), to lingual (2%) or have “S” or bayonet shape (19%). The average tooth length in the mandibular second molar is 21.4 mm³.

Elimination of all microorganisms from the root canal system is accomplished by mechanical instrumentation supported by various irrigation solutions and the placement of intracanal medicaments. The use of sonic irrigation devices can activate the irrigation solution inside the root canal, thus greatly contributed to debridement and disinfection of the root canal system. In addition, this irrigation devices can help remove residual of the intracanal medicaments such as calcium hydroxide².

The root canal obturation is a critical stage and may be the cause of treatment failure⁴. The root canal filling must seal the canal space both apically and coronally. The most commonly used material for root canal obturation is gutta-percha combined

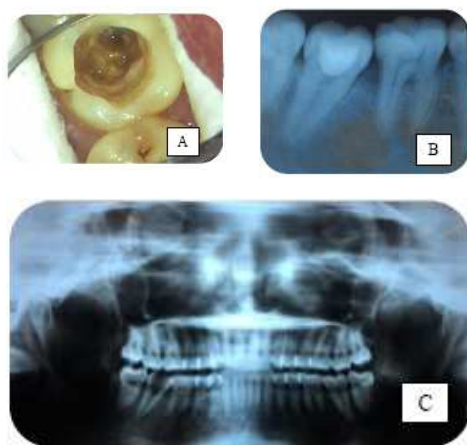
with a sealer⁵. As well as the obturation technique, the use of a sealer is essential to obtain a fluid-tight seal between the dentinal wall and the main obturation material. The use of resin based root canal cement provides adhesion and showed diminished leakage over time, which can be explained by the slow setting properties of this material⁵.

Permanent restoration that is performed immediately in endodontically treated teeth can improve prognosis because it can protect teeth better from possible fractures or crown leakage⁴. Tooth that has undergone endodontic treatment needs to be restored in order to provide a coronal seal (this has a significant effect on the outcome of the endodontic treatment), return the tooth to function and protect the remaining tooth structure from fracture⁶. The use of adhesive restorative techniques do not require the creation of macromechanical retention, there is consequently a reduction in hard tooth structure loss¹.

CASE REPORT

The 31-year-old female patient came to the clinic of conservative dentistry RSGM Prof Soedomo too seek treatment for her mandibular right molar tooth. The tooth cavity were initially small, but not treated. One month ago, patient felt spontaneous pain on her tooth then she came to the dentist's practice. The dentist removed caries of the tooth, then was temporarily restored. One week later the patient came back to the dentist's practice, the tooth was

still in pain, then the dentist removed the temporary restoration, and was temporarily restored. But the pain persisted a few days later. The patient then came to the clinic of conservative dentistry RSGM Prof. Soedomo Faculty of Dentistry, Gadjah Mada University for treatment of these tooth. Clinical examination at the time after removing temporary restoration showed a large cavity in the dental crown, positive to percussion, negative to palpation, and no tooth mobility. The periapical radiograph showed the radiopaque area of the dental crown that filled the pulp chamber, single root canal and the widening of the periodontal ligament at the root end of the tooth. The patient's panoramic radiograph shows the maxillary second molars and the mandibular second molar has a single root canal.

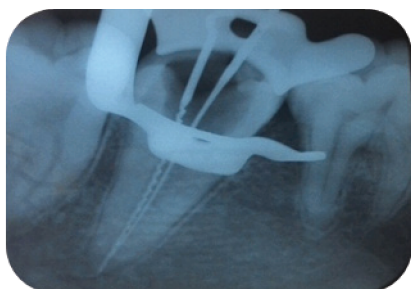


Picture 1. A. Clinical view of tooth 47 before treatment, B. Preoperative radiograph, C. Panoramic radiograph.

Based on clinical and radiographic examination, the dental diagnosis of 47 was deep caries with pulp necrosis with apical periodontitis. The treatment plan was root canal treatment and composite resin restoration with onlay preparation design and polyethylene fiber as reinforcement.

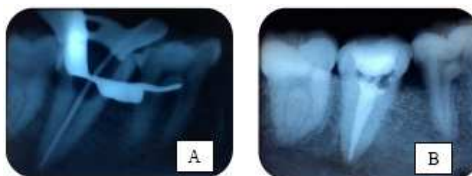
CASE MANAGEMENT

On the first visit, after the tooth was isolated with a rubber dam (Osung), the access cavity was cleaned and irrigated using 2,5% sodium hypochlorite (NaOCl) and saline. Then the exploration of root canal and pulp debridement were carried out, followed by irrigation using 2,5% NaOCl and saline. The working length was determined by using apex locator (Dentaport ZX, Morita) and confirmed by taking a periapical radiograph with two types of file (K-file and Hedstrom file, Dentsply Maillefer, Switzerland) that had been inserted into the root canal at once to confirm the number of root canals. The working length was 23 mm. Root canal preparation was performed by conventional technique, with irrigation of each file using 2,5% NaOCl and saline. After preparation was complete, the root canal was irrigated with 2,5% NaOCl, saline, and EDTA 17% (Smear Clear, SybronEndo) solution. The root canal was dried and calcium hydroxide was used as an intracanal medicament. The cavity was temporarily restored with zinc oxide based material (Cavition, GC).



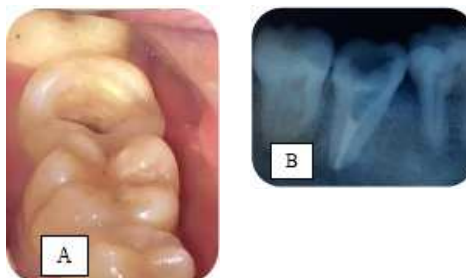Picture 2. Measurement of working length.

On the second visit there was no complaint of pain. On clinical examination the temporary restoration was still intact, negative to percussion, negative to palpation, and no tooth mobility. The tooth was isolated using a rubber dam, temporary restoration was removed and then followed by repeated irrigation using 2,5% NaOCl to remove and clear the calcium hydroxide contained in the root canal. Endoactivator (Dentsply, Maillefer) was also used to help remove residual calcium hydroxide. Apical cone master was confirmed with a periapical radiograph. The root canal was irrigated with 2,5% NaOCl and saline, then flooded with 2% chlorhexidine digluconate (Cavity cleanser, Bisco) for 30 seconds and finally irrigated with a 17% EDTA solution that was activated with endoactivator. The root canal was obturated using lateral condensation technique with resin sealer (TopSeal, Dentsply), followed by the application of phosphoric cement as a base and temporary restoration with zinc oxide. Obturation result was confirmed using a periapical radiograph.



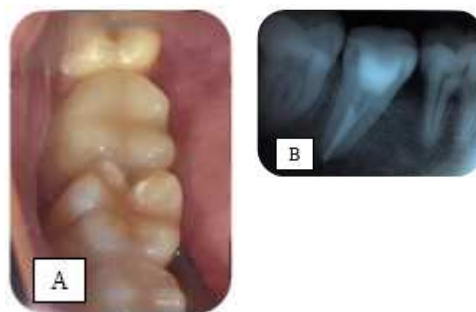
Picture 3. A. Master cone gutta-percha, B. Obturation of root canal.

Evaluation was performed at the third visit. Patient had no complaints of pain. On the clinical examination temporary restoration was still intact, negative to percussion, negative to palpation, and no tooth mobility. Periapical radiograph showed that the root canal had been obturated and there were no periapical abnormalities. Temporary restoration was removed, followed by crown preparation. Gutta percha was reduced up to 5 mm from the orifice using gates glidden drill (Dentsply, Maillefer), peeso reamer (Dentsply, Maillefer), and hedstrom file (Dentsply, Maillefer) for the placement of polyethylene fiber (Construct, Kerr). Removal of gutta percha was confirmed by taking periapical radiograph.



Picture 4. A. Clinical view of crown preparation, B. Removing gutta-perca until 5 mm under orifice.

The root canal was irrigated and dried by paper point. The enamel and dentin surfaces as well as the cavities in the crown were etched with 37% phosphoric acid (DenFil Etchant-37) and then continued with bonding application (STAE, SDI). The packable composite resin (Filtek™ P60 A3 color, 3M ESPE) was applied to the buccal and lingual surfaces. Cement resin (Rely X U200, 3M ESPE) was prepared, then inserted into the root canal using lentulo (Dentsply, Maillefer). Polyethylene fibers with length of 15 mm that had been folded into two were inserted into the root canal using a hand plugger instrument then pressed towards the buccal and lingual surfaces of the crown and light-cured for 20 seconds. The packable composite resin was applied incrementally to the crown cavity. All cusps and fissures were formed according to the anatomy of the teeth. Once the composite resin application was completed, an occlusion and articulation was checked, then the restoration was smoothed and polished. The periapical radiograph was taken after insertion of polyethylene fiber and composite resin restoration. One week later the patient came for evaluation. The patient had no complaints of pain and there was no abnormality in the clinical examination. Patient was educated to always maintain oral hygiene and routine control to the dentist.



Picture 5. A. Clinical view after composite resin restoration, B. Radiograph after application polyethylene fiber and composite resin.

DISCUSSION

The main aim of root canal treatment are to eliminate the major bacteria that cause the development of pulp inflammation and apical periodontitis. This aim is included in the endodontic triad consisting of shaping canals, cleaning in three dimensions, and filling root canal system^{1,7}. Maximum elimination of existing bacteria in the root canal can only be done after the working length is determined, then continued with the cleaning and shaping of the root canal. Some techniques that can be used to determine the working length are radiograph, electronic, and tactile methods⁴. In this case the determination of the working length using electronic apex locator (Dentaport ZX, Morita) is then confirmed by radiograph. A good quality radiograph can be used to determine the working length and can provide information about the shape of teeth and the relationship of teeth with the surrounding structure, the number and length of the root and the root

relationship with the crown. Periapical radiograph is the most commonly used during root canal treatment¹.

In this case the mandibular second molar has one root with one large root canal in the middle of the root. This case is rarely found. The mandibular second molar can have two roots or one root. The mandibular second molar with two roots is most commonly found, having mesial roots and distal roots. Each root most often has one root canal but it can also be with two canal that are attached or separated at the apex end. The mandibular second molar also may have only a single root with several variants: one single, large canal; two canals that merge or remain separate; or the so-called C-shaped tooth⁸.

The principle of root canal preparation should be followed so that the root canal is clean and well-formed making it easy to fill the root canal. The principles of root canal preparation consist of outline form, convenience form, toilet of the cavity, retention form and resistance form. The outline form starts from the enamel's edge to the resistance form on the apical foramen. Resistance form is apical stop on cemento-dentinal junction so that will produce solid obturation and restrain the extrusion of debris from root canal and root canal obturation material. Toilet of the cavity is by doing adequate irrigation. The retention form is intended to allow the apical portion of the master cone to fit the root canal shape at 2 to 3 mm from the apical foramen⁹.

The primary objectives in cleaning and shaping the root canal system are to remove infected soft and hard tissue, give disinfecting irrigants access to the apical canal space, create space for delivery of medicaments and subsequent obturation, and retain the integrity of radicular structure¹⁰. During and after cleaning and shaping, the root canal should be irrigated to remove remaining pulp tissue and dentine debris³. In this case the root canal is irrigated using 2,5% NaOCl, EDTA, chlorhexidine, and saline. NaOCl is the main endodontic irrigant used, due to its antibacterial properties and its ability to dissolve organic tissue¹¹. The effective concentration of sodium hypochlorite used as an organic tissue solvent is 2.6% to 5.2%. The destruction of bacteria by sodium hypochlorite occurs in two phases: penetration into bacterial cells and chemical combinations with protoplasmic bacterial cells that destroy them³.

The use of NaOCl alternately with EDTA has the potential as the best cleaning agent to reduce organic debris and smear layer⁴. Smear layer is a combination of dentine, pulpal, and bacterial debris³. Removal of smear layer can reduce microleakage and improve the fluid-tight seal of filled root canal.⁵ EDTA solution serves to form a calcium-chelate solution with calcium dentine ions, so dentine becomes more easily destroyed and more easily instrumented³. A final flush with 2% chlorhexidine after sodium hypochlorite and EDTA has proposed to ensure good

results in cases of persistent infection, due to its broad spectrum of action and its property of substantivity. However, chlorhexidine is hindered by its interaction with NaOCl, which tends to create products that may discolor the tooth and precipitates that may be potentially mutagenic. This interaction has been prevented or minimized by an intermediate wash with saline or distilled water¹¹.

In multi-visit root canal treatment is required intracanal medicament³. Calcium hydroxide is recommended as an intracanal medicament because of its proven antimicrobial activity, for its capacity to neutralize bacterial endotoxin and stimulate apical and periapical repair^{2,9}. Calcium hydroxide can be used as an intracanal medicament in cases of pulp necrosis with apical periodontitis¹. Calcium hydroxide should be removed before the obturation of root canal because the remnants of calcium hydroxide on the canal walls influence dentine bond strength of sealer and negatively affect the quality of root canal filling. It is difficult to remove calcium hydroxide residues from irregularities of the root canal walls. NaOCl irrigation solutions is commonly used for the removal of residual calcium hydroxide. In addition, the use of sonic irrigation devices such as endoactivator can help remove residual calcium hydroxide. Endoactivator system was designed to safely agitate the irrigants to the apical terminus of root canals. Endoactivator performed better result in removing calcium hydroxide from apical

third when compared with 30 gauge blunt ended side vented needle. Fluid activation in well-shaped canals plays an important role in debridement and disinfection of the root canal system².

The root canal filling is a critical stage and may be the cause of treatment failure⁴. According to a study by Ingle and Beveridge, 58% of root canal treatment failures are associated with incomplete root canal filling³. The root canal filling must seal the canal space both apically and coronally. The most commonly used material for root canal obturation is gutta-percha combined with a sealer⁵. Gutta-percha is a solid material and is considered an impermeable core material but does not bond to the root dentin walls^{4,5,12}. The primary ingredient of a gutta-percha cone is zinc oxide (\pm 75 percent). Gutta-percha accounts for approximately 20% and gives the cone its unique properties such as plasticity. The remaining ingredients are binders, opaquers, and coloring agents⁴. Gutta percha is sterilized in sodium hypochlorite solution for 1 min before use⁹. As well as the obturation technique, the use of a sealer is essential to obtain a fluid-tight seal between the dentinal wall and the core obturation material⁵. This case using gutta-percha as the main obturation material and resin-based cement (TopSeal, Dentsply). Resin sealer provides adhesion and showed diminished leakage over time, which can be explained by the slow setting properties of this material⁵.

One of the methods used for root canal filling is lateral compaction³. Lateral compaction can be done on condition that the canal shape is continuous taper after preparation, the spreader can enter 1 to 2 mm of working length, have apical stop and the additional gutta percha diameter should be smaller of the spreader used. Weine has shown that lateral compaction that done correctly provides an optimum obturation of root canal⁹.

Permanent restoration performed immediately in endodontically treated teeth can improve prognosis because it can protect teeth better from possible fractures or crown leakage⁴. Tooth that has undergone endodontic treatment needs to be restored in order to provide a coronal seal (this has a significant effect on the outcome of the endodontic treatment), return the tooth to function and protect the remaining tooth from fracture. In most instances, teeth that have undergone endodontic treatment will be doubly weakened. By the very nature of factors resulting in loss of vitality, the majority of endodontically treated teeth will already have suffered from a significant loss of the tooth structure as a result of the cumulative ravages of caries and previous restoration. To enable endodontic access these already weakened teeth then a significant further amount of tooth structure has to be removed. In addition, it has been suggested that endodontically treated teeth are more brittle. When restoring endodontically treated posterior teeth, consideration need

to be given to the high risk of cuspal fracture⁶. Endodontic treatment associated with the use of intracanal retainers is necessary before building up the coronal restoration. After placement of these intracanal retainers, the remaining coronal tooth structure can be restored with direct or indirect techniques¹³. There have been many recent advances in the methods available for restoring endodontically treated teeth. Most are related to adhesive techniques and as result, composite resin/ceramic materials and non-metallic posts have become popular. Since adhesive restorative techniques do not require the creation of macromechanical retention, there is consequently a reduction in hard tooth structure loss¹. In this case the tooth is restored with direct technique using composite resin and polyethylene fiber as reinforcement (intracanal retainer). The use of fiber in composite resin resulted in an increase in strength of restoration and produce a good esthetics. Polyethylene fibers improve the impact strength, modulus of elasticity, and flexural strength of composite materials. Polyethylene fiber appear to have best properties in elasticity, translucency, adaptability, tenaciousness, resistance to traction and impact¹³.

Insertion of polyethylene fiber into the root canal used resin cement. Resin cements are based on bisphenol-a-glycidyl methacrylate (Bis-GMA) resin and other methacrylates, which are modified from the composite resin (restorative material). This cements has a setting reaction based

on polymerization. Resin cements have the advantage of high compressive/tensile/bonding strength, low solubility, and esthetics. In this case Rely X U200 (3M ESPE) was used, which is a dual cured resin cement. The bonding mechanism of this cement is self-adhesive (does not require surface pre-treatment and bonding agent to maximize their performance), therefore the technique sensitivity of this cement has been greatly reduced compared to the conventional resin cement¹⁴.

CONCLUSION

The mandibular second molar having one root with one root canal are very rare. Good quality radiograph can help show the number of root canal in the tooth. Proper root canal treatment procedures that are immediately followed by the making of permanent restorations are important factors for successful treatment. Adhesive restorations on endodontically treated teeth can reduce loss of the hard tooth structure.

REFERENCES

1. Chong BS,. Harty's endodontics in clinical practice. 6th ed. Edinburg, London, New York, Oxford: Churchill Livingstone Elsevier; 2010. P. 269-270.
2. Dabhi M, Kishan KV, Vaishali V, Vishnu R,. Comparative Evaluation of 3 Different Irrigation System: 30 Gauge Blunt Ended Side Vented Needle, Endoactivator & Endovac In Removal of Ca(OH)₂ from Root Canal System-sem Study. Journal of Dental and Medical Science. 2016; 15; 3: 84-89.
3. Grossman LI, Oliet S, Rio CED,. Endodontic Practice. Philadelphia: USA; 1995. . P. 188-189, 206, 208, 244, 248, 266.
4. Torabinejad M, Walton, RE,. Endodontics Principles and Practice. 4th ed. St. Louis: Sauders; 2009. P. 91-92, 256, 276-278, 296, 306-307, 312-313, 317, 343.
5. Ferreira MM, Abrantes M, Ferreira H, Carrilho EV, Botelho MF,. Comparison of the apical seal on filled root canals with Topseal vs MTA Fillapex sealers: A quantitative scintigraphic analysis. Journal of Stomatology. 2013; 3: 128-132
6. Qualtrough AJE, Satterthwaite JD, Morrow LA, Brunton PA,. Principles of Operative Dentistry. Australia: Blackwell Munksgaard; 2005. P. 93.
7. Khademi JA, Trudeau M, Narayana P, Raby RM, Baerg SD,. Image-Guided Endodontics: The Role of the Endodontic Triad. Dental ce today. 2016; 35; 8: 1-6.
8. Weine FS,. Endodontic Therapy. 6th ed. St. Louis: Mosby; 2004. P. 107, 151.
9. Ingle JJ, Bakland LK,. Endodontics. 5th ed. London: BC Decker Inc; 2002. P. 530, 558, 577, 612.
10. Hargreaves KM, Berman LH,. Cohen's Pathways of the Pulp. 11th

- ed. St. Louis: Elsevier; 2016. P. 137, 210, 249.
11. Plotino G, Cortese T, Grande NM, Leonardi DP, Giorgio GD, Testarelli L, Gambarini G,. New Technologies to Improve Root Canal Disinfection. Brazilian Dental Journal. 2016; 27; 1: 3-8.
 12. Rashmi NC, Basavanna RS, Gupta D,. Influence of a Resin Based Root Canal Filling Material on Resistance to Fracture of Endodontically Treated Teeth: An in-vitro Study. OHDM. 2014; 13; 4: 1013-1016.
 13. Sholapurmath SM, Anand S,. Use of polyethylene fiber in pediatric esthetics-clinical reports of two cases. J. Int Oral Health. 2010; 2; 2: 99-104.
 14. Yu H, Zheng M, Chen R, Cheng H,. Proper Selection of Contemporary Dental Cement. OHDM. 2014; 13; 1: 54-58.

CASE REPORT

THE CONSERVATIVE MANAGEMENT OF EXTERNAL ROOT RESORPTION OF PERMANENT INCISIVE CENTRAL CAUSED BY A TRAUMA : A CASE REPORT

Ruth Sarah Wibisono¹, Tamara Yuanita²

¹Resident, Departement of Conservative Dentistry

² Staff Department of Conservative Dentistry

Faculty of Dental Medicine, Universitas Airlangga Surabaya, Indonesia

ABSTRACT

Background: External tooth resorption usually follows trauma to the periodontal ligament. It is a lytic process occurring in the cementum or cementum and dentin of the roots of teeth. Resorption of cementum is regulated by mechanisms similar to those controlling osteoclastogenesis and bone resorption. **Case:** A 20 year-old male patient reported to departement of endodontic, with the chief complaint of pain in his upper right central incisor. Twelve years ago he got an accident and his upper right central incisor got broken. His gum was often swollen but he never took any medicine. On clinical examination of tooth 11, it was found that his tooth was perforated, tender to vertical percussion and no tooth mobility was seen. The Intraoral periapical radiographic examination of tooth 11 revealed root resorption on the root, associated with periapical radiolucency and some bone loss. **Case Management:** Canal was cleaned and shaped with a brushing movement technique. Then Calcium hydroxide as an intracanal medicament was placed in canal for 2 weeks. The canal was next obturated with MTA on the apical third. After 1 day, the canal was filled using injection termoplastis technique. The tooth was finally restored with fiber post and porcelain fused to metal crown. **Conclusion:** The use of biomaterials, such as MTA in teeth with perforating external root resorption gave optimal results.

Keyword: External Root Resorption, Mineral Trioxide Aggregate, Apexification.

Correspondence: Ruth Sarah Wibisono, Resident of Conservative Dentistry, Faculty of Dental Medicine, Airlangga University. Email: Ruth_sarah@gmail.com

INTRODUCTION

Etiology of different types of root resorption requires two phases: mechanical or chemical injury to the protective tissue and stimulation by infection or pressure. Injury can be similar in various types of root resorption. The selection

of proper treatment is related to the stimulation factors. Intrapulpal infection is the stimulation factor in internal root resorption and external root periradicular inflammatory root resorption. Therefore, various types of root resorption can be classified according to the stimulation

factors: pulpal infection, periodontal infection resorption, orthodontic pressure resorption, impacted tooth or tumor pressure resorption and ankylotic resorption.

The most common stimulation factor for root resorption is pulpal infection. Following injury to precementum or pre dentin, infected dentinal tubules may stimulate the inflammatory process with osteoclastic activity in periradicular tissues or in pulpal tissues, consequently initiating external or internal root resorption. Clinically, teeth are usually not symptomatic in early period of the process, the resorption may be seen at this stage only in radiographs. However, as the process progresses, the teeth may become symptomatic and periradicular abscesses may develop with increasing tooth mobility. Radiographically, radiolucency is observed in the external tooth surface of dentin and adjacent bone.

External root resorption occurs on the outer surface of the root and the causes for this may vary. MTA is most commonly used in these cases because of its sealing ability, biocompatibility and potential induction of osteogenesis and cementogenesis.

The major challenges associated with endodontic treatment of teeth with open apices due to resorption are achieving complete debridement, canal disinfection, and optimal sealing. One of the aims of endodontic treatment is to form an apical barrier or a stop against which one can place canal filling material avoiding over extrusion.

Recently mineral trioxide aggregate (MTA) has emerged as a reliable material due to its biocompatibility, good sealing property, and it encourages regeneration of peri-radicular tissues such as periodontal ligament bone and cementum. MTA renders favorable properties for the management of tissues damage caused by ERR.

The present case report describes the advanced ERR in the permanent incisive central which is treated with MTA obturation.

CASE

A 20 year-old male patient reported to departement of endodontic, with the chief complaint of pain in his upper right central incisor. Twelve years ago he got an accident and his upper right central incisor got broken. His gum was often swollen but he never took any medicine. On clinical examination of tooth 11, it was found that his tooth was perforated, tender to vertical percussion and no tooth mobility was seen. The Intraoral periapical radiographic examination of tooth 11 revealed root resorption on the root, associated with periapical radiolucency and some bone loss

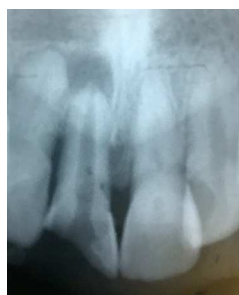

Figure 1: initial x-ray showing ball shaped external root resorption with periapical radiolucent lesion.

CASE MANAGEMENT

Under rubber dam isolation access opening in tooth #11 was done and single root canal was found. Working length was measured with apex locator (Morita,Kyoto,Japan) and confirmed with periapical x-ray (Figure 2). Canal was cleaned and shaped with reciproc 40 (VDW, Germany) with brushing movement technique, irrigation with sodium hypochlorite 2,5%, and followed by normal saline solution and EDTA 17% as final irrigation. Using EndoActivator System (Dentstply Tulsa Dental Specialties, Tulsa,OK) to activate the irrigant. Canal was dried with absorbents points and calcium hydroxide as an intracanal medicament placed in canal and then followed by a temporary filling for 2 weeks.

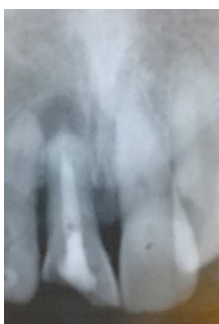

Figure 2: x-ray shows obturation with calcium

After the 1 week temporary filling was removed, the root canal was cleaned and dried. MTA was manipulated according to the manufacture instructions. The canal was obturated with MTA on the apical third, the material was placed in the canal with microaplicator and vertically condensed with hand plugger. Finally it

was covered with moist cotton pellet and followed by temporary filling with cavite (3M ESPE, St. Paul, MN, USA). After 1 day, the temporary filling was removed, the canal was filled using injection termoplastis technique (Beefill, Dentsply, Germany) and resin sealer (AH plus, Dentsply, Germany) from orifice up to middle third of apical. The endodontic treatment was done and recalled after seven days for restoration procedure.

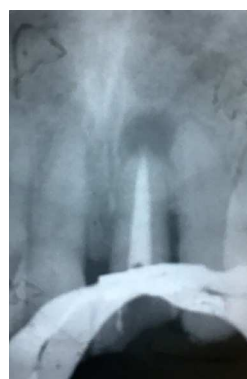

Figure 3. x-ray shows obturation with MTA and injection termoplastis.

After the 1 week temporary filling was removed, the canal was prepared for fiber post insertion. Porcelain fused to metal is used as the final restoration.

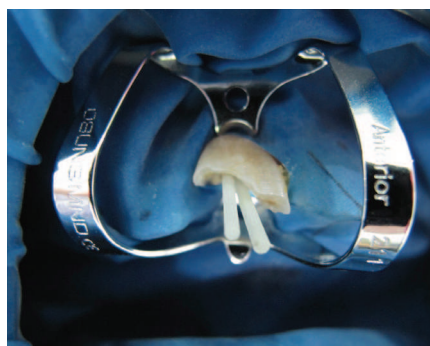

Figure 5. The canal was prepared for fiber post insertion

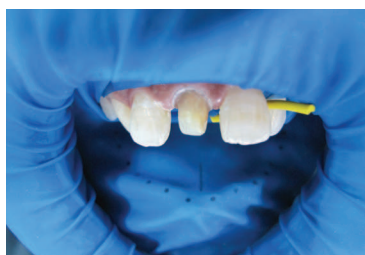

Figure 6. After preparation for crown

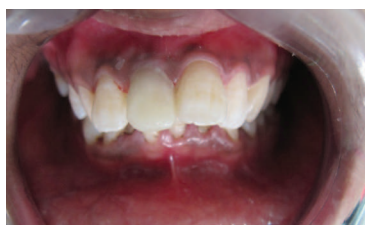

Figure 7. After insertion of crown
porcelain fused to metal.

After 3 month later the patient was recalled for follow-up. At the clinical examination the tooth was asymptomatic and the radiographic examination showed periapical tissue healing.

DISCUSSION

External root resorption is one of the most difficult dental treatment case. The Goal of apexification is to obtain an apical barrier to prevent the passage of toxins and bacteria into periapical tissues from root canal. Root canal treatment is required for external root resorption treatment. A pulpectomy will remove the granulation tissue and blood supply of these cells. For this reason, a pulpectomy alone is predictable treatment form in this type of resorption. For external resorption, it is critical to control the pulpal bacteria that act as a stimulation removed from the dentinal tubules can predictably arrest this

type of root resorption. In this case, canal was cleaned and shaped with reciproc 40 VDW with brushing movement technique because of the size of the canal which is bigger than the normal canal size.^{1,2}

Calcium hydroxide is the intracanal medicament of choice for treatment of external pulpal infection. Its strong antibacterial effect and low solubility create a long term effect in the root canal and remove the stimulation factor from the main canal. CH also increases the pH of dentin (8,0-10,0) and therefore inhibits the activity of osteoclastic acid hydrolases in periodontal tissues and activates alkaline phosphatases.^{2,6}

MTA is a bioactive material that mainly composed are tricalcium and silicate. Investigation has shown that MTA can conduct and induct hard tissue formation. MTA surfaces supports osteoblast cell attachment that is essential for osteogenesis, and MTA does not has a negative effect on the viability and morphology of cementoblasts and induced biomineralization of cementoblasts.² Antibacterial / antimicrobial activity of MTA seems to be associated with elevated pH. It was observed that an initial pH of 10.2 for MTA rising to 12.5 in 3 hours, it is known that pH level in order of 12.0 can inhibit most microorganisms including resistant bacteria such as *Enterococcus faecalis*. MTA was successfully used as a barrier between the root canal space and the periodontal tissue in cases of root perforation.^{4,5}

After the canal is filled with MTA in the apical third, the injection termoplastis technique is used to fill the canal using (Beefill, dentsply) from orifice up to middle third of apical. The use of System B HeatSource® offers a modification of the warm gutta-percha with the continuous wave condensation technique. The main advantage of this technique is that the gutta-percha canal filling can be performed through a continuous movement, with a plugger, electrically heated at the temperature recommended by the manufacturer (200 °C) therefore, allowing accessory canal filling^{7,8}

CONCLUSION

The use of biomaterials, such as MTA in teeth with perforating external root resorption gave optimal results

REFERENCES

1. Anantharaj A, Praveen P, Venkataraghavan K, Prathibha RS, Sudhir R, Murali Krishnan B. Challenges in pulpal treatment of young permanent teeth a review. J Dent Scien Res. 2011;2:142.
2. TS. Ashwini., Namrata. H., Chetan. R. P., Viraj.S.Y. Role of Mineral Trioxide Aggregate In Management of External Root Resorption. J Conserv Dent. 2013 Nov-Dec; 16(6): 579-581.
3. Raut AW, Mantri VR, Palekar AU, Kamat S. Single Step Apexification with Mineral Trioxide Aggregate (MTA)-Case Reports. NJDSR. 2012;1:28–2.
4. Maria F, Ida DA, Rahul W. Tooth Resorption Part I – Pathogenesis and Case Series of Internal Resorption. J Conserv Dent. 2013 Jan- Feb; 16(1): 4-8.
5. Patel S, Kanagasingam S, Pitt Ford T. External cervical resorption: A review. J Endod. 2009;35:616–25
6. Kaiwar A, Ranjini MA, Ashwini P, Pasha MF, Meena N. Internal resorption managed by root canal treatment: Incorporation of CT with 3D reconstruction in diagnosis and monitoring of the disease. J Int Oral Health. 2010;2:86–94.
7. Shikha D, Mukunda KS, Arun A, Rao SM. Apexification: A review. J Dent Sci Res. 2012;3:41–4.
8. Roger C ,Leopoldo F, Ma Carmen L. Microscopic Assessment of The Sealing Ability of of Three Endodontic Filling Techniques.2016; J Clin Exp Dent; 8(1); e27-e31.

ROOT CANAL RETREATMENT OF PERIAPICAL ABSCESS ON MAXILLARY LATERAL INCISOR

Sasi Suci Ramadhani¹, Ratna Meidyawati²

¹Post Graduate Student, Department of Conservative Dentistry,
Faculty of Dentistry Indonesia University

²Lecturer, Department of Conservative Dentistry,
Faculty of Dentistry Indonesia University

ABSTRACT

Failure in root canal treatment is caused by cleansing, forming, inadequate obturation and iatrogenic factor. The main causes of root canal failure are the presence of bacterial colonies in the apical portion of the root canal. Bacteria and its product will continue to develop in the root canal to the space of the periodontal ligament, thus stimulating the body defense mechanism resulting in periapical tissue damage. The purpose of this case report is to present a clinical case of endodontic retreatment of periapical abscess of the maxillary lateral incisor.

An 18-years old man was referred for root canal treatment of maxillary lateral incisor to the Department of Conservative Dentistry. He felt discomfort on his anterior upper left tooth and swelling on his palate for 3 days. The tooth was once treated root canal by the former dentist a year earlier. A clinical examination showed a composite restoration on tooth #22, sensitive to percussion and not sensitive to palpation, sinus tract on palatal side. A pre-operative radiograph revealed underfilled obturation and defused radiolucency with the diameter of 10 mm. Considering the clinical and radiograph findings, the diagnosis was chronic apical abscess et causa inadequate root canal treatment. Therefore root canal retreatment was decided to be performed.

Keywords : root canal retreatment, periapical abscess, healing process

Introduction

Teeth that have been treated for root canals and obturated can be reinfected. The main cause of root canal failure is the presence of bacterial colonies in the apical portion of the root canal. The most commonly found bacteria persisting in the treated root canal or in the persistent

infection is *E. faecalis*.^{1,2} This bacteria has a unique ability to infiltrate the dentinal tubules, resistant to extreme conditions (high pH) and limited nutrition.^{1,2}

The apical foramen which became the bacterial exit and its by-product from root canal to the periodontal space, this process can infiltrate microbial aggregation

and its products in the periradicular tissue and stimulate the body defense system to produce periapical or periradicular tissue damage.³ The main purpose of re-treatment is to remove material from the root canal and repair tissue damage caused by pathological or iatrogenic conditions.³

Antimicrobial irrigation is used during root canal preparation and its aims to reduce bacterial populations effectively, although some bacteria still survive in lateral and accessory canals. Chlorhexidine is used as additional irrigation for root canal retreatment. Chlorhexidine is a positive charge hydrophobic and lipophilic molecule that can interact with phospholipids and lipopolysaccharides in bacterial cell membranes and can enter into bacterial cells through active and passive transport mechanisms.^{6,7}

Intracanal medication placement between visits can eliminate the remaining microorganism and can support the results of the treatment. Calcium hydroxide is selected as a root canal medication in the persistent periapical disease, it can be used to control exudate to allow for healing and calcification processes.⁹

Case

Eighteen years old male patient came to the conservation clinic with an anterior maxillary left tooth complaint, he felt uncomfortable and swelled on his gum about three days ago, the tooth was once root canal treated a year ago. Patients have experienced pain in the tooth and take

antibiotics and pain relievers. Currently, the patient has no pain and the fistula has gone. The patient claimed no history of a systemic disease and currently have orthodontic treatment.

Clinical examination saw on the palatal part of the tooth 22 there is a composite crater (figure 1a). Vitality test is not sensitive, sensitive to percussion, and palpation is not sensitive. There is a fistula on the palatal portion of tooth 22 (figure 1b). The radiographic examination of the tooth 22 (figure 1c) shows an inadequate root canal filling, widened periodontal ligaments, lost of lamina dura and radiolucent features around the apical tooth 22 with an unclear boundary and a diameter of approximately 10 mm.

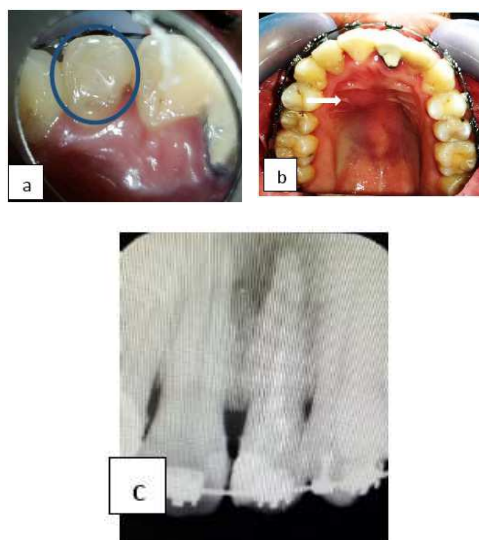


Figure 1. Clinical features (a) composite filling on the palatal portion of the tooth 22, (b) fistula on the palatal portion, (c) radiographic photo of tooth 22

Based on anamnesis, clinical examination and radiographic examination on the teeth 22, then the diagnosis of this case is a chronic periapical abscess et causa inadequate root canal treatment. The treatment plan this case is the root canal retreatment with composite resin restorations and fiber posts.

Case Management

On the first visit, access opening of the pulp chamber using a diamond bur. Performed gutta percha using the hedstrom file. After the root canal cleaned from the filler material, radiograph made using K-file ISO # 20 along 22 mm (figure 2a). Root canal preparation with ProTaper hand used until the F4 with a working length of 22 mm with irrigation at every turn of the file using EDTA and activated with endoactivator, then radiograph of the main gutta percha has taken by gutta-percha single cone ProTaper hand used F4 22 mm (Figure 2b). The root canal was irrigated with NaOCl 2.5% and activated with endoactivator, rinsed with sterile saline followed by irrigation using Chlorhexidine 2% and activated with endoactivator. Canals were dried using sterile paper point. Medication use of calcium hydroxide and covered with temporary fillings (Figure 2c).

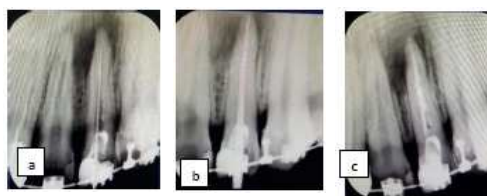


Figure 2. Radiographic photo of tooth 22 (a) master file #20. (b) main guttap (c) calcium hydroxide medication

On the second visit (2 weeks after the first visit) there was no subjective complaint. On clinical examination, the fistula is absent, percussion and palpation are negative, the radiographic appearance of smaller lesions (Figure 3). On the second visit (2 weeks after the first visit) there was no subjective complaint. Temporary fillings then dismantled and done root canal irrigation using 2.5% NaOCl and activated with endoactivator, and rinsed with sterile saline and then re-irrigated with Chlorhexidine and activated with endoactivator. Root canal filling was done using gutta-percha Protaper hand used F4 throughout the working length with single cone technique and using MTA fillapex as a sealer, covered with temporary fillings using GIC. On the third visit (2 months after the second visit) control was performed. No subjective complaints of the patient, Clinical examination revealed negative percussion and palpation. Radiographically, the size of the periapical lesion decreases (Figure 4a). So it can be continued the final restoration of composite resin with fiber post. Gutta-percha retrieval with fiber Kleer along 17mm (Figure 4b), then does a trial installation of fiber posts.

Cementation of fiber posts using breeze (resin cement) and light cured for 20 seconds and then cut to 2 mm above the orifice (Figure 4c) and do restoration with composite resin (Figure 4d).

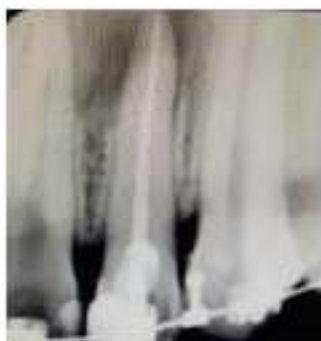

Figure 3. radiographic of tooth 22 revealed smaller lesions

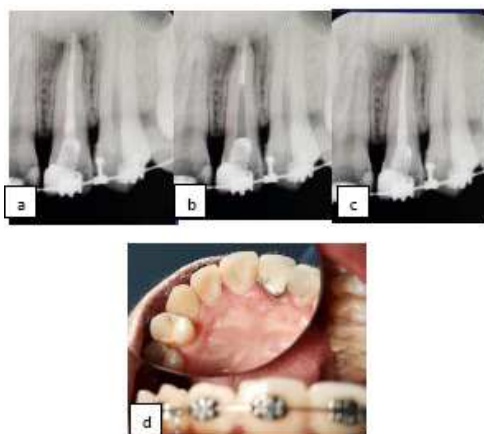


Figure 4. Radiographic and clinical photo of tooth 22 (a) smaller lesions, (b) gutta percha retrieval along 17 mm, (c) fiber post cementation, (d) final restoration with composite resin

Discussion

Based on anamnesis, subjective examination, objective and radiographic images concluded that the diagnosis, in

this case, is chronic periapical abscess et causa inadequate root canal treatment. In this case, the teeth 22 had been treated for the root canal a year ago, but the root canal treatment performed was inadequate, resulting in periapical abnormalities due to bacteria and its toxin entering the periodontal tissues causing periapical tissue inflammatory reaction and progressing into an abscess.^{1,2} An abscess is a collection of pus located within a sac formed in tissue caused by a process of infection by bacteria, parasites or other foreign bodies. An abscess is a body reaction that aims to prevent infectious agents from spreading to other body parts. Pus is a collection of dead local tissue cells, white blood cells, infectious organisms or foreign objects and toxins produced by abscesses for drainage.⁴

In this case, root canal retreatment was chosen to eliminate the infected bacteria that cause infections as clinically access control and orthograde filling can be performed, the rest of tissue can still be restored, and the periodontal tissue is healthy.⁵ The radiograph revealed that periapical lesions is less than 10 mm, the filling material was not performed perfect length and the patient is still young so that the immune reaction of the body is expected to quickly localize the infection and the healing process is expected to occur more quickly.

In failed root canal treatment, the number of *E. faecalis* bacteria to be 9 times more than primary infection.¹ At pH 11.5 *E. faecalis* bacteria will die. However,

the buffering capacity of dentinal tubules makes pH 11.5 difficult to reach. *E. faecalis* can withstand the root canals with calcium hydroxide medicaments more than 10 days by utilizing proton pumps into cells that have a low pH so that the pH balance is maintained.⁶

Use of additional 2% chlorhexidine irrigation aims to kill persistent bacteria because it has a broad spectrum of antimicrobial, substantive properties, and low toxicity. Chlorhexidine is very effective against gram-positive and gram-negative bacteria and facultative anaerobic bacteria. Its effectiveness is based on the interaction of positively charged molecules with the phosphate group on the wall of microbial cells that are negatively charged. This will affect the cell's osmotic balance. Increased permeability of cell walls can facilitate chlorhexidine molecules into bacterial cells.^{6,7}

Calcium Hydroxide selected for this case, according to Athanassiadis (2007) calcium hydroxide has the advantage of being bactericidal, assisting healing and repair tissue, high pH can stimulate the formation of fibroblasts, neutralize acidic pH, stop internal resorption, inexpensive and easy to use.⁸ The ability of calcium hydroxide to kill microorganisms is divided in two ways, first, chemically calcium hydroxide can work by destroying the cytoplasmic membrane by direct contact with hydroxyl ions, suppressing enzyme activity, disrupting cellular metabolism and inhibiting DNA replication. Calcium

hydroxide also can be used to control the exudate of the tooth with persistent periapical abnormalities. According to Heithersay, high concentrations of Ca ions cause precipitated contractions, resulting in reduced blood flow to the capillaries. The result will affect the reduction of the amount of plasma fluid that comes out into the tissues as a result of the inflammatory reaction. With the reduction of plasma fluid out into the tissues so that this condition allows the healing and calcification process.⁹

Single cone technique used as root canal filling method and MTA Fillapex is used as a sealer in this case because it can bind very well with the dentine, thereby preventing leakage in the periapical, otherwise the MTA content in this material will support the healing and formation of the hard tissue of the lesions.^{5,6}

Conclusion

In this case, root canal retreatment of the chronic periapical abscess which the etiology inadequate root canal treatment, not hermetic obturation can be done and has a successful outcome. The success criteria were characterized by loss of symptoms and clinical sign such as negative of percussion and palpation, with radiographic features seen as tissue repair of radiopaque in lesions, as well as a smaller size of a lesion from 10 mm to 4 mm.

References

1. Siqueira Jose F. Treatment of Endodontic Infections. Quintessence Publishing Co. Ltd. 2011.
2. Artiningsih D.A. Efek Laser Terapi Foto Dinamik dan Larutan Kalsium Hidroksida 50% Terhadap Karakter Fenotip Pada Genotip cps Enterococcus Faecalis Isolat Infeksi Intra Radikuler Persisten. Disertasi Universitas Indonesia. 2016.
3. Kanmaz et al. Nonsurgical endodontic treatment of a large periradicular lesion. Turk Endod J 2017;2(1):21-24.
4. Grossman L. Ilmu Endodontik Dalam Praktek. Edisi 11. Buku Kedokteran EGC. 1995
5. Mahmoud T, Walton R. Endodontic Principles and Practice 4th ed. Saunders Elsevier. 2002.
6. Hargreaves K, Berman L. Cohen's Pathways of The Pulp Eleventh Edition. Elsevier. 2016
7. Mohamadi Zahed et al. Agonistic and Antagonistic interaction between Chlorhexidine and other Endodontic Agent: A Critical Review. Iranian Endodontik Journal 2015; 10(1): 1-5.
8. Attanasiadis B. et al. The Use of Calcium Hydroxyde, Antibiotics and Biocides as Antimicrobial Medicament in Endodontics. Aus Dent J 2007. 52(Isuppl): S64-S82
9. Evan M, et al. Mechanism Involved in The Resistance of The Enterococcus Faecalis to Calcium Hydroxyde. International J.2001.35; 221-228.
10. Angerame D et al. Periapical Healing After Simplified Endodontic Treatments: A Digital Subtraction Radiography Study. Giornale Italiano Di Endodontia. 2013.27, 74-79.

APEXIFICATION AND ESTHETIC MANAGEMENT OF DISCOLORED AND FRACTURED NECROTIC TOOTH WITH IMMATURE ROOT: *A CASE REPORT*

Sinta Puspitadewi¹, Adioro Soetojo²

¹Resident, Departement of Conservative Dentistry

²Staff Department of Conservative Dentistry

Faculty of Dental Medicine, Airlangga University

Surabaya, Indonesia

Sinta Puspitadewi¹, Phone : +6281336110201, Email : dewisinta.drg@gmail.com

ABSTRACT

Background: Trauma to an immature permanent tooth may result pulp necrosis, apical closure stop causing the apical wide and open, and also discolored tooth. Apexification is the treatment to induce a calcified barrier by placing apexification material on the open apex area. *Mineral Trioxide Aggregate* [MTA] is an apexification material that has good biocompatibility, ability to close apical areas and high pH. Internal bleaching is a non-vital bleaching method performed after endodontic treatment using strong oxidator agent in pulp chamber. **Purpose:** The purpose of this case report is to present the management of discolored non vital permanent dental treatment with open apex area with class IV fracture *Ellis*. **Case:** A 21-year-old man comes to the Department of Conservative Dentistry, Airlangga University with chief complaints about discolored on his broken anterior tooth, with a history of trauma 11 years ago. **Management:** Patient performed endodontict treatment with apexification using MTA to induce root canal closure at apical and obturation with gutta percha thermoplastis, then performed internal bleaching and composite restoration. **Conclusion:** Treatment results indicate that apexification with MTA may shorten visit times by formation of apical barriers that stimulate healing. Internal bleaching can improve the initial color of dark grey tooth [5M1] into yellowish white [2M2] followed by final restoration of class VI composite.

Introduction

The completion of root development and closure of the apex occurs up to 3 years after the eruption of the tooth. Traumatic injuries to young permanent teeth affect 30% of children. These injuries often result in pulpal inflammation or necrosis and subsequent incomplete development of dentinal wall and root apices and causing

the apical wide and open. Before 1966 the clinical management of the “Blunder buss” canal usually required a surgical approach for the placement of an apical seal into the often fragile and flaring apex. Apicoectomy further reduces the root length resulting in a very unfavorable crown root ratio. ¹ The treatment of choice for wide and open apical of necrotic teeth is apexification, which is induction of apical closure to

produce more favorable conditions for conventional root canal filling. The most commonly advocated medicament is calcium hydroxide. The use of calcium hydroxide was first introduced by Kaiser in 1964 who proposed that this material mixed with camphorated parachlorophenol [CMCP] would induce the formation of a calcified barrier across the apex. Calcium hydroxide can be mixed with a number of different substances [camphorated mono chlorophenol, distilled water, saline, anesthetic solutions, chlorhexidine and cresatin] to induce apical closure.¹ Although recently considerable interest has been expressed in the use of mineral trioxide aggregate [MTA]. In recent times, interest has centered on the use of MTA for apexification. It has been used in both surgical and non-surgical applications.² MTA is an apexification material that has good biocompatibility, ability to close apical areas and high pH.

Tooth discoloration can be intrinsic, extrinsic or a combination of both. The discoloration is caused by the incorporation of intrinsic chromatogenic material into the dentin and enamel during odontogenesis or after teeth eruption.^{3,4} The causes of intrinsic discoloration in the pre-eruption are the administration of tetracycline, exposure to high levels of fluoride, trauma to the developing tooth, in addition to hereditary diseases such as amelogenesis imperfecta and dentinogenesis, and congenital erythropoietic porphyria.⁵

After dental eruption, the main

causes of discoloration are pulp necrosis, deposition of blood components into the tubules after trauma or pulpectomy, and deposition of secondary dentin due to aging or iatrogenic injuries.^{5,6} Food and beverages such as coffee, tea, red wine, carrots, oranges and tobacco are primarily responsible for giving rise to extrinsic stains.^{3,6}

Dental trauma can be the factor of discoloration teeth. Bacterial, mechanical, or chemical irritation to the pulp may result in tissue necrosis and release of disintegration by-products that may penetrate tubules and discolor the surrounding dentin. The degree of discoloration is directly related to how long the pulp has been necrotic.

Internal bleaching is used to lighten a discolored tooth that has had root canal therapy. It involves placing a chemical oxidizing agent within the coronal portion of a tooth to remove discoloration. Dental bleaching offers a solution for conservative and aesthetic problems instead of invasive repair options, such as crowns or porcelain veneers. Different protocols have been proposed for bleaching non-vital teeth,^{5,7} where the main bleaching technique for these clinical situations involves placing oxidizing agents inside the pulp chamber in direct contact with the dentin, it's called inside bleaching.⁸ Several substances have been used, such as oxalic acid, sodium hypochlorite, aluminum chloride, acetic acid, hydrogen peroxide, sodium perborate and carbamide peroxide. The thermocatalytic inside bleaching technique

involves the placement of chemical oxidants in the pulp chamber, which can be activated by different heat sources in order to accelerate the whitening process.⁹ Although this technique is effective, it was abandoned due to excessive heat, which may be responsible for the appearance of external cervical resorption.¹¹ It has been hypothesized that hydrogen peroxide penetrating through open dentin tubules can initiate an inflammatory reaction which could result in root resorption.

The walking bleach technique is an approach that uses no heat. This technique involves placing an active ingredient (such as 37% carbamide peroxide, sodium perborate or sodium perborate combined with 5-35% hydrogen peroxide) within the pulp chamber, followed by sealing the cavity.¹⁰

Case

An 21-year-old male patient comes to the Department of Conservative Dentistry, Airlangga University with chief complaints of discolored left maxillary central incisor with a history of trauma 11 year back.. On clinical examination revealed brown–grey discoloured teeth and Ellis Class IV fracture in permanent left maxillary central incisor was evident. [Figure 1] The periapical radiograph revealed a large blunderbuss canal and a large periapical lesion, suspect radicular cyst was diagnosed [Figure 2].

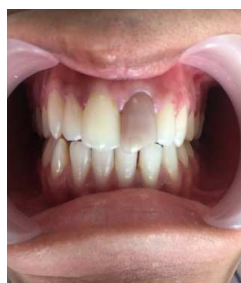

Figure 1: Pre-operative clinical photo

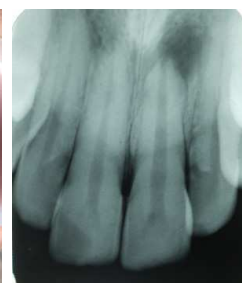

Figure 2: Pre-operative periapical radiograph

Case Management

The management of discolored non vital anterior tooth treatment with open apex area with class IV fracture *Ellis* is endodontic treatment with apexification using MTA to induce root canal closure at apical, internal bleaching to improve discolored tooth and an aesthetic restoration composite for the incical fracture. Before procedure started pre-operative photo has been taken [Fig. 1] and initial shade was noted [VITA shade guide] [Fig. 3] to objectify the result.

Access opening was prepared under rubber dam isolation and working length (WL) was determined by an electronic apex locator [TriAuto ZX, Morita, Japan] [Figure 4a] confirmed radiographically the WL was 25 mm using file #25 because the file under size 25 couldn't stay in the root canal. [Figure 4b] Biomechanical preparation was carried out with rotary instruments using reciproc file # 50 [VDW, Munich, Germany] [Figure 5a] followed by manual activated files up to master apical file [MAF] file size 80 with

circumferential and brushing filing motion. Root canal debridement was done using irrigation solution with aquadest and 2.5% NaOCL and sonically passively activated with EndoActivator [Dentsply Maillefer, Ballaigues, Switzerland]. [Figure 5b] Calcium hydroxide (Ultracal-Ultradent, St. Louis, MO, USA) medicament intracanal were placed into root canal and patient recalled after 6 days. [Figure 6]

At subsequent appointment, canal was irrigated with 2.5% NaOCl, 17% EDTA, aquadest, and 2% chlorhexidine. The canal was dried with paper points sterile and Mineral Trioxide Aggregate plug [Pro-MTA] was placed using MTA applicator and compacted with plugger until thickness of 5 mm [Figure 7,8]. A wet cotton pellet was placed in the canal and access cavity was sealed with Cavit [3M ESPE, St. Paul, MN, USA].

In next appointment, the obturation canal was completed using injection thermoplastic gutta-percha [Beefill-VDW, Germany] and AH Plus sealer [Dentsply Maillefer]. Gutta-percha filled under 2 mm bellow cemento-enamel junction for placing a plug of GIC [GC Fuji PLUS, GC Corporation, Tokyo, Japan] as a base to cover the root canal filling material in order to prevent resorptions. [Figure 9]

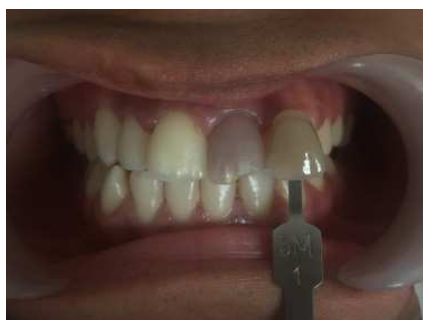

Figure 3: Initial shade of tooth 21 shows greater discoloration than the shade sample Vita 5M1.

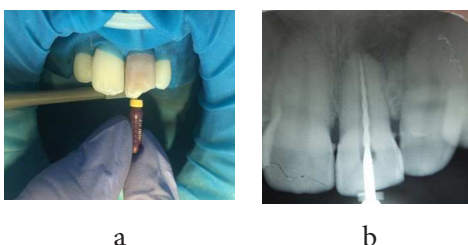

Figure 4.a: WL was determined by an electronic apex locator; **4.b:** Periapical radiograph showing WL determination of tooth 21.

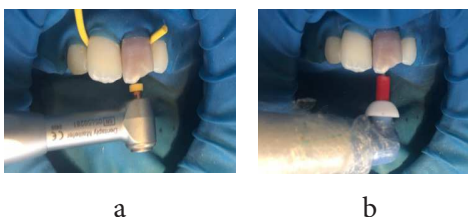


Figure 5.a: Biomechanical preparation with rotary instruments; **5.b:** Activating the irrigation solution tooth 21.

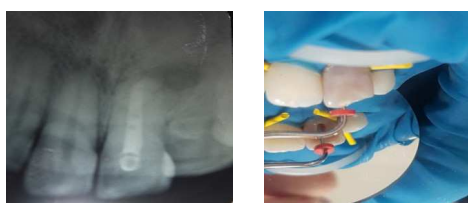


Figure 6: Medicament intracanal using CaOH

Figure 7: Compacting MTA with a plugger

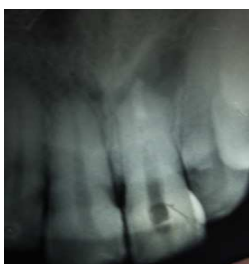

Figure 8: Periapical radiographic showing ± 5 mm of

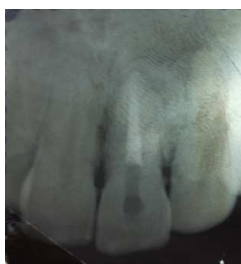

Figure 9: Gutta-percha filled under 2 mm bellow cemento-enamel junction for placing GIC as a base

The pulp chamber was etched with 37 % phosphoric acid [Total Etch, Ivoclar Vivadent] for 20 seconds and washed away. After drying the pulp chamber, 35% hydrogen peroxide [Opalescence Endo gel, Ultradent, St. Louis, MO, USA] as bleaching agent was applied inside the pulp chamber and a piece of dry cotton was placed over and the access cavity was sealed with glass ionomer cement [GC Fuji Plus, GC Corporation, Tokiyo, Japan] [Fig. 10]

After 4 days, the bleaching result was examined. The shade of discolored teeth showing an improvement, but still doesn't match with the other teeth. The bleaching agent is again inserted into the access cavity the patient was recalled after 1 week.

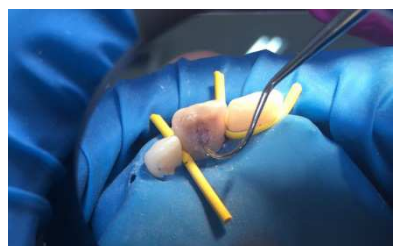


Figure 10: Bleaching agent was applied inside the pulp chamber

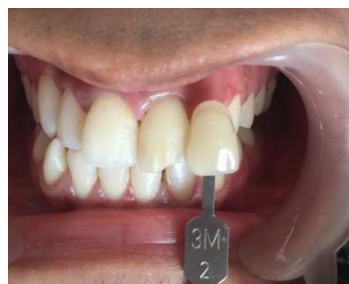

Figure 11: The control of shade guides shown 3M2 4 days after applied bleaching agent

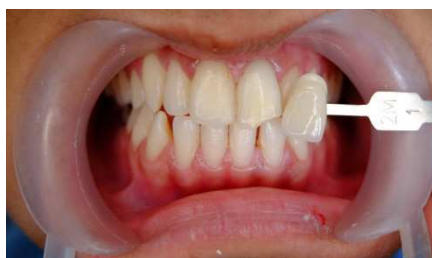

Figure 12: The final shade guide shown 2M1 after 11 days after applied bleaching agent

The final shade determination was improved from 5M1 initial shade become 2M1 final shade.[Figure 12] the bleaching agent was removed from the pulp chamber and the access cavity was dressed by Calcium hydroxide [Ultradent, St. Louis, MO, USA] in order to diminish oxygen inhibition of the polymerization of the definitive composite filling, and to counteract the increased permeability of

the dentin caused by the bleaching agent,¹² and temporary sealed with with Cavit [3M ESPE, St. Paul, MN, USA] for a week.

After 1 week pulp chamber was rinsed with water and the access cavity was restored by A2 composite resin [Filtek Z350, 3MESPE, MN, USA].

The last procedure in this case will presented an aesthetic composite restoration. Palatal index was made from diagnostic wax up using putty. Before the treatment start, opradam (ivoclar) was inserted. The tooth was prepared with minimal invasive, making slight bevel on facial and palatal surface using fissure diamond bur. [Figure 13]

After that, shade selection was done by putting the composite directly to the tooth and light cured to see the right color of the tooth at the third incisal. Etching procedure was done using phosphoric acid 37% [Total etch, Ivoclar] for 15 second. After the etch was rinsed, bonding procedure using 3M-ESPE single Bond2 and light cured for 20s. [Figure 14]

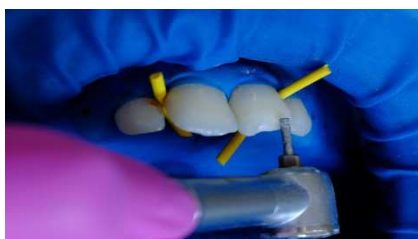

Figure 13: Tooth preparation

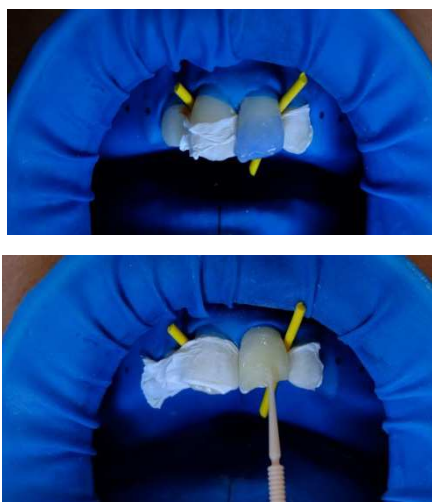


Figure 14: Etching and bonding procedure

After bonding procedure, palatal silicone index was inserted and thin palatal wall was made from composite. [Figure 15]

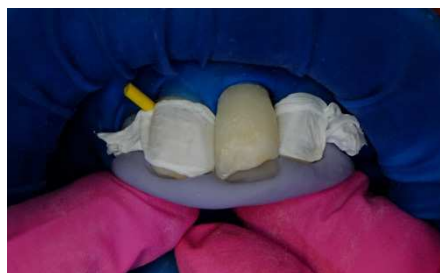

Figure 15: Palatal wall using palatal silicone index

Filling procedure was continue using shade composite A2 [Gaenial, GC] incrementally. Dentin part was done using OA2 Gaenial composite, the next layer was done using A2 composite for body part and TE composite for incisal part. The last layer for this procedure was AE composite to fill the enamel part. [Fig. 16]

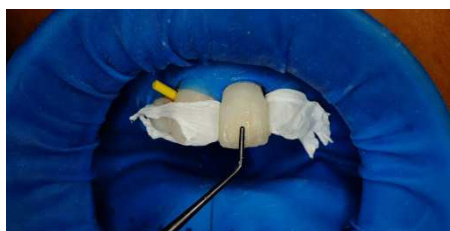

Figure 16: Filling procedure

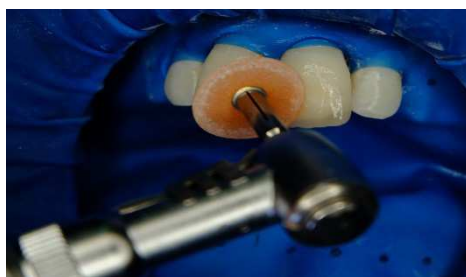

Figure 17: Polishing procedure

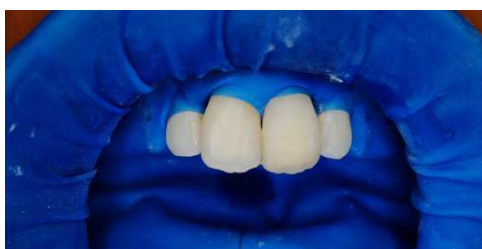

Figure 18: Post Treatment

After filling procedure was done, checked the occlusion using articulating paper. Finishing procedure was done using fine finishing fissure diamond bur followed by Sof-Lex™ disc [3M-ESPE] and Eve Diacomp Twist-Composite Polisher. [Figure 17]

Discussion

Trauma in immature tooth may result pulp necrosis, apical closure stop causing the apical wide and open, and also discolored tooth. Management treatment for this case is endodontic treatment with apexification to induce root canal closure

at apical before filling the root canal using gutta-percha thermoplastic and then followed by intracoronar / internal bleach.

The goal of apexification is to obtain an apical barrier to prevent the passage of toxins and bacteria into periapical tissues from root canal. Calcium hydroxide for apical barrier formation was reported successfully in 74-100% of cases and the average time for apical barrier formation was ranging from 5 months to 20 months.¹³

There are new strides in the apexification procedure with MTA. MTA as an apexification material represents a primary monoblock. Appetite like interfacial deposits form during the maturation of MTA result in filling the gap induced during material shrinkage phase and improves the frictional resistance of MTA to root canal walls. MTA has superior biocompatibility and it is less cytotoxic due to its alkaline pH and presence of calcium and phosphate ions in its formulation results in capacity to attract blastic cells and promote favorable environment for cementum deposition.¹³

A total of 5 mm barrier is significantly stronger and shows less leakage than 2 mm barrier.¹⁴ In the present case, MTA was placed for around 5 mm in the apical region. After on clinical examination was asimpomatis and there is no complaints from patient. Canal was ready to filled and prepared for internal bleaching to improve discolored tooth.

In every case, the root-canal filling material should be sealed with a base material, in order to prevent penetration of the bleaching agent into the periodontal space or root canal. The ubiquitous cements used to close perforations must also be covered with a base. Particularly MTA exhibits a much-reduced marginal seal when it comes into contact with bleaching agents.^{16, 17}

An intrinsic discoloration is defined as one with its origin within the pulp chamber. This includes hemorrhage, necrosis, calcification, and iatrogenic discoloration due to dental treatment. Hemorrhage of the pulp is the most common cause of discoloration after trauma. The dentinal tubules were entered by blood and then decomposes. This leads to a deposit of chromogenic blood degradation products, such as hemosiderin, hemine, hematin, and hematinoidin.¹⁵

Internal bleaching procedure in order to improve penetration into dentin, the access cavity was first etched with phosphoric acid so that the dentin tubules were slightly opened. However, this did not improve results, but will improve at least with more highly concentrated bleaching agents and dependent on the application duration of the bleaching agent

After the desired bleaching result has been obtained or slightly surpassed, sometimes an application of calcium hydroxide is recommended in order to diminish oxygen inhibition of the polymerization of the definitive composite

filling, and to counteract the increased permeability of the dentin caused by the bleaching agent as well as raise the low pH value in the cavity.^{18, 19, 20}

In this case discolored tooth presented with a class IV fracture *Ellis*. was included in Class VI restoration. Treatment of choice for this case is composite restoration. Composite resin has become an integral part of contemporary restorative dentistry and can be called “Star of Minimal Invasive”. The direct composite resin allow greater preservation of sound tooth structure than indirect restorations. direct composite resin restorations have become a viable alternative for young patients that require anterior restorative procedures.^{21, 22}

Conclusion

Based on the appropriate indication, treatment results indicate that apexification with mineral trioxide aggregate may shorten visit times by formation of apical barriers that stimulate healing. Internal bleaching improve the initial color of dark grey tooth (5M1) into yellowish white (2M1) and composite restoration was minimally invasive procedure in conservative dentistry and relatively low-risk intervention to improve the aesthetics of endodontically treated teeth.

References

1. Shikha D, Mukunda KS, Arun A, Rao SM. Apexification: A review. J Dent Sci Res. 2012;3:41–4.
2. Rafter M. Apexification: A review.

- Dent Traumatol. 2005;21:1–8.
[PubMed]
3. Hattab FN, Qudeimat MA, al-Rimawi HS. Dental discoloration: an overview. J Esthet Dent. 1999; 11: 291-310.
4. Valera MC, Camargo CH, Carvalho CA, de Oliveira LD, Camargo SE, et al. Effectiveness of carbamide peroxide and sodium perborat in non vital discolored teeth. J Appl Oral Sci. 2009; 17: 254-261.
5. Attin T, Paqué F, Ajam F, Lennon AM. Review of the current status of tooth whitening with the walking bleach technique. Int Endod J. 2003;36: 313-329.
6. Watts A, Addy M. Tooth discolouration and staining: a review of the literature. Br Dent J. 2001;190: 309-316.
7. Higashi C, Rauski RD, Gomes JC, Loguercio AD, Reis A. One-year follow-up of non-vital discolored teeth after bleaching with an association of techniques: a case report. Gen Dent. 2007;55: 676-682.
8. Chng HK, Ramli HN, Yap AU, Lim CT. Effect of hydrogen peroxide on intertubular dentine. J Dent. 2005; 33: 363-369.
9. Buchalla W, Attin T. External bleaching therapy with activation by heat, light or laser--a systematic review. Dent Mater. 2007;23: 586-596.
10. Nutting EB, Poe GS. Chemical bleaching of discolored endodontically treated teeth. Dent Clin North Am. 1967
11. acIsaac AM, Hoen CM. Intracoronal bleaching: concerns and considerations. J Can Dent Assoc. 1994; 60: 57-64.
12. Demarco F F, Freitas J M, Silva M P, Justino L M: Microleakage in endodontically treated teeth: influence of calcium hydroxide dressing following bleaching. Int Endod J. 2001;34: 495–500
13. Sheehy EC, Roberts GJ. Use of calcium hydroxide for apical barrier formation and healing in non-vital immature permanent teeth: A review. Br Dent J. 1997;183:241–6.
14. Kubasad GC, Ghivari SB. Apexification with apical plug of MTA-report of cases. Arch Oral Sci Res. 2011;1:104–7.
15. Arens D: The role of bleaching in esthetics. Dent Clin North Am. 1989; 33: 319–336
16. De Oliveira L D, Carvalho C A, Hilgert E, Bondioli I R, De Araújo M A, Valera M C: Sealing evaluation of the cervical base in intracoronal bleaching. Dent Traumatol. 2003; 19: 309–313
17. Loxley E C, Liewehr F R, Buxton T B, McPherson J C 3rd: The effect of various intracanal oxidizing agents on the push-out strength of various perforation repair materials. Oral

Surg Oral Pathol Oral Radiol Endod.
2003; 95: 490–494

18. Casey L J, Schindler W G, Murata S M, Burgess J O: The use of dentinal etching with endodontic bleaching procedures. *J Endod.* 1989; 15: 535–538
19. Demarco F F, Freitas J M, Silva M P, Justino L M Microleakage in endodontically treated teeth: influence of calcium hydroxide dressing following bleaching. *Int Endod J.* 2001; 34: 495–500
20. Kehoe J C: pH reversal following in vitro bleaching of pulpless teeth. *J Endod.* 1987; 13: 16–19
21. M u h a m a d , A b u - H u s e i n . , Azzaldeen,Abdulgani., and Mai,Abdulgani. Esthetic of Class IV Restoration with Composite Resin. *Journal Of Dental and Medical Science.* 2016 ; 15(1) : 61-66
22. Sowmya,Kyatham., K.S.Dwijendra., V.Pranitha., and Roy,Konda Karthik. Esthetic Rehabilitation with Direct Composite Veneering: A Report of 2 Cases. *Case Report in Dentistry.* 2017; 2017 : 1-3.

CASE REPORT

RESTORATION DIRECT COMPOSITE CLASS I WITH TECHNICAL STAMP : A CASE REPORT

Ricky Yudatmoko¹, Laksmiari Setyowati²

¹Resident, Department of Conservative Dentistry

² Staff Departement of Conservative Dentistry
Faculty of Dental Medicine, Universitas Airlangga
Surabaya, Indonesia

ABSTRACT

Background: Stamp technique is a new method for placing large composite restorations with accurate occlusal topography. It was introduced mainly to restore Class I and class II cavities and erosively damaged teeth. This technique is possible in teeth where preoperative anatomy of the tooth is intact and not destructed by carious lesion. This technique makes the procedure faster by accurately copying the occlusal anatomy, allowing a little or no occlusal adjustment. **Aim** to replicate occlusal anatomy by making a copy of the original unprepared tooth structure to get perfect anatomy. **Case:** A 24-year-old female complained of pain in left mandibular molar where black spot was spotted. The tooth had never been in pain before. Clinical examination showed tooth number 37 with media dentinal caries, vitality test showed positive, percussion and palpation tests showed negative results. Diagnosis was reversible pulpitis **Method:** Initially, by drying it before applying the flowable composite on occlusal surface of unprepared tooth and placed microbrush stick on top of flowable with slightly pressure then cure. After the matrix had been made, the preparation procedure is performed following the minimally invasive principle. The occlusal matrix was tested on preprinted 37th gear. Furthermore, liner, etching, bonding, and composite patching applications are employed, placed teflon tape on occlusal surface the occlusal matrix is applied and pressed until fully adapted, then cure. **Conclusion:** Using the stamp technique to restore Class I cavities is achievable, simple and practical, and result in a very accurate anatomical restoration.

Keywords: stamp technique, occlusion, anatomy, composite.

Correspondence: Ricky Yudatmoko, Resident Department of Conservative Dentistry University Airlangga, Surabaya, Indonesia, ryudatmoko@gmail.com.

INTRODUCTION

The main purpose of the restoration is for the shape, function and occlusion of the tooth damaged by caries. When compared with indirect restorations, where contact, contour and occlusion are well established because they are made in the laboratory, direct restorations have challenges in their application in the oral cavity. Both in terms of time and possibly form and occlusion are imperfect.¹

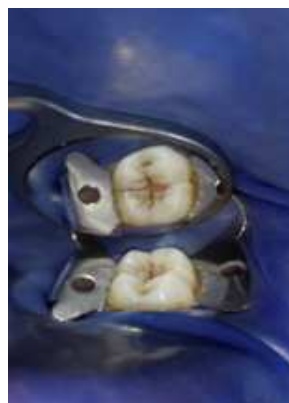Restoration of occlusal parts requires knowledge of anatomy and skill, this has the risk of over-fillings or less. In addition, the final surface obtained after polishing will not be as smooth as being completed using a stamp.²

In the posterior tooth there are sometimes carious lesions with occlusal anatomical forms that still appear intact but the caries depth has reached or exceeded the dentinoenamel. Therefore, some literature suggests that restoration techniques using stamp techniques allow to obtain the original dental occlusal form using clinical conditions such as those before preparation. This technique begins by molding the surface structure of the tooth, at the time prior to the preparation, aiming to obtain a negative stamp of the anatomical form of the occlusal surface of the tooth. To perform this technique, it is important that we ensure that the occlusal area is not destroyed and the anatomical structure is intact or only slightly damaged. Appropriate indication of stamp technique is only for caries with pit and fissure cavities

where the tooth still has an anatomical shape intact. Therefore, occult caries can be returned by stamp technique even though the lesion has reached clinical dentine but is not visible because the enamel surface is still intact from the anatomical perspective³

CASE(S)

A 24-year-old female complained of pain in left mandibular molar where black spot was spotted. The tooth had never been in pain before. Clinical examination showed tooth number 37 with media dentinal caries, vitality test showed positive, percussion and palpation tests showed negative results. Diagnosis was reversible pulpitis.



**Fig . 1 Pre – operative,
Class I superficial cavitated caries in left
mandibular second molar**

CASE MANAGEMENT(S)

The first action is that the tooth is isolated by using a rubber dam and the tooth surface is cleaned and dried. Using a microbrush, a thin layer of vaseline is applied to the tooth surface. To create a stamp, a composite flow resin is applied

to the occlusal surface, the microbrush stick inserted into the composite flow and then cure. Furthermore all caries tissue is cleaned along the occlusal access and stops at the arrested caries. At the bottom of the cavity is given a linear layer. Enamel layer is etched with 37% phosphoric acid for 15 seconds. The cavities are then rinsed and dried. Then the bonding liquid was applied using a microbrush and blown gently for 5 seconds and cure for 15 seconds. The cavities are filled with a composite to the fullest. Teflon tape is placed on the occlusal surface and the occlusal stamp is placed over the tape. Next, the tape was removed. The excess composite material of the occlusal is cleaned and then followed by polymerization with light curing. Next done finishing and polishing.

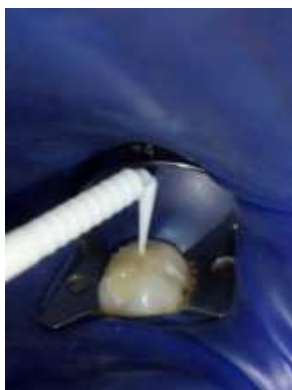

Fig 2. Application of a single coat of vaseline continued with flowable composite applied over the Vaseline then microbrush is pressed on the flowable composite with gentle pressure and cure

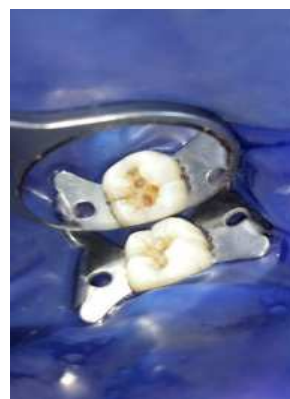

Fig 3. caries excavation/ cavity preparation

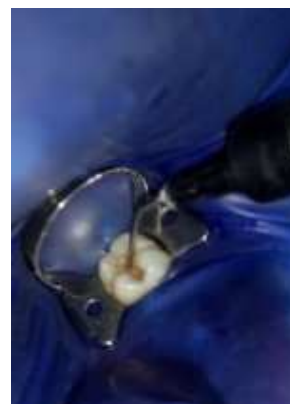

Fig 4 Protection of dentin-pulp complex with liner.

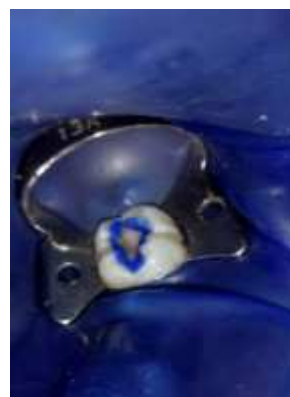

Fig 5. Selective enamel etching with 37% phosphoric acid

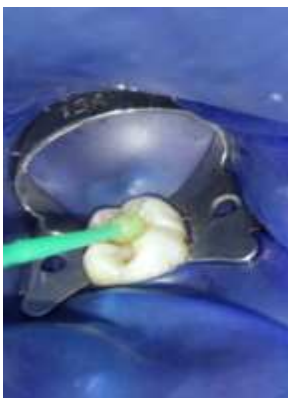

Fig 6. Bonding agent applied and cured

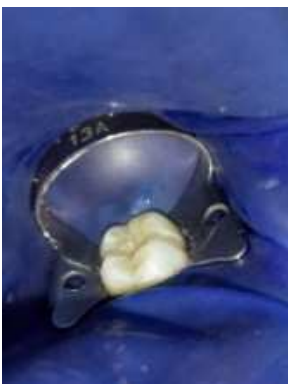

Fig 7. resin composite applied



Fig 8. Teflon tape acting as barrier material and the stamp used to replicate the occlusal topography.

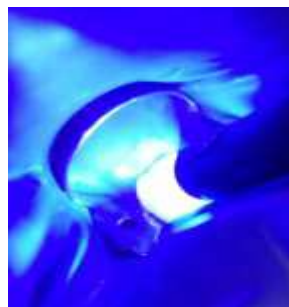

Fig 9. Curing done with LED curing light

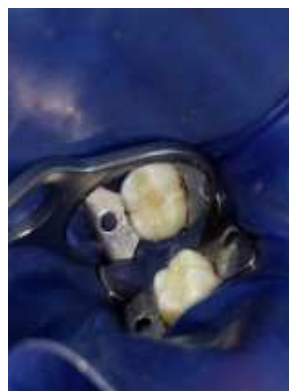

Fig 10. Final restoration

DISCUSSION

Effective use of fluorides, particularly concerning caries prevention in teeth, is widely used and is present around us. The use of fluoridation substances has altered the morphological factors of dental caries development, leading to caries lesions where enamel surfaces still appear intact. This phenomenon is identified as a “Fluoride Syndrome” and shows the direct relationship of the benefits of fluoride which increases the resistance on enamel surfaces. This lesion may leave an almost complete occlusal surface, can be diagnosed by radiographic examination and, clinically, a dark color underneath the transparent

enamel. However, there are other methods that can be performed to diagnose this type of caries, such as endoscopy (AcuCam), laser fluorescence (DIAGNOdent), optical fiber transillumination, digital radiography, electrical caries and caries detection (ECM).³

In this case, the material used to make the stamp is a flowable composite, but otherwise there are materials that can be used such as gingival barrier, pit and fissure sealant, and transparent acrylic resin. To make this technique more cost effective and get good detail, used composite resins that can flow. The pressure provided by the stamp on the composite resin decreases the formation of microbubbles and oxygen disturbances in polymerization. Prior to application in the last composite layer, the Teflon tape was placed as a barrier material.⁴

As we know that every technique is known to have advantages and disadvantages. The advantage of the stamp technique is that the time for overall treatment is reduced because the formation of detail from the assisted anatomy due to the use of stamp. This is an advantage for busy operators and helps improve their reputation with their patients. Furthermore, the degree of porosity present in the final restoration will decrease. This is because the stamp matrix provides pressure on the composite, thereby reducing the trap of air bubbles causing polymerization disturbance in the composite end layer.⁵

CONCLUSION

Using stamp techniques to return class I caries is simple, practical, effective, and efficient to recreate accurate occlusal anatomy in teeth with minimal occlusal damage resulting in accurate anatomical restoration.

REFERENCES

1. Tambake Neha Joshi, et al; Stamp technique -New perspective of Aesthetic Dentistry: A Case; IOSR-JDMS), 2017, June Vol 16, Issue 6 Ver. XII; 49-51
2. Mary Geena and Jayadevan Ambily, Microbrush stamp technique to achieve occlusal topography for composite resin restorations - A Technical Report, Journal of Scientific Dentistry; 2016; 6(2); 76-82
3. Occlusal stamp technique for direct resin composite restoration: a clinical case report; International Journal of Recent Scientific Research 2016; July Vol. 7; 12427-30.
4. Murashkin Alexey, Direct posterior composite restorations using stamp technique-conventional and modified: A case series, IJDR 2017; March 2(1): 3-7
5. Varsha Rao, Case Report: Microbrush Stamp Technique; dentaltown.com \ September 2015. Available from: [URL:http:// www.dentaltown.com/magazine/articles/5522/case-report-microbrush-stamp-technique](http://www.dentaltown.com/magazine/articles/5522/case-report-microbrush-stamp-technique)

CASE REPORT

AESTHETIC TREATMENT ON NON VITAL TRAUMATIC ANTERIOR TEETH BY INTRACORONAL BLEACHING

Sumitro TH¹, Nanik Zubaidah²

¹ Resident of Conservative Dentistry

² Lecture of Department of Conservative Dentistry

Department of Conservative Dentistry

Faculty of Dental Medicine – Airlangga University

Surabaya, Indonesia

ABSTRACT

Background : Discoloration teeth especially anterior teeth can affecting the aesthetic and appearance of people. Dental aesthetic, including tooth colour is of great importance for majority of the people and any discoloration or staining can impact patient quality life and confident. This aesthetic demand motivate patient to get treatment. To manage discoloration tooth cause of trauma can be use intracoronaral bleaching. Intracoronaral bleaching is a non vital bleaching method performed after endodontic treatment using strong oxidator agent in pulp chamber. The intracoronaral bleaching agents most commonly used are hydrogen peroxide, carbamide peroxide and sodium perborate. **Purpose :** The aim of this case is to present the management of non vital bleaching caused by traumatic injury through intracoronally bleaching. **Case :** A 31 years old female with discolored anterior teeth. Patient exposed to trauma 5 years ago and get the root canal treatment. The patient wish to enhance the appearance and to be confident again. **Case Management :** Tooth discoloration on anterior teeth cause by traumatic injury can be treated with intracoronally bleaching. Intracoronally bleaching will aesthetically recover its original colour, therefore will improve the self confident **Conclusion :** Intracoronally bleaching treatment on anterior teeth is able to recover the dental aesthetic colour and self confidence for the patients.

Keyword : Dental bleaching, Anterior teeth

Correspondence : Nanik Zubaidah, c/o Departemen Konservasi Gigi, Fakultas Kedokteran Gigi Universitas Airlangga. Jln. Prof. Dr. Moestopo No.47 Surabaya 60132. Indonesia. E-mail: nanikzubaidah@yahoo.com

Introduction

Discoloration teeth especially anterior teeth can affecting the aesthetic and appearance of people. Dental aesthetic, including tooth colour is of great importance for majority of the people and

any discoloration or staining can impact patient quality life and confident. In the middle of the 19th century, the first attempts were made to lighten discolored teeth using various agents. Initially, oxalic acid was used, until the tooth bleaching effect

of hydrogen peroxide was discovered in 1884.¹

Tooth whitening is of great importance in dental aesthetics. Whitening may be visually perceived and measured within a few days or weeks, depending on the technique used for peroxide delivery and retention, and the method of assessment.² Tooth bleaching can be performed externally, termed vital tooth bleaching, or intracoronally in root-filled tooth, called non-vital tooth bleaching. The bleaching of non vital teeth is relatively low risk treatment for improving the esthetics of endodontically treated teeth.³

Non vital bleaching which is non invasive technique has many benefits over other treatment options like full veneer crowns. Nonvital bleaching technique is non invasive procedure, very economical, less time consuming and economical.⁴

Case

The patient is a thirty one year old woman. Came with clinical discolored of her anterior teeth (fig 1). Patient exposed to trauma 5 years ago and get the root canal treatment. The patient wanted a treatment for her anterior teeth so that she could get the normal colour and the dental aesthetics similar to her original ones. During the intra oral examination on the teeth number 21, it was found that the tooth discolored , for conducting diagnosis and treatment plan, local radiographic photos must be taken first. The photo result showed treated on teeth 21. The condition of her teeth

was non vital with a clinical diagnosis of necrotic pulp with root canal treatment.

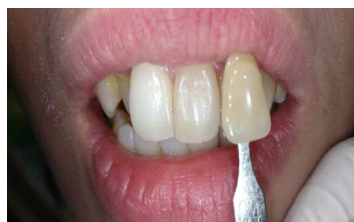

Fig 1. Initial discolored tooth

Case Management

First time patient came periapical radiography and the shade guide of the discolored tooth was assessed under normal daylight with a Vita shade guide. Before applying the bleaching agent ,1–2 mm of the gutta-percha was removed in an apical direction (Fig 2). A base of 1–2 mm glass ionomer cement was placed over the root filling (Fig 3) material to assure a mechanical barrier between the sealed root canal. The pulp chamber is etched with 37% phosphoric acid for 30s, washed and dried. Then applied hydrogen peroxide 35% (Fig 4). After 1 weeks desired results were obtained (Fig 6). Then the access cavity restored with resin composite (Fig 7). Clinical evaluation was recorded by comparing the tooth shade with its original one before treatment using the Vita shade guide and photographs. The tooth had lightened to a suitable degree with accepted clinical success.

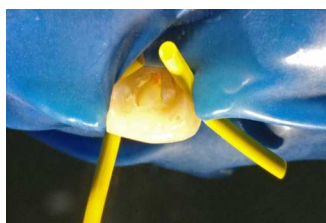


Fig 2. Exposed gutta-percha

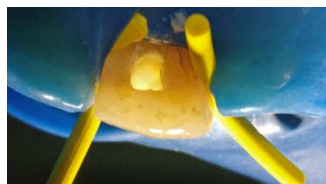


Fig 3. Base glass ionomer cement




Fig 4. Applied Hydrogen peroxide

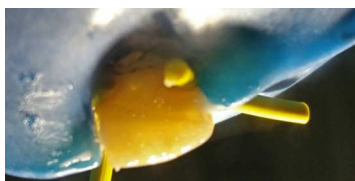

Fig 5. Cover with Glass ionomer

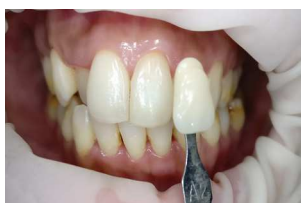

Fig 6. After 1 weeks

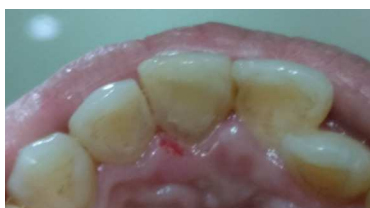

Fig 7. Resin composite restoration

Discussion

Tooth color is determined by a combination of phenomena associated with optical properties of tooth structure and light. Intrinsic color is determined by the optical properties of enamel and dentin. Treatment for discolored teeth includes removal of surface stains, micro abrasions, bleaching, veneering and placement of porcelain crowns.⁵

The discoloured anterior non vital tooth has likely been weakened from a combination of previous trauma, endodontic therapy, dental caries and restorative treatment. Destructive alternative prosthodontic treatment options such as veneers or crowns are odds to further weaken the tooth lending it towards possible failure and extraction in the future.¹³

Bleaching is the simplest, least invasive, least expensive means available to lighten discolored teeth in both vital and non vital teeth. Intra coronal bleaching of non-vital teeth involves the use of chemical agents within the coronal portion of endodontically treated teeth to remove tooth discoloration. Commonly used bleaching agents are carbamide peroxide, Hydrogen peroxide and sodium hydroxide and non- hydrogen peroxide containing materials i.e. sodium perborate.⁶

The intracoronal bleaching technique that was introduced in 1961 involved the placement of a mixture of sodium perborate and water into the pulp chamber

that was sealed off between the patient's visits to the clinician.⁷ The method was later modified and water was replaced by 30–35% hydrogen peroxide, to improve the whitening effect.⁸ Some modifications have been done in an attempt to minimize the risk of cervical or apical resorption; thus, a base of 1–2 mm glass ionomer cement was placed over filling material of the root to have a mechanical barrier between the sealed root canal and the bleaching gel, which is in agreement with other studies Friedman et al. as they did not use an intermediate lining prior to the bleaching material.⁹

Another modification added to the bleaching technique was that on reaching the desired shade guide; thus, the pulp chamber was filled by calcium hydroxide for seven days before the final filling material. This was necessary to allow for elimination of residual oxygen, which interferes with the polymerization of the filling material and to neutralize and render the medium alkaline that reduces the risk of cervical resorption.¹⁰ An interim dressing of calcium hydroxide is recommended to prevent any bacterial penetration and minimize further the risk of cervical root resorption.¹³

Non vital bleaching has not found much favour amongst the clinicians because of the fear of resorption following the procedure, which has a poor prognosis. But in this case report adhering to the proper barrier placement methods can definitely prevent the development of the

resorption. The protective barrier was placed 1 mm below the facial CEJ because it resulted in more acceptable aesthetic results, particularly in the cervical region. However, this procedure exposed more dentinal tubules, leading towards the approximal cervical parts of the periodontal ligament. But the placement of the intra-coronal bleach barrier based on Steiner and West's protocol prevents the extra radicular diffusion of the bleaching agent.¹¹

Non vital bleaching has several advantages over other post endodontic treatment options like full veneer crowns. Difficulties in shade matching and achieving the life like appearance and the emergence profile of the natural teeth are the possible drawbacks of the full coverage restorations. In contrast, non vital bleaching is a non invasive procedure and it is also less time consuming and economical and the patient's natural tooth structure is preserved.¹²

References

1. Goldstein R E. 1997. In-office bleaching: where we came from, where we are today. *J Am Dent Assoc* 128: 11S–15S
2. Gerlach RW, Barker ML, Sagel PA. 2002. Objective and subjective whitening response of two self-directed bleaching systems. *Am J Dent* 15:7A-12A.
3. Brigitti Zimmerli, Franziska Jeger, Adrian Lussi. 2010. Bleaching of nonvital teeth- A clinical relevant

- literature review. Schweiz Monatsschr Zahnmed vol. 120:4
4. Cohen SC, Bums RC. 1980. Pathways of the Pulp. St. Louis, C.V. Mosby ,
5. Galiatsatos AA. 2005. An indirect repair technique for fractured metal-ceramic restorations: a clinical report. The Journal of prosthetic dentistry. 93(4):321-3.
6. Zekonis R, Matis B, Cochran M, Shetri SEA, Eckert G, Carlson T. 2003. Clinical evaluation of in-office and at-home bleaching treatments. Operative dentistry. 28(2):114-21.
7. Spasser HF. 2006. A simple bleaching technique by using sodium perborate. *NY State Dent J*; 27:332–34.
8. Lambrianidis T, Kapalas A, Mazinis M. 2002. Effect of calcium hydroxide as a supplementary barrier in the radicular penetration of hydrogen peroxide during intra-coronal bleaching in vitro. *Int Endod J* 2002; 35:985-90.
9. Griffiths C.E., Bailey, Jarad F.D., Youngson C.C. 2008. An investigation into most effective method of treating stained teeth: An in vitro study. *J Dent*. 36:54-62
10. Goldstein R.E. 1998. Esthetics in dentistry, B.C. Decker Inc., London
11. Rostein I. 2002. Tooth discoloration and bleaching. In: Ingle JJ, Bakland LK, editors. Endodontics. 5th ed. Hamilton, Ontario, Canada: BC Decker Inc, 2002:845-60.
12. Truman J. 1864. Bleaching of non-vital discoloured anterior teeth. *Dent Times* 1:69–72
13. Atreya S, Patel B. 2016. Endodontic treatment, Retreatment, and Surgery mastering clinical practice. 449

MANAGEMENT OF FRACTURED INSTRUMENTS BY FILE BYPASS TECHNIQUE IN ROOT CANAL MANDIBULAR MOLAR

Meita Herisa¹, Ratna Meidyawati²

¹Post Graduate Student, Department of Conservative Dentistry, Faculty of Dentistry
Universitas Indonesia

² Lecturer, Department of Conservative Dentistry, Faculty of Dentistry,
Universitas Indonesia

ABSTRACT

Root canal treatment aims to remove all microbial pathogens from inside the root canal mechanically by preparation using endodontic instruments, and chemically with irrigation and intra canal medicament. However, many incidents might happened during the process, one of which is the fractured instrument in the root canal. The purpose of this case report is to present a clinical case of separated instrument and its treatment with bypass in first mandibulary molar. A 29-year-old woman was referred for root canal treatment of right mandibular first molar to the Department of Conservative Dentistry. One week earlier, she had an unfinished root canal treatment by former dentist because she felt a spontaneous pain since 2 weeks ago. Now she felt pain and discomfort while chewing on her lower right tooth. A clinical examination showed a deep cavity on tooth #46 (D6. Site 2, size 3), sensitive to percussion, no respond to palpation and cold test, and gingiva normal. Pre-operative radiograph showed a separated instrument in apical third disto lingual canal and difusedperiapical radiolucency with diameter of 1 mm. Considering the clinical and radiographic findings, our final diagnosis was chronic apical abscess et causa pulp necrosis and separated instrument. Therefore, root canal treatment with bypassing separated instrument was performed in this case.

Keywords : root canal treatment, separated instrument, bypass, mandibular molar

INTRODUCTION

A fractured instrument during root canal treatment is an undesirable condition. But this occurs from time to time and can cause distress for both clinician and the patient. Fractured file in the root canal will obstruct the cleaning and shaping procedures and blockade access to apical

foramen, hence there are still congregation of bacteria and debris that are untouchable when doing the root canal preparation because of the separated file. Beside that, the effort to remove the fractured file is difficult and time consuming. It is important for clinician to understand the probability and the cause of fractured file

on the root canal treatment so they can prevent this condition.

The best treatment that clinician should do when there is a fractured file is removing it. However, in a certain occasion, the effort to removing the fractured file may cause ledge formation, over enlargement, and root canal transportation that will weaken the tooth structure. Clinician must evaluate the choices whether to remove the fractured file, doing the bypass, or leaving the fractured file in the root canal. The choice must be adjusted to the diagnosis, root canal infection, root canal anatomy, the position of fractured file, and the type of the fractured file.^{1,5,6}

Bypass is a conservative procedure that can be done if the fractured file can not be removed. The aim of bypass technique is making the process of cleaning and shaping the root canal can be done in a working length while the fractured file is still in the root canal. This option is recommended to a condition where the fractured file is in a difficult position such as apical one-third or in a curved canal. Removing the fractured file in apical one-third has a vertical fracture risk compared to middle and coronal third of root canal. There was a research stated that leaving the fractured file while carrying out the bypass treatment would not reduce the success rate of the treatment because it would still make a favorable obturation. It is also stated that if the bypass procedure could still be done, the fractured file can also be removed.^{1,6,7}

CASE REPORT

A 29 year old woman was presented at the clinic to continue the treatment of her right mandibular first molar. The former dentist had done a root canal treatment one week earlier, but the treatment had been unfinished and the patient was referred to the Department of Conservative Dentistry Clinic, University of Indonesia. The patient stated that she had a spontaneous intermittent pain since two weeks ago. But now she only had pain when chewing.

Intraoral examination found a temporary filling on #46. On the objective examination revealed that there was a D6 caries (site 2 size 3) on #46, sensitive to percussion, no respond to palpation and cold test.

Radiograph examination showed a normal pulp chamber, curved mesial root canal to the distal, constriction on distal root canal, and radiopaque images showing the fractured file on the disto lingual apical third of root canal. There was a widening of periodontal ligament, disconnected lamina dura and diffused radiolucency images in the periapical with 1mm diameter.

Based on the subjective, objective, and radiograph examination it can be concluded that the diagnosis of #46 is chronic periapical abscess et causa necrotic pulp and fractured file. The treatment needed to be carried out is root canal treatment on #46 with fractured file bypass and ceramage onlay restoration.

CASE MANAGEMENT

Removing the temporary filling was done on tooth 46 after rubber dam isolation, followed by completion of access opening that had been done by former dentist. After it had been suspected that there was a fractured file, patient had been informed that there was a probability that there was a fractured file on one of the root canal and the best treatment procedures would be carried out, with the probability of doing the endodontic surgery if the periapical lesions persisted.

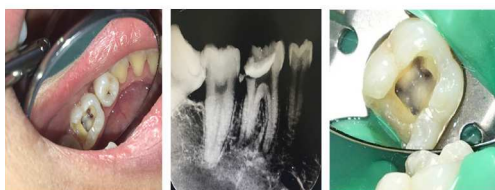

Figure 1. (a) Photograph of pre-operative tooth after removal of temporary filling, (b) Periapical radiograph of pre-operative tooth. (c) Photograph of the tooth after rubber dam isolation and completion of access opening

After that, preparation of the root canal was performed on coronal two-third of the 4 orifices; 2 mesial orifices and 2 distal orifices using SX file. Initial exploration of the root canal using k-file ISO #10 through the working length; that is mesiobuccal root (MB), mesio lingual (ML), and disto buccal (DB) 18,5 mm. The working length for disto lingual root (DL) was 18mm but the k-file could only reach 16 mm because of the fractured file at the apical third of the root. The actual working length was determined by electronic apex locator and confirmed by radiograph. Initial file was

k-file #10 with 18,5 mm working length for MB, ML, and DB root canal and initial k-file #10 with 18 mm working length for DL root canal.

Preparation of MB, ML, and DB was using Protaper hand-use (Dentsply Maillefer, Switzerland) until reaching the working length. Preparation was done until root canal were clean and master apical file that was F3/18.5 mm was obtained for MB, ML, and DB. DL root canal was prepared until coronal part of the fractured file until F3/16. Irrigation was always done with 2,5% NaOCl and application of EDTA gel during the process of root canal preparation.

Afterward a radiograph of master apical cone was conducted and it could be seen that the preparation had reached the working length except for the DL root canal because of the fractured file as can be seen on Figure 2. The root canals were given Calcium Hydroxide (Calcipect, Nippon Sika-Yakuhin, Shimonoseki, Japan) as a medicament and tooth was restored with temporary filling.

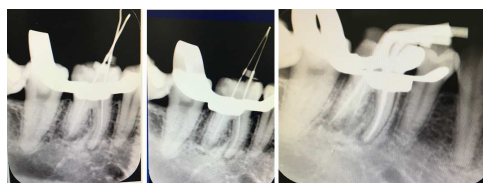

Figure 2. (a) Radiograph of determination of MB and DB actual working length, (b) Radiograph of determination of ML and DL actual working length, (c) Radiograph of master apical cone of MB, ML, and DB root canal.

One week after the first visit, there was no chief complaint, negative palpation, but the percussion was still positive on tooth 46. Afterward, bypass procedure was done on the DL root canal to go through the fractured file using C+ #8 and #10 (Dentsply Maillefer, Switzerland) with watch winding movement. Estimated 18 mm working length was obtained. After the bypass technique was successfully going through the fractured file, the same process was repeated using larger hand file carefully until reaching F2/17 mm master apical file. Irrigation with 2,5% NaOCl and MD-Cleanser (Meta Biomed Co., Ltd., USA) that contained 17% EDTA as a dentin softener and RC- Prep (Premier Dental, Philadelphia, PA, USA) lubricant that contained 15% EDTA sodium were used in every use of files to ease the preparation of root canal. Working length then was reconfirmed with master apical cone radiograph. The root canals were given ChKM medicament and then the tooth was restored with temporary filling.

After the third visit there was no chief complaint, percussion and palpation were negative so obturation could be carried out with cold lateral condensation technique using non-iso *gutta percha* (Protaper Universal *Gutta Percha*, Dentsply Tulsa Dental, Switzerland) and accessory cones which were F3/18,5 mm *gutta percha* protaper for MB, ML, DB root canals and F2/17 mm for DL root canal. We used MTA Fillapex as the sealer. After root canals were filled, we applied glass ionomer

cement as a basis and the tooth was restored with temporary filling (Cavition, GC Corporation, Japan).

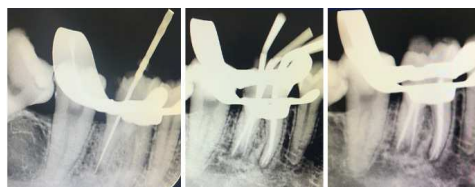


Figure 3. (a) Radiograph of DL root canal *bypass*, (b) Radiograph of master apical cone, (c) Radiograph of root canal obturation

Permanent restoration was conducted one month after obturation using onlay ceramag and it was done using shoulder edge design preparation. Impression was made using double impression material on tooth 46 and alginate on the antagonist jaw. Afterward bite wax record and suitable color shade determination were conducted and then the model was sent to the dental lab. One week after that the placement of onlay ceramag was conducted on tooth 46.

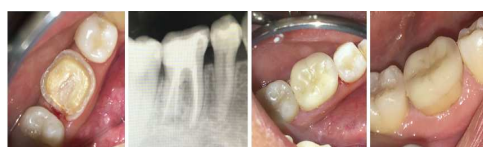

Figure 4. (a) Photograph of tooth 46 onlay preparation (b) Radiograph of onlay try in on tooth 46, (c) (d) Photographs of onlay ceramag placement on tooth 46.

DISCUSSION

On this case report, the fractured file is known from radiograph image, where there was a radiopaque image in the distolingual apical region of root canal

and when the initial file exploration was conducted it could not reach the estimated working length. Before the treatment was performed, the patient was given the information about her tooth condition, the options of fractured file treatment and which one was the most likely to be done, along with the prognosis.

Based in the radiograph, the root canal was not yet to be widened and the radiopaque image of the fractured file seemed to be thin with ± 1 mm length. So it can be concluded that the root canal was not yet to be prepared or it was still in the initial stage and the fractured file was the initial file that was from stainless steel material and manual operated.

Several probabilities that cause fractured file in this case were access preparation that was not sufficient and the root canal anatomy that is narrow, using file without lubricant, and overuse files. Access preparation that is not excellent will cause the pulpal wall to obstruct the file to go through the canal without inhibition so there will be an excess pressure and not appropriate on the file that will cause the file easily fractured. If the file is in contact with access cavity wall during instrumentation, the potential of fractured instrument to take place will increase. Access preparation that is not sufficient will also increase the amount and severity of curvatures that is need to be negotiated by file⁸.

The narrow root canal anatomy will cause torque fatigue on the file. Torque fatigue happens when the end of the

instrument detained on the narrow root canal meanwhile the base is always rotated, so the instrument will fracture in the detained area. When the limit of elasticity of the metal material has been exceeded, the fractured file can not be avoided.^{9,10}

In addition, the file that is fractured on this case is a small size stainless steel file. Small sized files are also said to be prone to fracture because the file diameter size will decrease the torsion strength and increase the torsion failure. Smaller size of files are also initial files that obtained more stress and will prone to fracture⁹.

Using file without irrigation and lubrication will also dry the root canal and increasing friction between file and root canal wall and then will fracture the file. Hence, continual root canal lubrication with irrigation or lubricant will reduce the friction an increase the efficacy of instrumentation⁸.

Overuse files. File has flutes which are the debris retention during preparation. If using file repeatedly from time to time the efficiency will decrease and will cause excess friction pressure and then fracture the file. Therefore the pressure during instrumentation is done periodically, flutes are cleaned from debris, and file must be replaced after several uses⁸.

Bypass is performed after consideration of the position of fractured file, which is on the apical third of the narrow root canal, small size and shortness of fractured file, and good visualization that

can not be obtained. James L. Gutmann stated that if there is a fractured instrument that is in the apical of curvature and in the site that is difficult to do the access such as in the apical third, the fractured file can always be left in the root canal. The effort of removing the fractured file in this position will increase the risk of iatrogenic error and excess removal of dentin tissue so the tooth will prone to vertical fracture^{1-3,11}.

Bypass aims to obtaining access until reaching the apical end of root canal so great preparation and obturation can be obtained. Bypass technique is done based on the root canal anatomy factor which usually is not perfectly round shaped so there is a probability to insert the small size between the fractured file and root canal wall¹².

Bypass procedure of the fractured filed starts with using small hand file. In this case, we used C+ hand file that is from stainless steel that has a cutting end and rigid because it has been through a particular hardening process so it will not be easily bent and has a strength to penetrate the hard part^{8,13,14}. 17% EDTA irrigation fluid is used as a dentin softener to ease the procedure of root canal preparation and will effectively remove the smear layer when directly in contact with root canal for less than 1 minute.¹⁵ In this condition, usually excellent instrumentation in the root canal can be done after bypassing the fractured instrument successfully has been carried out.

NaOCl irrigation has been used because it is a gold standard of irrigation material because of broad spectrum of antimicrobial against the microorganisms and biofilm including the microbes that are difficult to be destroyed in the root canal such as *Enterococcus*, *Actinomyces*, and fungi¹⁵.

Calcium Hydroxide medicament is biocompatible and is an antimicrobial material with high pH effect. The mechanism of Ca(OH)_2 comes from its ability to dissociated to become a calcium ion and hydroxyl ion that will increase the local pH. This will cause the creation of alkali environment that will not promote the growth of bacteria. Ca(OH)_2 will hydrolyze the lipid part of LPS negative gram bacteria that will eliminate LPS ability to produce $\text{TNF-}\alpha$ in the monosit peripheral blood so it will decrease the local inflammation respond and stimulate the periapical hard tissue healing. ChkM medicament is used because it has antimicrobial effect that is long lasting and also used as a light sedative.¹⁵

Fractured file is not a direct cause of decreasing endodontic treatment prognosis, however it is a microbial control that is not sufficient from cleaning and shaping process that is not perfect that will increase the failure of endodontic treatment¹². Hence the bypass technique will give good prognosis because the cleaning, shaping and obturation of root canal can be reached until working length.

The prevention of fractured file that must be done are excellent preparation access so the file can be inserted to the root canal and will decrease the stress and probability of fractured file. Always irrigate and use the lubricant to decrease the friction and excess stress, also promote the instrumentation efficacy. Replace the old file with the new file if it shows damage such as flaws where there is a shiny area or unwinding at the flutes, file has been bent or wavy, the file has been overbending or excess precurving, and corrosion⁸. Operator must notice the anatomy and curved root canal radius, rotation speed, and inappropriate torsion use, and whether or not there is a glide path in the root canal^{9,12}.

Cold lateral condensation technique is used on the obturation of oval shaped root canal so hermetically obturation of root canal will be obtained. MTA Fillapex sealer is a biocompatible sealer, has a great flow, and has setting expansion so it will give a root canal closure and prevent the entry of the tissue and recurrence of bacteria contamination.

CONCLUSION

In this case report, the bypassing fractured file has been done in the distolingual root canal of right first mandible. Bypass technique can be performed without direct visibility of fractured file so it can be a great choice if the location of the fractured instrument is in the apical third of the root canal. Bypass

technique is done to prevent iatrogenic mistake such as ledge formation or when the fractured file is pushed toward the apical direction when attempted to remove the fractured file. Root canal treatment can be finished greatly as long as the working length after the bypass and subjective and objective examination has shown the good result. The treatment can be completed using onlay ceramange restoration.

REFERENCES

1. Suter B, Lussi A, Sequeira P. Probability of removing fractured instruments from root canals. *Int Endod J*. 2005;(38):112-123.
2. Hülsmann M, Schinkel I. Influence of several factors on the success or failure of removal of fractured instruments from the root canal. *Endod Dent J*. 1999;15:252-258.
3. Ward JR, Parashos P, Messer HH. Evaluation of an ultrasonic technique to remove fractured rotary nickel-titanium instruments from root canals: clinical cases. *J Endod*. 2003;29:764-767.
4. Shen Y, B P, Shun-pan G, Chueng GS. Factors associated with the removal of fractured NiTi instruments from root canal systems. *Oral Surg Oral Med Oral Pathol Oral Radiol Endod*. 2004;(98):605-610.
5. Nimet G, Dilek H. Comparison of the Different Techniques to Remove Fractured Endodontic Instruments from Root Canal Systems. *Eur J*

- Dent.* 2009;3(2):90-95.
6. Mcguigan MB, Louca C, Duncan HF. Clinical decision-making after endodontic instrument fracture. *Br Dent J.* 2013;214(8):395-400. <http://dx.doi.org/10.1038/sj.bdj.2013.379>.
 7. Cohen S, Hargreaves K. *Pathway of the Pulp*. 11th ed. Colombus: Elsevier Inc; 2016.
 8. Mcguigan MB, Louca C, Duncan HF. Endodontic instrument fracture : causes and prevention. *Br Dent J.* 2013;214(7):341-348. doi:10.1038/sj.bdj.2013.324.
 9. Rambabu T. Management Of Fractured Endodontic Instruments In Root Canal: A Review. *J Sci Dent.* 2014;4(2):40-48.
 10. Grande NM, Plotino G, Pecci R, Bedini R, Malagnino VA, Somma F. Cyclic fatigue resistance and three-dimensional analysis of instruments from two nickel – titanium rotary systems. *Int Endod J.* 2006;39:755-763.
 11. Ruddle CJ. Broken Instrument Removal : The Endodontic Challenge. *Dent Today.* 2002;(July).
 12. Rhodes JS, Ford TRP, Lynch JA, Liepins PJ, Curtis R V. Micro-computed tomography : a new tool for experimental endodontology. *Int Endod J.* 1999:165-170.
 13. Alomairy KH. Evaluating two techniques on removal of fractured rotary nickel-titanium endodontic instruments from root canals; an in vitro study. *J Endod.* 2009;35:559-562.
 14. Gutmann J. *Problem Solving in Endodontics; Prevention, Identification, and Management*. 5th ed.; 2012.
 15. Fors UGH, Berg JO. Endodontic treatment of root canals obstructed by foreign objects. *Int Endod J.* 2006;(19):2-10.

CASE REPORT

BICUSPIDIZATION : TREATMENT FURCAL PERFORATION IN MANDIBULAR MOLAR

Tri Estiyaningsih¹, M.Rulianto²

¹ Resident of Conservative Dentistry Specialist Program

² Lecturer of Department of Conservative Dentistry

Department of Conservative Dentistry

Faculty of Dental Medicine – Airlangga University

Surabaya – Indonesia

Background: Minimal invasiveness is the prime principle for conduction endodontic treatment. Nevertheless, due to the extend of carious lesion, or operator factor, complications might happen. One of the most common endodontic complications is furcal perforation. Iatrogenic furcal perforation occurs during preparation of endodontic access opening phase or exploring root canal orifice of molar. Purpose: To describe the bicuspidization technique. Case: A 30-year-old male with a non-contributory medical history was referred with complaint of an increasingly painful swelling over his mandibular left first permanent molar. Clinical examination showed that 36 was the offending tooth and was tender to percussion. Dental history showed that the tooth had been endodontically treated by general dental practitioner two months ago. Radiographic examination showed obturated canals and a radiolucency on furcal region, which denote a furcal perforation. Case Management: Access opening revealed two obturated canals and two missing canals, which was negotiated, shaped, and obturated. In second appointment under local anesthesia, a vertical cut was made to separate the distal and mesial part of the tooth, seven weeks after surgery the dissected portions were prepared for porcelain restorations, then a prefabricated post was inserted and a core was built. Furthermore, each dissected parts of the tooth was restored. Follow up periods at both 3 and 8 months showed clinical and radiographic favorable healing response and absence of symptoms. Conclusion: bicuspidization is an effective treatment to preserve the natural dentition which has been damaged to the extend of furcal perforation.

Correspondence: M.Rulianto. Department of Conservative Dentistry, Faculty of Dental Medicine, Universitas Airlangga. Jl. Mayjen Professor Doktor Moestopo No. 47, Surabaya, East Java 60132, Indonesia.

E-mail: mohamad-r@fkg.unair.ac.id

INTRODUCTION

Dental technology is growing rapidly at the current time and provides an opportunity for patients to maintain functional dentition for lifetime. Therapeutic measures performed to ensure retention of teeth vary in complexity. The treatment may involve combining restorative dentistry, endodontics, orthodontics, and periodontics so that the teeth are retained in whole or in part¹.

Root perforation is an artificial communication between root canal system and the supporting tissues of teeth or the oral cavity. Root perforation is usually caused by the presence of iatrogenic, resorption of the roots, and caries². This is due to the frequent use of iatrogenic, for example are improper rotaries during the preparation of the access to endodontic and the search for the root canal. Inappropriate post space preparation for permanent restoration of endodontically treated teeth is another common iatrogenic cause of iatrogenic perforation³. During root canal treatment, when seeking root canal entrances or permanent restoration of endodontically treated teeth is another common iatrogenic cause of preparing a canal for a post, it might caused iatrogenic furcation perforation. Perforation in furcation area could reduce prognosis of involved tooth because inflammation will be happen. Perforation could be treated using a hermetic and biocompatible sealant, but if furcation region irritated by these materials, the only way to repair it

is surgical access to remove the irritants under the fornix⁵.

Bicuspidization technique is the separation of mesial and distal roots of mandibular molars along with its crown portion, where both segments are then retained individually.^{5,6}

CASE

A 30-years-old male with was referred to the Conservative Departement Dental Hospital, Airlangga University with complaint of an increasingly painful swelling over his mandibular left first permanent molar. Based on the results of the anamnesis, he had no contributory medical history. Dental history showed that the tooth had been endodontically treated by general dental practitioner 2 months ago.

Based on the results of the clinical examination, temporary filling by a previous dentist which already released (Fig. 1).

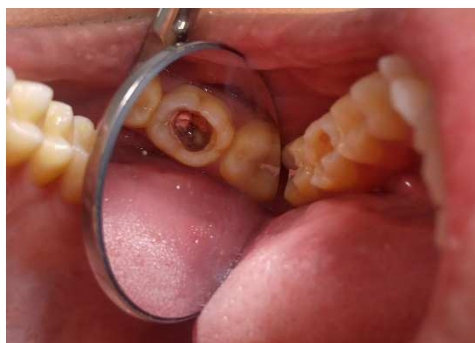

Figure 1. Intra oral before treatment

it showed that an occlusal cavity by obturated the root canal at the mesiobuccal

and distobuccal, in the bifurcation area there is a widely perforation. The tooth was tender to percussion, there was inflammation, on gingiva around the teeth and negative vitality test,

Based on radiographic examination, it was showed that there were gutta-percha cones on mesiobuccal and distobuccal canals and it the obturation is hermetic and a radiolucency on furcal region, which denote a furcal perforation. However there was no periapical lesion related with mesial and distal root. (Fig.2) The diagnosis was pulp necrosis.

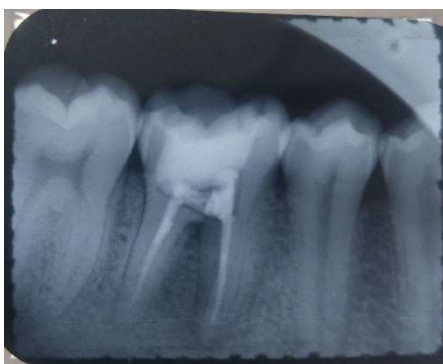


Figure 2. Radiograph appearance before treatment

CASE MANAGEMENT

Subjective and objective examination, intraoral photo, preoperative radiograph, diagnosis and signing of informed consent was done before treatment started. Then, prepared to isolate those area using rubber dam and saliva ejector and opened temporary filling. On radiographic examination, it could be seen gutta-percha whose good and hermetic filling on mesio-

buccal and disto-buccal roots. The next step was seeking 2 another roots which could be found on mesio-lingual and disto-lingual roots. Pulp extirpation was using NaOCl 2,5% and aquadest. Glide path was achieved using c pilot (VDW, Germany) no 10 and no 15 with 21 mm length and canal lubricant (Glide, Dentsply) and working canal length was determined using apex locator (Morita) (Fig. 3)

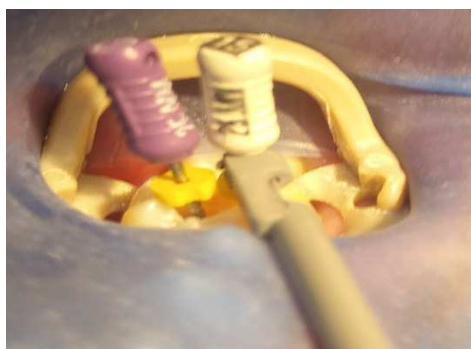

Figure 3. working length with apex locator

Diagnostic wire photo to confirm it. Both root canals has 20 mm length.. Cleaning and shaping were achieved using crown down pressureless with Endomotor (Dentsply, Maillefer). The root canal was prepared using Proglider, continued with protaper X3, it used canal lubricant, NaOCl 2,5% irrigation, Chlorhexidine, EDTA and aquadest. And then, gutta percha point was used to trial and confirmed with radiograph. (Fig. 4) Both canals obturated using single cone gutta percha with sealer (AH plus, Dentsply), then tooth were temporary filled and the patient was prescribed to reduce painful swelling.

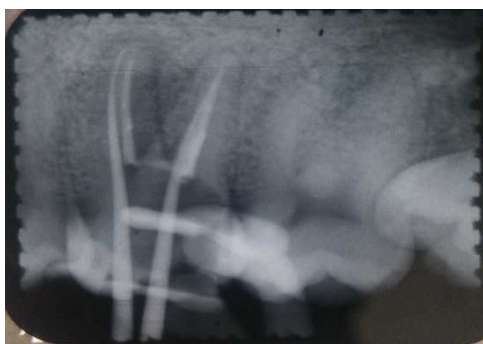


Figure 4 : Radiographic confirmation of trial guttapercha

Surgical treatment was planned with bicuspidization, the first thing should be done in these procedure was intra-oral asepsis used povidone iodine 10% on tooth area. Under local anesthesia using lidocaine 2%, the vertical cut method was used to separate the crown. A thin flame diamond bur was used to make vertical cut (bucco-lingual) toward the bifurcation area.(Fig.5) Radiographic was done to confirmed it .(Fig. 6) Patient was given analgesic prescription and post-operation instruction.

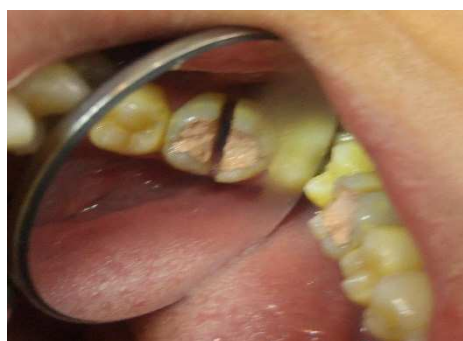

Figure 5.Separation the tooth

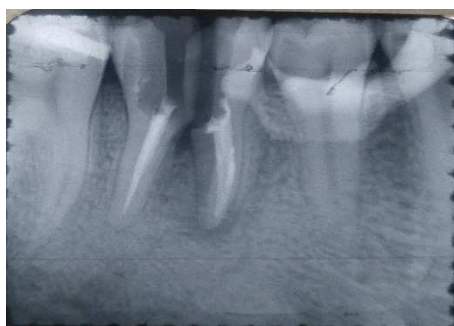

Figure 6. Radigraphic confirmation of separation

Seven weeks later, patient visited and there was no complaint on subjective examination and there were no gingival inflammation and no response for percussion and palpation test on objective examination.gutta percha point was reduced 2/3 of canal lenght or at least as long as crown lenght using drill from fiber post (LuxaPost, DMG) and confirmed with Radiographic (Fig. 7), after fiber post matched with the root canal, insertion was performed. The root canal was etched using phosphoric acid 37 % for 10 second and rised using aquadest. The root canal was dried using three-way syringe. The root canal and etched-fiber post was applied bonding agent before inserted fiber post into the root canal.Fiber post was insertd to the root canal using dual cure resin. The excess of resin was cleaned up and cured by light cure for 20 seconds.

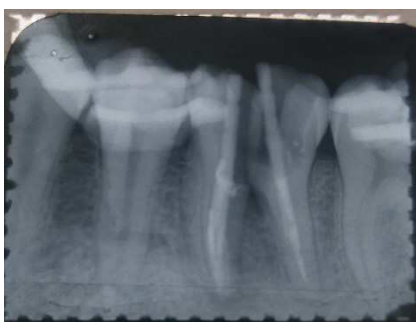

Figure 7. Inserted fiber post on radiographic

Fiber post was cementation, excess of fiber post was removed using diamond bur. core built up achieved using Muti-core (Ivoclar Vivadent) with layering technique to shape the crown (Fig.8)

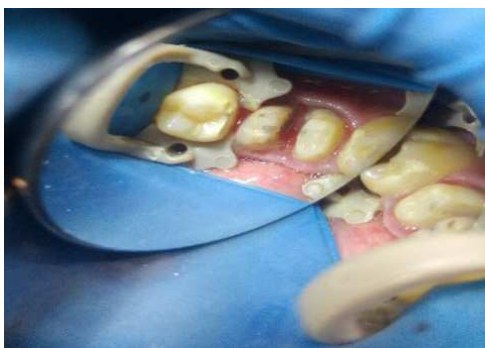

Figure 8.Preparation on both segments

The preparation started from choosing shade guide for tooth color. Gingival retraction was done before composite core build up. Tooth preparation was used round wheel bur on occlusal segmen and tappereed round-end diamond bur for chamfer preparation. After gingival management used retraction cord (#000 Ultrapack, Ultradent) and hemostate solution, 5 minutes later retraction cord was removed. Dental impression was made using elastomer with double impression technique and the maxiilla of which is antagonist with alginate and then registration check bite (Memoreg 2, Herraues). (Fig. 9)

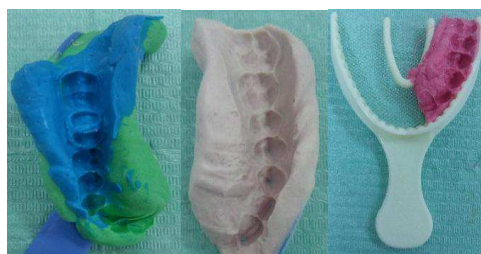

Figure 9. Final Impression

Good condition was shown on the next visit. Temporary crown was removed and residual cement from temporary crown was cleaned, then crown trial showed excellent crown self-retention, excellent anatomy and marginal integrity, moreover patient felt comfort. Therefore, PFM crown was attached using luting cement (Type I GIC, GC).(Fig.10) and it confirmed radiographically(Fig.11) Articulating paper was used to check articulation and occlusion.

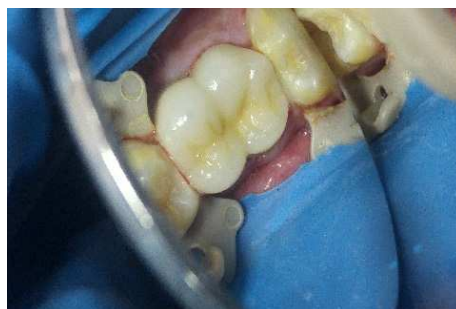

Figure 10. Inserstion the crown

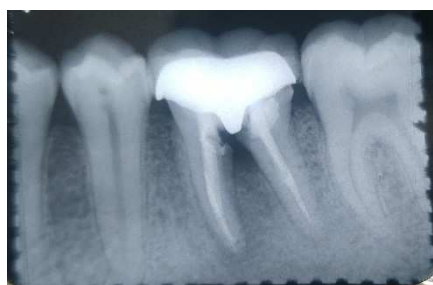

Figure 11.Confirmation Radiographic of insertion

Ten days post-crown insertion, there was no complaint and patient felt comfortable with his new tooth. For objective examination, there were no gingival inflammation, negative response on percussion and palpation test and there was no trauma occlusion. The patient *follow up periods at both 3 and 8 months showed clinical and radiographic favorable healing response and absence of symptoms*

DISCUSSION

Root canal treatment which is performed by the dentist, usually have errors or treat that may reduce the success of the treatment. There so many factor of root canal failure, one of them is furcation perforation, it makes prognosis of the treatment decreased⁵.

Treatment that can be performed to perforation cases is coronal approach technique. This technique aims to improve furcation area with a good material of biocompatibility and can induce calcific barrier repair for healing, but prognosis will be decreased if furcation perforation caused perforat which perfor more than 4 mm, it is due inflammation that may damaging periodontal tissue.⁷ Many failures in nonsurgical therapy due to retention plaques that are often present in the furcation areas that often cause periodontitis widespread rapidly.⁶

Bicuspidization is a technique that has the intention of dividing each root and crown segment from a tooth that has double

roots restored as if each root is a bicuspid root. When there is irreparable material or no repairable perforation in the furcation Bicuspidization, technique is indicated in Class II and III furcation involvements, and preferred to eliminate the irritans under the fornix⁸. Each case that is handled by each clinician has a different prognosis, a good prognosis of Bicuspidization depending on the condition and various factors and conditions. These factors are (1) the size of the defect in perforated bufurcation; (2) adequate stability and support for dental restorations; (3) Good contours on the separation area; (4) Adequate root separation; (5) allowing the embrassure area to play an effective role for maintaining good oral hygiene; (6) excess occlusal stress; (7) the accompanying periodontal disease. The Contraindications of bicuspidization are (1) The existence of deep furcation; (2) Restoration not possible; (3) The presence of periodontal disorder; (4) Root canal treatment can not be performed; (5) Fusion of the root.⁹

Prior to treatment bicuspidization should be carried out by the root canal and part of the separation of the mesial and distal portions of the tooth should be well restored. There is a very important thing to note on the root part of the root which is separated in the furcation area because the area is very vulnerable as retention plaque, so that the risk of caries is increased this greatly affects the success of the prognosis of treatment, in addition to root canal treatment should be done hermetic,

separation process, contour separation should also be smooth and crown shape to be inserted, so it does not become the path of bacteria to form a periodontal disease.¹⁰

The crown that will be inserted on the teeth aims to prevent the occurrence of tooth fracture. The margin crown area must reach apical on the pulp floor in the separated area. The poor condition of the restoration will lead to periodontal destruction. If there is a defect in the crown margin otherwise the occlusion contact and the proximal surface area contact should be excellent it is of particular importance to remove the destructive compression which may cause the occlusion trauma that will lead to the failure of the treatment.⁹

Case selection is needed in the treatment of this technique, the selection of patients with health status and attitudes, the use of medicinal drugs consumed. The most important after the bicuspidization treatment performed is to maintain oral hygiene. Patient must perform a good procedure in preventing the accumulation of plaque, especially in areas adjacent to furcation.¹¹

In this case report, the treated tooth has sufficient conditions for bicuspidization technique. This technique can be an alternative that should considered as a treatment option to restore the normal function of the teeth, since most practitioners prefer extracting the involved tooth, because they feel that the technique is quite complicated and complexes, and replacing it with fixed protheses or dental

implant.¹² Although in journals and case reports showing the success of dental implant installation, but patients also have to spend a greater cost.

CONCLUSION

In conclusion bicuspidization *is an effective treatment to preserve* the natural dentition which has been damaged to the extent of Iatrogenic furcation perforation.

REFERENCES

1. Andreasen FM, Andreasen JO, Cvek M. Root fractures. In: Textbook and Color Atlas of Traumatic Injuries to Teeth. Andreasen FM, Andreasen JO, eds. Copenhagen: Blackwell Publishing Ltd, 2007: pp337– 371.
2. Eleftheriadis GI, Lambrianidis TP. Technical quality of root canal treatment and detection of iatrogenic errors in an undergraduate dental clinic. *Int Endod J* 2005;38:72534.
3. Kvinnsland I, Oswald RJ, Halse A, Grønningsaeter AG. A clinical and roentgenological study of 55 cases of root perforation. *Int Endod J* 1989;22:7584
4. Behnia A, Strassler HE, Campbell R. Case Report: Repairing Iatrogenic Root Perforations. *JADA*. 2000;131:196-201.
5. Das, D., Das, U.K. and Maiti, N., 2015. SEPARATION TO SAVE A TOOTH: BICUSPIDIZATION. *Guident*, 8(5).
6. Arabaci, T., Çiçek, Y. and Güngör, H., 2012. Treatment of a complicated

- iatrogenic furcation perforation in a mandibular molar with bicuspidization technique: A case report. *Journal of Marmara University Institute of Health Sciences*, 2(3), pp.130-133.
7. Parmar G, Vashi P Hemisection: A case-report and review. *Endodontology*. 2003;15:26-29.
 8. Lemon RR. Nonsurgical repair of perforation defects. Internal matrix concept. *Dent Clin North Am*. 1992;36:439-457
 9. Dalkız, M., Çilingir, A. and Beydemir, B., 2008. Bicuspidization: a case report. *Gulhane Medical Journal*, 50(1), pp.042-045.
 10. Asha Ramesh, M.D.S., Delphine Priscilla, M.D.S., Julie Toby Thomas, M.D.S., Sheeja, S. and Varghese, M.D.S., 2015. BICUSPIDIZATION-TWINNING A MOLAR TOOTH. *International Journal*, 3(6), pp.28-30.
 11. Novaes Jr, A.B., Palioto, D.B., Andrade, P.F.D. and Marchesan, J.T., 2005. Regeneration of class II furcation defects: determinants of increased success. *Brazilian dental journal*, 16(2), pp.87-97.
 12. Al-Ali M, Aqrabawi J. Endodontic Surgery: A chance to rewrite history. *Smile Dent J*. 2007; 5: 13-20

LITERATURE REVIEW

THE ANTIBACTERIAL EFFECT OF A DIODE LASER ON *ENTEROCOCCUS FAECALIS* BIOFILM

Ayu Sandini, Ratna Meidyawati

Department of Conservative Dentistry, Faculty of Dentistry,
Universitas Indonesia
Email: meidyawati58@gmail.com

ABSTRACT

Failure to eliminate bacteria in the root canal, especially in the form of biofilms, causes unsuccessful of endodontic treatment. Root canal preparation, both mechanically and chemically using antibacterial agents in the form of irrigation and medication, often failing to kill *E. faecalis*. This is due to the ability of *E. faecalis* penetrate into dentine tubules and form biofilms that are more resistant to antibacterial agents. Along with the development of technology, there is a phototherapy system that brings a new breakthrough to perform root canal disinfection through the laser application. Diode laser is one type of laser that is widely used in dentistry. Some of the advantages of diode lasers are their small size, price range, and their wide use of applications for dentistry.

INTRODUCTION

Endodontic treatment is divided into three stages known as triad endodontics, which include access opening, root canal preparation, and complete obturation of the canal space. Primary goal of endodontic treatment is to eliminate polymicrobial infection, which is the main cause of periapical disease. ¹Bacteria that infect the root canal may be either planktonic or in biofilms.^{2,3} Primary endodontic infections are composed of a wide variety of bacteria that are mostly obligate anaerobes and less facultative anaerobes.⁴Obligate anaerobic

bacteria are relatively easy to eliminate by instrumentation, irrigation and medication procedures. While facultative anaerobic bacteria are more difficult to eliminate because of their ability to survive from a chemomechanical preparation.^{5,6}

There are about 150 species of microorganisms that can colonize in the root canal but only 10 to 30 species are known to the infected root canal. These microorganisms can also be found in the dentinal tubules and may cause root canal reinfection if not completely removed.⁷*Enterococcus faecalis*(*E.*

faecalis) is a bacteria that can be found in infected root canals that have not been done for endodontic treatment and can also be found in root canals with unsuccessful endodontic treatments.⁸In an in vitro test of 50 teeth that had undergone root canal treatment, Zoletti et al. (2006) found that 80% were infected by *E. faecalis*⁹. Additionally, Wang et al. (2012) observed an *E. faecalis* infection in 38% of the 58 teeth with poor root canal treatments that they studied and noted a higher prevalence in teeth with poor obturation¹⁰

Enterococcus faecalis have ability to penetrate into dentine tubules, reaching 1000 µm, faster than other pathogenic bacteria and have strong adhesion to collagen.¹¹*E. faecalis* is able to adapt to unfavorable conditions and lack of nutrients, and can accumulate to form biofilms. Biofilm is the aggregation of various microorganisms that secrete protective and adhesive exopolymeric matrices, EPS (Extracellular Polymeric Substance or exopolysaccharide). In the biofilm itself there is a quorum sensing mechanism, communication between bacterial populations of the same or different species.. Through this mechanism allows for the establishment of inter-species growth factors and exchange of information, causing bacteria present in the biofilm to become more resistant to phagocytosis by the body's defense cells and also resistant to antimicrobial agents commonly used during root canal procedures^{12,13}

Although there are different concepts and strategies for root canal preparation, there is mutual agreement on a chemo mechanical preparation that combines a chemical irrigant with a mechanical debridement using hand or rotary instruments¹⁴. Because of instrumentation alone is not enough to make root canal space free of bacteria, it is also necessary to add disinfection materials in the form of bactericidal irrigation solution. These Irrigant also serve to remove necrotic tissue, debris dentin and smear layer and as a lubricant.^{2,15}

The irrigation works in direct contact with the target and, to a limited extent, penetrates the root canal wall. Paque (2009) reported that areas remained unaffected after mechanical instrumentation using either rotary instruments or manual techniques¹⁶. The irrigant was therefore unable to reach and eliminate microorganisms from the inner side of the dentine layer¹⁷. This is the reason that a combination of a disinfectant solution with a supplementary irrigant is used^{18,19}.

Numerous antibacterial irrigants can be used in endodontic. A combination of chlorhexidine (CHX) and sodium hypochlorite (NaOCl) is the most commonly used endodontic treatment and is considered the golden standard. The first, CHX, is a wide-spectrum antibacterial agent that works on a lot of microorganisms, including *E. faecalis*. It is also recommended due to its substantivity, which leads to a longer therapeutic effect.

However, Mistry et al. (2012) found CHX to be cytotoxic in direct contact with human cells ¹⁴.

As endodontic technology has developed, research has been conducted on instruments and techniques with the ultimate goal of shortening working times and improving the effectiveness of root canal treatment. One of the latest technological innovations has been the use of lasers as supplementary tools to disinfect the root canal. A laser is a device that emits a monochromatic and coherent light. This high-intensity beam is effective and shortens the duration of root canal sterilization procedures. The laser's antibacterial effect depends on the amount of heat that the device generates ^{1,19,20}.

Lasers were first used in endodontic treatment procedures in 1980, and their use has expanded ever since. Diode lasers are the most commonly used lasers in dentistry ²¹. With wave lengths of 810 nm and 980 nm, diode lasers have a fiber diameter range of 200–600 µm. Gutknecht et al. demonstrated that a 980-nm-wavelength diode laser could eliminate bacteria from the inside of the canal space and even from deep inside the dentine tubules ²². Benedicenti et al. (2008) found that the use of a diode laser in addition to a conventional endodontic treatment increased the success rate of the treatment in vitro and significantly lowered contamination in the canal space. A diode laser is the primary choice because it is relatively more economical than other lasers and is easy to both use and transport ^{1,18}.

REVIEW

Enterococci is a normal flora of the human and animal digestive system, but it is also an important pathogen that can cause infection. Enterococci comprises more than 17 species, but only few can cause clinical infections in humans. *Enterococcus faecalis* and *Enterococcus faecium* are the most common species found in humans, leading to clinical infections. Common infections are urinary tract infections, endocarditis, bacteremia, infection associated with catheter insertion, wound infection, and intra-abdominal infections. Many of the strains that cause infection come from the patient's intestinal flora, spreading and causing urinary tract infections, intra-abdominal infections, and surgical wound infections. ²³

In dentistry, *E. faecalis* is an opportunistic pathogen commonly found in secondary and persistent endodontic infections. Secondary endodontic infections occur due to bacterial contamination during the endodontic treatment process. *Enterococcus faecalis* can be found in the oral cavity (10%), which is derived from the digestive tract, and is commonly found in planktonic form in saliva. A non-sterile root canal procedure will cause contamination of *E. faecalis* from saliva into the root canal. ¹⁰

Enterococcus faecalis is a Gram-positive, with a size of 0.5 - 1 µm. *Enterococcus faecalis* is also a facultative anaerobic bacteria that can grow in the presence of oxygen or without oxygen

(Figure 2.1). *Enterococcus faecalis* can be found as a single, paired, or short-chain bacteria. These bacteria can use various substances; carbohydrates, glycerol, lactate, malate, and citrate; to be a source of energy.^{23,24}

Enterococcus faecalis can survive in poor environments including in high pH (<11.5) and high salt concentration environments. *Enterococcus faecalis* can also grow at a temperature of 10°C to 45°C and survive at 60°C for 30 minutes.^{23,25}. The cell wall of *E. faecalis* contains a large number of peptidoglycan and antigen in the form of teichoic acid. The peptidoglycan is a crosslinking of peptide that help to overcome the cytoplasmic pressure and provide the shape and strength of the bacterial cell wall.^{23,26}

In the absence of nutrients, *E. faecalis* are able to maintain viability for several time and become resistant to heat, sodium hypochlorite (NaOCl), hydrogen peroxide, ethanol, and acids. In addition, *E. faecalis* can also enter a defensive state but cannot be multiplied (viable but not cultivable). This mechanism was adopted from a group of bacteria when exposed to a bad environment, and recovered when conditions improved. The ability of *E. faecalis* to adapt and adverse environmental conditions may benefit other species to settle in a biofilm.^{23,24,27}

In root canal space, *E. faecalis* is able to survive even in nutritional deficiencies. This is consistent with the study of Sedgley et al. (2005) that inoculated bacterial

suspensions directly into the bovine root canal, thus allowing bacterial growth into the dentin tubule through the root canal. After 48 hours of non-nutritional condition on the root surface, there was a description of the penetration of *E. faecalis* bacteria into the dentin tubule to a depth of 300 - 400 µm. In addition, *E. faecalis* is also able to maintain viability for 12 months without any additional nutrients. The ability of *E. faecalis* to survive in this bad environment, because *E. faecalis* has various virulence²⁷.

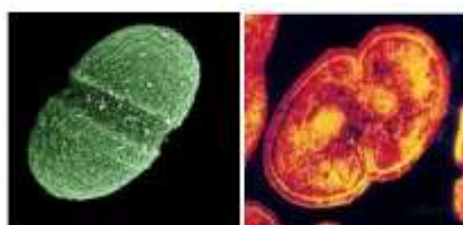


Figure 1. Thin Section *E. faecalis* in planktonic form (TEM magnification 33000)²³

The various virulence factors possessed by *E. faecalis* play a role in the process of attaching bacteria to the host tissue and then invading it, the secretion of products that can form biofilms, modulate the inflammatory response and the formation of the abscess. These substances include aggregate substances (SA), surface protein chromosomes namely enterococcus surface protein (Esp), gelatinase (GeIE), cytolytic toxin, lipoteichoic acids (LTA) and collagen binding protein (Ace).^{12,18,26,28}

The aggregate substance (SA) of *E. faecalis* is an adhesin that helps contact

between cells and facilitates the exchange of plasmids between recipients and donors. This allows the transfer of antibiotic resistance properties between *E. faecalis* and other species. Aggregate substances can also modify the phagosomal maturation of PMN and macrophages so that PMN and macrophages cannot kill bacteria.^{10,29}

Lipoteichoic Acids (LTA) in bacterial cell membranes, allow *E. faecalis* to colonize and attach to the mineral part of the tooth, triggering bacterial attachment to PMN cells and red blood cells. This LTA triggers the release of hydrolase acids, proteinases, bactericidal cationic peptides and growth factors and also triggers the release of cytokines from PMN and microphages. *Enterococcus faecalis* also has protein adhesion such as collagen binder (Ace) and enterococcus surface protein (Esp). These adhesion proteins mediate bacterial attachment to the host tissue and play a role in biofilm formation. Esp is thought to have a role in retreating the protein from the surface of the bacteria so that it is hidden from the immune system.²⁴

Biofilms are cell populations attached to the surface and incorporated in the matrix of exopolymeric substances, polysaccharides, proteins, nucleic acid DNA. Biofilm formation is a complex process consisting of adhesion to surfaces, interactions between cells, microcolonial formation, early biofilm formation and the establishment of a three-dimensional biofilm structure (Figure 2). Bacteria in

the biofilm will be more than 1000 times more resistant and phagocytic processes, the nutrients are more concentrated and facilitate communication between bacterial in the same or different populizations.³⁰

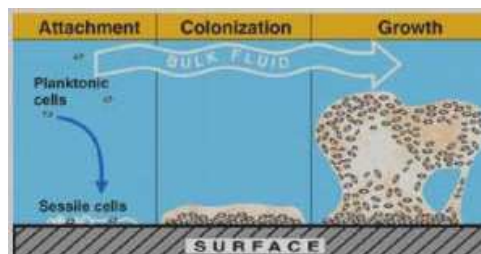


Figure 2. Biofilm Formation onTooth Surfaces.¹²

Several factors affecting bacterial attachment to the substrate are the surface energy of the substrate, temperature, pH, fluid flow rate passing through the substrate, the length of bacteria in contact with the substrate, surface hydrophobicity and nutrient availability. The surface structure of bacteria that plays an important role in bacterial attachment is pili, flagella and EPS. Adhesin or ligand in bacteria will bind to receptors on the substrate. In the third phase occurs the multiplication and metabolism of bacteria inherent and form a complex community. In this phase there is biofilm maturation..^{24,30,31}

Biofilm formation is regulated by quorum sensing system by some pathogenic bacteria. The formation of biofilms is influenced by physiochemical factors, which consist of layers of substrate and planktonic bacteria that will be attached to the substrate layer. A nutrient-

rich environment, with both aerobic and anaerobic conditions, produces a biofilm structure with bacterial aggregates located on the surface with a water channel. While in minimal nutritional conditions, biofilms that form, like irregular clumps of cells.

Factors affecting biofilm formation are nutrient content in growth medium, serum, iron, carbon dioxide, pH and temperature.²⁴ Changes in osmotic pressure also affect the formation of *E. faecalis* biofilms. Isolate *E. faecalis* that produces extracellular polysaccharides so as to produce biofilms is more susceptible to macrophages than isolates that do not produce biofilms. In anaerobic and nutrient-rich conditions, *E. faecalis* showed a mature biofilm with water channels on the root canal wall.^{30,32}

LASER is an acronym of light amplification by stimulated emission of radiation. The laser is a form of energy in the form of particles called photons and moves in waves. Each wave of photons has three basic properties: velocity (light velocity), amplitude (energy of wave) and wavelength (horizontal wave measurement).³³ Lasers are generated by the medium present in the tube. The medium may be gas, crystal or liquid. After the energy is given, the photons will move and are reflected by two mirrors present at each end of the tube. This reaction continues to move forward and backward. In one mirror there is a small hole so that the laser light can come out. The outgoing laser light is then delivered through optical fiber (*fibre optic*).³³

Laser Diodes are one of the most widely developed types of lasers in dentistry (Figure 3). Some of the advantages of diode lasers are their small size, price range, and wide use of dental treatment applications.^{28,31} The relatively small size of the diode laser provides benefits for the relatively small area of the workspace, easy to carry and move, and relatively light. In addition, the diode laser has a more affordable price range than any other laser system.³⁶ Another advantage of diode lasers is its short application time, requiring only a few seconds for the laser beam to be emitted after the laser system is turned on. In general, other laser systems require several minutes to reach the ready condition to emit light. Electricity consumption of diode lasers is also small compared to other laser systems, it can be said to be more efficient and play a good role against environmental protection.^{18,33}

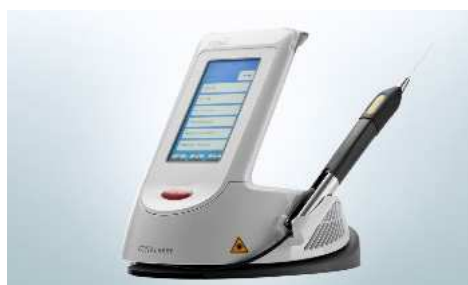

Figure 3. Diode Laser

The diode laser is a type of laser with an active medium of semiconductor, having four different wavelengths, 810nm, 940nm, 980nm and 1064nm. The laser light of the diode is channeled through the plastic fibers and concentrated at the ends

of the fibers causing a heat effect. Laser diodes can be used in various dentistry procedures. Generally used in soft-tissue therapy procedures such as surgery and periodontal pocket therapy, but also can be applied to procedures involving hard tissues such as teeth. One is in endodontic treatment such as root canal disinfection.³⁷

Laser diodes can convert electrical energy into light using the same principle as other types of lasers, but with internal reflection capabilities that give rise to resonators, the stimulated light can be reflected back to front and backwards so that only certain wavelengths can be generated.^{28,34,38} The active medium used in diode lasers is solid, such as GaAlAs (Gallium Aluminum arsenate). Due to the crystalline nature of the active medium, the crystal tip can be selectively polished for the internal refractive index resulting in a total or partial reflection surface. This provides the same functionality as an optical resonator in a larger laser system (figure 4).³⁸

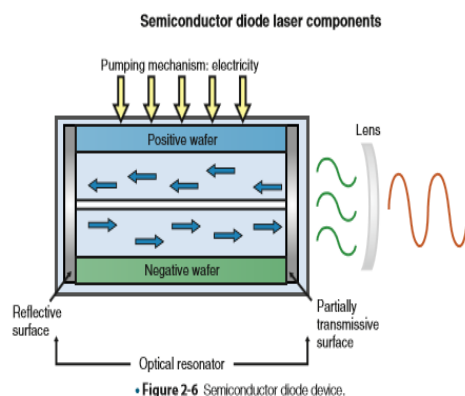


Figure 4 Semiconductor Component In Diode Laser³⁸

Laser diodes use flexible glass fibers to channel energy to the desired target tissue area. Generally, these flexible glass fibers are incorporated into the handpiece. Some things to consider when using glass fiber, such as the selection of fiber diameter to be used. The flexible glass fiber in the diode laser is available in diameters of 200-320 μm . The diameter affects the light energy emitted by the diode laser system. In addition to diameter, which is worth noting is the speed of movement of the fiber end during treatment. Burned networks are an unwanted side effect due to excessive force or movement of the fiber ends too slowly. Glass fibers can be driven 1-2 mm with a light vibration such as using a brush and move quickly when working on soft tissue.^{11,38}

Debris can accumulate on the glass fiber end during treatment and this causes the tip of the fiber to become very hot and act as a cutting iron. This can cause unwanted tissue heating and lead to additional damage. Therefore, the flexible glass fiber condition should be routinely checked, if the fiber end becomes blacker then a 2-4 mm cut from the fiber ends.^{33,38}

As with other types of lasers, in laser diodes, the effects of rays on a target cell or network rely on the formation of molecules that then react with tissue molecules.³³ There are 4 types of laser light interaction with target tissue: reflection, absorption, transmission and scattering as shown in Figure 5.³⁸ These four interactions depend on the optical properties of a network

such as water content, presence or absence pigmentation and wavelength of the laser light used. In the reflection properties, the laser beam is reflected by collimated and diffuse light properties without having any effect on the target tissue. In some cases, the nature of this reflection may be dangerous because the laser energy may change direction of the eye or another area of tissue.

The second interaction of laser-tissue is absorption. The laser energy absorbed by the target tissue is a less favorable laser trait. The nature of this absorption resulted in weakening of the strength of light and the reaction between the photon with the material that passes. Transparent water cannot absorb the energy emitted by diode type lasers and Nd; YAG. Therefore this interaction becomes the basis of consideration of the selection of a type of laser to the target network. The third effect is transmission. The transmission effect is strongly influenced by the wavelength of the laser light used. And the last interaction is scattering or spreading laser energy. This interaction is advantageous because it can diffuse the radiated power emitted.³⁸ The direction of the photon can be spread so that heat transfer to the target tissue through the medium passes through the ray, as shown in illustration of figure 5 and figure 6.³³ Through the reflection, transmission and dissemination, allowing photons to pass through a material without damaging the tissue. However, when the photon is absorbed, it allows the physical

or chemical reaction between the laser and the tissue.

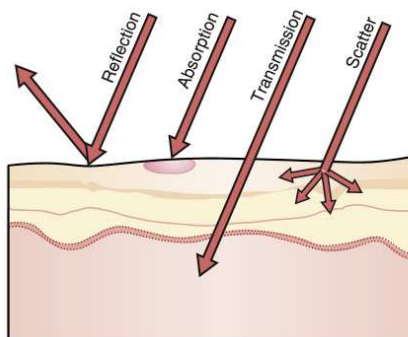


Figure 5 Potential Laser-tissue Interactions³⁸

In endodontics, several studies have suggested that the effectiveness of laser diodes against root canal disinfection is not much different from the solid-based laser system Nd: YAG.^{37,39,40} It is found by testing the bactericidal effect of diode laser and Nd: YAG against *E. faecalis*. The glass fiber diameter used in laser diodes is capable of effectively channeling laser light on the root canal system to reduce bacterial contamination. Antibacterial effects are seen to reach 1 mm into the dentine, far exceeding the ability of chemical disinfectants such as NaOCl irrigation materials. This shows the effectiveness of antibacterial effect of *E. faecalis* even to the deeper layers of dentine.³³

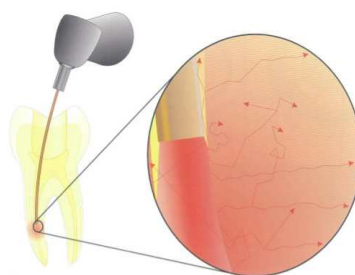


Figure 6 Scattering effect on Dentin.³³

The laser directly acts as an effective adjunct irrigant in the process of root canal disinfection. The laser beam penetrates into the canal space which irrigation solutions cannot reach such as the accessories root canal and deep dentin tubules. The antibacterial effect of diode laser is obtained by ionic reactions and the resulting heat (photothermal).^{34,35} Although laser light is weakened, the bactericidal effect can be maintained because enamel or dentine tubules act as light conductors.⁴² Several study of diode lasers with different parameters shows that the diode laser can effectively reduce intracanal bacteria and penetrate to a depth of 500 µm into the dentin.

The diode laser application is by gently moved of the fiber, in a circular direction with a spiral-shaping motion from the apical direction to the coronal root canal during laser operation. The procedure is repeated four times for five seconds. Always pay attention to moving the glass fibers that deliver the light at the tip of the fiber. This is to prevent the increase in surface temperature of teeth that can damage the tissues around the teeth. If required, treatment with the laser beam of this diode may be repeated after three to seven days, but not more than twice overall. Power strength should be set at 1-1,5 W.^{37,41}

CONCLUSION

The main goal of endodontic treatment is to remove all infected or necrotic

pulp tissue, bacteria and endotoxins from the root canal system. Root canal treatment consists of three stages known as endodontic triads ie access opening, root canal preparation and obturation. The root canals have complex anatomy and can complicate mechanical cleaning with endodontic instruments, consequently root canal preparation with mechanical instrumentation alone will only partially reduce bacteria from the root canal.

Failure to eliminate bacteria in the root canal, especially in the form of biofilms, causes the failure of endodontic treatment. The most common bacteria found in cases of unsuccessful endodontic treatment is *E. faecalis*. Root canal preparation mechanically and chemically using antibacterial ingredients in the form of irrigation and medication, often failing to kill *E. faecalis*. This is due to the ability of *E. faecalis* penetrate into dentinal tubules and form biofilms that are more resistant to antibacterial agents. Much research has been done to find the most effective way of removing *E. faecalis* from root canals, one of which is by irrigation of root canals.

Along with the development of technology, there is a phototherapy system that brings a new breakthrough to perform root canal disinfection is through laser applications. Endodontic laser applications have been introduced since 1980 and the number of users has continued to increase to date. Some studies say that the laser is able to lift the smear layer from the root canal space and has a bactericidal effect

on pathogenic bacteria grown in the root canal. Nevertheless, the effectiveness of laser use in clinical reporting is still.

REFERENCES

1. Beer F, Buchmair A, Wernisch J, Georgopoulos A, Moritz A. comparison of two diode lasers on bactericidity in root canals-an in vitro study. *lasers med sci*. 2012;27:361-364.
2. Napte B, Srinidhi S. Endodontic Irrigants. *J Dent Allied Sci*. 2015;4(1):25. doi:10.4103/2277-4696.167536.
3. Shrestha A, Zhilong S, Gee NK, Kishen A. Nanoparticulates for antibiofilm treatment and effect of aging on its antibacterial activity. *J Endod*. 2010;36(6):1030-1035. doi:10.1016/j.joen.2010.02.008.
4. *Origin Of Intraradicular Infection With Enterococcus Faecalis In.*; 2015.
5. Ricucci, D, bergenholtz G. Bacterial status in root-filled teeth exposed to the oral environment by loss of restoration and fracture or caries--a histobacteriological study of treated cases. *Int Endod J*. 2003;36(11):737-802.
6. Saber, Shehab el-din muhamed, el-hady soha. Development of an intracanal mature *Enterococcus faecalis* biofilm and its susceptibility to some antimicrobial intracanal medications; an in vitro study. *eur j den*. 2012;6(1):43-50.
7. Philip Lumley Phillip Tomson Nick Adams. *Practical Clinical Endodontics.*; 2006.
8. Kaufman B, Spångberg L, Barry J, Fouad AF. *Enterococcus* spp. in endodontically treated teeth with and without periradicular lesions. *J Endod*. 2005;31(12):851-856. doi:10.1097/01.don.0000164133.04548.26.
9. Zoletti GO, Carmo FL, Pereira EM, Rosado AS, Siqueira JF, Santos KRN. Comparison of endodontic bacterial community structures in root-canal-treated teeth with or without apical periodontitis. *J Med Microbiol*. 2010;59(11):1360-1364. doi:10.1099/jmm.0.018887-0.
10. Wang Q-Q, Zhang C-F, Chu C-H, Zhu X-F. Prevalence of *Enterococcus faecalis* in saliva and filled root canals of teeth associated with apical periodontitis. *Int J Oral Sci*. 2012;4(1):19-23. doi:10.1038/ijos.2012.17.
11. Moritz A. *Oral Laser Application*. (Moritz Andreas, ed.); 2006.
12. Paath SL. Universitas Indonesia Daya Antimikroba Air Berozone , Klorheksidin Dan Natrium Hipoklorit Terhadap *Enterococcus Faecalis* (In Vitro) Daya Antimikroba Air Berozone , Klorheksidin Dan Natrium Hipoklorit Terhadap *Enterococcus Faecalis* (In Vitro). 2010.
13. Cardoso MG, Oliveira LD, Kogo-Ito CY JA. Effectiveness of Ozonated

- Water on *Candida Albicans*, *Enterococcus faecalis* and endotoxins in root canals. *Oral Surg Oral Med Oral Pathol Oral Radiol endod.* 2008;105:85-91.
14. Deivanayagam Kandaswamy and Nagendrababu Venkateshbabu. Root canal irrigants. 2010;13(4):256-264.
 15. Amelia N. Pengaruh Teknik Irigasi Ultrasonik dan Manual terhadap Kebersihan Dinding Saluran Akar Pada Daerah Sepertiga Apeks. 2011:8-71.
 16. Bago I, Plecko V, Panduric d g, Schauerperl Z, Baraba A AI. Antimicrobial efficacy of a high-power diode laser, photo-activated disinfection, conventional and sonic activated irrigation during root canal treatment. *Int Endod J.* 2013;46:339-347. *Int Endod J.* 2013;46:339-347.
 17. Mehrvarzfar P, Saghir M, Asatourian A et al. Additive effect of a diode laser on the antibacterial activity of 2,5% NaOCl, 2% CHX and MTAD against *Enterococcus faecalis* contaminating root canals: an in vitro study. *J Oral Sci* 2011;53(3):355-360. 2011;53.
 18. Dewa Ayu NPA, Boy M Bachtiar SMSA. Quantitative real-time PCR of cps Type 1,2 and 5 of *Enterococcus faecalis* and *Candida albicans* Isolated from Infected Root Canal of Subject Requiring Endodontic Treatment. *J Int Dent Med Res.* 2016;9(3):157-163.
 19. Shajahan PA, Ranjith Kumar P, Hariprasad A, Mathew J, Shaji AP, Fazeel M. Lasers : The Magic Wand in Esthetic Dentistry. *J Int oral Heal Int Soc Prev community Dent.* 2015;7(April):119-121.
 20. Banerjee S, Pal sreya PT. Low level laser therapy (lllt)- a boon to dentistry. *guident.* 2015:62-64.
 21. Coluzzi D, Convissar R RD. *Laser Fundamentals. In: Convissar R, Ed. Principles and Practice of Laser Dentistry. 2nd Ed.;* 2016.
 22. Gutknecht N, Franzen R, Schippers M, Lampert F. Bactericidal effect of a 980-nm diode laser in the root canal wall dentin of bovine teeth. *J Clin Laser Med Surg.* 2004;22(1):9-13. doi:10.1089/104454704773660912.
 23. Stuart CH1, Schwartz SA, Beeson TJ OC. *Enterococcus faecalis*: its role in root canal treatment failure and current concepts in retreatment. *J Endod.* 2006;32(293-8).
 24. McHugh CP1, Zhang P, Michalek S EP. pH required to kill *Enterococcus faecalis* in vitro. *J Endod.* 30(4):218-219.
 25. Stuart CH, Schwartz SA, Beeson TJ OC. *Enterococcus faecalis* : Its Role in Root Canal Treatment Failure and Current Concepts in Retreatment. *JOE.* 2006;32(2):93-98.
 26. Portenier I, Waltimo TMT, Haapasalo M. *Enterococcus faecalis*- the root canal survivor and “star” in post-treatment disease. *Endod Top.* 2003;6(1):135-159. doi:10.1111/

j.1601-1546.2003.00040.x.

27. Sedgley CM1, Lennan SL AO. Survival of *Enterococcus faecalis* in root canals ex vivo. *Int Endod J*. 2005;38(10):735-742.
28. Arlyta P. Daya Antibakteri Kitosan 2% dan Klorheksidin 2% terhadap *Enterococcus Faecalis* dalam Biofilm. 2014;(November):41-43.
29. Sundqvist G, Figdor D. Life as an endodontic pathogen Ecological differences between the untreated and root-filled root canals. *Endod Top*. 6(1):3-28.
30. Gary M. Dunny, Lynn E. Hancock and NS. *Enterococcal Biofilm Structure and Role in Colonization and Disease*.
31. Mohamed JA1 HD. Biofilm formation by enterococci. *j med microbiol*. 56:151-158.
32. Di Filippo G, Sidhu SK, San Chong B. The role of biofilms in endodontic treatment failure. *Endod Pract Today*. 2014;8(Table 1):87-103.
33. Moritz, A. ; schoop U. lasers in endodontics. In: *Oral Laser Application*. berlin: quintessenz verlags-GmbH; 2006:241-277.

CASE REPORT

MANAGEMENT OF CRACK TOOTH SYNDROME ON VITAL TOOTH MAXILLARY LEFT FIRST MOLAR

Laili Aznur*, Irmaleny**

*Bagian Konservasi Gigi Rumah Sakit Umum Pusat Hasan Sadikin Bandung

**Kepala Bagian dan Staf Pengajar Konservasi Gigi Fakultas Kedokteran Gigi
Universitas Padjadjaran Bandung

Email: lailiaznur@yahoo.com

Hp: 081221353896 / 08119474333

ABSTRACT

Background: Crack tooth syndrome is a toothache caused by a broken tooth (tooth fracture) without associated cavity or gingival disease. Cracked tooth syndrome is most common in molars and usually due to chewing or biting hard objects. Biting on the area of tooth fracture can cause severe sharp pains and pulp damage. The treatment usually is to protect the tooth with a crown. However, if placing crown does not relieve pain symptoms, a root canal procedure may be necessary. The fracture may be so severe as to require removal of the tooth. **Case:** A woman 37 years old came to endodontist clinic at Hasan Sadikin General Government Hospital and complained his tooth was crack on crown of maxillary left first molar. The tooth almost split in two with reddish gum around the tooth. The tooth was sensitive when touched or chewing food. **Management:** At first visit, fixation on tooth 16 has done, the tooth was tied by a metal band and then cemented using a glass ionomer cement. Furthermore, the tooth was removed contact with the lower teeth. Patients were given antibiotics and analgesics for one week. Subsequent pulpectomy was performed with 4 times of medicament replacement using Ca (OH) and filling of root canal using guttapercha and sealer endomethason. Porcelain Fuse to Metal restoration was selected as a final restoration using a fabricated metal pin on three root canals. **Conclusion:** Evaluation one year after treatment showed good results, no complaints and the patient was satisfied with his tooth condition.

KeyWords: Crack tooth syndrome, pulpectomy, fabricated metal pin, porcelain Fuse to Metal

INTRODUCTION

Cracked tooth syndrome is a dental disease caused by a ruptured tooth (fractured tooth) without any connection to cavity or other gum disease. The tooth syndrome of the crack has symptoms with an incomplete fracture (infracture) feature on vital teeth that affect dentin or enamel and occasionally extends to the pulp.^{1,2} Dental crack syndrome often occurs in posterior teeth, especially in the molar 1 and lower 2 molar teeth. Sharp pain in the absence of clear signs, is a clinical symptom of crack syndrome. Patients often have a history of protracted pain with varying degrees of pain. Crack on the teeth can cause a momentary discomfort, until severe and chronic pain.^{1,2,3}

Cracks in teeth may occur in both horizontal and vertical directions involving the crown and / or roots. The etiology is generally excessive occlusal force, developmental defect or restoration procedures. The symptoms depend on the depth and direction of the crack and the injured tissue.^{1,2,3}

Teeth with developmental disorders will be more susceptible to crack in normal occlusal loads or with a slight increase in mastication pressure. Improper restoration procedures, can damage tooth structure. Normal occlusal contacts occur in large occlusals or in proximal-occlusal intracoronal restorations in order to prevent the remaining tooth tissue from cracking. The deep cusp-fossa relationship due to excessive carving, or putting a restoration

ending without proper consideration to protect the cusp also makes the teeth brittle.^{1,2,3}

Excessive carving during restoration, and the loss of normal occlusal contact can lead to extrusion of the antagonist tooth, alter the cusp-fossa relationship and produce fractures in non-functional cusps. Fractures of the cusp, both functional and non-functional, are due to large intracoronal restorations and carious lesions. Another cause of cracked tooth syndrome is iatrogenic including excessive hydraulic pressure induced into luting the crown or bridge. Bridge used in the long run using too much torque on the tooth of the boundary affects the occurrence of cracks. Other common causes are accidents during mastication such as biting on hard and rigid bodies with very high strength or excessive dental structure disposal during preparation. Para-functional habits such as bruxism are also associated with cracking. Thermal cycles and destructive horizontal strength or parafunctional habits are also involved in the process of cracking on his special enamel on un-restored teeth.^{1,2,3}

CASE

A 37-year-old woman came to the Dental Conservation Specialist clinic of Hasan Sadikin General Hospital Bandung to treat upper right molar teeth. The tooth is severe pain continuously, especially if there is cold or hot stimulation. Increased pain is felt when eating or when touched. This situation was felt \pm 1 day ago. Bad

habits bruxism patients, this can be seen on the anterior teeth of the lower jaw atrisi. The result of the objective examination showed that Region 16 experienced Mesial-Distal crack (Split Tooth). Percussion and positive pressure, positive cold test, soft tissue around the hyperemic tooth. Radiographic examination of widening of the Mesial-Distal periodontal ligament of Mesial-Distal dental crack and teeth has never been performed root canal treatment (Figure 1)

Public health is good. History of heart disease, hypertension, diabetes mellitus, lung disorders, blood disorders and allergies are denied.

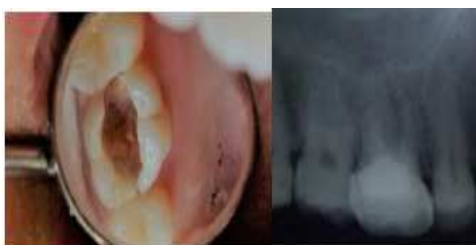

Figure 1. Crack Mesial – Distal Tooth

The dental diagnosis is acute irreversible pulpitis with gingivitis. Prognosis is bad because crack ends disubginggiva. The patient wants the 16th gear maintained and willing to be restored with a fuse to metal porcelain with a fabricated pin on three root canals. Patients cooperative, no systematic abnormalities and dental conditions can still be done root canal treatment.

The first visit was onsubjective and objective examination and radiographic examination on the tooth 16. The patient

performed the informed consent signature, after which the patient described the condition of the tooth with a poor prognosis. This type of treatment is vital pulpectomy and restoration finally porcelain fuse to metal with peg fabricated on the three channels.

Dental treatment 16 begins with an anesthetic of infiltration in buccal as much as 1 cc and in palatal as much as 0.5 cc. Fixation of the tooth region by binding the dental crown using a metal band cemented to the tooth (Fig. 2). Teeth 16 removed its contact with its antagonist teeth. On this first visit, cavity access preparations were made directly using bur endo access to the three root canals. The pulp chamber is cleaned with an excavator. Root canal assessment is done on the distal root canal, buccal mesio and buccal distto to obtain the glide path using the K-file needle # 8. Root canal preparation is done by crown down technique using one shape rotary system. Measuring the length of work with Apex Locator, obtained 23 mm long palatal work, 20 mm buccal mesio and buccal distal 18 mm. Then the root canal is irrigated using Maxi Probe Endodontic Irrigation Probe. The irrigation solution used 2.5% NaOCl and 0.12% chlorhexidine.

Each change of irrigation files with NaOCl 2.5% and Chlorhexidine 0.12%. The tooth is then dried with a paper point and Ca (OH) 2 application into the root canal as an intracanal medicament. Close the cavity with Glass Ionomer Cement.

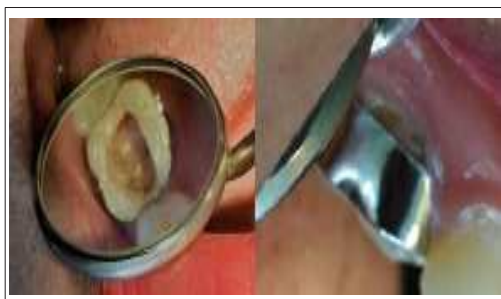

Figure 2. Binding of the Dental Crown Using Metal Band

Second visit is done after 2 weeks, patient still feel pain, on objective examination, percussion test, test, press give positive response. Temporary fillings are opened, then the calcium hydroxide paste is opened and looks wet and dirty. The root canal was irrigated using 2.5% NaOCl solution and 0.12% Chlorhexidine which was activated by sonic power using endo activator. The root canal is cleaned with a paper point. Apply calcium hydroxide paste, cover restoration with Glass Ionomer Sement.

Third visit after 2 weeks, no patient complaints, and on objective examination, percussion test, pressure test give negative response. Temporary fillings cleaned, calcium hydroxide paste looks clean but still wet. The root canal was irrigated using 2.5% NaOCl solution which was activated by sonic with endoactivator and ended with 0.12% Chlorhexidine solution. The root canal is dried with a paper point. Apply calcium hydroxide paste, cover with Glass Ionomer cement.

Fourth visit 2 weeks later, the procedure is the same as on the third visit.

At the fourth visit, the calcium hydroxide paste was dry and clean. The fourth visit still applied the calcium hydroxide paste and cover with Glass Ionomer Sement (Figure 3).

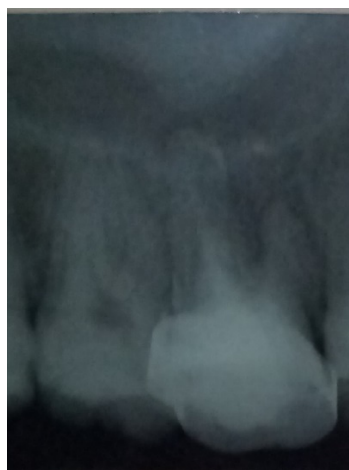

Figure 3. Intracanal Medicament Radiography Ca(OH)_2

The 5th visit of October 2, 2014, was carried out by filling the root canal after an objective examination, percussion tests and press tests gave negative responses. Calcium hydroxide paste in a dry and clean state. The root canal was then irrigated using 2.5% NaOCl irrigation solution, chlorhexidin 0.12% and activated with sonic energy using endoactivator and dried with paper point. Performed a rosent photo of the charging trial with the main cone and the main con's look corresponding to the working length. The root canal is then filled with guttaperca with lateral condensation technique and the sealer material used is endomethason The filler is cut $\pm 1\text{mm}$ from the orifice and is grounded using Glass ionomer and then closed with a temporary fill. Performed photos of filling and visible

charging has been in accordance with the length of work and hermetic. (Figure 4).

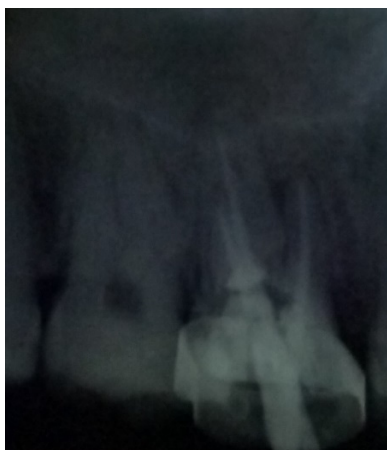

Figure 4. Trial Radiography

On the sixth visit after one week, the filling controls were performed by subjective, objective checks. On subjective examination there were no complaints while on objective examination conducted percussion test and press test and give negative response. Follow up to be done is the installation of fabricated pins and porcelain crown making. On the seventh visit, a post-filling week is done with the installation of a fabricated pin on the 16th gear. Largo drill number 2 is used for guttaperca cutting. The root channels were irrigated 2.5% NaOCl and 0.12% chlorhexidine were activated using sonic power using endoactivator and dried with paper point.

The root channel is etched for 20 seconds then rinsed with saline solution and dried. Pin fabricated using ceramix etching, special etching for metal. The dual cure self-adhesive resin cement is inserted into the root canal with a special tip and then the

fabricated pin is inserted into the root canal with its gently thread rotated to its proper position and locked. Posterior composite placement with sonicfill composite system after semented peg fabricated. Figure 5.

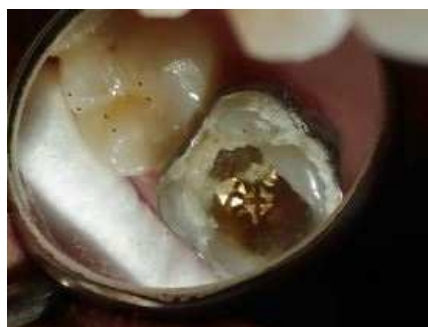

Figure 5. Pin Fabricated Cementing

At the eighth visit after one week post-completion, subjected to subjective examination found no complaints from the patient, objective examination in the form of percussion test, press test and unsteadiness gave negative response. Bands on the 16th gear were removed and porcelain crown preparations were performed.

On the ninth visit, be prepared to do a try in crown fuse metal porcelain. At the time of try in did not find any trauma occlusion. Conducted cement porcelain fuse metal crown. The cement resin cement material is inserted into the porcelain crown and mounted on the core and pressed slowly to the crown just in position. Excess cement cleaned. (Figure 6)

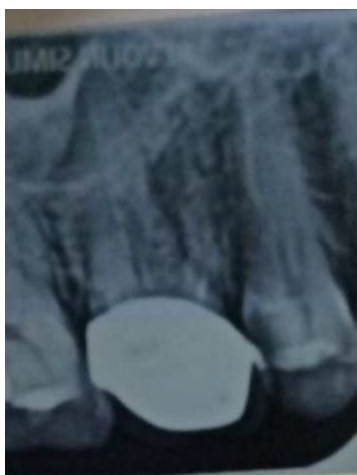

Figure 6. Crown Fuse Metal Porcelain
Cementing

The tenth visit was a week of porcelain crown restoration control. On subjective examination found no complaints from patients. In an objective examination the porcelain crown was observed in good adaptation, no abnormalities in the gingiva, percussion test (-), press test (-), and no premature contact with antagonist teeth (Figure 7).

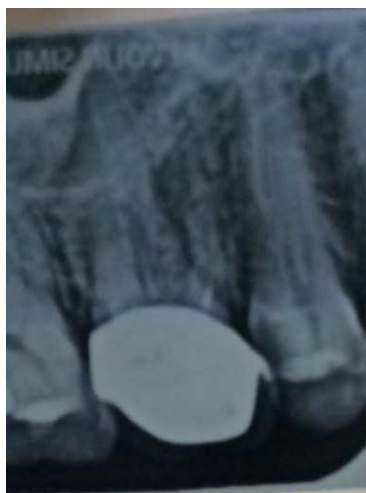

Figure 7. Control After 2 Years Treatment of
Cracked Tooth Syndrome

DISCUSSION

The dental syndrome of the crack is a group of symptoms characterized by an incomplete fracture of the vital teeth that affect the dentine and tooth enamel and at times widen to the pulp. In this case, the crown fracture of the tooth 16 is caused by the functional function of the patient in the form of bruxism, seen in the anterior mandibular atrial. Crack 16 gear experienced by patient 1 day before.

In the 16th gear, the type of crack that has been separated (split tooth), can be reunited again the roots immediately carried binding crown with the ring and then treated the root canal and covered with cement glass ionomer.^{3,4,5}

Teeth that crack and have done root canal treatment structurally differ with vital tooth structure. Characteristic changes especially loss of tooth structure. Changing this tooth structure may result in the tooth becoming weaker so that it needs pegs and cores as retention of the full crown.⁶

Pulp chamber disposal in endodontic treatment causes the tooth to require both internal and external support therefore the crown peg becomes an indication (Weine, 2004). In this case the fabricated peg is used as retention of the porcelain fuse metal crown. The stake retention is fabricated on the cracked tooth of the thread because it binds actively to the root canal wall. The cementation on the stake is fabricated for fixation not to shake.^{7,8}

Posterior use with sonicfill composite system, reduces the clinical step by incremental patching, reduces porosity and establishes consistent fillings resulting in short clinical time and patient costs. The making of a porcelain fuse metal crown is performed after an evaluation of 2-3 weeks as important as fabricated pegs. If it is cured the removable ring is replaced with a temporary crown made of acrylic. After a month of good condition, the temporary crown is replaced with a permanent crown. The stage of porcelain cementation has an important role in the success of porcelain. Good attachment depends on the action before cementation.⁹

CONCLUSION

Evaluation one year after treatment showed good results, no complaints and the patient was satisfied with his tooth condition

SUGGESTION

Every dentist should know the tooth syndrome crack and this condition becomes a consideration when the patient complains about the pain / discomfort when chewing / chewing without visible damage.

REFERENCES

1. John MK, Parameshwaran M, Vidya S, Sreeja S, Kiran, and Prabhu S. 2015. *Cracked Tooth Syndrome*. A Review. J. Recent Advances; p. 94-97.

2. William K. 2008. *The Cracked Tooth Conundrum: Terminology, Classification, Diagnosis, and Management*. Am J Dent; p. 275-282.
3. Mardewi SSA. 2014. *Retak Pada Gigi, Ini Penyebabnya*. Dental Health Maret-April 2014 ed. Jades; p. 8-11.
4. Gary N, Gary A. 2010. *Restoration of Endodontically Treated Teeth*. India. Textbook of Endodontics 2nd ed.; p. 291-407.
5. Santos J. 2009. *Adhesive Cementation of Esthetic Ceramic Extrinsic Restorations*. JCDA; p. 75 (5).
6. Torabinejad M, Walton RE. 2009. *Endodontics Principle and Practice 4th ed*. St. Louis, Missouri. Saunders, an Imprint of Elsevier Inc.; p. 66-74
7. Ferrari M., Scotti R. 2002. *Fiber Posts Characteristics and Clinical Applications*. Masson, Milan. A MediMedia Company; p. 77-79.
8. Garg N, Garg A. Restoration of Endodontically Treated Teeth. Textbook of Endodontics. 2nd ed. India: Jaypee; 2010. p 391 – 407
9. Karla K, Bindal D. March – April 2017. A Novel Sonicfill Composite System used for Bulk Fill Posterior Restorations. Int J Oral Health Med Res 2017;3(6):112-116

**Proceeding
International Scientific Meeting (TINI IV)
& National Congress IKORGI IX**

**Revolutionary Paradigm for the Future Vision of Endodontics and Restorative Dentistry
Surabaya, November, 3rd – 5th, 2017**

