

# caeserean-delivery-of-women- with-covid-19-in-padang- indonesia-a-case-report

*by* Vauline Vauline2

---

**Submission date:** 13-Sep-2021 06:12PM (UTC+0800)

**Submission ID:** 1647307164

**File name:** ery-of-women-with-covid-19-in-padang-indonesia-a-case-report.pdf (904.17K)

**Word count:** 2063

**Character count:** 11243

## Caeserean Delivery of Women with COVID-19 in Padang, Indonesia: A Case Report

Vaulinne Basyir<sup>1\*</sup>, Syahredi R Adnani<sup>1</sup>, Prima Nanda Fauziah<sup>2</sup>

<sup>1</sup>Department of Obstetrics and Gynecology, Faculty of Medicine, Universitas Andalas, Padang, 25127, West Sumatra, Indonesia

<sup>2</sup>Department of Obstetrics and Gynecology, M. Djamil Hospital, Padang, 25127, West Sumatra, Indonesia

<sup>3</sup>Department of Medical Laboratory Technology, Faculty of Health, Universitas Mohammad Husni Thamrin, Jakarta, 13550, Indonesia

### ABSTRACT

Pregnant women become one of the groups which require more attention during COVID-19 pandemic. Pregnant women seem more likely to have a mild symptom of COVID-19 infection or to be an asymptomatic case.

**Case presentation:** A 29 year old female, 36 weeks pregnant, was tested positive for COVID-19 and hospitalized in dr. M Djamil Hospital, Padang, during COVID-19 pandemic. Patient recovered from fever five days prior, and the remaining symptoms included cough and shortness of breath. Patient was eliminated with low segment cesarean section (LSCS/ C-Section), and inpatient for 3 weeks. There was no negative outcome and the baby was tested negative of COVID-1. Likewise, patient was tested negative after 14 days. Further investigation revealed that patient suffered mild COVID-19-related liver injury. The follow-up treatment was albumin injection.

**Conclusion:** There was no vertical transmission of COVID-19 between mother and the baby which suggests caesarean delivery may not increase neonatal infection. However, this case also exhibited that liver dysfunction has been continuingly related to COVID-19 infection and intensive care admission.

**Keywords:** Caeserean, COVID-19, neonatal, pregnant

### Correspondence:

Vaulinne Basyir

Department of Obstetrics and Gynecology, Faculty of Medicine, Andalas University, Padang, West Sumatra, Indonesia

Email: [vaulinne@gmail.com](mailto:vaulinne@gmail.com)

### INTRODUCTION

According to the World Health Organization's report on April 10, 2020, there have been more than 100 countries suffering the outbreaks of COVID-19, and the number of confirmed cases worldwide has exceeded 1.5 million, including more than 90,000 deaths (1). During the pandemic, pregnant women become one of the groups which require more attention. Pregnant women seem more likely to have a mild symptom of COVID-19 infection (1) to be an asymptomatic case (2). It has been reported that pregnant women may be susceptible to COVID-19 infection (3). Thus, prevention and control of COVID-19 infection among pregnant women have become a major concern (4).

Progression of COVID-19 in pregnancy has been currently studied. Although the majority of pregnancies infected by COVID-19 have good outcomes, a recent systematic analysis showed that up to 3% of pregnancies were associated with severe maternal morbidity (5). Mothers with a complicated medical history could be at increased

risk for severe outcomes. The clinical recommendations for managing COVID-19 in pregnancy should be based on lessons learned from the current epidemic (6), which emphasizes the importance of presenting COVID-19 cases associated with complex clinical management. In this study, we reported caesarean delivery in pregnant women with COVID-19 including the maternal and neonatal outcome.

### CASE PRESENTATION

A 29 year old female was transferred from Padang Panjang hospital to dr. M Djamil Hospital, Padang, during COVID-19 pandemic on 27 April due to requirement of NICU. Patient was previously tested positive for COVID-19 twice in Padang Panjang hospital. Patient recovered from fever five days prior to admission, and the remaining symptoms included cough and shortness of breath. Patient was allegedly infected from her husband who works as a nurse. Following the admission, patient's husband were also tested positive and treated afterward.

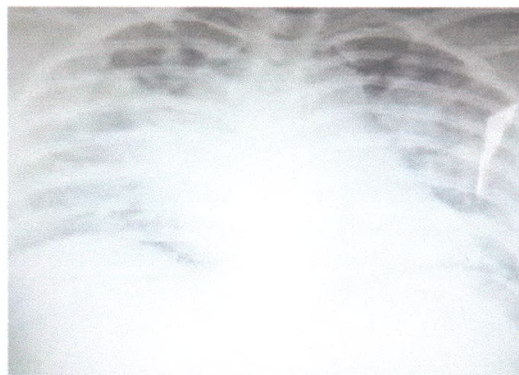


Figure 1. Chest x-ray of patient Day 1 with pneumonia and cardiomegaly.

The physical examination showed a body temperature of 37°C and blood pressure of 110/80 mmHg. Hematological examination showed normal haemoglobin (12.2 g/dL), high white cell count (17,220/mcL), thrombocytopenia (190,000/mcL), and haematocrit 36%. Chest X-ray also revealed suggestive pneumonia and cardiomegaly (Figure 1). Oxygen saturation of patient was 91,8%. Due to symptoms as described above, patient was treated with azithromycin (1x500 mg), oseltamivir (2x75 mg), and vitamin C (3x1 tab). Before LSCS, measurement of SGOT/SGPT level showed 387/245 and hypoalbumin which might indicate COVID-19-related liver injury. The follow-up treatment was albumin injection (> 3 g/dL)

Patients were currently 36 weeks pregnant, and suggested to undergo LSCS to minimize the risk of SARS-CoV-2 transmission. Patient gave birth to an infant with a birth weight of 2000 gr on April 28, 2020. Apgar score was 5/7. Both infant and maternal nasopharyngeal swab samples were carried and tested for SARS-CoV-2 with the WHO-recommended qRT-PCR kit. Swab tests were performed three times overall since the labor, which took place on Mei 5, 11, and 14. Results showed both infant and mother were SARS-CoV-2 negative. Chest x-ray was also conducted which exhibits clearer area of lungs (Figure 2). During her hospitalization, there was no COVID-19-related clinical symptoms.

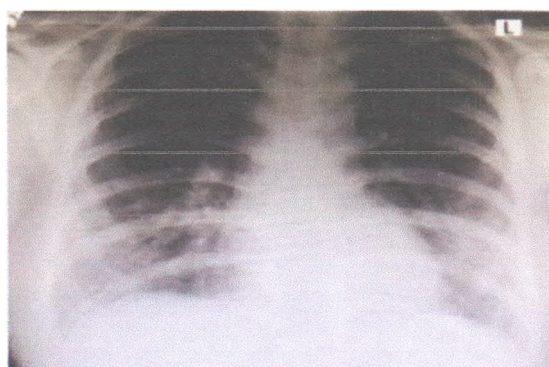


Figure 2. Chest x-ray of patient Day 14.

#### DISCUSSION

This patient came with the most common symptoms of COVID-19, including shortness of breath and fever (7). In addition, the patient has history of frequent close contact with her husband who was a nurse in hospital. Any job that requires human-to-human contact frequently, regardless of the COVID-19 status, is considered having medium exposure risk (8). The median incubation period was estimated to be 5.1 days (95% Confidence interval [CI] 4.5 to 5.8 days) (9).

Furthermore, chest X-ray also revealed suggestive pneumonia. The most distinct features for pneumonia in COVID-19 patients compared to non-COVID-19 pneumonia included a peripheral distribution (80% vs. 57%), vascular thickening (58% vs. 22%) and ground-glass opacity (91% vs. 68%) (10). Abnormality around the costophrenic angle may signify pleural effusion. However, pleural effusion, pericardial effusion, and pneumothorax, are uncommon findings in COVID-19 patients. As COVID-19 pneumonia was monitored using radiographic imaging, lesions and involved lobes were lower as clinical improvement occurs. Moreover, imaging patterns pertinent to the improvement also include gradual resolution of consolidative opacities (11). Chest X-ray is, however, less sensitive compared to CT scan (12).

In this case report, patient was diagnosed with liver injury after giving birth. Liver injury has been frequently reported by a number of studies in patients with severe COVID-19 (13-16) making this organ the most commonly affected alongside the respiratory system. Transient elevation of serum aminotransferases is often documented and a number of factors have been implicated for acute liver damage in severe COVID-19, including severe

hypoxemia due to acute respiratory failure, drug interactions, septic shock and multiorgan dysfunction (13). Although there is insufficient evidence for direct SARS-CoV-2 virus-related hepatocyte injury, liver dysfunction has been continuingly related to severe COVID-19 infection (16) and intensive care admission (17, 18).

There was no neonatal infection and the newborn's swab was also tested negative, which suggests there was no vertical transmission of COVID-19 between mother and the baby. Zhang *et al.* (2020) reported early COVID-19 detection in newborns, implying the potential risk of vertical transmission (19). Although in the vast majority of cases, yet no such evidence has been identified (20, 21). Although the patient was recommended to undergo C-section in this study, there is no convincing indication that the cesarean section is protective against the transmission of COVID-19 (22). Vaginal delivery is not contraindicated in patients with COVID-19 (23,24).

#### CONCLUSION

Taken together, maternal-fetus vertical transmission of COVID-19 has not been established. In addition, caesarean delivery in pregnant women with COVID-19 may not increase the possibility of neonatal infection. While vertical transmission remains unclear, it should be monitored and systematic studies are highly required.

#### ETHICS APPROVAL AND CONSENT TO PARTICIPATE

Ethical approval was not sought due to the nature of the case report. Written informed consent was obtained from the patient for publication of this case report and any

accompanying images. A copy of the written consent is available for review by the Editor of this journal.

#### CONSENT FOR PUBLICATION

The patient provided written informed consent for the publication of potentially identifying images and clinical details on behalf of themselves and their child.

#### COMPETING INTEREST

Authors declare that there is no competing interest.

#### ACKNOWLEDGMENTS

The authors want to thank M.Djamil Hosptial for providing facilities, as well as dedicated staffs involved in this case.

#### REFERENCES

- World Health Organization. Novel Coronavirus (2019-nCoV) Situation Report-83, 2020.
- Mullins E, Evans D, Viner RM, *et al.* Coronavirus in pregnancy and delivery: rapid review. *Ultrasound Obstet Gynecol* 2020;55:586–92.
- Zhu H, Wang L, Fang C, *et al.* Clinical analysis of 10 neonates born to mothers with 2019-nCoV pneumonia. *Transl Pediatr* 2020;9:51–60.
- Qiao J. What are the risks of COVID-19 infection in pregnant women? *Lancet* 2020;395:760–2.
- Zaigham M, Andersson O. Maternal and perinatal outcomes with COVID-19: A systematic review of 108 pregnancies [published online ahead of print, 2020 Apr 7]. *Acta Obstet Gynecol Scand*. 2020
- Liang H, Acharya G. Novel corona virus disease (COVID-19) in pregnancy: What clinical recommendations to follow? *Acta Obstet Gynecol Scand*. 2020;99:439–42.
- Qin C, Zhou L, Hu Z, *et al.* Dysregulation of immune response in patients with COVID-19 in Wuhan, China. *Chin Infect Dis*. 2020 Mar 12; pii: ciaa248.
- Occupational Safety and Health Administration. Worker Exposure Risk to COVID-19. USA Occupational Safety and Health Administration; 2020. <https://www.osha.gov/Publications/OSHA3993.pdf>
- Lauer SA, Grantz KH, Bi Q, *et al.* The Incubation Period of Coronavirus Disease 2019 (COVID-19) From Publicly Reported Confirmed Cases: Estimation and Application. *Ann Intern Med*. 2020 Mar 10.
- Bai HX, Hsieh B, Xiong Z, *et al.* Performance of radiologists in differentiating COVID-19 from viral pneumonia on chest CT. *Radiol*. 2020; 28.
- Salehi S, Abedi A, Balakrishnan S, *et al.* Coronavirus disease 2019 (COVID-19): A systematic review of imaging findings in 919 patients. *Am J Roentgenol*. 2020;215:1–7.
- Susilo A, Rumende CM, Pitoyo CW, *et al.* Coronavirus disease 2019: Tinjauan literatur terkini. *J Penyakit Dalam Indones*. 2020;7(1):45–77.
- Li J, Fan JG. Characteristics and Mechanism of Liver Injury in 2019 Coronavirus Disease. *J Clin Transl Hepatol*. 2020;8(1):13–7.
- Zu ZY, Jiang MD, Xu PP, Chen W, Ni QQ, Lu GM, *et al.* Coronavirus disease 2019 (COVID-19): A perspective from China. *Radiol*. 2020;296(2):E15–25.
- Ren M, Jie L, Jun S, Subrata G, Liang-Ru Z, Hong Y, *et al.* Implications of COVID-19 for patients with pre-existing digestive diseases. *Lancet Gastroenterol Hepatol*. 2020.
- Guan WJ, Ni ZY, Hu Y, Liang WH, Ou CQ, He JX, *et al.* Clinical characteristics of coronavirus disease 2019 in China. *N Engl J Med*. 2020.
- Huang C, Wang Y, Li X, Ren L, Zhao J, Hu Y, *et al.* Clinical features of patients infected with 2019 novel coronavirus in Wuhan, China. *Lancet*. 2020;395:497–506.
- Wang D, Hu B, Hu C, Zhu F, Liu X, Zhang J, *et al.* Clinical characteristics of 138 hospitalized patients with 2019 novel coronavirus-infected pneumonia in Wuhan, China. *JAMA* 2020
- Zhang ZJ, Yu XJ, Fu T, Liu Y, Jiang Y, Yang BX, Bi Y. Novel Coronavirus Infection in Newborn Babies Under 28 Days in China. *Eur Respir J*. 2020 Apr 8. pii: 2000697.
- Yang P, Wang X, Liu P, Wei C, He B, Zheng J, Zhao D. Clinical characteristics and risk assessment of newborns born to mothers with COVID-19. *J Clin Virol*. 2020 Apr 10;127:104356.
- Liu W, Wang J, Li W, Zhou Z, Liu S, Rong Z. Clinical characteristics of 19 neonates born to mothers with COVID-19. *Front Med*. 2020 Apr 13.
- Alzamora MC, Paredes T, Caceres D, Webb CM, Valdez LM, La Rosa M. Severe COVID-19 during pregnancy and possible vertical transmission. *Am J Perinatol* 2020. [doi: 10.1055/s-0040-1710050].
- Zaigham M, Andersson O. Maternal and perinatal outcomes with COVID-19: A systematic review of 108 pregnancies. *Acta Obstet Gynecol Scand* 2020;99:823–9.
- Dashraath P, Wong JL, Lim MX, Lim LM, Li S, Biswas A, *et al.* Coronavirus disease 2019 (COVID-19) pandemic and pregnancy. *Am J Obstet Gynecol* 2020;222:521–31

# caeserean-delivery-of-women-with-covid-19-in-padang-indonesia-a-case-report

## ORIGINALITY REPORT

15%

SIMILARITY INDEX

11%

INTERNET SOURCES

15%

PUBLICATIONS

3%

STUDENT PAPERS

## PRIMARY SOURCES

- 1 Jing Peng, Ruobing Li, Heng Yin, Fei Tang, Hui Xie, Min Li, Yun Zhao. "A case report of a pregnant woman infected with coronavirus disease 2019 pneumonia", Medicine, 2020  
Publication 5%
- 2 [www.actamedindones.org](http://www.actamedindones.org)  
Internet Source 4%
- 3 Anisha Choudhary, Vinita Singh, Murari Bharadwaj, Archana Barik. "Pregnancy With SARS-CoV-2 Infection Complicated by Preeclampsia and Acute Fatty Liver of Pregnancy", Cureus, 2021  
Publication 3%
- 4 [ina-jghe.com](http://ina-jghe.com)  
Internet Source 3%

Exclude quotes On

Exclude bibliography Off

Exclude matches < 3%