

# Expression of epidermal growth factor receptor in advance stage nonkeratinizing nasopharyngeal carcinoma in West Sumatra, Indonesia

*by* Sukri Rahman

---

**Submission date:** 07-Mar-2021 03:23AM (UTC-0800)

**Submission ID:** 1526286592

**File name:** 1.\_Archive\_of\_Oncology.pdf (283.96K)

**Word count:** 2364

**Character count:** 13681

1

# Expression of epidermal growth factor receptor in advance stage nonkeratinizing nasopharyngeal carcinoma in West Sumatra, Indonesia

Sukri Rahman<sup>1</sup>, Histawara Subroto<sup>1</sup>, Bestari J Budiman<sup>1</sup>, Aswiyanti Asri<sup>2</sup>, Hafni Bachtiar<sup>3</sup>

## SUMMARY

**Introduction:** Nasopharyngeal carcinoma is a head and neck cancer with a unique geographic distribution. Indonesia is one of the countries with an intermediate incidence of nasopharyngeal carcinoma where 13,000 new cases are found every year or 6.2 cases/100,000 in population per year. The subcellular mechanism of the nasopharyngeal carcinoma has not been clearly confirmed, but in several studies overexpression of the epidermal growth factor receptor was found. Based on histopathological classification, nonkeratinizing subtypes consisting of differentiated (WHO II) and undifferentiated (WHO III) are the most frequent types in endemic areas, whereas in non-endemic areas the majority of cases are keratinizing subtype (WHO I). The objective of this study was to evaluate the expression of epidermal growth factor receptor in advanced stage nonkeratinizing nasopharyngeal carcinoma as well as to evaluate difference in the expression between differentiated nonkeratinizing (WHO II) and undifferentiated (WHO III) nasopharyngeal carcinoma that may affect the anti-epidermal growth factor receptor therapy for nasopharyngeal carcinoma.

**Methods:** Biopsies from 34 advance stage (stage III and stage IV) nonkeratinizing nasopharyngeal carcinoma consisting of 17 differentiated nonkeratinizing and 17 undifferentiated carcinomas were included in the study. Expression of epidermal growth factor receptor in tumor tissues was investigated by immunohistochemistry (IHC). **Results:** Our results demonstrated that epidermal growth factor receptor was expressed in 23 out of 34 subjects (67.65%). Expression in differentiated nonkeratinizing nasopharyngeal carcinoma was 76.47% (13 out of 17), and it was higher than in undifferentiated carcinoma (58.82%), but there was no statistically significant difference between the two histopathological subtypes ( $p=0.465$ ). **Conclusions:** The epidermal growth factor receptor was expressed in most cases of advance stage nonkeratinizing nasopharyngeal carcinoma, and there was no difference in the expression between differentiated nonkeratinizing (WHO II) and undifferentiated nonkeratinizing nasopharyngeal carcinoma (WHO III).

**Keywords:** nonkeratinizing, nasopharyngeal carcinoma, epidermal growth factor receptor

## INTRODUCTION

Nasopharyngeal carcinoma (NPC) is a malignant tumor of nasopharyngeal epithelium. The etiology of the nasopharyngeal carcinoma is considered to be related with a complex interaction of Epstein-Barr virus (EBV) infection, genetic susceptibility and environmental factors (1-4).

NPC has a unique geographic distribution. Its incidence is highest in southern China, especially in the province of Guangdong (5) reaching 20-50/100,000 in male population per year (1). NPC is predominantly found in certain ethnic groups in China, Southeast Asia and North Africa (6). Indonesia is one of the countries with an intermediate prevalence of NPC (7).

Based on histopathology, World Health Organization (WHO) classified NPC into 3 subtypes: 1) Keratinizing squamous cell carcinoma (WHO I), 2) Nonkeratinizing squamous cell carcinoma, that further classified into differentiated (WHO II) and undifferentiated (WHO III), and 3) Basaloid squamous cell carcinoma (8). Keratinizing squamous cell carcinoma subtypes are rare in endemic areas, while nonkeratinizing squamous cell carcinoma subtypes are seen frequently in endemic areas and are closely associated with Epstein-Barr virus infections (2,9-14).

Nasopharyngeal carcinoma is radiosensitive cancer, but NPC patients frequently experience local recurrence after radiotherapy. The development of targeted therapies specific to NPCs is critical to improving survival and patient prognosis. Revealing the signaling pathway involved in the cancer biology of NPC will provide important information about the targeted therapy for this malignancy.

There are several signaling pathways involved in NPC, the epidermal growth factor receptor (EGFR) being one of the most widely studied (15). Activation of EGFR provides signal for cell proliferation and angiogenesis (16). EGFR expression is also associated with the clinical stage of the tumor such as tumor size, lymph node involvement and presence of distant metastasis that worsen the prognosis (17-19). Recent study proposed EGFR as a new target for the therapy of NPC (15).

The aim of present study was to investigate the expression of EGFR in advanced stage nonkeratinizing NPC as well as to evaluate whether there was a difference in expression of EGFR between differentiated nonkeratinizing NPC (WHO II) and undifferentiated NPC (WHO III) that may affect anti-EGFR therapy of NPC.

## MATERIAL AND METHODS

Biopsies from 34 advance stage nonkeratinizing NPC patients consisting of 17 differentiated nonkeratinizing and 17 undifferentiated nonkeratinizing samples were included in the study. Expression of EGFR in tumor tissue was investigated by immunohistochemistry (IHC).

The study was approved by the Ethics Committee of Andalas University, Faculty of Medicine, Padang, Indonesia (No. 100/KEP/FK/2015).

Immunohistochemical-staining for EGFR was performed on 4-6  $\mu$ m sections of paraffin-embedded blocks using a specific EGFR antibody (Bioss, USA). Standard immunostaining protocols using streptavidin-biotin immunoperoxidase method were utilized for EGFR immunostaining

Arch Oncol 2018; 24(2):20-23

Published Online  
September 24, 2018

<https://doi.org/10.2298/AO180401005R>

<sup>1</sup> Andalas University, Faculty of Medicine, Dr. M. Djamil General Hospital, Department of Otorhinolaryngology, Head and Neck Surgery, Padang, Indonesia

<sup>2</sup> Andalas University, Faculty of Medicine, Dr. M. Djamil General Hospital, Department of Pathology, Padang, Indonesia

<sup>3</sup> Andalas University, Faculty of Medicine, Department of Public Health, Padang, Indonesia

Correspondence to:  
Sukri Rahman, MD, FICS  
[sukrirahman@fk.unand.ac.id](mailto:sukrirahman@fk.unand.ac.id)

Received 2018-04-01

Accepted 2018-08-22



This work is licensed under a Creative Commons Attribution 4.0 license

using anti-EGFR (Bioss, USA). A subject with more than 10% of positively stained cells was considered EGFR positive, and all others were considered EGFR negative. EGFR positively stained cells were scored as +1, +2 and +3 when percentages were 11- 50%, 51- 80% and 81 - 100%, respectively.

Data were analyzed using the Mann-Whitney test to evaluate the differences between single group pairs; the level of statistical significance was set at  $P < 0.05$ .

## RESULTS

### Patients' Characteristics

A total of 34 advance stage nonkeratinizing nasopharyngeal carcinoma samples were analyzed, including 17 specimens of differentiated nonkeratinizing and 17 specimens of undifferentiated carcinoma. The clinicopathological characteristics of the patients were presented in Table 1. Of these patients, 24 were male and 10 were female; 29 were stage IV, and five were stage III according to the American Joint Committee on Cancer staging.

Characteristics	No. of patients (%)
Patients	
Total number	34
Age in years (range)	47.29 (19-75)
Gender	
Male	24 (70.6)
Female	10 (29.4)
Stage	
III	5 (14.70)
IV	29 (85.30)
Histopathological subtype/EGFR Expression	
Differentiated nonkeratinizing	
EGFR positive	13 (76.47)
EGFR negative	4 (23.53)
Undifferentiated nonkeratinizing	
EGFR positive	10 (58.82)
EGFR negative	7 (41.18)

Table 1. Participants' characteristics

### Expression of EGFR in nonkeratinizing Nasopharyngeal Carcinoma

Of 34 tumor tissues, 23 (67.65%) showed positive expression of EGFR (Figs. 1 and 2), including three cases of weakly positive expression (+1), nine cases of intermediately positive expression (+2) and 11 cases of strongly positive expression (+3); the remaining 11 cases (32.35%) showed negative expression.

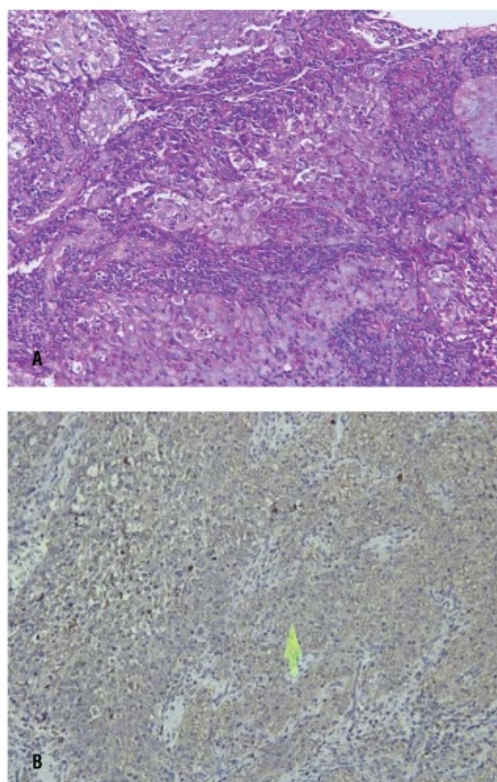


Figure 1. Differentiated nonkeratinizing NPC (hematoxylin-eosin) (A); strongly positive expression of epidermal growth factor receptor in differentiated nonkeratinizing NPC (B). Light microscopy (magnification  $\times 200$ )

### Expression of EGFR in comparison with histopathological subtype

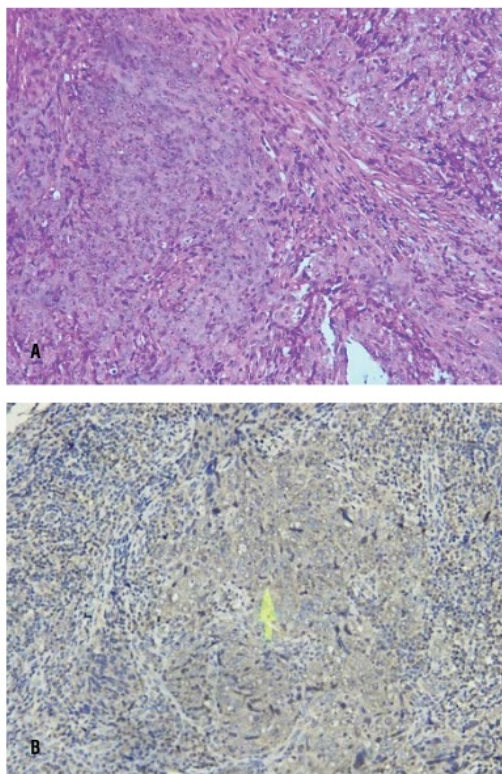
When the subjects were stratified based on histopathological subtype, EGFR expression in differentiated nonkeratinizing was 76.47% (13 out of 17; mean values of the percentage of the cells staining EGFR positive was  $49.4 \pm 34.6$ ), it was higher than undifferentiated NPC (58.82%; mean values of the percentage of the cells staining positive EGFR was  $39.1 \pm 37.7$ ), but there was no statistically significant difference between the two histopathology subtype ( $P=0.469$ ; Table 2).

EGFR	Histopathological Subtype (mean* $\pm$ standard deviation)		P
	Differentiated (n=17)	Undifferentiated (n=17)	
EGFR Expression	49.4 $\pm$ 34.6	39.1 $\pm$ 37.7	0.469

\*Mean values of the percentage of the cells staining positive  
EGFR-Epidermal Growth Factor Receptor

Table 2. Expression of EGFR in comparison with histopathological subtype





**Figure 2** Differentiated nonkeratinizing NPC (hematoxylin-eosin) (A); strongly positive expression of epidermal growth factor receptor in undifferentiated nonkeratinizing NPC (B). Light microscopy (magnification  $\times 200$ )

## DISCUSSION

Nasopharyngeal carcinoma is the most common head and neck cancer in Indonesia, with an incidence rate of 6.2/100,000 in population per year. The incidence of NPC compared with other types of malignancies is rare globally. World Health Organization (WHO) estimated that there were 86,691 new cases of NPC in 2012, only 0.6% of all malignancies diagnosed worldwide (1,7).

Most of NPC patients (75-90%) are discovered at an advanced stage (stage III and IV) that is associated with low life expectancy and increased recurrence rate even after radiotherapy. Therefore, it is very important to investigate new treatments to increase the patient's survival. In several studies of head and neck cancers overexpression of EGFR was found marking EGFR as possible target in cancer therapy (15,16).

In the present study, using immunohistochemistry we analyzed the expression of EGFR and its association with histopathological subtype. EGFR was highly expressed in NPC, EGFR-positive expression was observed in 23 out of 34 NPC patients (67.65%). The rates of positive expression were lower than in prior research by Huang et al. (21) Putti et al. (22) and Chua et al. (23) with 84.1, 83.0 and 89% of EGFR expression in NPCs respectively.

Previous study have reported on association of increased EGFR immunostaining intensity with higher degree of dysplasia (21). Our study did not find any correlation of EGFR expression with histological subtype

(grading). This was similar to that reported in research of Hujii et al. and Huang et al. (20, 21) that did not find a correlation of EGFR overexpression with any of the clinicopathological variables, including histopathological subtype. These result suggests that target therapy with anti-EGFR do not different based on histopathological subtypes of nonkeratinizing NPC.

## CONCLUSION

In conclusion, the EGFR was expressed in most cases of advance stage nonkeratinizing nasopharyngeal carcinoma, and there was no difference in EGFR expression between the differentiated (WHO II) and undifferentiated (WHO III) nonkeratinizing nasopharyngeal carcinoma.

## Declaration of Interests

Authors declare no conflicts of interest.

## REFERENCES

- 1 Ma J, Cao S. The Epidemiology of Nasopharyngeal Carcinoma. In: Lu J.J, Cooper J.S, Lee A.W.M., editors. Nasopharyngeal Carcinoma. Berlin Heidelberg; 2010.p.1-7
- 2 Chang ET, Adami HO. The Enigmatic Epidemiology of Nasopharyngeal Carcinoma. *Cancer Epidemiologic Biomarkers Prev* 2006;15(10):1765-77
- 3 Turkoz FP, Celenkoglu G, Dogu GG, Kalender ME, Coskun U, Alkis N et al. Risk Factors of Nasopharyngeal Carcinoma in Turkey- an Epidemiological Survey of the Anatolian Society of Medical Oncology. *Asian Pacific J Cancer Prevention* 2011;12:3017-21
- 4 Ekburaranawat W, Ekspanyaskul C, Brennan P, Kanka C, Tepsuwan K, Temisyath S et al. Evaluation of Non-Viral Risk Factors for Nasopharyngeal Carcinoma in Thailand: results from a Case-control Study. *Asian Pacific J Cancer Prev* 2010;11:929-32
- 5 Huang YZ, Zhang BB, Ma N, Murata M, Tang A, Huang GW. Nitrate and Oxidative DNA Damage as Potential Survival Biomarkers for Nasopharyngeal Carcinoma. *Med Oncology* 2011;28:377-84
- 6 Thompson LDR. Malignant Neoplasma of the nasal cavity, paranasal sinuses and nasopharynx. In: Head and Neck Pathology, Thompson LDR editors. Elsevier Philadelphia 2006.p.170-3
- 7 Roezin A. Faktor Risiko pada Karsinoma Nasofaring. *Maj patologi Indonesia* 2002; 11(4):42-45
- 8 Chan J.K.C., Bray F, Mc Carron P, Foo W. Nasopharyngeal carcinoma in Barnes L, Eveson JW, Reichart P, Sidrasky D editors. WHO classification of tumors: Pathology and genetics head and neck tumors Lyon 2005.p.85-97
- 9 Guo X, Johnson RC, Deng H, Liao J, Guan L, Nelson GW, Tang M et al. Evaluation of Nonviral Risk Factors for Nasopharyngeal Carcinoma in a High-Risk Population of Southern China. *Int.J.Cancer* 2009;124:2942-7
- 10 Wei, William I, Nasopharyngeal Cancer. In Bailey, Byron, Johnson, Jonas T, Newlands, Shawn D, editors. Head and Neck Surgery Otolaryngology Fourt Edition. Lippincot Williams and Wilkins; 2006.p.1658-68
- 11 Tulalamba W, Janvilisri T. Nasopharyngeal Carcinoma Signaling Pathway: An Update on Molecular Biomarkers. *International Journal of Cell Biology* 2012.1-10
- 12 Brennan B. Nasopharyngeal carcinoma. *Orphanet Journal of Rare Diseases* 2006;1(1):23
- 13 Zeng MS, Zeng YX. Pathogenesis and Etiology of Nasopharyngeal Carcinoma. In: Lu J.J, Cooper J.S, Lee A.W.M., editors. Nasopharyngeal Carcinoma. Berlin Heidelberg; 2010.p.9-20

- 14 Lutzky VP, Moss DJ, Chin D, Coman WB, Parsons PG, Boyle GM. Biomarkers for Cancers of the Head and Neck. *Clin Med ENT* 2008; 1:5-15
- 15 Scaltriti M, Baselga J. The Epidermal Growth Factor Receptor Pathway: A Model for Targeted Therapy. *Clin Cancer Res* 2006;12:5268-72.
- 16 Yarden Y, Sliwkowski MX. Untangling the ErbB signaling network. *Nat Rev Mol Cell Biol* 2001;2:127-37.
- 17 [2] [2] for CI. Biological modifiers as potential radiosensitizers: targeting the epidermal growth factor receptor family. *Semin Oncol* 2000;27(suppl 11):15-20.
- 18 Newby JC, Johnston SR, Smith IE dkk. Expression of epidermal growth factor [2] [2] ptor and c-erbB2 during the development of tamoxifen resistance in human breast cancer. *Clin Cancer Res* 1997;3:1643-1651.
- 19 Chen X, Yeung TK, Wang Z. Enhanced drug resistance in cells coexpressing ErbB2 with EGF receptor or ErbB3. *Biochem Biophys Res Commun* 2000;277:757-763.
- 20 Fujii M, Yamashita T, Ishiguro R, Tashiro M, Kameyama K. Significance of Epidermal Growth Factor Receptor and Tumor Associated Tissue Eosinophilia in the Prognosis of Patients With Nasopharyngeal Carcinoma. *Auris Nasus Larynx* 2002;29:175-81
- 21 Huang TL, Li CF, Huang HY, Fang FM. Correlations between Expression of Epidermal Growth Factor Receptor (EGFR), Phosphorylated EGFR, Cyclooxygenase-2 and Clinicopathological Variables and Treatment Outcomes in Nasopharyngeal Carcinomas. *Chang Gung Med J* 2010;33:619-26
- 22 Putti TC, To KF, Hsu HC, Chan AT, Lai GM, Tse G et al. Expression of epidermal growth factor receptor in head and neck cancers correlates with clinical progression: a multicentre immunohistochemical study in the Asia-Pacific region. *Histopathology* 2002 Aug;41(2):144-51. [2]
- 23 [2] [2] a DT, Nicholls JM, Sham JS, Au GK. Prognostic Value of Epidermal Growth Factor Receptor Expression in Patients With Advanced Stage Nasopharyngeal Carcinoma Treated with Induction Chemotherapy and Radiotherapy. *Int J Radiat Oncol Biol Phys* 2004;59:11-20

# Expression of epidermal growth factor receptor in advance stage nonkeratinizing nasopharyngeal carcinoma in West Sumatra, Indonesia

## ORIGINALITY REPORT

9%

SIMILARITY INDEX

11%

INTERNET SOURCES

5%

PUBLICATIONS

0%

STUDENT PAPERS

## PRIMARY SOURCES

1

[talenta.usu.ac.id](http://talenta.usu.ac.id)

Internet Source

6%

2

[scholar.unand.ac.id](http://scholar.unand.ac.id)

Internet Source

3%

Exclude quotes Off

Exclude matches Off

Exclude bibliography Off