



EACCME  
European Accreditation Council for Continuing Medical Education

# Certificate

International Conference on Clinical PET-CT and Molecular Imaging (IPET 2015 ): PET-CT in the era of multimodality imaging and image-guided therapy  
Vienna, Austria (5.-9.10.2015)

has been accredited by the European Accreditation Council for Continuing Medical Education (EACCME) to provide the following CME activity for medical specialists.

International Conference on Clinical PET-CT and Molecular Imaging (IPET 2015 ): PET-CT in the era of multimodality imaging and image-guided therapy  
is designated for a maximum of, or up to 27 European CME credits (ECMEC).

Dr. Aisyah Elliyanti  
Indonesia

Each medical specialist should claim only those credits that he/she actually spent in the educational activity.  
The EACCME is an institution of the European Union of Medical Specialists (UEMS). [www.uems.net](http://www.uems.net).  
Through an agreement between the European Union of Medical Specialists and the American Medical Association, physicians may convert EACCME credits to an equivalent number of AMA PRA Category 1 Credits™. Information on the process to convert EACCME credit to AMA credit can be found at [www.ama-assn.org/go/internationalcme](http://www.ama-assn.org/go/internationalcme).  
Live educational activities, occurring outside of Canada, recognized by the UEMS-EACCME for ECMEC credits are deemed to be Accredited Group Learning Activities (Section 1) as defined by the Maintenance of Certification Program of The Royal College of Physicians and Surgeons of Canada



# Follicular Thyroid Cancer With Skull Metastasis: A Case Report.

AISYAH ELLIYANTI

Faculty of Medicine Andalas University/Dr.M.Djamil Hospital Padang,  
West Sumatera-Indonesia. aellyanti@yahoo.com

## ABSTRACT

Follicular thyroid cancer is differentiated thyroid cancer (DTC). It is relatively common of malignancy but skull metastasis is rarely case. We report a case of follicular thyroid cancer with skullmetastasis. A 51 year-old Indonesian woman was referred to our department with growing mass at her head. Biopsy of the mass indicated a tumor of thyroid origin. The patient underwent a near-total thyroidectomy. Pathology result confirmed a follicular thyroid cancer. Radioiodine scintigraphy shows no uptake of I-131 at the skull area. Bone scan confirmed hot spot spot at parietal bones and cold lesion at left of frontal bone.

Prognosis of follicular thyroid cancer is poorer once distant metastases have occurred. Furthermore, non-responsiveness to radioiodine can be caused by cell dedifferentiation. This is due to the fact that cell dedifferentiation results in loss of ability to accumulate I-131. Appropriate treatment is essential key for successful management of this patient.

Keywords : Follicular thyroid cancer, skull metastasis, radioiodine uptake, scintigraphy

## BACKGROUND

Thyroid cancer is relatively common of malignancy but skull metastasis rarely case. Follicular thyroid cancer is differentiated thyroid cancer (DTC). It is a slow growing tumor and has a good prognosis. However if a distant metastasis is present the prognosis usually becomes poor. Iodine-131 (I-131) has been used for 70 years to treat thyroid cancer. Patients with follicular and papillary cancer who undergo total or near total thyroidectomy are subsequently treated with I-131. However, bone metastases sometime fail to uptake radioiodine.

## METHODOLOGY

A 51 year-old woman was referred to our department complaining of lump size increase at her head. In beginning, she was diagnosed with adenomatous thyroid but eight years later, she complained of growing mass at her head. Biopsy results of the mass confirmed a follicular thyroid cancer. She underwent a total thyroid surgery and was followed by I-131 treatment (100 mCi) at other hospital and never came back to the hospital for follow up. She came to our hospital and we examined thyroid-stimulating hormone (TSH), thyroglobulin, anti-thyroglobulin level proceed with thyroid scintigraphy. She received 29,5 mCi of I-131, was followed by whole body scintigraphy four three days later.

## RESULTS

After four weeks of thyroxin withdrawal, TSH, thyroglobulin, and anti-thyroglobulin results are 2.77 mU/L, 1.78 ng/mL, and negative, respectively. Level of TSH does not increase after thyroxin withdrawal. Thyroid scintigraphy using  $^{99m}\text{Tc}$  showed no uptake in thyroid bed. Furthermore, she received 29.5 mCi of I-131. Image from iodine-131 whole body scan does not show uptake of I-131 at thyroid bed and skull area.  $^{99m}\text{Tc}$ -methylene diphosphonate (MDP) bone scintigraphy demonstrated high uptake at right and left parietal bones and cold lesion at frontal bone. Hot spot also notice at 1/3 distal of right femur bone.

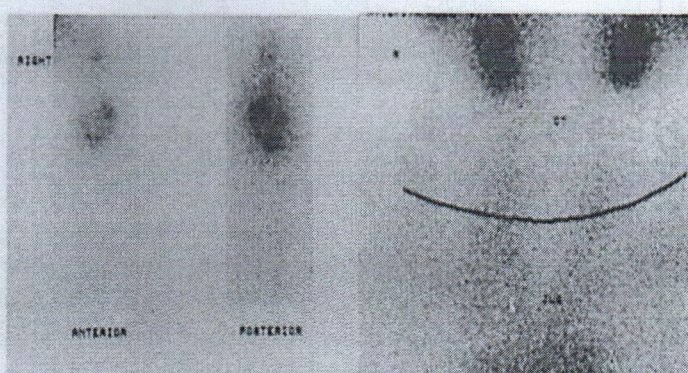


Figure 1: Scintigraphy result after received 29,5 mCi of NaI-131. (A) Whole body image. (B) Thyroid bed image.

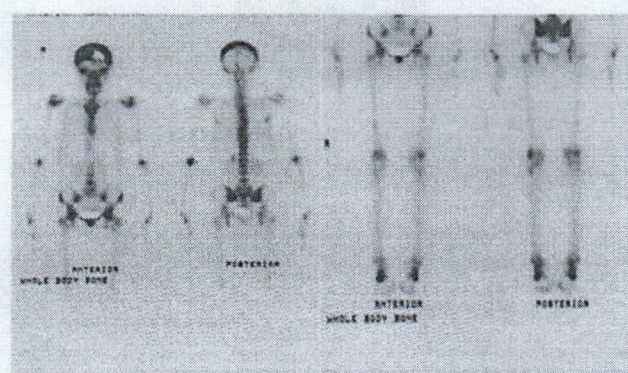


Figure 2 : Bone scan ( $^{99}\text{Tc}$ -MDP) shows high uptake at right and left parietal bones