



# Certificate of Attendance



This is to certify that

**M. Hidayat, MD**

Has attended as

**Speaker**

The 3<sup>rd</sup> East Java Ophthalmology Workshop & Symposium

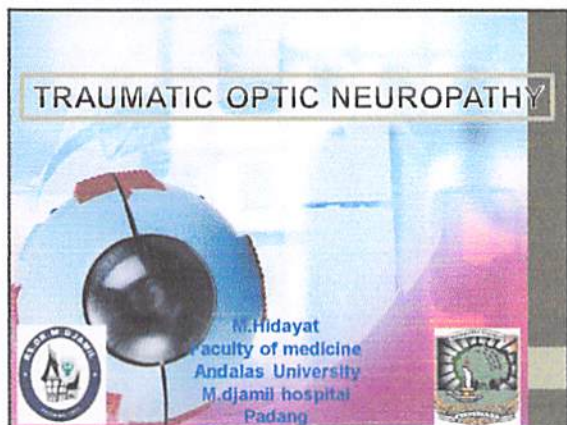
JW-MARRIOT Hotel, Surabaya

April 22<sup>nd</sup> - 23<sup>rd</sup>, 2016

Wimbo Sasono, MD  
Chairman of East Java IOA

Muh. Firmansjah, MD  
Chairman of Organizing Committee





### INTRODUCTION

- Traumatic Optic Neuropathy (TON) is in impact injury which results in partial or complete loss of function.
- Result of severe head trauma, orbit, globe or may be associated with little or no evidence of head injury.
- 0.5% to 5% of closed head injuries
- 1 and in 2.5% of maxillofacial trauma and midface trauma

### INTRODUCTION

- The optic nerve : vulnerable to indirect & direct trauma functional impairment of vision.
- varieties of direct optic nerve injury : optic nerve avulsion, compressive, optic nerve sheath haemorrhage, orbital haemorrhage & orbital emphysema.

### INTRODUCTION

- Visual loss is usually instantaneous with impact. Delayed visual loss is also reported
- Approximately 50% of the cases with permanent visual loss
- No proven form of treatment for traumatic optic neuropathy
- Controversy exists concerning the value of high dose corticosteroids and the role of decompressing surgery or no treatment ?

### INTRODUCTION

- The prevalence of severe initial visual loss (light perception and no light perception ) : = 43%-78%.
- Turner (1943) : 100% of 46 patient with TON, no light perception
- Hooper(1951) : 14 of 21 patient (67%) no light perception

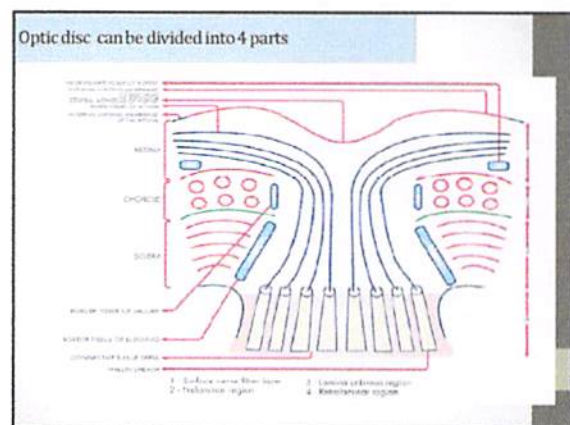
### ANATOMY OF OPTIC NERVE HEAD

Intraocular (1mm)  
Intraorbital (20-30 mm)  
Intracanalicular (6-10 mm)  
Intracranial (6-10 mm)

### ANATOMY OF OPTIC NERVE HEAD

**INTRAOCULAR REGION  
(4 parts)**


- Superficial nerve fiber layer
- Prelaminar area
- Lamellar area
- Retrolaminar area



## 2. Intraorbita

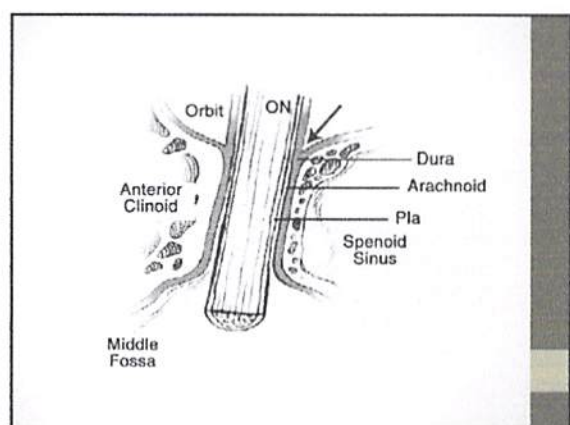
Before passing into the optic canal the nerve → annulus of Zinn

At the optic canal, the dural sheath → the periosteum completely immobilizing the nerve.



## 3. Intracanalicular

- Optic nerve → foramen optikum → the optic canal
- Optic canal lies in the lesser wing of sphenoid
- Medial wall of the channel → sphenoid sinus



Anatomy of the optic nerve

### 4. Intracranial

- Two optic nerves lie above the ophthalmic arteries  
→ posteriorly the cavernous sinus → optic chiasm
- The chiasm : right and left optic tracts
  - lateral geniculate bodies
- From these bodies arise the geniculocalcarine pathways
  - primary visual cortex

- ZH : Zinn Haler
- PV : Pial vessel
- SPCA: Short Posterior Ciliary Arteries
- CRA : Central Retinal Artery
- CRV : Central Retinal Vein

**FIGURE 9-4** Schematic representation of the macular blood supply to the optic nerve and retina. CRA, central retinal artery; CRV, central retinal vein; SPCA, short posterior ciliary arteries; ZH, Zinn-Haller; PV, pial vessels. From Klein, L.F. (1993) *Neuro-Ophthalmology*. San Francisco: American Academy of Ophthalmology, 1993: 20 (with permission).

### Vascularization of the optic Nerve

#### 1. Intraocular → optic nerve head

- Nerve fiber layer → the retinal arterioles
- The prelaminar region → vessel of the ciliary region
- Lamina cribrosa → ciliary vessels
- Retrolaminar → ciliary and retinal circulation

### Vascularization of the optic nerve

#### 2. Intraorbita

Periaxial system

- Internal carotid artery
- Ophthalmic artery
- Long posterior ciliary artery
- Short posterior ciliary artery
- Lacrimal artery
- Central retinal artery

Axial system

- Branches of CRA

### Vascularization of the optic nerve

#### 3. Intracanalicular

the periaxial system of vessel mainly branches from the ophthalmic artery

### Vascularization of the optic nerve

#### 4. Intracranial

Periaxial system of vessel  
Contributed by 4 sources :

- internal carotid artery
- anterior cerebral artery
- ophthalmic artery,
- anterior communicating artery



### TRAUMATIC OPTIC NEUROPATHY

#### ETIOLOGY

- TON refers to an acute injury of the optic nerve secondary to trauma.
- The optic nerve axons may be damage either directly or indirectly
- Visual loss may be partial or complete

### PATHOPHYSIOLOGY

- Primer & secondary mechanism of injury
- Mechanical forces are considered to be the primary mechanism of injury.
- Cause optic nerve :
  - lacerations,
  - partial or complete avulsion,
  - contusion necrosis,
  - disruption of the nerve's vascular supply
- and cause permanent damage.

### PATHOPHYSIOLOGY

Primer & secondary mechanism of injury

- Mechanical forces are considered to be the primary mechanism of injury.

Optic nerve : lacerations, partial or complete avulsion, contusion necrosis, disruption of the nerve's vascular supply

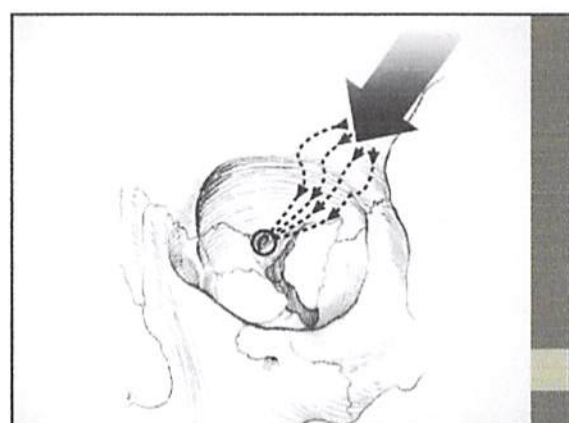
permanent damage.

### PATHOPHYSIOLOGY

- Blunt trauma to the frontal bone → forces being transmitted to intracanalicular → fracture of the optic canal.
- Indirect injury : axons is thought to be induced by shearing forces that are transmitted to be fibers or to the vascular supply of the nerve

Blunt trauma to the frontal bone → forces being transmitted to intracanalicular → fracture of the optic canal.

Indirect injury : axons is thought to be induced by shearing forces that are transmitted to be fibers or to the vascular supply of the nerve



## PATHOPHYSIOLOGY

### . A secondary mechanism ,

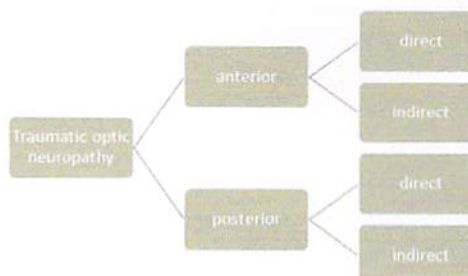
The vascularity of the optic nerve is disturbed, rise in intraluminal pressure or reactive vasospasm.

The generation of free radicals and arachidonic acids, lipid peroxidation, production of inflammatory mediators such as bradykinin, loss of calcium homeostasis with disruption of cellular function, glutamate-induced excitotoxicity, cell-mediated inflammation, and initiation of neuronal apoptosis

### . The optic nerve swelling

- exacerbate retinal ganglion cell degeneration

## Classification



## Direct :

- Usually involve direct anatomical disruption of the optic nerve caused by injuries to the head, face and orbit due to projectiles
- Direct injuries tend to produce severe and immediate visual loss, with little likelihood of recovery.
- Direct optic nerve injury is less common because of the protection offered by the bony orbit.

## Indirect injuries

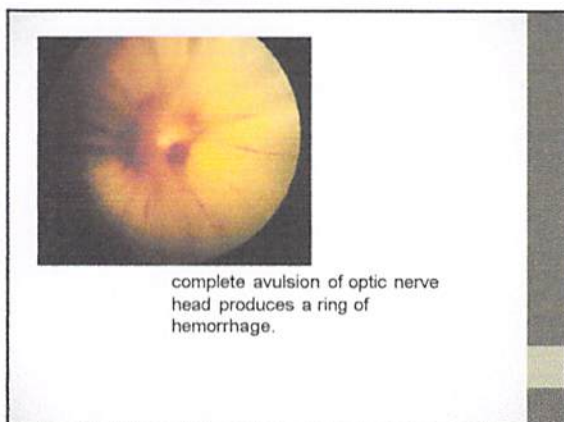
- Result from deforming forces applied to the bony orbit, or by motion of the globe, where the optic nerve absorbs energy concentrated at the orbital apex
- Absence of open wounds but with a positive history of blunt frontal trauma.
- The most frequent form is posterior indirect traumatic optic neuropathy , blunt head trauma that transmits force to the optic nerve, resulting in contusion or sometimes transection.
- The least common are anterior indirect injuries, associated with sudden rotation of the globe from blunt trauma..

## CLINICAL ASSESSMENT

- TON : usually follows head trauma with or without a history of loss of consciousness.
- Present with reduced visual acuity which may be as profound as only light perception or even no light perception.
- If better visual acuity on presentation, loss of colour vision is a common finding.

## CLINICAL DIAGNOSTIC

- Visual acuity
- Pupillary reflex : RAPD (+)
- Fundus examination
  - partial & complete avulsion of optic nerve head.
- Neuroimaging (CT scan , MRI)
- Color vision
- Visual field
- Visual evoked potential (VEP)



### IMAGING

**CT scan.**

a. Axial Ct Scan shows avulsion of the optic nerve on the left side (arrow)  
 b. Orbital exploration confirmed optic nerve avulsion

### TREATMENT

Remains Controversial

- Three major therapeutic options :
  - Corticosteroids
  - Surgical optic nerve decompression
  - Combination of the two

### TREATMENT

**Medical therapy :**  
 Steroids (1980s) to provide neuroprotection

- In 1990, NASCIS 2 : mega dose corticosteroid therapy
- The I O N T Sin 1999 : no clear benefit for either corticosteroids or optic canal decompression in patients of TON
- A coherence systematic review (2007): no convincing data of additional benefits of steroids over observation alone
- Mc Cann & Seiff : have improvement vision
  - 28% spontaneous
  - 50% patients treated with corticosteroid,
  - 57% optic nerve decompression
  - 62% with corticosteroid & optic nerve decompression.

### Using corticosteroid :

- Patient cooperative and without contraindication and within 8 h oh injury
- Dosage recommendation : from 1 g/day up to megadosages (30 mg/kg loading dose)

**Categorized**

1. Moderate dose (60-100 mg of oral prednisolone)
2. High dose (1 gram of IV methylprednisolone/day)  
 VA improves after 24 hour, tapering to oral
3. Mega dose (30 mg/kg loading dose IV methylprednisolone, followed by 5,4 mg/kg/hr for 24 hours)

VA improves after 24 hour, tapering to oral

### Categorized

Moderate dose (60-100 mg of oral prednisolone)  
 High dose (1 gram of IV methylprednisolone/day)  
 VA improves after 24 hour, tapering to oral  
 Mega dose (30 mg/kg loading dose IV methylprednisolone, followed by 5,4 mg/kg/hr for 24 hours)

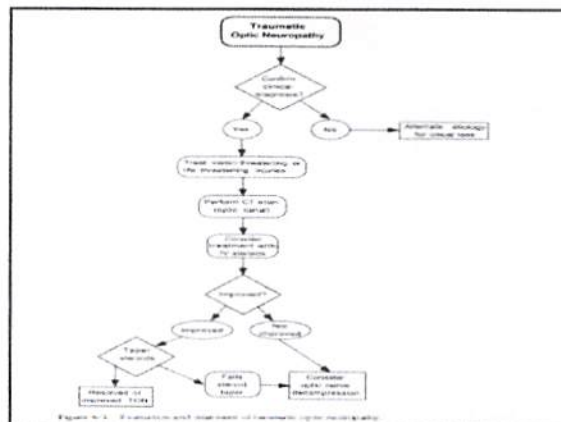
Visual function improves → after 24 hour tapering to oral corticosteroid



### SURGICAL THERAPY

1. Surgical intervention for TON → empirical
2. The reduction of bone fragment impinging
3. Opening the canal to reduce compression

The goal of optic nerve decompression is to provide surgical relief of pressure on the intracanalicular segment of the optic nerve



### PROGNOSIS

- Depends in part on whether is direct or indirect
- Direct injury tend to produce severe and immediate visual loss
- Indirect optic neuropathies

### CONCLUSION

- Management Traumatic optic neuropathy was controversial
- Research on neurotogenic and neurotrophic agents such as monosialogangliosides and neurotrophic growth factors has had promising results
- Right now, the scientific consensus is that the best treatment for TON may be no treatment.
- Patients can spontaneously recover from TON, have ranged from 20 to 57 %
- The prognosis of an optic nerve injury depends in part on whether it is direct or indirect.

Do No Harm

