



CERTIFICATE OF APPRECIATION

Presented to

M. HIDAYAT

For her/his invaluable contribution as

SPEAKER

at the

• **3rd ASEAN OPHTHALMOLOGY SOCIETY CONGRESS 2017** •

JAKARTA, INDONESIA 19, 20 AND 21 JULY, 2017

Ari Djatikusumo, MD

Chairman

M Sidik, MD

President AOS

Symposium
SK PB IDI No 01435/PB/A.4/09/2017
Participant 12. Speaker 14. Moderator 6. Committee 3

Didactic Courses: Cornea, Lens & Refractive Surgery
Workshops: Glaucoma, Orbita, Trauma
SK PB IDI No 01436/PB/A.4/09/2017
Participant 4. Speaker 14. Moderator 6. Committee 3

Workshop Retina
SK PB IDI No 01437/PB/A.4/09/2017
Participant 5. Instructor 6. Committee 4

CLINICAL PROFILE OF BILATERAL OPTIC NEURITIS IN M. DJAMIL HOSPITAL PADANG

M. Hidayat, MD

Neuro-Ophthalmology Subdivision
Ophthalmology Department M. Djamil Hospital
Medical Faculty of Andalas University
Padang – West Sumatera

Optic Neuritis

Inflammation, disintegration and demyelination of the optic nerve

Unilateral or Bilateral

Temporary or permanent visual loss

Age of onset : 16-55 yo, male and female : 2:1

Incidence : 1 and 5 in 100.000

Clinical Definite Multiple Sclerosis presents in 15-20% of optic neuritis

Clinical Manifestation

Acute Visual Loss

Main symptom : 90% central, and the rest is peripheral in superior or inferior.

Visual loss is worsen after a few hours, days, even minutes

20/20 to light perception

Peak is within a few days to weeks. Maximal recovery in 2-3 weeks and takes up to 6 months

Orbital pain

Orbital pain exacerbated by eye movement

- Last for weeks
- Caused by stimulation of optic nerve inflammation to trigeminal nerve in optic nerve sheath
- Color vision and photophobia
- Phosphenes perception (flashing lights with noise or eye movement) and decreased depth perception

Visual Field

Variety of visual field defect, usually central scotoma

Less common defect : arcuate, superior or inferior altitudinal, quadranopia, peripheral constriction, cecentral, bitemporal or a left or right hemianopic defect.

Recovery phase : central scotoma → small, dim, central or paracentral defect.

Less severe optic neuritis : blurry vision

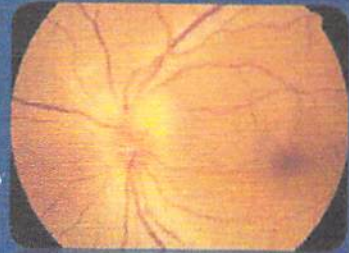Uhthoff phenomenon : large variation in visual field on different days and at different time on the same day

Contrast Sensitivity and Color Vision

- Both are reduced in acute optic neuritis.
- Contrast sensitivity even worse than visual loss
- Farnsworth examination shows specific sensitivity.
- Dyschromatopsia happen after optic neuritis and related to the time course of disease
- Blue yellow defect often in acute phase, green red after 6 months
- ONTT : no spesific color defect related to optic neuritis

Fundus Finding

- Optic disc is elevated and hyperemic. Lesion adjacent to head of optic nerve cause papillitis with minimal blood vessel enlargement and rarely peripapil hemorrhage
- Vitritis : anterior optic neuritis → infection or inflammation related to multiple sclerosis
- Retrobulbar optic neuritis : normal optic disc
- MS : 75% patient shows pallor of optic disc in temporal or diffused and nerve fiber layer atrophy



Differential Diagnosis

AION

Leber hereditary optic neuropathy (LHON)

Other systemic and infection disease : sarcoidosis, HIV, CMV

Bilateral Optic Neuritis

Bilateral acute optic neuritis in adults is related to multiple sclerosis (MS), about 10-75%

Morrissey et al. found bilateral acute optic neuritis in 23 adult and 5 patient (22%) with MS

Bradley dan Whitty : classified the patient to unilateral optic neuritis (71%), bilateral simultaneous (7%), bilateral neuritis and non simultaneous might present within 3 months. No significant recovery time in bilateral or unilateral

Rischbieth and Hutchinson support this finding

Bilateral Optic Neuritis

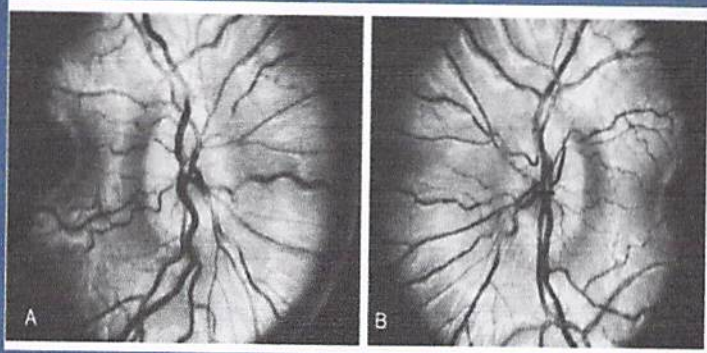
Children

- Follow viral syndrome
- Not associated with multiple sclerosis

Adults

- Rare cases, particularly without known systemic inflammatory or autoimmune disease

ONTT : 48% patients with defect in one eye will damage the fellow eye
→ bilateral optic neuritis
Bilateral optic neuritis often in children and related to viral infection



Treatment

- Treatment is for all patients are based on ONTT protocol

TABLE 1.2. Treatment recommendations of the Optic Neuritis Treatment Trial

- Corticosteroid treatment should be considered when the brain MRI scan reveals multiple abnormalities consistent with MS.
- Methylprednisolone 250 mg IV should be administered to patients with optic neuritis over a 30-min period every 6 h for a total of 12 doses, or 1 g IV methylprednisolone in one dose over 1 h each day for 3 consecutive days, followed by a prednisone taper at 1 mg/kg/day orally for 11 days. Prednisone should be tapered to 20 mg on day 15 and to 10 mg on days 16 and 18. There are no current studies to demonstrate a clinically significant difference between administering IV methylprednisolone four times a day and giving it all in one dose.
- IV methylprednisolone decreases the incidence of more neurological deficits within the 2 years after treatment, especially in patients who had initial abnormal brain MRI scans.
- IV methylprednisolone does not improve the ultimate visual outcome.

Objective

Establish the clinical profile of bilateral optic neuritis in adults

Investigate the efficacy of intravenous steroid therapy

Investigate the extent of visual recovery

Methods

Retrospective View

- Medical record of patients diagnosed with bilateral optic neuritis from January 2016 to April 2017

Inclusion Criteria

- New onset of acute bilateral visual loss caused by optic nerve disease
- Had complete clinical examination
- Had follow up clinical examination at least 3 months

Methods

Exclusion Criteria

- Previous multiple sclerosis
- Previous optic neuritis or myelopathy
- Known systemic disorders associated with optic neuropathy
- Use of medications related to toxic optic neuropathy
- Known uveitis
- Known systemic or intracranial neoplasm

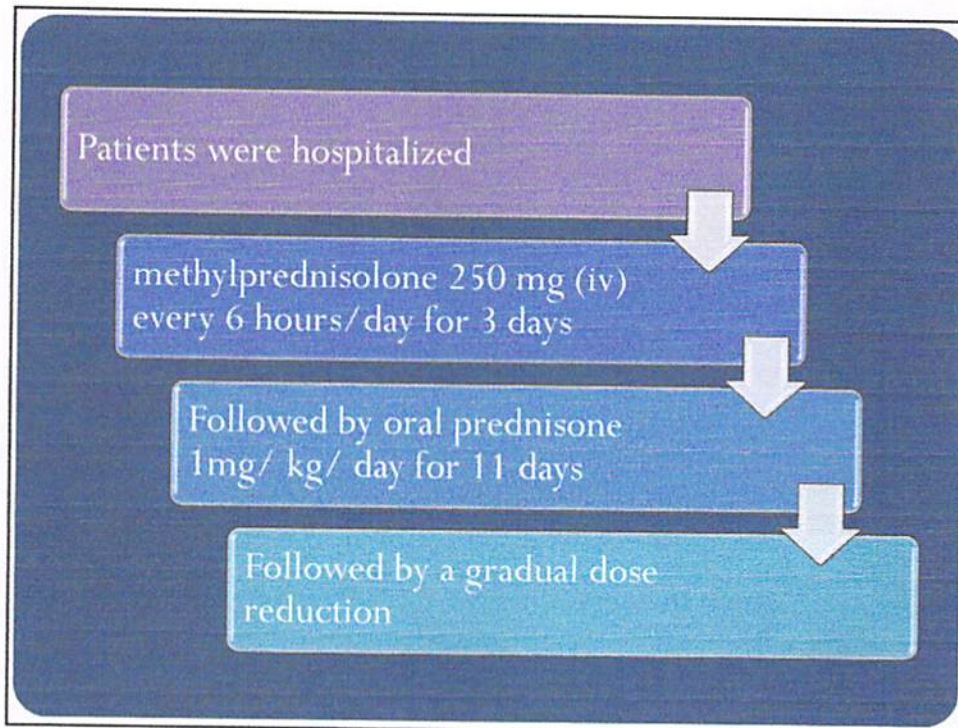
Visual function testing : follow up of 3 days, 2 weeks, and 3 months.

Visual acuity

Perimetry

Presence or absence of pain with extraocular movement.

Neuro-imaging (CT Scan)



Result

→ 9 patients had bilateral optic neuritis vision from January 2016 to January 2017

- 3 Men, 6 women → 21 - 45 years old

- Orbital pain was found in all 9 patients
- Visual acuity ranging from finger counting to hand movement, with sudden onset

- RE : 1/300 to 3/60, with mostly 1/300 : 4 eyes (44%), 1/60 : 2 eyes (22%), 2/60 2 eyes (22%), 3/60 : 1 eye (11%)
- LE : 1/300 to 5/60, mostly 1/60 : 2 eyes (22%), 4/60 and 5/60 : 1 eye (11%)

- All patients were treated metil prednisolon IV 4x 250 mg in 3 days (total 12x)
- Followed by oral prednisone 11 days : 1 mg/kg BB, and tapering off

Perimetry : mostly
unspecific → central
scotoma, quadranopia
scotoma, general depressed,
and multiple focal

CT scan within normal
limit

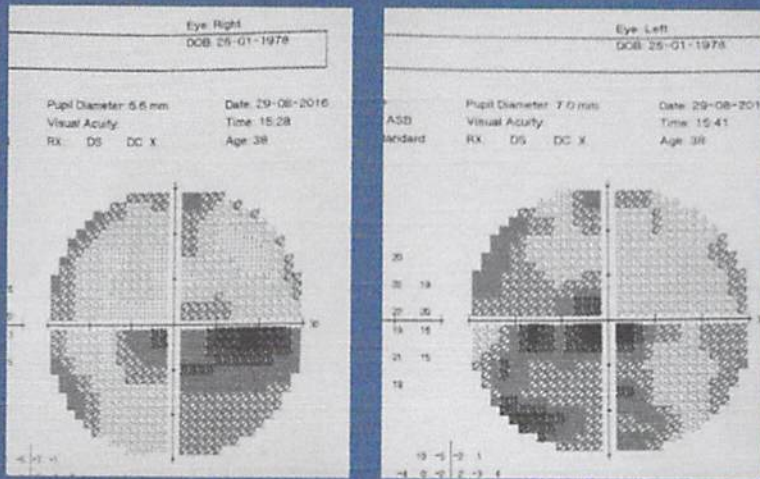
After 2 weeks Treatments

- Better outcome : improvement in visual acuity for both eyes
(RE : 8 eyes, LE : 8 eyes)

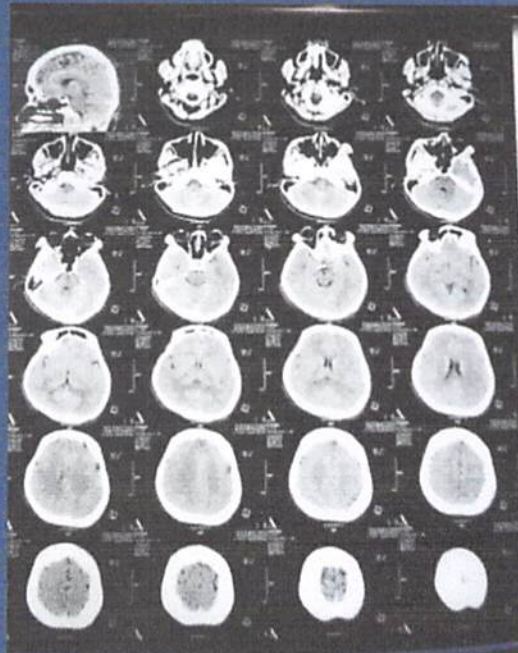
- 1 patient with 1/60 both eyes :

41 y.o female, came with chief complaint blur vision on left eye since a month ago, right eye was blur since 6 months ago with VOD 1/300 and VOS 1/60 without improvement after treatment. After 2 weeks VODS remain 1/60.

Perimetry Examination



Brain CT Scan



No.	Age	Sex	Visual Acuity Before Treatment		Visual Acuity after 3 days treatments		Visual Acuity after 2 weeks treatments		Visual Acuity after 3 months treatments	
			RE	LE	RE	LE	RE	LE	RE	LE
1	30	P	3/60	5/60	6/9	1/60	6/7.5	6/9	6/6F	6/7,5
2	21	P	1/300	4/60	6/21	6/9	6/12	6/6	6/10	6/6
3	41	P	1/300	1/60	1/60	6/6 f	1/60	1/60	1/60	1/60
4	30	P	1/60	3/60	6/9	6/7.5	6/7.5	6/7.5	6/6	6/6
5	39	L	2/60	3/60	6/6 f	6/12	6/6 f	6/6 f	6/6	6/6
6	23	L	2/60	2/60	6/7.5	6/7.5	6/6	6/6	6/6	6/6
7	45	L	1/300	2/60	6/12	6/6 f	6/7.5	6/6	6/6	6/6
8	43	P	1/300	1/60	6/7.5	1/60	6/6f	6/6f	6/6	6/6
9	35	L	1/60	1/300	6/6 f	6/9	6/6	6/6f	6/6	6/6

Discussion

- Our study shows prevalence of bilateral optic neuritis in female is more than male with ratio 2:1. All literatures stated that female outnumbered male, thus, supporting our study.
- Orbital pain was found in all patients. In the literature stated that pain within and around the affected eye arises before or at the time of the onset of visual loss in about 90% of cases.
- Sudden visual loss in both eyes is the chief complain from all patients in this study, suitable to the main sign of optic neuritis.

- Visual outcome in 8 patients are good, with 20/20 after 2 weeks follow up.
- Visual outcome for bilateral optic neuritis is better after treatment of IV methylprednisolone and oral prednisone, reaching up to 20/20 in 6 months to 1 year of follow up. The benefit of this treatment regiments is greatest in the first 15 days.
- The remaining 1 patient in this study has poor visual outcome with 1/60 for both eyes after treatment. This patient came to us after 6 months of visual loss (late condition).

CONCLUSION

Acute bilateral optic neuritis occurs rarely in adults

The bilateral visual loss improves with corticosteroid therapy especially when patients come early.

Neurological disease or recurrent visual loss may not develop over 3 months of follow up. Follow up should be continued until 6 months to 1 year.

This study shows bilateral optic neuritis without systemic processes or infectious etiology, supported by good laboratory findings and normal CT scan.

